Published online: 2019-03-08

A Pushed Descending Aorta due to Hiatal Hernia

Cetin Gecmen, MD[1] Muzaffer Kahyaoglu, MD[1] Arzu Kalayci, MD[1] Ender Ozgun Cakmak, MD[1] Ozkan Candan, MD[1] Ahmet Guner, MD[1] Ibrahim Akin Izgi, MD[1] Cevat Kirma, MD[1]

[1] Department of Cardiology, Kartal Kosuyolu Heart and Research Hospital, Istanbul, Turkey

AORTA 2018;6:107–108.

Address for correspondence Cetin Gecmen, MD, Department of Cardiology, Kartal Kosuyolu Heart and Research Hospital, 34846, Kartal, Istanbul, Turkey (e-mail: koronerr@hotmail.com).

Abstract

A 91-year-old female patient was admitted to hospital for evaluation of transcatheter aortic valve implantation. A chest radiography showed a hiatal hernia, and the stomach and duodenum appeared in the thoracic cavity. The descending aorta was pushed by the stomach and duodenum.

Keywords
- descending aorta
- aortic displacement
- hiatal hernia

A 91-year-old female patient was admitted to hospital for evaluation of transcatheter aortic valve implantation. A chest radiography showed a hiatal hernia, and the stomach and duodenum appeared in the thoracic cavity (►**Fig. 1A**). The patient had severe aortic stenosis, and a contrast-enhanced thoracoabdominal computed tomography (CT) was performed to evaluate vascular structures. A contrast-enhanced CT scan of the chest in the coronal plane revealed normal diameter and non-tortuous ascending aorta (►**Fig. 1B**). The descending aorta was pushed by the stomach and duodenum (►**Fig. 1C**). A contrast-enhanced CT scan of the chest in the sagittal plane showed the pushed descending aorta (►**Fig. 1D**). A contrast-enhanced CT scan of the chest in axial plane showed the descending aorta on the left side of the vertebra (►**Fig. 1E**). The abdominal aorta travels on the left side of the vertebra (►**Fig. 1F**). A successful intervention was done, and the patient was discharged from the hospital.

received
June 1, 2017
accepted after revision
November 5, 2018

DOI https://doi.org/10.1055/s-0039-1679910.
ISSN 2325-4637.

Copyright © 2018 by Thieme Medical Publishers, Inc., 333 Seventh Avenue, New York, NY 10001, USA. Tel: +1(212) 584-4662.

License terms

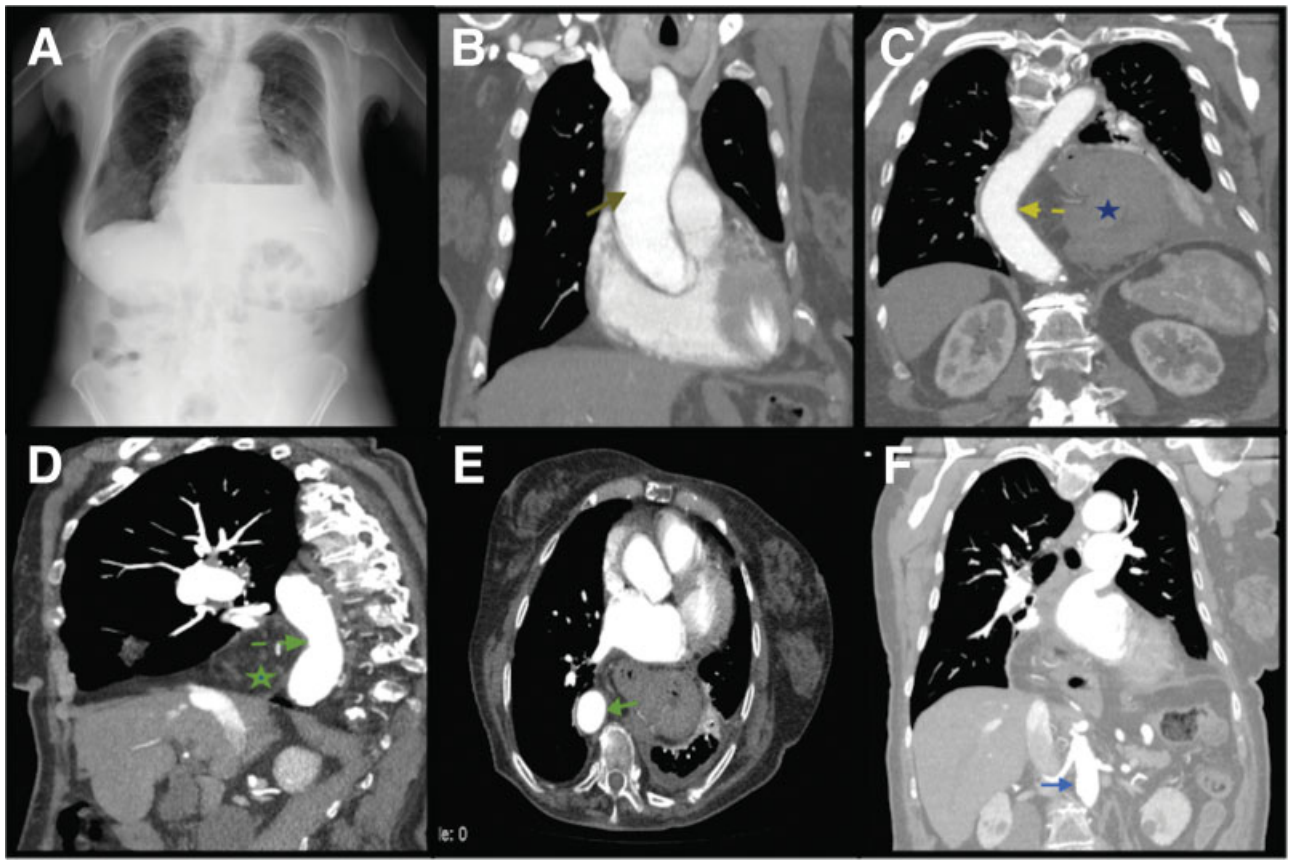

Fig. 1 (**A**) A chest radiography showing hiatal hernia and stomach in the thoracic cavity. (**B**) A contrast-enhanced computed tomography (CT) scan of the chest in coronal plane showing non-tortuous ascending aorta. (**C**) A contrast-enhanced CT scan of the chest in coronal plane showing the pushed descending aorta. (**D**) A contrast-enhanced CT scan of the chest in sagittal plane showing the pushed descending aorta. (**E**) A contrast-enhanced CT scan of the chest in axial plane showing the descending aorta on the left side of the vertebra. (**F**) Abdominal aorta travels on the left side of the vertebra.

Funding
None.

Conflict of Interest
The authors declare no conflict of interest related to this article.

Acknowledgements
None.