

# Duodenal Stenosis with Diaphragmatic Hernia—A Rare Combination—Delayed Diagnoses with Barium Study

Rupa Ananthasivan<sup>1</sup> Sudarshan Rawat<sup>1</sup> Pramesh Reddy<sup>1</sup> Pooja G. Patil<sup>1</sup>  
Chittur Narendra Radhakrishnan<sup>2</sup>

<sup>1</sup>Department of Radiology, Manipal Hospital, Bangalore, Karnataka, India

<sup>2</sup>Department of Pediatric Surgery, Manipal Hospital, Bangalore, Karnataka, India

**Address for correspondence** Rupa Ananthasivan, DNB, Department of Radiology, Manipal Hospital, Bangalore 560017, Karnataka, India (e-mail: rupanth@yahoo.com).

J Gastrointestinal Abdominal Radiol ISGAR 2019;2:69–73

## Abstract

Duodenal stenosis is part of a spectrum of disorders due to non-cannulization of the fetal gut lumen occurring in 11 to 13 weeks of fetal life. The diagnosis is often made in the neonatal period owing to bilious vomiting. The authors present a case of a 9-year-old boy who was diagnosed by an upper gastrointestinal study that showed a hugely dilated stomach filled with food residue and a dilated first part of the duodenum with an abrupt narrowing in the second part of the duodenum in keeping with duodenal stenosis. There was no associated malrotation (a known association), but the delayed images showed a surprising finding of herniation of large bowel loops into the thorax suggestive of a congenital diaphragmatic hernia (Bochdalek type). Both these findings were confirmed on surgery, and the patient underwent duodenoduodenostomy and diaphragmatic hernia repair and is doing well on follow-up. This case is unusual due to the rare association of duodenal stenosis with congenital diaphragmatic hernia and delayed diagnosis. Both these pathologies most often present in the neonatal period, and delayed diagnosis is most often seen with associated trisomy 21 that was not the case in our patient.

## Keywords

- diaphragmatic
- duodenal
- hernia
- stenosis

## Introduction

Duodenal stenosis and congenital diaphragmatic hernia are usually diagnosed in the neonatal period, and the occurrence of both these pathologies in the same individual is rare.

We present a 9-year-old boy who was diagnosed with these two pathologies by a barium study and successfully treated.

## Case Presentation

A 9-year-old boy was referred for an ultrasound of the abdomen and further imaging, with complaints of recurrent vomiting and failure to gain weight.

The referring pediatrician commented that the child appeared malnourished despite hailing from a well-to-do family. He also documented the presence of visible gastric peristalsis.

An ultrasound revealed a normal appearance of the liver, spleen, biliary tree, and kidneys but a hugely dilated fluid-filled stomach (►Fig. 1) though the mother denied feeding the boy for the past 6 hours. She revealed that he often vomited partially digested food hours after his meal and sometimes brought up a meal he had the previous day.

An abdominal X-ray erect showed large fluid level in region of the stomach (►Fig. 2), supine was performed, which revealed a dilated stomach (►Fig. 3). There was poor visualization of gas shadows in the small and large bowel, which gave a gas-less-like appearance to the abdomen apart from the dilated stomach.

An ill-defined opacity was identified in the left lung base with poor visualization of the diaphragmatic contour. This was thought to be pneumonia secondary to aspiration.

An upper gastrointestinal (GI) study was performed with barium.

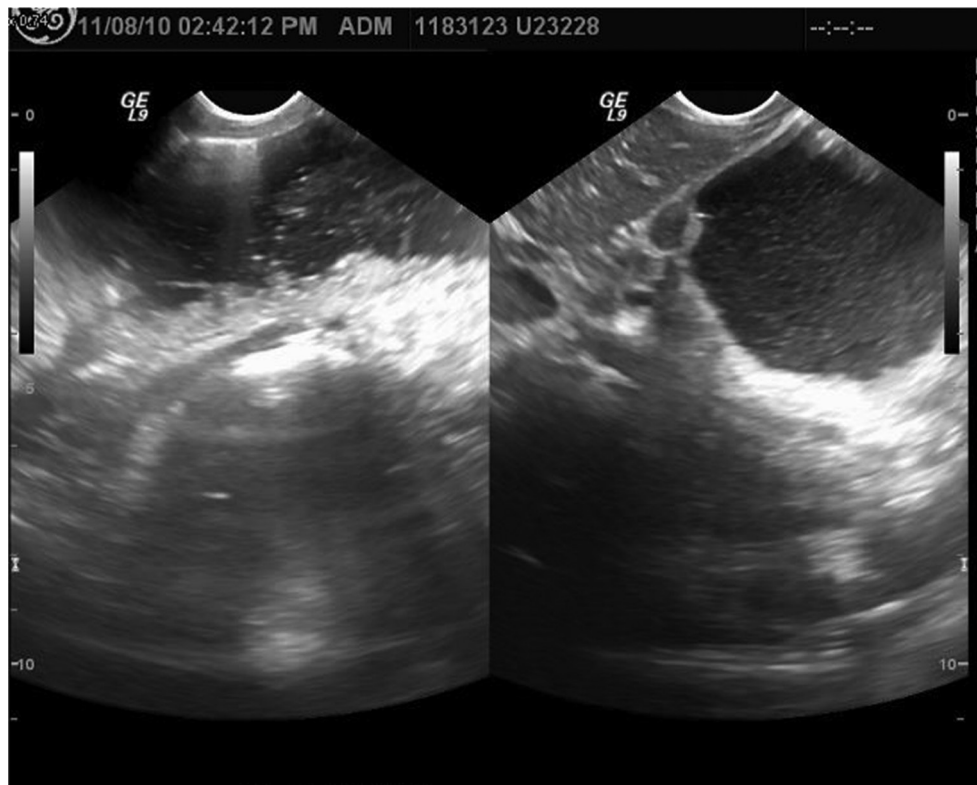
received  
August 30, 2018  
accepted after revision  
January 3, 2019

DOI <https://doi.org/10.1055/s-0039-1683770>

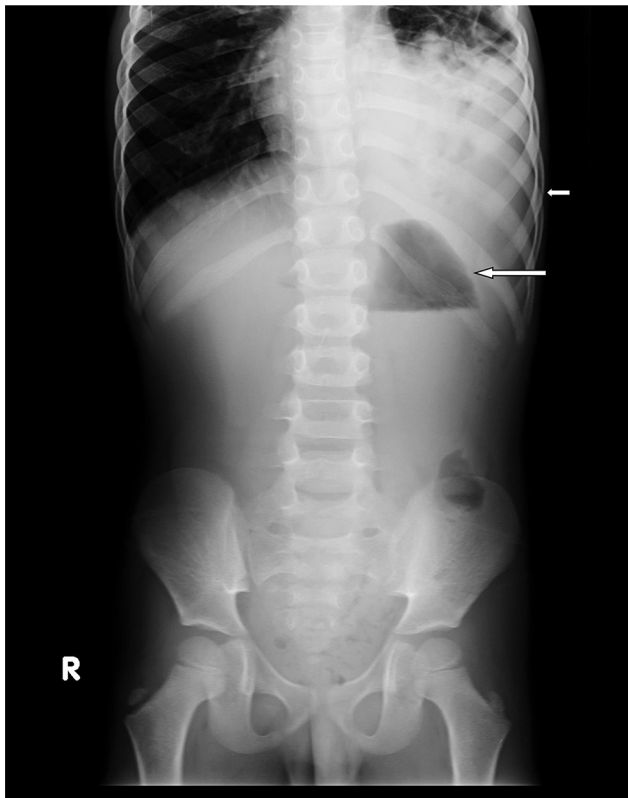
©2019 Indian Society of  
Gastrointestinal and Abdominal  
Radiology

License terms

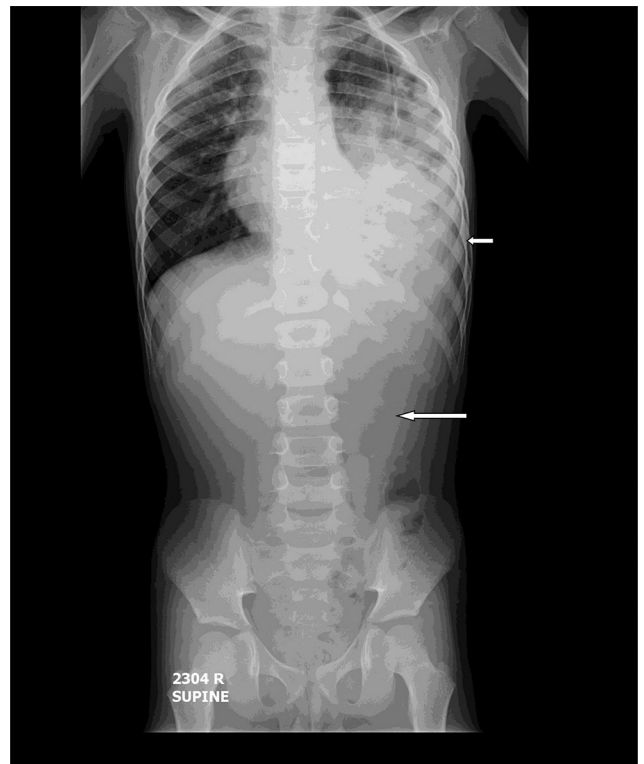




**Fig. 1** Dilated fluid-filled stomach identified on ultrasound.



**Fig. 2** Abdominal X-ray erect shows a large fluid level in the dilated stomach (white arrow).



**Fig. 3** Abdominal X-ray AP (anteroposterior)-supine shows a dilated fluid-filled stomach (white arrow) with a gas-less appearance in the rest of the abdomen. Patchy opacities in the left lower thorax with associated lucencies and nonvisualization of the left diaphragmatic contour (short white arrow).

The patient was made to swallow 200 to 250 mL of 50% barium.

The passage of barium through the esophagus was studied fluoroscopically in the anteroposterior (AP) and right anterior oblique (RAO) positions and was found to be unremarkable.

The barium-filled stomach was studied particularly in the AP and RAO positions.

The stomach was hugely dilated with hyper-peristalsis (accounting for the presence of visible gastric peristalses noted by the referring pediatrician).

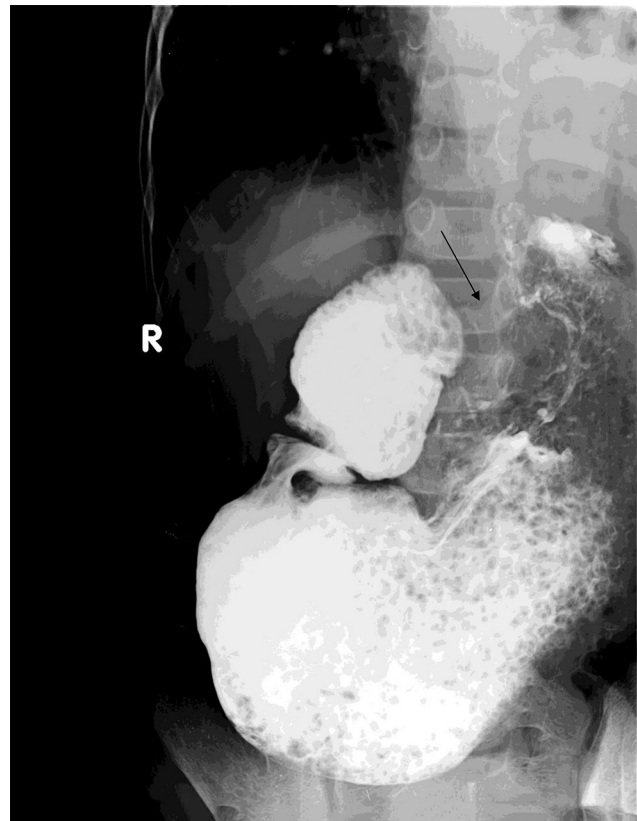Food residue was identified in the dilated stomach as filling defects (►Fig. 4).

The first part of the duodenum was also dilated with an area of abrupt narrowing at the second part with slow passage of contrast beyond (►Figs. 5, 6).

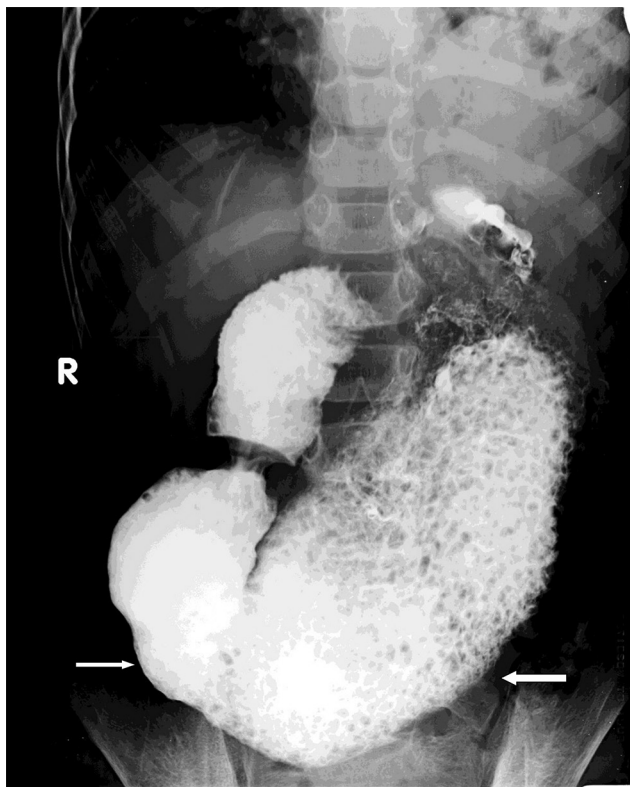
A delayed image was acquired to assess the degree of emptying, which revealed a surprising finding. The opacity in the left lung base was due to large bowel loops that were herniated into the thoracic cavity (►Fig. 7).

The child was taken up for surgery that confirmed duodenal stenosis with associated thick Ladd's band across the second part of the duodenum. No malrotation was present.

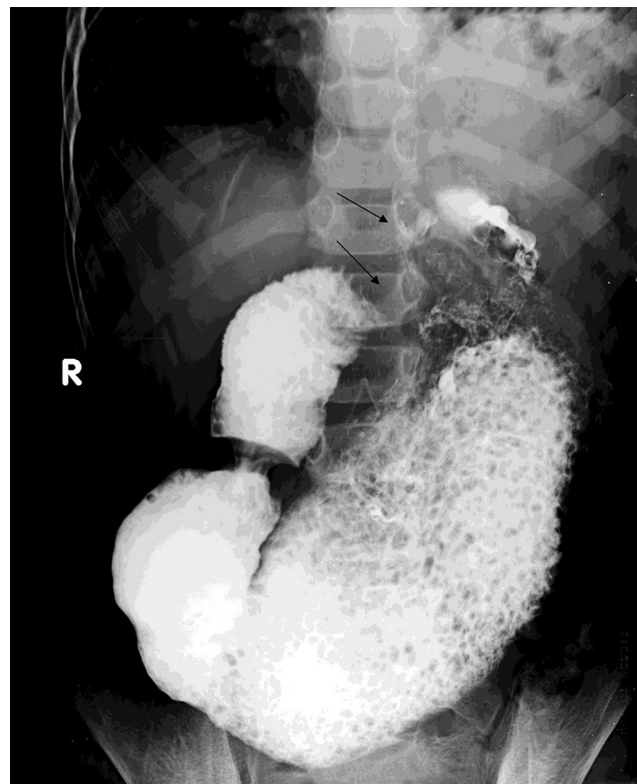
A left-sided posterolateral diaphragmatic hernia (Bochdalek) with herniation of large and small bowel loops and spleen was identified.



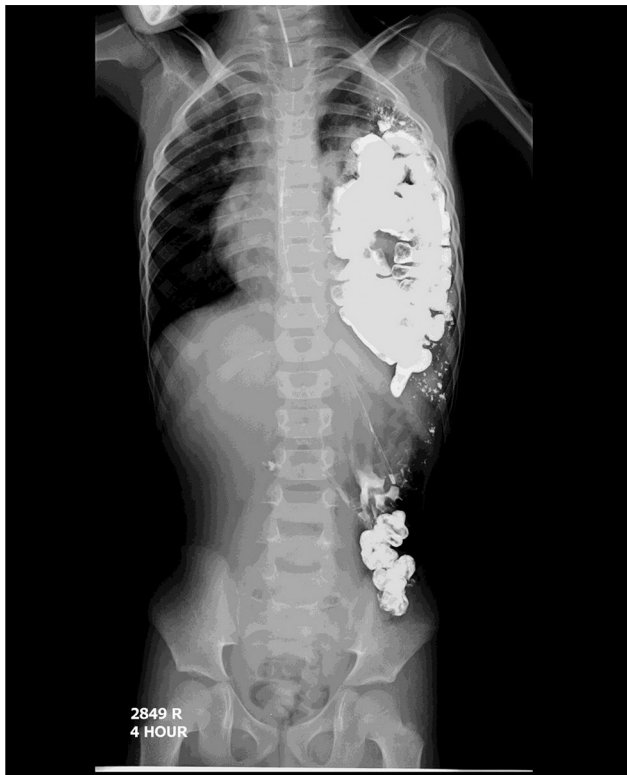**Fig. 5** Dilated first part of the duodenum is shown on the right anterior oblique (RAO) view with an abrupt narrowing at D2 (black arrow).



**Fig. 4** Upper gastrointestinal barium study shows a hugely dilated stomach with food residue (white arrows).



**Fig. 6** Dilated first part of the duodenum is shown on the right anterior oblique (RAO) view with an abrupt narrowing at D2 (black arrows).



**Fig. 7** Delayed imaging shows herniation of large bowel into the left thoracic through a diaphragmatic hernia (black arrow).

The diaphragmatic contents were reduced, and the diaphragmatic defect was repaired.

The thick bands across the second part of the duodenum were released, and a duodenoduodenostomy was performed. The postoperative period was uneventful.

The patient is doing well on follow-up. He tolerates feeds well and is gaining weight.

## Discussion

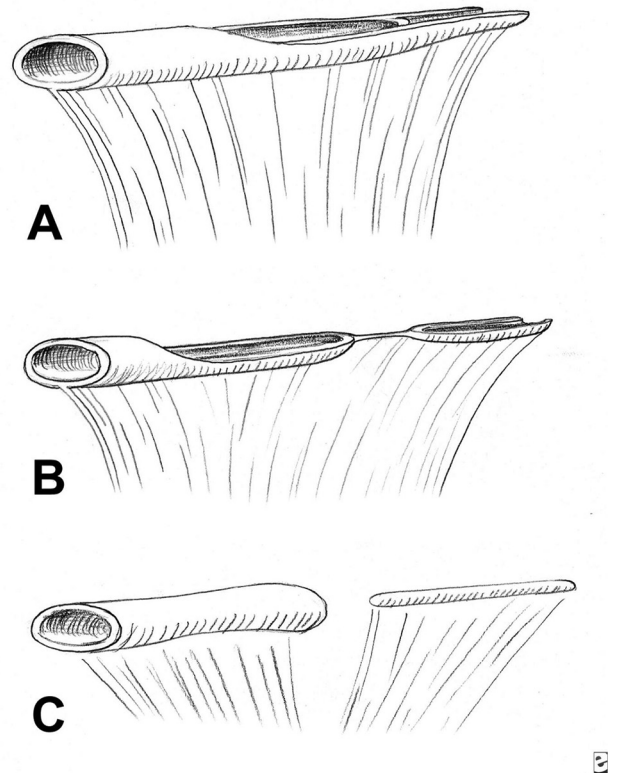
Neonatal duodenal obstruction is quite rare. The incidence has been estimated as 1 in 5,000 to 25,000 births,<sup>1</sup> and the ratio of atresia: stenosis is 3:2 to 2.2:1.<sup>2</sup>

Duodenal atresia and stenosis are part of a spectrum of disorders due to non-cannulization of the fetal gut lumen occurring in the 11 to 13 weeks of fetal life.<sup>3</sup>

In duodenal atresia, the intestinal lumen is completely obliterated, whereas in duodenal stenosis, the lumen is partly occluded or narrowed by a web or a diaphragm (► **Fig. 8**). An intrinsic abnormality can coexist with an extraluminal one that can contribute to the luminal narrowing such as annular pancreas, Ladd's band, or preduodenal portal vein (► **Table 1**). The obstruction or narrowing is usually in the second part of the duodenum distal to the ampulla of Vater and rarely in the third part of the duodenum.

Duodenal stenosis may be diagnosed in the antenatal scan and is seen as a dilated fluid-filled stomach and duodenum with or without polyhydramnios.<sup>4</sup>

Duodenal stenosis most often presents in the neonatal period with bilious vomiting though there are case reports



**Fig. 8** Schematic representation of duodenal non-cannulization abnormalities. (A) Duodenal diaphragm. (B) Duodenal stenosis. (C) Duodenal atresia.

**Table 1** Common causes of congenital duodenal stenosis

Congenital causes of duodenal obstruction	
1	Duodenal atresia
2	Duodenal web/diaphragm
3	Duodenal stenosis
4	Annular pancreas
5	Ladd's bands/Volvulus malrotation
6	Predudodenal portal vein
7	Abdominal situs inversus
8	Duodenal hemangioma
9	Choledochal cyst

of delayed diagnosis.<sup>5</sup> Delayed diagnosis is often seen in patients with Down's syndrome and is attributed due to the associated mental retardation. Our patient is of normal intelligence.

Known associations of duodenal stenosis are VACTERAL abnormalities, trisomy 21, annular pancreas, and malrotation. Approximately 30% of trisomy 21 are associated with duodenal abnormalities.<sup>4,6</sup>

The association with congenital diaphragmatic hernia is rare with only one previous case reported.<sup>7</sup>

The diaphragm is formed by the septum transversum, pleuroperitoneal membrane, dorsal mesentery of the esophagus, and body wall. Congenital diaphragmatic hernia results from failure of the pleuroperitoneal canals



(PPCs) to close at the end of the embryonic period (eighth gestational week). The body wall components are complete only by 12th gestational week.<sup>8</sup>

Congenital diaphragmatic hernia can occur as an isolated condition; however, associated anomalies are relatively common and include pulmonary hypoplasia (also a complication), bronchopulmonary sequestration, trisomy (13, 18, 21), Turner's syndrome, congenital cardiac anomalies, and neural tube defects.<sup>8</sup> Duodenal abnormalities are not known associations.

The overlap between the duodenal recannulization process and the later half of the diaphragmatic fusion may account for this unusual combination, and an embryological insult between 11 and 13 weeks is postulated to have caused both these birth defects.

Duodenal atresia presents with a characteristic double-bubble sign on plain radiographs. This suffices to make the diagnosis in the correct clinical scenario. Duodenal stenosis may show a dilated stomach depending on the chronicity as in our case.

Upper GI contrast studies are the method of diagnosis in partial duodenal obstruction.<sup>9</sup> Barium is used unless perforation is suspected.<sup>10</sup> The procedure should be tailor-made, and care should be taken not to overfill the dilated stomach, which may obscure the duodenal narrowing. Emptying the stomach through a nasogastric tube before upper GI contrast study is useful.<sup>10</sup> Aspiration into the lungs should be avoided while using water-soluble contrast agents, particularly in infants. Previously used high osmolality ionic contrasts were known to produce severe pulmonary edema. Though rare with the newer nonionic low and iso-osmolar contrast agents, aspiration should be guarded against.

There is dilatation of the stomach and the first part of the duodenum. The stenosis is most often in the second part of the duodenum distal to the ampulla of Vater<sup>9</sup> and is seen as an abrupt short-segment narrowing. A wing-sock appearance is seen in case of a duodenal web.

Associated abnormalities include annular pancreas and Ladd's bands and malrotation, which may be diagnosed in

the same study. An apparent raised dome of the diaphragm or lucencies in the lower thorax should raise the suspicion of an associated congenital diaphragmatic hernia—though rare—and the examination should be tailored for the same with delayed images.

This case study illustrates the importance of proper history taking and selecting the appropriate radiologic investigation for diagnosis.

#### Conflict of Interest

None declared.

#### References

- 1 Kimura K, Loening-Baucke V. Biliious vomiting in the newborn: rapid diagnosis of intestinal obstruction. *Am Fam Physician* 2000;61(9):2791–2798
- 2 Schnauffer L. Duodenal atresia, stenosis and annular pancreas. In: Welch KJ, Randolph JG, Ravitch MM, et al, eds. *Pediatric Surgery*. 4th ed. Chicago, IL: Year Book Medical; 1991:829–837
- 3 Berrocal T, Torres I, Gutiérrez J, Prieto C, del Hoyo ML, Lamas M. Congenital anomalies of the upper gastrointestinal tract. *Radiographics* 1999;19(4):855–872
- 4 Choudhry MS, Rahman N, Boyd P, Lakhoo K. Duodenal atresia: associated anomalies, prenatal diagnosis and outcome. *Pediatr Surg Int* 2009;25(8):727–730
- 5 Smith GV, Teele RL. Delayed diagnosis of duodenal obstruction in Down syndrome. *AJR Am J Roentgenol* 1980;134(5):937–940 STEN
- 6 Mirza B, Sheikh A. Multiple associated anomalies in patients of duodenal atresia: a case series. *J Neonatal Surg* 2012;1(2):23
- 7 Castle SL, Naik-Mathuria BJ, Torres MB. Right-sided congenital diaphragmatic hernia, hepatic pulmonary fusion, duodenal atresia, and imperforate anus in an infant. *J Pediatr Surg* 2011;46(7):1432–1434
- 8 Chavhan GB, Babyn PS, Cohen RA, Langer JC. Multimodality imaging of the pediatric diaphragm: anatomy and pathologic conditions. *Radiographics* 2010;30(7):1797–1817
- 9 Kaddah SN, Bahaa-Aldin KHK, Aly HF, Hassan HS. Congenital duodenal obstruction. *Ann Pediatr Surg* 2006;2(2):130–135
- 10 Gupta AK, Guglani B. Imaging of congenital anomalies of the gastrointestinal tract. *Indian J Pediatr* 2005;72(5):403–414