

A Rare Case of Absence of the Lateral Cutaneous Nerve of Forearm: Case Report

Helson Freitas da Silveira¹ Jalles Dantas de Lucena² Osvaldo Pereira da Costa Sobrinho³
 Roberta Silva Pessoa³ Gilberto Santos Cerqueira¹ André de Sá Braga Oliveira⁴
 Howard Lopes Ribeiro Júnior¹

¹ Department of Morphology, Universidade Federal do Ceará, Fortaleza, CE, Brazil

² Postgraduate Program in Morphofunctional Sciences, Universidade Federal do Ceará, Fortaleza, CE, Brazil

³ Course of Medicine, Universidade Federal do Ceará, Fortaleza, CE, Brazil

⁴ Department of Morphology, Universidade Federal da Paraíba, João Pessoa, PB, Brazil

Address for correspondence André de Sá Braga de Oliveira, MD, Centro de Ciências da Saúde, Departamento de Morfologia, Universidade Federal da Paraíba, Campus I, 58059-900, João Pessoa, PB, Brazil (e-mail: andre.sboliveira@gmail.com).

J Morphol Sci 2019;36:129–133.

Abstract

Introduction Variations in the formation and in the branching pattern of the brachial plexus are common. Numerous anastomotic variations between the musculocutaneous nerve (MCN) and the median nerve (MN) have been reported and could be implicated in a wide range of sensory and motor dysfunctions.

Objective To report an uncommon case of an anastomotic variation between the MN and the MCN with a rare absence of the lateral cutaneous nerve of forearm (LCNF).

Material and Methods A dissection of a male cadaver was performed at the Morphology Department of the Universidade Federal do Ceará, Fortaleza, state of Ceará, Brazil. The brachial plexus was exposed.

Results It was observed that the MCN, after its origin in the lateral fasciculus of the brachial plexus, anastomoses with the MN in the middle third of the arm. It diverges from the most prevalent anatomical pattern, in which the MCN continues to pass distally beneath the brachii biceps, originating the LCNF. In this case, the MCN does not emit its main terminal branch, the LCNF, which innervates the lateral portion of the skin of the forearm. In the present case, the innervation of the lateral portion of the skin of the forearm is provided by radial nerve branches. The reported case has practical implications, since the absence of the LCNF could cause hypoesthesia in the skin of the forearm.

Conclusion Thus, the knowledge of the formation and of the branching pattern of the brachial plexus is clinically important for the correct clinical interpretation of the sensory and motor disorders of the upper limbs caused by peripheral nerve injuries, as well as for planning surgical procedures to correct upper limb traumas.

Keywords

- ▶ upper limb
- ▶ median nerve
- ▶ musculocutaneous nerve
- ▶ lateral cutaneous nerve of forearm
- ▶ brachial plexus

Introduction

Changes in the brachial plexus and in its terminal branches are common, ranging from 12.8 to 53% of the cases.^{1,2} The anastomosis between the musculocutaneous nerve (MCN) and the median nerve (MN) are the most common variations

observed between brachial plexus branches, corresponding to between 10 and 53.6% of the reports.^{3,4}

The normal morphological pattern of the MN is formed by the union of branches of the lateral fasciculus (lateral root of C5, C6 and C7) and also by the contribution of the medial

received
 October 23, 2018
 accepted
 February 15, 2019

DOI <https://doi.org/10.1055/s-0039-1685224>.
 ISSN 2177-0298.

Copyright © 2019 by Thieme Revinter Publicações Ltda, Rio de Janeiro, Brazil

License terms



fasciculus of the brachial plexus (medial root of C8 and T1), following its path through the medial bicipital groove toward the cubital fossa without anastomosis with any other nerve. Mainly, the MN supplies the musculature of the anteromedial compartment of the forearm and part of the muscles and of the skin of the hand.⁵

The MCN originates from the lateral fasciculus of the brachial plexus (lateral root of C5, C6 and C7), where it initially emits a branch to the shoulder and then perforates and innervates the coracobrachialis muscle, follows deep between the biceps brachii and brachialis muscles, and emits a muscle branch for each of these muscles.⁶ This nerve extends to the lateral face of the forearm, where it continues as the lateral cutaneous nerve of forearm (LCNF), without any communication with the MN or other nerves.³

Although the first reports of communication between the MCN and the MN are dated to the 19th century,⁷ knowledge of new anatomical variations between these nerves has neurophysiological, clinical, and surgical implications relevant to the approach to the upper limbs.^{2,8,9}

The objective of the present study was to report an uncommon case of an anastomosis between the MCN and the MN with a rare absence of the LCNF, not previously described, and to discuss its possible cause and clinical implications.

Case Report

During a routine dissection of the upper limbs of a glycerin-preserved male cadaver of the Human Anatomy and Dissection Laboratory of the Universidade Federal do Ceará, Fortaleza, State of Ceará, Brazil, an uncommon anatomical variation of the MCN in the right upper limb was observed. The MCN, following the origin of the lateral fasciculus of the brachial plexus, as it is usually seen, pierces the coracobrachialis muscle, traverses between the biceps brachii and brachialis muscles, and sends branches to all of the muscles of the anterior compartment of the arm. However, approximately in the middle third of the arm, the MCN curves medially and anastomoses with the MN, which has a usual path. After the anastomosis between the two nerves, the presence of the LCNF, the terminal branch of the MCN, was not observed, and its agenesis (→ **Figs. 1 and 2**) was

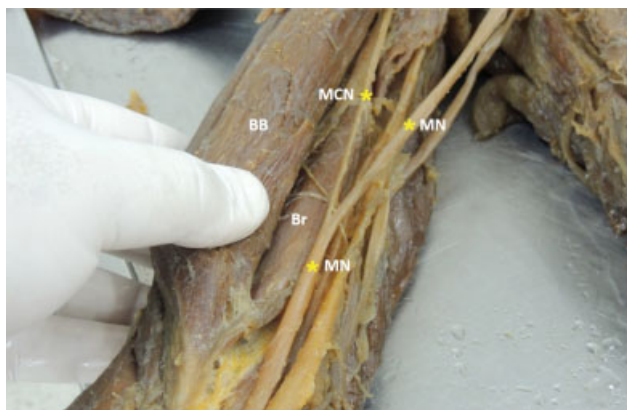


Fig. 1 Communication between the musculocutaneous and the median nerve. MN- median nerve, MCN- musculocutaneous nerve, BB- biceps brachii muscle, Br- brachialis muscle.

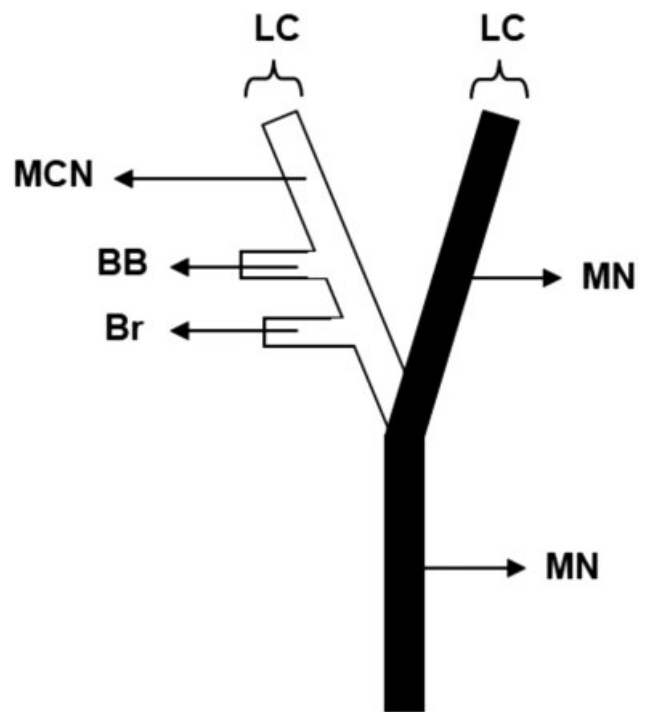


Fig. 2 Schematic diagram showing the communication between the musculocutaneous and the median nerve reported in the present study. LC- lateral cord, MN- median nerve, MCN- musculocutaneous nerve, Br- branch to the brachialis muscle, BB- branch to the biceps brachii muscle.

recorded. Therefore, a careful macroscopic dissection of the arm and of the forearm of the right upper limb was performed to observe the course of the MN after the anastomosis and the other branches of the brachial plexus, revealing that the cutaneous territory that would normally be supplied by the LCNF received innervation from branches originating from the radial nerve. The variation was unilateral, and the innervation pattern of the left upper limb was normal. The arterial pattern in the arm was also normal.

Discussion

The anastomosis between the MCN and the MN is the most common and frequent anatomical variation found between branches of the brachial plexus.¹⁰ → **Table 1** describes the communication between the MCN and the MN, and shows the presence of the LCNF in previous studies.

Several classifications of communications between the MCN and the MN were proposed by different authors, based on different criteria.¹¹ Le Minor¹² classified the communication between the MCN and the MN in five types. In type I, there is no communication between the MCN and the MN; in type II, the lateral fibers of the MN follow those of the MCN in the same sheath, anastomosing with the MN in the middle of the arm; while in type III the fibers of the lateral root of the MN join the MCN and, after some distance, they continue to form the lateral root of the MN. In type IV, the fibers of the MCN join the lateral root of the MN, and after some distance, the MCN arises from the MN. In type V, the MCN is absent, and the muscle fibers supplied by the MCN branch emerge

Table 1 Presentation of the communication between the musculocutaneous nerve and the median nerve, with presence of the lateral cutaneous nerve of forearm in all cases

References	Material analyzed	Communication between the MCN and the MN, and presence of the LCNF
Olave et al, 2000 ²⁷	32 upper limbs of 16 adult cadavers, Brazilian, of both genders	Ten cases of communicating branches between the MCN and the MN, with 9 cases of communicating branch starting from the MCN to the MN, without reports of absence of the LCNF.
Carlotto et al, 2009 ²⁸	Upper left limb of an adult cadaver, Brazilian, male	The MCN originated from the lateral face of the MN, previously crossed the coracobrachialis muscle, to terminate as the LCNF.
Sachdeva et al, 2011 ²⁹	Upper right limb of an adult cadaver, male	The MCN gives a branch to the coracobrachialis muscle, and then anastomoses completely with the MN, no longer appearing. Next, the MN sends branches to the brachialis and brachii biceps muscles, and to the LCNF.
Cerda et al, 2012 ¹¹	Upper limbs of a adult cadaver, Chilean, male	The MCN and the MN had communicating branches in both members. In the right upper limb, the MCN follows the standard anatomy. In the left upper limb, the MCN emits a distal communicating branch to the MN at 15.3 cm from the coracoid process. But, soon after, it terminate as the LCNF.
Radunovic et al, 2013 ²	Upper limb of an adult corpse	Communicating branch of the MCN to the MN was 8.2 cm after the lateral cord branching, inside its passage though the coracobrachial muscle. After the anastomosis, the MCN delivered branches to the brachialis and brachii biceps muscles, and to the LCNF.
Teli et al, 2013 ¹⁷	Upper limbs of an adult cadaver, male	Communicating branch of the MCN to the MN. In the middle of the arm, the MCN gave three branches: 1) for the arm, 2) passing between the brachialis and brachii biceps muscles that continued as the LCNF, and 3) for the MN, in both arms.
Cerda, 2014 ³⁰	Upper limbs of an adult cadaver, Chilean, male	In the left upper limb, the MCN penetrated the coracobrachialis muscle and gave three terminal branches in the lower third of the arm; branch to the brachialis muscle, to the LCNF and a communicating branch to the MN. In the right upper limb, the MCN penetrated the coracobrachialis muscle and gave four terminal branches in the lower third of the arm; two branches to the brachialis muscle, one to the LCNF, and a branch communicating to the MN.
Ballesteros et al, 2015 ³¹	106 upper limbs of 53 adult cadavers, Colombians, male	Communicating branch in 21/106 upper limbs. In 17% of the cases, there was a communication from the MCN to the MN, without report of LCNF agenesis. In 2.8% of the cases, the connection was MN-MCN.
Nascimento et al, 2016 ³²	Right upper limb of an adult cadaver, male	In the right upper limb, the MCN passed under the coracobrachialis muscle to then give its first branch to the brachii biceps muscle. It then continued for a further 29.56 mm and provided two more branches: the LCNF and a branch for the brachialis muscle. In the sequence it followed for a further 29.34 mm and attached to the MN, which was 145.90 mm long from its origin to its union with the MCN.

Abbreviations: LCNF; lateral cutaneous nerve of forearm; MCN, musculocutaneous nerve; MN, median nerve.

directly from the MN. The anastomosis between the MCN and the MN in the present study does not correspond to any of the described types, since after the anastomosis of the MCN and the MN, agenesis of the LCNF, the terminal branch of the MCN, was observed.

Choi et al¹³ classified the communication between the MCN and the MN in three types. In type I, both nerves are fused. In type II, there is a branch of communication between the MCN and the MN. This type was subdivided into two subtypes based on the number of branches of the MCN that join to form a connection with the MN. In type II a, a single branch of the MCN communicates the two nerves, while in type II b, two or three branches of the MCN join in one anastomotic branch to the MN. In type III, two individual

communication branches are present between the MCN and the MN. In the present study, the anastomosis between the MCN and the MN does not correspond to any of the described communication patterns.

Venieratos et al¹⁰ studied 79 cadavers and found a communication between the MCN and the MN in 22 corpses. They reported three types of communication between the MCN and the MN, considering the coracobrachialis muscle as a reference point. In type I, the communication between the MCN and the MN is proximal to the entrance of the MCN in the coracobrachialis. In type II, the communication between the two nerves is distal to the coracobrachialis muscle; and in type III, neither the MCN nor its communicating branches pierce the coracobrachialis. The variation presented in the

present study is morphologically similar to that of type 2 of Venieratos et al,¹⁰ but with two important differences: (1) after the anastomosis with the MN, the MCN does not emit its terminal branch, the LCNF, (2) we suggest that the part of the cutaneous innervation of the forearm that is made by the LCNF is supplied by the posterior antebrachial cutaneous nerve (PACN), a branch of the radial nerve, providing sensory innervation to the skin of the posterior forearm.¹⁴

Matzi et al¹⁵ reported that, after the separation from the radial nerve, the PACN emerged from the lateral intermuscular septum (LIMS), and immediately pierced the deep fascia after emerging from the LIMS.¹⁶ More distally, its main trunk and branches course in the subcutaneous layer to the posterior forearm, as far as the wrist.¹⁴ Data regarding its anatomy remain insufficient, especially regarding its origin and number of branches.¹⁴

The anastomotic variability between the MCN and the MN described in the literature suggest that these anastomoses may be attributed to ontogenetic and phylogenetic factors that influence the formation mechanism of muscles and nerves of the upper limbs during embryonic life.^{17,18}

Significant variations in nerve patterns may be a result of altered signaling between mesenchymal cells and neuronal growth cones.¹⁹ Chiarapattanakom et al²⁰ believe that the limb muscles develop from the local mesenchyme, while the axons of the spinal nerves grow distally to reach the muscles or the skin. They point to the lack of coordination between the development of muscles and their innervation as a factor responsible for the emergence of a communicating branch. Tatar et al²¹ cite that the common origin of the MCN and of the MN from branches of the lateral fasciculus of the brachial plexus is the explanation for many anastomotic variations between these nerves.

There are also those who believe that the communication between the MCN and the MN is reminiscent of phylogenetic development.^{6,17} Comparative anatomy studies have observed similar anastomotic branches in monkeys and in some primates, with the connections representing a primitive innervation of the arm muscles.⁶ Chauhan et al³ suggest the correlation between phylogenetic knowledge and knowledge of the development of nerve structures of the upper limbs for the interpretation of nerve anomalies in the development of the arm.

The PACN innervating the LCNF area is of clinical importance, causing variations in the innervated areas and affecting the electrophysiological study. The knowledge of the formation and of the branching pattern of the terminal branches of the brachial plexus is clinically important in order to avoid iatrogenic PACN injury during surgical procedures at the elbow.^{14,22} Portal placement in the elbow arthroscopy could injure the nerve.²³ The PACN injury was diagnosed after the surgical treatment of lateral epicondylitis.²⁴ Furthermore, preservation of the PACN during harvest of the lateral arm free flap for soft tissue reconstruction was associated with less sensory disturbances.²⁵

In cases of brachial plexus injuries with denervation of the muscles supplied by the MCN, it is important to know the morphological variations of this structure to improve its

intervention. Muscles supplied by the MCN have a good recovery due to surgical reinnervation after the trauma. This behavior is indicated in cases in which spontaneous recovery of movements such as forearm flexion or adduction of the upper limb does not occur. These approaches aim, for example, to release nerve fibers involved by scar tissue that compress or interpose nerve grafts between compromised MCN regions by microsurgery.²⁶

In conclusion, the present article showed a rare case of absence of the LCNF, not previously described in the literature, and an uncommon anastomotic variation between the MCN and the MN. Knowledge of these variations is important in surgical approaches and in the treatment of upper limb injuries. Surgeons and clinicians should always consider possible communicating branches during surgical procedures and clinical investigations of the arm.

Conflicts of Interests

The authors declare that have no conflict of interest that might constitute an embarrassment to the publication of this article.

References

- 1 Johnson EO, Vekris M, Demesticha T, Soucacos PN. Neuroanatomy of the brachial plexus: normal and variant anatomy of its formation. *Surg Radiol Anat* 2010;32(03):291–297 10.1007/s00276-010-0646-0
- 2 Radunovic M, Vukasanovic-Bozanic A, Radojevic N, Vukadinovic T. A new anatomical variation of the musculocutaneous and the median nerve anastomosis. *Folia Morphol (Warsz)* 2013;72(02):176–179
- 3 Chauhan R, Roy TS. Communication between the median and musculocutaneous nerve – a case report. *J Anat Soc India* 2002;51(01):72–75
- 4 Guerri-Guttenberg RA, Ingolotti M. Classifying musculocutaneous nerve variations. *Clin Anat* 2009;22(06):671–683 10.1002/ca.20828
- 5 Standring S. *Gray's Anatomy: The Anatomical Basis of Clinical Practice*. In: Pectoral girdle, shoulder region and axilla. 41st ed. New York: Churchill Livingstone Elsevier; 2015:791–822
- 6 Sahu SK, Baruah P, Choudhury PR, et al. Bilateral communicating branch between musculocutaneous and median nerve. *Int J Anat Res*. 2015;3(03):1252–1254 10.16965/ijar.2015.205
- 7 Harris W. The True Form of the Brachial Plexus, and its Motor Distribution. *J Anat Physiol* 1904;38(Pt 4):399–422. 5
- 8 Budhiraja V, Rastogi R, Asthana AK, Sinha P, Krishna A, Trivedi V. Concurrent variations of median and musculocutaneous nerves and their clinical correlation—a cadaveric study. *Ital J Anat Embryol* 2011;116(02):67–72
- 9 Sawant SP, Shaikh ST, More RM. Study of variant connections of median nerve with musculocutaneous nerve. *Int J Med Pharma Sci*. 2012;3(03):35–43
- 10 Venieratos D, Anagnostopoulou S. Classification of communications between the musculocutaneous and median nerves. *Clin Anat* 1998;11(05):327–331 10.1002/(SICI)1098-2353(1998)11:5<327:AID-CA6>3.0.CO;2-M
- 11 Cerda A, Suazo Galdames I. Bilateral Communications of the Musculocutaneous and Median Nerves, Morphological Aspects and Clinical Significance. *Int J Morphol* 2012;30(02):651–655 10.4067/S0717-95022012000200048
- 12 Le Minor JM. [A rare variation of the median and musculocutaneous nerves in man]. *Arch Anat Histol Embryol* 1990;73:33–42
- 13 Choi D, Rodríguez-Niedenführ M, Vázquez T, Parkin I, Sañudo JR. Patterns of connections between the musculocutaneous and median nerves in the axilla and arm. *Clin Anat* 2002;15(01):11–17 10.1002/ca.1085

- 14 Chodewaratham P, Chentanez V, Agthong A, Huanmanop T. Anatomy of posterior antebrachial cutaneous nerve related to the lateral epicondyle and interepicondylar line. *Int J Morphol* 2016;34(03):953–957 10.4067/S0717-95022016000300023
- 15 Matzi V, Hörlesberger N, Hohenberger GM, et al. Minimally invasive approach to the radial nerve—A new technique. *Injury* 2015;46(12):2374–2378 10.1016/j.injury.2015.09.017
- 16 MacAvoy MC, Rust SS, Green DP. Anatomy of the posterior antebrachial cutaneous nerve: practical information for the surgeon operating on the lateral aspect of the elbow. *J Hand Surg Am* 2006;31(06):908–911 10.1016/j.jhssa.2006.03.013
- 17 Teli CG, Kadlimatti HS, Kate NN. Bilateral communication between musculocutaneous and median nerve. *J Dent Med Sci*. 2013;12(06):92–94 10.9790/0853-1269294
- 18 Kothandaraman U, Lokanadham S. Types of communications between musculocutaneous nerve and median nerve. *J Clin Biomed Sci*. 2014;4(02):300
- 19 Abhaya A, Bhardwaj R, Prakash R. Bilaterally Symmetrical Dual Origin of Musculocutaneous Nerve. *J Anat Soc India* 2006;55(02): 56–59
- 20 Chiarapattanakom P, Leechavengvongs S, Witoonchart K, Uerpair-ojkit C, Thuvasethakul P. Anatomy and internal topography of the musculocutaneous nerve: the nerves to the biceps and brachialis muscle. *J Hand Surg Am* 1998;23(02):250–255 10.1016/S0363-5023(98)80122-6
- 21 Tatar I, Brohi R, Sen F, Tonak A, Celik H. Innervation of the coracobrachialis muscle by a branch from the lateral root of the median nerve. *Folia Morphol (Warsz)* 2004;63(04):503–506
- 22 El Falougy H, Selmeciova P, Kubikova E, Stenova J, Haviarova Z. The variable communicating branches between musculocutaneous and median nerves: a morphological study with clinical implications. *Bratisl Lek Listy* 2013;114(05):290–294
- 23 Chaware PN, Santoshi JA, Pakhare AP, Rathinam BA. Risk of nerve injury during arthroscopy portal placement in the elbow joint: A cadaveric study. *Indian J Orthop* 2016;50(01):74–79 10.4103/0019-5413.173510
- 24 Iyer VG. Iatrogenic injury to posterior antebrachial cutaneous nerve. *Muscle Nerve* 2014;50(06):1024–1025 10.1002/mus.24347
- 25 Ki SH. Lateral arm free flap with preservation of the posterior antebrachial cutaneous nerve. *Ann Plast Surg* 2016;76(05): 517–520 10.1097/SAP.0000000000000296
- 26 Rodrigues DB, Viegas MLC, Rogério JS, Pereira ELR. Tratamento cirúrgico das lesões traumáticas do plexo braquial. *Arq Bras Neurocir*. 2014;33(02):125–131
- 27 Olave E, Gabrielli C, Braga MTT, Del Sol M, De Souza A. Communicating branch between the musculocutaneous and median nerves in man. *Rev Chil Anat* 2000;18(02):301–304 10.4067/S0716-98682000000200014
- 28 Carlotto JRM, Ambros LE, Dal Vesco JA, Reichert PR. Anomalous Origin and Trajectory of Musculocutaneous Nerve. *Int J Morphol* 2009;27(02):507–508 10.4067/S0717-95022009000200033
- 29 Sachdeva K, Singla RK. Communication between median and musculocutaneous nerve. *J Morphol Sci*. 2011;28(04):246–249
- 30 Cerda A. Third head of biceps brachii muscle, associated with musculocutaneous and median nerve bilateral communication and with a communicating branch between median nerve roots. *Int J Morphol* 2014;32(02):510–514
- 31 Ballesteros LE, Forero PL, Buitrago ER. Communication between the musculocutaneous and median nerves in the arm: an anatomical study and clinical implications. *Rev Bras Ortop* 2014;50(05):567–572 10.1016/j.rboe.2014.08.009
- 32 Nascimento SR, Ruiz CR, Pereira E, Andrades L, de Souza CC. Rare anatomical variation of the musculocutaneous nerve - case report. *Rev Bras Ortop* 2016;51(03):366–369 10.1016/j.rboe.2015.08.019