

# Arachnoid Cyst—Institutional Experience

Madhan Singaravelu<sup>1</sup> Selvaraj Ramakrishnan<sup>1</sup> Lakhmipathy Gopalakrishnan<sup>1</sup>

<sup>1</sup>Institute of Neurosurgery, Madras Medical College, Chennai, India

**Address for correspondence** Madhan Singaravelu, MBBS, DA, MCh, Institute of Neurosurgery, Madras Medical College, Chennai, India (e-mail: madhansingaravelu82@gmail.com).

Indian J Neurosurg 2019;8:20–24

## Abstract

**Background** Arachnoid cysts are benign, non-neoplastic fluid collections within the arachnoid mater layer of the meninges. The etiology and significance of arachnoid cysts are poorly understood. Although they frequently represent incidental findings on central nervous system imaging, a wide variety of conditions have been attributed to their presence. The aim of this study is to ascertain the clinical presentation, location, and clinical course of patients with arachnoid cysts in the institution.

**Methods** The authors analyzed the clinical presentation, radiologic images, and clinical course of 16 patients presented over a period of 6 months from August 2017 to January 2018.

**Results** Of these 16 patients, 11 were adults and 5 were pediatric patients. Of these, seven were female and the remaining nine were male. Three patients presented with seizures, seven with headache, two with developmental delay, one with hydrocephalus, one with giddiness, one with hard of hearing, and one with bulging posterior fontanelle. Of these, 6 underwent surgery and 10 were managed conservatively.

**Conclusion** Arachnoid cysts (non-neoplastic lesions) that produce symptoms through mass effect and obstructive hydrocephalus need surgical management, whereas a large percentage of cysts that are asymptomatic can be managed conservatively. The various surgical options available are marsupialization, cystoperitoneal shunt, ventriculoperitoneal (VP) shunt, and endoscopic fenestration. Microsurgery and endoscopy both allow for rapid decompression of the cyst and restoration of cerebrospinal fluid (CSF) circulation, whereas shunting tends to produce greater reduction in cyst size. Timing of presentation also decides upon the treatment options. Patients presenting late after the establishment of neurocognitive decline may not benefit from surgery and can be managed conservatively. A detailed genetic study may aid in the evolution of newer prevention and management options. Currently, most pediatric neurosurgeons prefer to avoid shunting, if possible. However, treatment paradigms are operator dependent and produce comparable outcomes.

## Keywords

- ▶ arachnoid cyst
- ▶ non-neoplastic lesion
- ▶ marsupialization

## Introduction

Arachnoid cysts are the most common cystic congenital abnormality of the brain.<sup>1</sup> They comprise 1% of intracranial masses<sup>1</sup> and are found in approximately 1.7% of the adult population.<sup>2</sup> Studies of their true prevalence in the general population must be made carefully because they carry a selection bias toward those patients undergoing neuraxis imaging. Autopsy studies demonstrated a lower prevalence

of cysts at 0.1% of individuals.<sup>3</sup> As pathologic entities, they are more frequently diagnosed in the pediatric population in which their prevalence is 2.6%.<sup>4</sup> A male predominance (male-to-female ratio: 2:1) is noted in both adults and children.<sup>2,4,5</sup> In this study also, there is a slight male predominance (adult males [6] to females [5] is 1.2:1) (male children [3] to female children [2] is 1.5:1). Most arachnoid cysts appear to be congenital anomalies.<sup>4</sup> They are usually discovered during workup for headache, increasing head circumference,

## received

April 24, 2018

## accepted

June 15, 2018

## published online

April 22, 2019

DOI <https://doi.org/>

10.1055/s-0039-1686959

ISSN 2277-954X.

©2019 Neurological Surgeons' Society of India

## License terms



or developmental delay, or after trauma.<sup>4</sup> In this study, seven (43.75%) patients had headache, one (6.25%) had hydrocephalus, and two (12.5%) had developmental delay. Ten (62.5%) patients were discovered during workup for headache, increasing head circumference, and developmental delay.<sup>4</sup> Rarely, they cause weakness and cranial neuropathies or have been associated with seizures and psychiatric disorders.<sup>6-9</sup> In this study, five (31.25%) patients had seizures, one (6.25%) had weakness, and one (6.25%) had neuropsychiatric manifestation. In this study, other symptoms that led to the diagnosis of arachnoid cyst are numbness of limbs in one (6.25%) patient, visual obscuration in one (6.25%), and hard of hearing in one (6.25%). Arachnoid cysts secondary to trauma, hemorrhage, or meningitis have also been described.<sup>10,11</sup>

### Epidemiology

Retrospective studies of arachnoid cyst prevalence do not distinguish between congenital and acquired arachnoid cysts, but acquired cysts are thought to represent a minority of cases. In the era before computed tomography (CT) and magnetic resonance imaging (MRI), a literature review demonstrated 49% of cysts in the middle fossa or sylvian fissure; in the cerebellopontine (CP) angle, 11%; quadrigeminal plate area, 10%; vermis, 9%; suprasellar area, 9%; inter-hemispheric fissure, 5%; cerebral convexity, 4%; and interpeduncular area, 3%.<sup>12</sup> More recent prevalence studies have shown a slightly different distribution.<sup>2,4</sup> Among adults, middle fossa and retrocerebellar cysts show roughly the same prevalence (34% and 33%, respectively). Although middle fossa or sylvian fissure cysts remain the most common in all age groups, it is possible that some of the differences in prevalence reflect the likelihood of cysts in each location to cause symptoms. In their study of adults with radiographically diagnosed arachnoid cysts, Al-Holou and colleagues found a statistically significant increased rate of symptomatic cysts for cysts located in the CP angle, quadrigeminal cistern, sellar, and ambient cisterns.<sup>2</sup> Middle fossa cysts in adults were associated with a significantly lower rate of symptoms.<sup>2</sup> In this study, 7 out of 16 patients with symptoms had middle fossa cyst (43.75%), which is contrary to the study by Al-Holou et al in which middle fossa cysts were associated with lower rate of symptoms. Of these seven, four were adults. Two were male and two were female.

### Pathology

The most general definition of arachnoid cyst implies a loculated cavity within the arachnoid mater without discrimination of the wall or cyst content. This definition allows for a variety of etiologies. As proposed by some,<sup>5</sup> a more precise definition would exclude entities that have an appearance similar to arachnoid cysts, such as leptomeningeal cysts secondary to infection or trauma, porencephalic cysts, and neuroepithelial cysts. This definition makes some presumptions on the etiology of congenital cysts but also highlights important confounding factors in the diagnosis of arachnoid cysts.

Using a somewhat broader definition, a recent pathologic analysis of a series of arachnoid cysts demonstrated varying cyst wall composition. Although most

cysts had walls of normal arachnoid cells, several walls demonstrated fibrosis and some demonstrated microvilli and cilia.<sup>13</sup> This suggests the possibility that there may be more than one patho physiologic origin. From a practical perspective, because only select cases undergo operation and pathologic examination, it may not be possible to distinguish between all types of cysts arising from the arachnoid. In this study, four patients underwent marsupialization, and histopathologic examination (HPE) was conclusive of arachnoid cyst in all four cases.

A recent study analyzing the fluid contained within a series of middle fossa cysts determined that arachnoid cyst contents are very similar, but not identical, to cerebrospinal fluid (CSF). The contents have some unique characteristics, particularly with regard to protein, lactate dehydrogenase, and phosphate concentration.<sup>14,15</sup> In this study, one patient underwent cystoperitoneal shunt and one underwent ventriculoperitoneal (VP) shunt. However, owing to logistical difficulties, lactate dehydrogenase and phosphate concentrations could not be assayed.

### Pathogenesis

Owing to a wide range of presenting symptoms, anatomic locations, age at presentation, and comorbidities, the possible etiologies for arachnoid cysts are several. Because most surgical cases present in the pediatric population, a congenital or genetic etiology is hypothesized. Evidence for a genetic cause is growing. Certain hereditary syndromes, such as Marfan's syndrome, neurofibromatosis, glutamic aciduria type I, autosomal dominant polycystic kidney disease, and tuberous sclerosis, have demonstrated a higher incidence of arachnoid cysts than the general population. A clearer genetic linkage was recently described in a consanguineous family with a high prevalence of arachnoid cysts. The authors found an autosomal recessive inheritance of the familial arachnoid cysts that linked to chromosome 6q22.31–23.2. A pattern in the location or size of the cysts did not appear.

### Molecular Biology and Genetics

The prevailing theory is that cystogenesis is brought about by a splitting or duplication of arachnoid membrane during embryogenesis. Cyst fluid may thereafter accumulate either by active water transport across the cyst membrane by cells lining the cystic cavity or by a one-way mechanical valve. In both cases, net flow of water is into the arachnoid cyst. There are several features of arachnoid cyst that are not fully explained by these theories alone.

These features include a significant predilection for middle cranial fossa (in this study 7 out of 16 had middle cranial fossa arachnoid cyst), a significant male preponderance (9 males out of 16 patients), and the left sidedness for cysts in this location (6 out of 7 middle fossa arachnoid cysts were left sided). For cysts in CP angle, there is female preponderance (both patients with CP angle arachnoid cyst were female in this study) and right sidedness (one was right side and one was left sided in this study). These peculiarities and several reports documenting a familial occurrence of arachnoid cyst, either as a separate entity or coexisting with other hereditary

disorders, indicate a genetic mechanism underlying the development of arachnoid cyst.

Owing to congenital nature of most intracranial arachnoid cysts, it is possible that altered gene expression in neural crest cells at the time of leptomeningeal development may contribute to cyst formation.

There is a limited amount of research on molecular biology of arachnoid cyst. In their publications, Go et al demonstrated that the morphologic features of the cells lining arachnoid cyst were consistent with fluid secretion capacity. Moreover, enzyme cytochemistry demonstrated a structural organization of (Na<sup>+</sup>-K<sup>+</sup>)-ATPase and alkaline phosphatase indicating fluid transport toward the lumen.

In “pure” arachnoid cyst family, that is, a family with familial arachnoid cyst occurrence without association to any other syndromes, genome-wide linkage analysis localized the linkage interval to chromosome 6q22.31–23.2. Other mutations described in connection with arachnoid cyst include *SOX2* mutations and *GPSM2*, as well as other gene alterations.

Investigations of gene expression profiles in arachnoid cyst tissue have further identified potential candidate genes underlying cyst formation such as *SHROOM3* and *SOX9*. The differential expression of these genes might be important for the development of arachnoid cyst, but owing to low number of cases studied, these findings must be further studied in model systems and replication studies containing more samples before firm conclusions can be made about causality in cyst development.

**Age Distribution**

In this observational study over 6 months, the authors encountered 16 patients with arachnoid cysts. In this study, prevalence in pediatrics is 31.25% (5) and in adults is 68.75% (11).

–**Table 1** shows prevalence of arachnoid cysts in various locations.

**Clinical Presentation**

The presenting symptoms for nonincidental pediatric arachnoid cysts are similar to other childhood mass lesions. Progressive macrocephaly, intracranial hypertension, headache, hydrocephalus, and developmental delay were the most common indications for workup leading to treatment of the arachnoid cyst. In adults, headache was the most common complaint found in patients considered to have symptomatic arachnoid cysts, but hydrocephalus, ataxia, vertigo, hearing loss, and seizures were also common complaints in this population.

**Table 1** Location and prevalence

Location	Recent studies (%)	This study
Middle fossa cyst	34	43.75% (7)
Retrocerebellar cyst	33	25.00% (4)
Cerebellopontine (CP) angle cyst	11	12.50% (2)
Convexity cyst	4	18.75% (3)

Obstructive hydrocephalus was the presenting feature (6.25%) in a 2-year-old female child with right CP angle arachnoid cyst that was managed with shunt surgery (–**Fig. 1**).

Global developmental delay (12.5%) was the presenting feature in an 8-year-old male child and a 30-year-old man (this patient had neuropsychiatric manifestations in addition to global developmental delay).

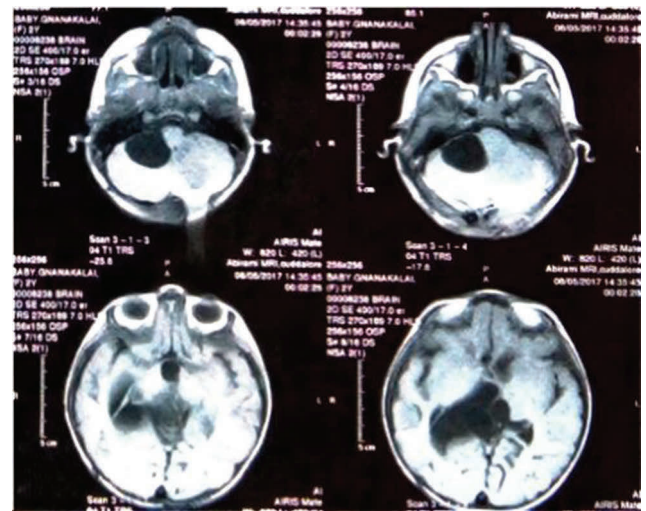
An 8-year-old boy had left temporal type III arachnoid cyst (–**Fig. 2**). He was managed conservatively.

A 30-year-old male patient with global developmental delay and neuropsychiatric manifestations had posterior fossa arachnoid cyst (–**Fig. 3**), which was managed conservatively.

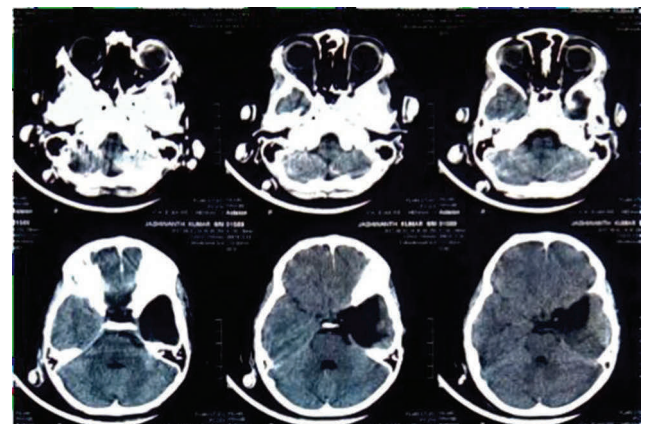
Seizure was the presenting symptom in two male children, one female child, and two adult male, a total of five (31.25%) patients.

One pediatric patient (7 years) had right temporal arachnoid cysts and was managed conservatively.

A 10-year-old boy with seizure had left temporal type II cyst. His seizures stopped following marsupialization of arachnoid cyst. One pediatric patient with obstructive hydrocephalus and seizure underwent shunt surgery.



**Fig. 1** Axial section of T1-weighted MRI of right CP angle arachnoid cyst.



**Fig. 2** Left temporal Galassi type III arachnoid cyst.



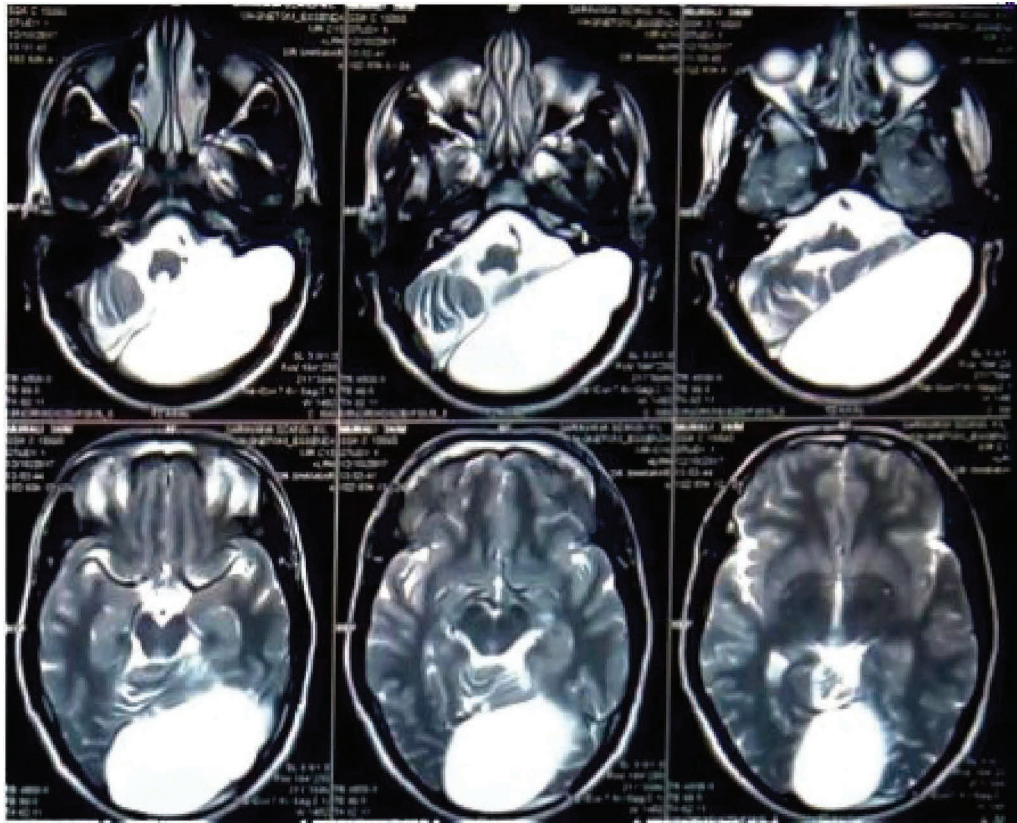


Fig. 3 CT of the brain showing posterior fossa arachnoid cyst.

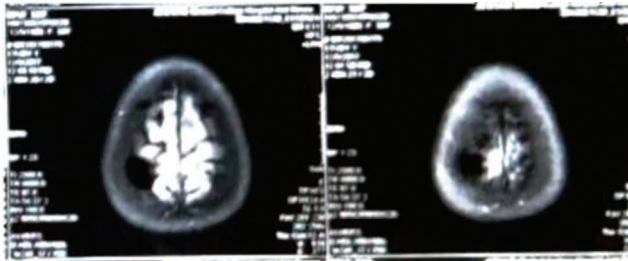


Fig. 4 CT of the brain showing right high parietal arachnoid cyst.

A 54-year-old man with seizures had posterior fossa arachnoid cyst and was managed conservatively.

One patient (34 years, male), who presented with giddiness (6.25%) and right-sided weakness, had posterior fossa arachnoid cyst. He underwent cystoperitoneal shunt and his symptoms improved.

Seven patients had headache (43.75%), and arachnoid cyst was detected during evaluation for headache. Four of these were managed conservatively.

A 35-year-old woman with right high parietal arachnoid cyst (► Fig. 4) was managed conservatively.

A 58-year-old woman with left temporal arachnoid cyst was managed conservatively.

A 23-year-old man with left temporal arachnoid cyst was managed conservatively.

A 40 years old man with right temporal arachnoid cyst was managed conservatively.

Six patients underwent surgery.

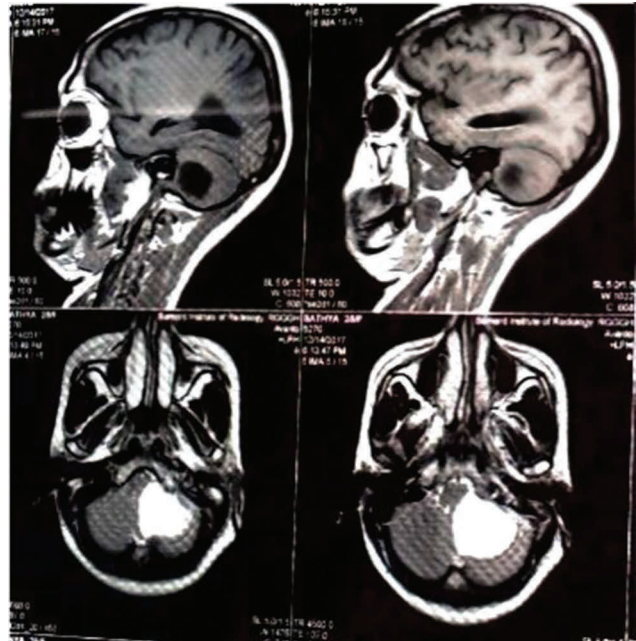


Fig. 5 CT of the brain showing left CP angle arachnoid cyst.

A 37-year-old woman with headache had left temporal arachnoid cyst and underwent marsupialization.

A 47-year-old woman with headache, who had left frontal arachnoid cyst, underwent marsupialization.

A 10-year-old man with left temporal Galassi type II arachnoid cyst underwent marsupialization.

A 28-year-old woman with headache had left cp angle arachnoid cyst (►Fig. 5) and underwent left retromastoid suboccipital craniectomy and marsupialization.

A 2-year-old female child with right cp angle arachnoid cyst (►Fig. 1) and obstructive hydrocephalus was managed with shunt surgery.

A 34-year-old man with posterior fossa arachnoid cyst underwent cystoperitoneal shunt and his symptoms improved.

### Management

Ten patients were managed conservatively (62.50%). Six patients underwent surgery (37.50%)—four underwent marsupialization, one underwent cystoperitoneal shunt, and one underwent VP shunt. In this study, patients with arachnoid cyst of size larger than 4 cm, cysts that produced mass effect and midline shift, and cysts that caused seizures, were marsupialized. Patient with arachnoid cysts that caused hydrocephalus underwent shunt surgery, and patient with arachnoid cyst of size larger than 8 cm, which caused mass effect over brainstem, underwent cystoperitoneal shunt. All the patients who underwent surgeries were relieved of their symptoms, whereas those managed conservatively are being followed up regularly and their symptoms are under control with medical management over the past 6 months.

### Conclusion

Arachnoid cysts (non-neoplastic lesions) that produce symptoms through mass effect and obstructive hydrocephalus need surgical management, whereas a large percentage of cysts that are asymptomatic can be managed conservatively. The various surgical options available are marsupialization, cystoperitoneal shunt, VP shunt, and endoscopic fenestration. Microsurgery and endoscopy both allow for rapid decompression of the cyst and restoration of CSF circulation, whereas shunting tends to produce greater reduction in cyst size. Timing of presentation also decides upon the treatment options. Patients presenting late after the establishment of neurocognitive decline may not benefit from surgery and can be managed conservatively. A detailed genetic study may aid in the evolution of newer prevention and management options. Currently, most pediatric neurosurgeons prefer to avoid shunting, if possible. However, treatment paradigms are operator dependent and produce comparable outcomes.

### Conflict of Interest

None.

### References

- 1 Cincu R, Agrawal A, Eiras J. Intracranial arachnoid cysts: current concepts and treatment alternatives. *Clin Neurol Neurosurg* 2007;109(10):837–843
- 2 Al-Holou WN, Terman S, Kilburg C, Garton HJ, Muraszko KM, Maher CO. Prevalence and natural history of arachnoid cysts in adults. *J Neurosurg* 2013;118(2):222–231
- 3 Shaw CM, Alford EC Jr. *Congenital Arachnoid Cysts and Their Differential Diagnosis*. Amsterdam, The Netherlands: North Holland Publishing Company; 1977
- 4 Al-Holou WN, Yew AY, Boomsaad ZE, Garton HJ, Muraszko KM, Maher CO. Prevalence and natural history of arachnoid cysts in children. *J Neurosurg Pediatr* 2010;5(6):578–585
- 5 Oberbauer RW, Haase J, Pucher R. Arachnoid cysts in children: a European co-operative study. *Childs Nerv Syst* 1992;8(5):281–286
- 6 Laporte N, De Volder A, Bonnier C, Raftopoulos C, Sébire G. Language impairment associated with arachnoid cysts: recovery after surgical treatment. *Pediatr Neurol* 2012;46(1):44–47
- 7 B Gjerde P, Schmid M, Hammar A, Wester K. Intracranial arachnoid cysts: impairment of higher cognitive functions and postoperative improvement. *J Neurodev Disord* 2013;5(1):21
- 8 Tunes C, Flønes I, Helland C, Goplen F, Wester KG. Disequilibrium in patients with posterior fossa arachnoid cysts. *Acta Neurol Scand* 2015;132(1):23–30
- 9 Baquero GA, Molero P, Pla J, Ortuño F. A schizophrenia-like psychotic disorder secondary to an arachnoid cyst remitted with neurosurgical treatment of the cyst. *Open Neuroimaging J* 2014;8:1–4
- 10 Handa J, Nakasu S, Kidooka M, Suzuki F. Cerebrospinal fluid entrapment cysts with subarachnoid dissemination of medulloblastoma: CT findings. *J Comput Assist Tomogr* 1984;8(5):988–989
- 11 Abhinav K, Bradley M, Aquilina K, Patel NK. Spinal arachnoiditis and cyst formation with subarachnoid haemorrhage. *Br J Neurosurg* 2012;26(4):574–575
- 12 Rengachary SS, Watanabe I. Ultrastructure and pathogenesis of intracranial arachnoid cysts. *J Neuropathol Exp Neurol* 1981;40(1):61–83
- 13 Rabiei K, Tisell M, Wikkelsø C, Johansson BR. Diverse arachnoid cyst morphology indicates different pathophysiological origins. *Fluids Barriers CNS* 2014;11(1):5
- 14 Berle M, Wester KG, Ulvik RJ, et al. Arachnoid cysts do not contain cerebrospinal fluid: a comparative chemical analysis of arachnoid cyst fluid and cerebrospinal fluid in adults. *Cerebrospinal Fluid Res* 2010;7:8
- 15 Berle M, Kroksveen AC, Garberg H, et al. Quantitative proteomics comparison of arachnoid cyst fluid and cerebrospinal fluid collected perioperatively from arachnoid cyst patients. *Fluids Barriers CNS* 2013;10(1):17