


Anatomical Pattern of Dorsal Metatarsal Arteries in a Black Kenyan Population

Thomas Amuti¹  Lee Oyugi¹ Innocent Ouko¹ Ibsen Ongidi¹ Julius Ogeng'o¹

¹Department of Human Anatomy, University of Nairobi, University of Nairobi, Nairobi, Kenya

Address for correspondence Thomas Amuti, BSc, Department of Human Anatomy, University of Nairobi, 30197-00100, Nairobi, Kenya (e-mail: tomamuti@gmail.com).

J Morphol Sci 2019;36:169–173.

Abstract

Introduction Knowledge of anatomical variations in the origin and in the course of the dorsal metatarsal arteries (DMTAs) is valuable for many procedures, including reconstructive surgeries and flap selection. However, there is a paucity of data on these arteries among black Africans.

Materials and Methods The present study studied the origin and the location of DMTAs in 30 formalin-fixed cadaveric feet of adult black Kenyans at the Department of Human Anatomy of the University of Nairobi, Nairobi, Kenya.

Results Dorsal metatarsal arteries were present in all of the cases. Of the right dorsalis pedis artery (DPA), in the majority of the cases, the 1st DMTA arose as the continuation of the DPA, while the 2nd to 4th DMTAs were given off as branches from the arcuate artery (AA). On the left feet, in the majority of the cases, the 1st DMTA arose as the continuation of the DPA, while the rest were given off as branches from the AA. In relation to the dorsal interossei muscles, all of the the arteries were either within the muscle fibers (53%) or beneath them (47%), on the right side. On the left side, the 1st DMTA was above the muscles in 40% of the cases; within the muscles in 53%; and beneath the muscles in 7%. The 2nd and 3rd DMTAs were above the muscles in 57% and in 53% of the cases, respectively.

Conclusion These results reveal that the DMTAs show variation in their origin and position relative to the dorsal interossei muscles. These variations display bilateral asymmetry.

Keywords


- ▶ dorsal metatarsal arteries
- ▶ interossei muscles
- ▶ dorsal myocutaneous flaps
- ▶ foot
- ▶ dorsalis pedis

Introduction

The dorsal metatarsal arteries (DMTAs) are the main blood supply to the structures located dorsally between the digits. They course between the metatarsal bones to bifurcate at the web of the toes into the proper dorsal digital arteries. Normally, the 1st DMTA is a branch of the dorsalis pedis artery (DPA), given off before the deep plantar artery and the arcuate artery (AA). The other DMTAs arise as branches from the AA, which is a branch of the DPA.^{1,2}

Variations have been reported on the origin of these vessels, as well as on their course between the web spaces.³⁻⁹

Knowledge of anatomical variations in the origin and in the course of the DMTAs is valuable to endovascular surgeons when selecting the artery to be revascularized based on the angiosome concept in critical limb ischemia cases in order to avoid amputation of feet of diabetic patients. It is also important in reconstructive surgeries and in flap selection in order to select the vascularized bone graft for reconstruction of metatarsals and digits of the amputated limb and for the reconstruction of the eyelids and of the nasal tip.⁴ There is a paucity of data on these arteries among black Africans. Therefore, the present study aimed to investigate the anatomical variations in the DMTAs in a select Kenyan population.

 Thomas Amuti's ORCID is <https://orcid.org/0000-0003-0532-3653>.

received
October 12, 2018
accepted
April 14, 2019

DOI <https://doi.org/10.1055/s-0039-1691757>.
ISSN 2177-0298.

Copyright © 2019 by Thieme Revinter
Publicações Ltda, Rio de Janeiro, Brazil

License terms



Methods and Materials

The present study, a descriptive cross-sectional study with a sample size of 30 specimens, was performed at the Department of Human Anatomy of the University of Nairobi, Nairobi, Kenya. The formalin-fixed specimens used were of adults of Kenyan indigenous ethnicity.

To dissect out the DMTA, the skin, the fat, and the fascia of the dorsum of the feet were removed. This exposed the DPA and its branches. The AA was then identified as the artery that branched from the tarsalmetatarsal joint and arched in a semicircular manner beneath the tendons of the extensor hallucis brevis muscle. The extensor digitorum brevis was therefore retracted to allow access to the branches of the AA.

The 1st DMTA was identified as the branch of the dorsalis pedis artery given off before the deep plantar artery and the AA. The other DMTAs were identified as the arteries that branched from the AA and coursed between the metatarsal bones to bifurcate at the web of the toes into the proper dorsal digital arteries. These vessels were then cleaned and tagged for visibility.

The origins of the arteries were then measured from the base of the respective metatarsal bones and recorded. The variations of the origin of the DMTAs, as well as their courses, were also observed and noted. Data was recorded and variations were photographed with a 12.1 megapixels digital camera Carl Zeiss Ikon (Carl Zeiss, Oberkochen, Germany).

The data was coded into SPSS version 21, IBM, in which the means of the different data were calculated. Side variations were also analyzed using the paired t-test. A *p-value* \leq 0.05 was considered significant at a 95% confidence interval (CI). Data were presented using tables and photographs.

Results

All of the the DMTAs were present.

Origin of the Dorsal Metatarsal Arteries

There were different topographical as well as morphometric points of origin as measured from the bases of the respective metatarsal bones.

Topographical Origins of the Dorsal Metatarsal Arteries

In 33% of the right DPAs, the 1st DMTA arose as a branch of the DPA, while the rest were given off as branches from the AA. In 20% of the right DPAs, the 1st DMTA arose as the continuation of the medial dorsalis pedis branch, while the rest were given off by the lateral dorsalis pedis branch. In the remaining 47% of the right DPAs, the main DPA gave off the 1st DMTA, the 2nd DMTA was given off as a direct branch from the DPA, while the 3rd and 4th DMTAs arose as branches from the lateral tarsal artery (LTA).

In 47% of the left feet, the 1st DMTA arose as a branch of the DPA, while the rest were given off as branches from the AA. In 13% of the cases, the 1st DMTA arose as the continuation of the medial dorsalis pedis branch, while the rest were given off by the lateral dorsalis pedis branch. In 40% of the cases,

the 1st DMTA arose as a branch of the DPA, the 2nd DMTA was given off as a direct branch from the DPA, while the 3rd and 4th DMTAs arose as branches from the LTA. (►Figs. 1–3)

Morphometric Origin of the Dorsal Metatarsal Arteries as Measured from the Respective Metatarsal Bases

The mean distance of the 1st DMTA on the right side arose at a point 2.36 mm from the base of the 1st metatarsal bone. The mean distance of the 2nd, 3rd and 4th DMTAs arose at 1.18mm, 1.52mm, and 1.46mm from their respective metatarsal bases, respectively. On the left side, the mean distance of the 1st DMTA arose at a point 1.46 mm from the base of the 1st metatarsal bone. The mean distance of the 2nd, 3rd and 4th DMTAs arose at 2.60mm, 1.60mm and 1.60mm from their respective metatarsal bases, respectively (►Table 1).

Relation of the Dorsal Metatarsal Arteries to the Dorsal Interossei Muscles

On the right feet, all of the DMTAs were noted to lie either within the muscle fibers of the dorsal interossei muscles or beneath them. The vessels lay within the muscles in 53% of the cases, and beneath the muscles in 47%. However, on the left feet, the relation of the DMTAs to the dorsal interossei muscles varied. The 1st DMTA was noted to be above the muscles in 40% of the cases, within the muscles in 53%, and beneath the muscles in 7%. The 2nd DMTA was noted to be

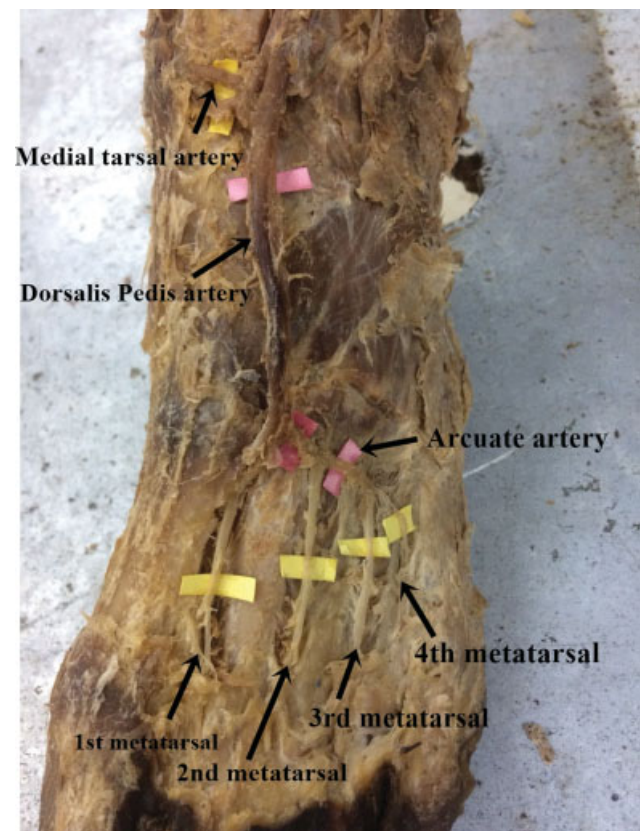


Fig. 1 Image showing the 1st type of branching pattern of the dorsalis pedis artery. Note the dorsalis pedis artery giving the arcuate artery (which gives the 2nd to 4th dorsal metatarsal arteries), while the dorsalis pedis artery continues as the 1st dorsal metatarsal artery.

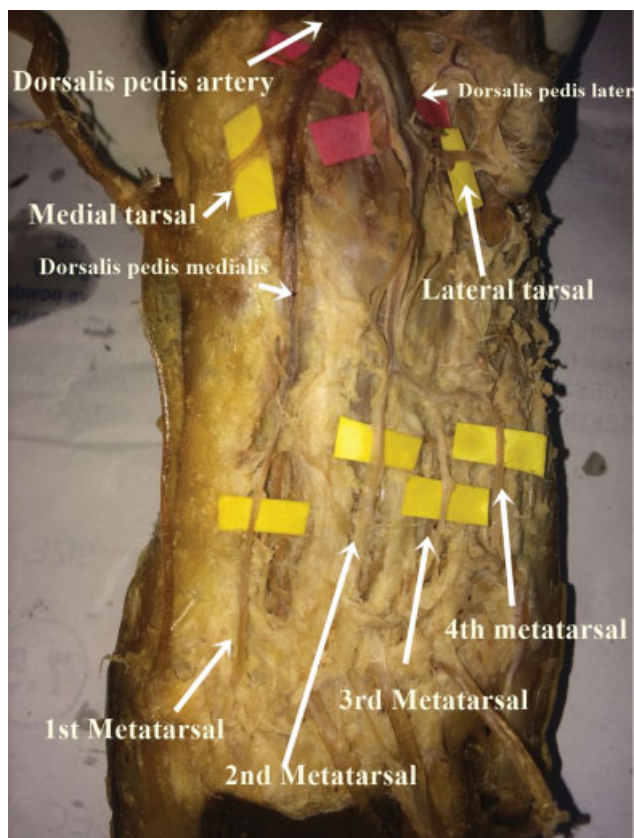


Fig. 2 Image showing the 2nd type of branching pattern of the dorsalis pedis artery. Note the dorsalis pedis artery dividing to give a lateral dorsalis pedis artery and a medial dorsalis pedis artery. The lateral dorsalis pedis artery gives the 2nd to 4th dorsal metatarsal arteries, while the medial dorsalis pedis artery continues as the 1st dorsal metatarsal artery.

above the muscles in 57% of the cases, and within muscles in 43%. The 3rd DMTA. On the other hand, it was above the muscles in 53% of the cases, and within the muscles in 47%. The 4th DMTA was noted to be above the muscles also in 53% of the cases, and within in 47% (► **Table 2**) (► **Fig. 4A–BC**).

Discussion

All of the the DMTAs were present in all of the cases of the present study. This is similar to data derived by Yeo et al⁷ in the Singapore population, who found that the 1st DMTA was present in 100% of the specimens. However, in contrast, in the American population, Upton⁶ found that the 1st DMTA was absent in 9% of the cases, while Kulkarni et al⁵ found that the 1st DMTA was absent in 33.3% of the cases in the Indian population. In another Indian study, Awari et al³ found that the 1st DMTA was absent in 8% of the feet. Absence of the DMTA could be attributed to some combinations of persistent primitive arterial segments, to abnormal fusions, to segmental hypoplasia of arteries, or to absence during the embryological development.¹¹ The presence or absence of DMTAs could influence their selection for flaps;^{12,13} however, since all of the DMTAs were present in our study, their selection in flap and reconstructive surgeries is recommended.

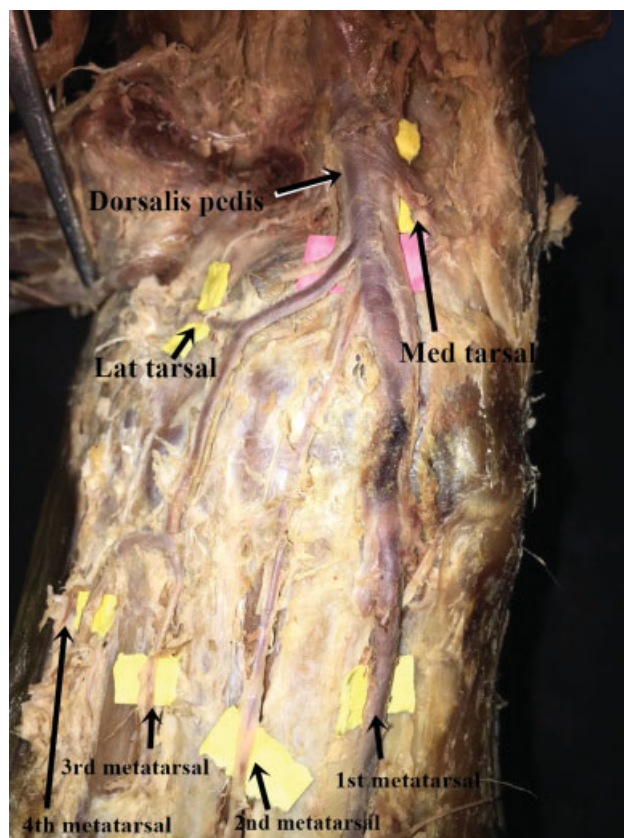


Fig. 3 Image showing the 3rd type of branching pattern of the dorsalis pedis artery. Note that the dorsalis pedis artery gives out the 2nd dorsal metatarsal artery as a single branch, and the lateral tarsal artery (which gives out the 3rd and 4th dorsal metatarsal arteries). It then continues off as the 1st dorsal metatarsal artery.

Table 1 Morphometric distance of the dorsal metatarsal arteries from their respective metatarsal bone bases

Side	Number	Morphometric distance (mm)	
		Mean	Range
Right	1 st	2.36	0.55–.44
	2 nd	1.18	1.01–2.82
	3 rd	1.52	0.84–2.71
	4 th	1.46	0.84–3.02
Left	1 st	1.46	0.57–3.83
	2 nd	2.60	0.65–2.70
	3 rd	1.60	0.60–2.84
	4 th	1.80	0.60–2.62

Regarding the origin of the DMTAs on the right feet, the 1st DMTA originated mostly as a branch of the main DPA, while the 2nd DMTA was given off as a direct branch from the DPA, while the 3rd and 4th DMTAs arose as branches from the LTA. On the left feet, however, the 1st DMTA originated mostly as a branch of the main DPA, while the 2nd, 3rd and 4th DMTAs arose as branches from the AA. These findings on the origin of the 1st DMTA are similar to those in the Indian population,

Table 2 Relation of the dorsal metatarsal arteries to the dorsal interossei muscles

Side (n = 30)	Relation of the DMTA to the dorsal interossei muscles	Frequency (%)
Right (All DMTAs had the same pattern)	Above	–
	Within	53
	Beneath	47
Left		
	1 st	
1 st	Above	40
	Within	53
	Beneath	7
2 nd	Above	57
	Within	43
	Beneath	–
3 rd	Above	57
	Within	43
	Beneath	–
4 th	Above	57
	Within	43
	Beneath	–

in whom the 1st DMTA was a branch of the DPA in most of the cases.³

Regarding the origin of the other DMTAs, data from Egypt found that the 2nd, 3rd, and 4th DMTAs arose from the AA in 85% of the specimens.⁸ In the Indian population, the 2nd, 3rd, and 4th DMTAs were seen arising from the AA in 60%, 54%, and 40% of the cases,³ respectively. Additionally, in the same Indian study, the 2nd DMTA originated from the DPA in 10% of the feet, from the deep plantar arch in 18% of the feet, and from the LTA in 10% of the feet. The 3rd DMTA originated from the deep plantar arch in 16% of the feet, and from the LTA in 22% of feet. The 4th DMTA

originated from the deep plantar arch in 24% of the feet, and from the LTA in 18% of the feet. Another study on the Indian population also revealed that the 3rd and 4th DMTAs arose from the 2nd DMTA in 5% of the cases.⁵

However, data on the 2nd, 3rd and 4th DMTAs contrast slightly. Data from Australia (El Saeed et al)⁸ and India (Awari et al)³ suggest that these DMTAs originated majorly from the AA. This is similar to data obtained in our setting, but specifically for the left feet. The origins of the 2nd to 4th DMTAs on the right feet, however, contrast sharply from all of the data that has been reported on it from other populations. Data on the origin of the DMTAs can help endovascular surgeons to select the artery to be revascularized based on the angiosome concept in critical limb ischemia cases to avoid the amputation of feet of diabetic patients, as well as in reconstructive surgeries.^{12,13} Therefore, in our setting, it is worth noting that approaches to the DMTA flaps should be slightly different when comparing procedures in the left feet with those in the right feet.

The DMTAs on the right feet were predominantly within the muscles, as compared with beneath or above. On the left feet, the 1st DMTA was predominantly within the muscles, while the other DMTAs were mostly above the muscles. This data contrasts sharply with that of the Chinese population,⁷ in whom the first dorsal metatarsal artery lies superficial to the muscles in 11% of the population, and between the muscles and the 1st metatarsal bone in 84%. It has been documented that the flap selection is easy when the dorsal metatarsal artery is superficial, since, in this case, the dissection of the pedicle is easy. Therefore, in the present study, the left 2nd, 3rd and 4th DMTAs would be more suitable for flap selection as compared with the other DMTAs.

The Dorsal Metatarsal artery has also been shown to portray variations in its relation to the dorsal interossei muscles. Data, especially on the 1st DMTA from the Chinese population, showed that the vessel lies superficial to the muscle in 11% of the population, and between the muscle and the 1st metatarsal bone in 84%.⁶ However, in our case, we did not record any vessel that lay between the muscle fibers

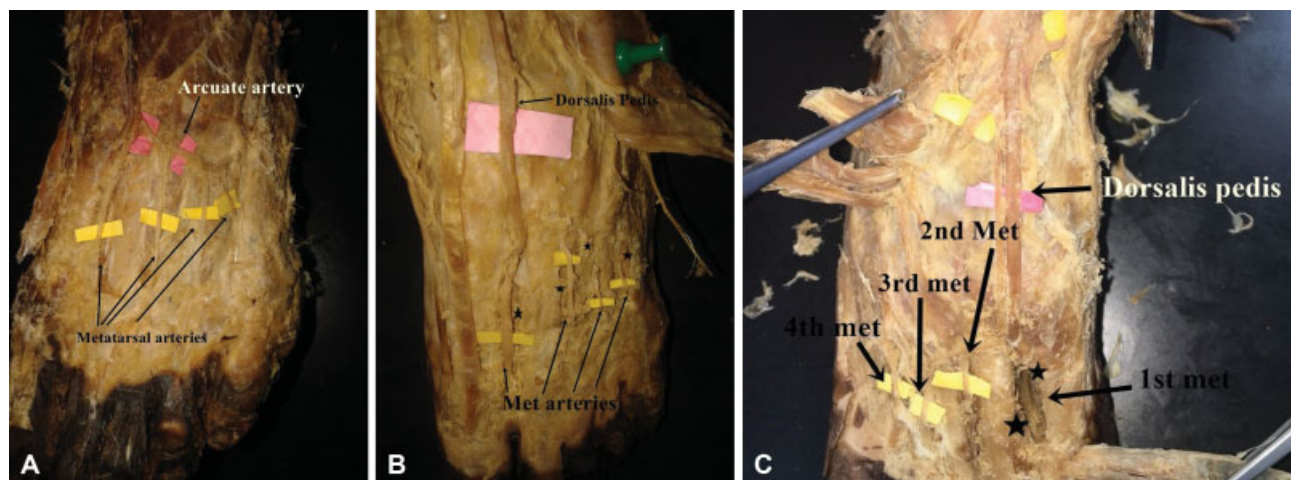


Fig. 4 (A) The dorsal metatarsal arteries are above the muscles. (B) The dorsal metatarsal arteries are within the dissected muscle fibers (*). (C) The 1st dorsal metatarsal artery appears deep into the dissected muscle fibers (*).

or beneath the muscles. When the vessel lies beneath or within the muscles, surgeons have been reported to cut open the muscles and try to dissect out the artery during flap selection. This causes many pitfalls during the surgery, by damaging the muscles, jeopardizing the blood supply to the skin, making the procedure more complicated, and prolonging the surgical time.⁶ This is in contrast to when the vessel is superficial, when the dissection of the pedicle is easy. The differences noted in the origin and in the course of the DMTAs may be due to the heterogeneity in the genetic makeup of different races. This difference may account for the different embryological development of the vessels and, therefore, in variant anatomy.

In conclusion, these results reveal that the DMTAs show variation in origin and in position in relation to the dorsal interosseus muscles. These variations display bilateral asymmetry. Surgeons should be ware when taking flaps from the dorsum of the foot. Preoperative ultrasound evaluation is recommended.

Conflicts of Interests

The authors have no conflicts of interests to declare.

Acknowledgments

We are grateful to the staff of the gross anatomy laboratory for the technical assistance and to Ms. Antonina Odock for the typing the manuscript

References

- 1 Sinnatamby CS. 2011 Last's Anatomy. Regional and applied. 12th edition. Chapter 3. Churchill Livingstone, Elsevier: Lower limb; 145–146
- 2 Standring S. 2008 Gray's Anatomy. The anatomical basis of clinical practice. 40th edition. Section 9, chapter 84: Churchill Livingstone, Elsevier 1455–1456
- 3 Awari PS, Vatsalaswamy P. Anatomical variations in dorsal metatarsal arteries with surgical significance: A cadaveric study. *Indian J Vascular Endovascular Surgery* 2017;4:176–179
- 4 Hou Z, Zou J, Wang Z, Zhong S. Anatomical classification of the first dorsal metatarsal artery and its clinical application. *Plast Reconstr Surg* 2013;132(06):1028e–1039e
- 5 Kulkarni V, Ramesh BR. A morphological study of dorsalis pedis artery and its clinical correlation. *IOSR J Pharm Biol Sci* 2012; 2:14–19
- 6 Upton J. Direct visualization of arterial anatomy during toe harvest dissections: clinical and radiological correlations. *Plast Reconstr Surg* 1998;102(06):1988–1992
- 7 Yeo CJ, Sebastin SJ, Ho SY, Tay SC, Puhaindran ME, Lim AY. The dorsal metatarsal artery perforator flap. *Ann Plast Surg* 2014;73 (04):441–444
- 8 El Saeed EM, El-Monsif AA, El-Sayed MA, Aly NM, Gezlan NA. Anatomical study of the dorsalis pedis artery and its surgical importance in reconstructive surgery. *Alexandra Bull Fac Med* 2008;44:557–571
- 9 Gabrielli C, Olave E. Origins of the dorsal metatarsal arteries in humans. *Scand J Plast Reconstr Surg Hand Surg* 2002;36(04): 221–225
- 10 Hollinshead WH. 1958 *Anatomy for Surgeons: The Back and Limbs*. 3rd ed. New York: Hoeber- Harper; 1958
- 11 Atanasova M, Georgi P, Georgie and Jeleu L., 2011. Intriguing variations of the tibial arteries and their clinical implications. *IJAV* 2011;4:45–47
- 12 Koul AR, Patil RK, Philip VK. Coverage of defects over toes with distally based local flaps: A report of four cases. *Indian J Plast Surg* 2008;41(01):62–66
- 13 Limthongthang R, Eamsobhana P. First dorsal metatarsal artery perforator flap to cover great toe defect. *J Orthop Surg (Hong Kong)* 2017;25(03):2309499017739497