

Interventional Radiology-Guided Procedures in the Treatment of Pediatric Solid Tumors: A Systematic Review and Meta-Analysis

Elisa Zambaiti¹ Alexander Siles Hinojosa² Valentina Montano³ Annika Mutanen⁴
Mathilde Glenisson⁵ Sabine Sarnacki⁶ Stephanie Franchi Abella⁷ Daniele Pariente⁷ Luca Pio⁶

¹ Department of Women's and Children's Health, Pediatric Surgery, Università degli Studi di Padova Dipartimento di Medicina, Padova, Italy

² Pediatric Surgery Department, Miguel Servet University Hospital, Zaragoza, Spain

³ Department Pediatric Surgery, Fondazione IRCCS Ca' Granda Ospedale Maggiore Policlinico, Milan, Italy

⁴ Division of General and Thoracic Surgery, Hospital for Sick Children, Toronto, Ontario, Canada

⁵ Department of Pediatric Surgery and Urology, Robert Debré Hospital, Assistance Publique-Hôpitaux de Paris (AP-HP), Paris, France

⁶ Hôpital Necker-Enfants Malades, Assistance Publique-Hôpitaux de Paris, Department of Pediatric Surgery and Urology, Descartes University, Université de Paris, Paris, France

⁷ Pediatric Radiology Department, Assistance Publique-Hôpitaux de Paris (AP-HP), Bicêtre Hospital, Le Kremlin-Bicêtre, France

Address for correspondence Luca Pio, MD, Paris Descartes University, Université de Paris, Hôpital Necker-Enfants Malades, Assistance Publique-Hôpitaux de Paris, Department of Pediatric Surgery and Urology, 149 rue de Sèvres, 75015, Paris, France (e-mail: lucakeats@hotmail.it).

Eur J Pediatr Surg 2020;30:317–325.

Abstract

Keywords

- ▶ interventional radiology
- ▶ pediatric surgical oncology
- ▶ radiologic embolization
- ▶ pediatric oncology

Introduction The use of interventional radiology (IR) in the treatment of pediatric solid tumors has markedly increased over the last three decades. However, data on effectiveness of IR-techniques, such as embolization/ablation, are scarce. In this systematic review and meta-analysis, we examined the outcomes of IR-procedures in the treatment of solid tumors in children.

Materials and Methods Using a defined search strategy, we searched for studies reporting the use of IR-techniques for pediatric solid tumors from 1980 to 2017. Reports with less than three patients, review, and opinion articles were excluded. The study was conducted under preferred reporting items for systematic reviews and meta-analyses (PRISMA) guidelines. We analyzed dichotomous and continuous variables by appropriate statistical methods.

Results Of 567 articles screened, 21 papers met the inclusion criteria (12 retrospective, 7 prospective, and 2 randomized-control trials). Many of the analyzed papers described relatively small cohorts of patients. IR-guided procedures were mainly rescue procedures to treat primarily unresectable tumors, local recurrences, or metastases.

received
January 10, 2019
accepted after revision
May 14, 2019
published online
June 23, 2019

© 2020 Georg Thieme Verlag KG
Stuttgart · New York

DOI <https://doi.org/10.1055/s-0039-1692655>.
ISSN 0939-7248.

Inclusion/exclusion criteria and success definition were not specified in most reports. Major side effects were documented in 17/286 (6%) infants, while minor side effects were self-limiting in most patients. Six studies had a comparison between tumor embolization (127 infants) to surgery or chemotherapy without IR-procedures (113 controls). The meta-analysis showed lower mortality (16 vs. 47%) and surgical time for resection (206 vs. 250 m), higher 2-year tumor-free survival (82 vs. 36%), and favorable histology in IR group ($p < 0.001$ for all).

Conclusion IR-guided techniques are promising in the treatment of pediatric solid tumors. Further prospective (randomized) trials are needed to clarify efficacy.

Introduction

Interventional radiology (IR) is a relatively new branch of application of imaging to guide diagnostic or therapeutic procedures. In adults, there is a range of evidence available on IR-guided procedures,^{1,2} especially on the treatment of solid tumors, while in children there are limited applications described. IR-guided procedures consist in primary, adjuvant, and neoadjuvant interventions following surgical resection or chemotherapy. They can be divided according to either the radiological technique used to monitor or perform the procedure, the type of ablative energy used to hit the tumor or the invasiveness of the method applied.³ Among the different approaches available, the two most frequently used methods are radiofrequency ablation (RFA) and IR-guided transarterial chemoembolization (TACE). RFA has been widely used in children to treat benign lesions, such as osteoid osteoma,⁴ and for the ablation of the accessory conduction pathways responsible for cardiac arrhythmia.⁵ In the recent years, RFA has been increasingly enforced as curative or palliative intent for solid tumors, either alone or in combination with systemic (immune or chemotherapy) or locoregional therapies (radiotherapy or chemoembolization).⁶ TACE is used as a local tumor control method with chemotherapy drugs used as embolizing agents. In pediatric patients, IR has been recently increasingly applied to treat primary and metastatic pediatric tumors localized in brain, liver, lung or kidney, or to treat oncological nonresponsive pain.⁷ However, little is known on the efficacy of IR-guided procedures in pediatric patients. Potential advantages of IR-guided techniques over surgical approach could be the treatment of deep lesions with smaller tissue losses compared to resection. Moreover, the presence of radiological guidance during the procedure could increase accuracy and allow the detection of any viable tumor remaining immediately after the procedure.

In this systematic review and meta-analysis, we investigated the literature to review the role of IR-guided procedures in pediatric patients, with a special interest on outcomes, including operative-related parameters, complications, and, finally, efficacy to decrease mortality and improve tumor-free survival.

Materials and Methods

The systematic review and the meta-analysis were adhered to the preferred reporting items for systematic reviews and meta-analyses (PRISMA) statement. This study was registered on international prospective register of systematic reviews (PROSPERO) (CRD42018093996).

Systematic Review

A systematic review of the literature was done using a defined search strategy. Two investigators (E.Z. and A.S.H.) independently searched scientific databases, such as PubMed, Medline, Cochrane Collaboration, Embase, and Web of Science, using a combination of keywords, pediatric oncology and embolization or ablation. We considered all papers published between 1980 and 2017, as the first applications of percutaneous intra-arterial procedures in the children dated early in the 1980s.⁸ The reference lists of potentially relevant articles were also manually searched to identify additional eligible studies. Exclusion criteria were articles in a language other than English, case reports, opinion articles, and case series with less than three patients. All gray literature publications (i.e., reports, theses, conference proceedings, bibliographies, commercial documentations, and official documents not published commercially) were also excluded. For studies, reporting data that overlapped the article published earlier was excluded. The full text of the potentially eligible studies was retrieved and independently assessed for eligibility by the same two investigators. Any disagreement between them over the eligibility of particular studies was resolved through discussion with a third author (V.M.).

Data Extraction

Data extracted from the included articles with study characteristics (authors, publication year, type of the study, time length of the study, presence of specific inclusion/exclusion criteria or definition of success, sample size, and follow-up period) and patient/tumor characteristics (localization and type of tumor, age at inclusion, type of IR procedure, and eventual additional procedures). Specific information on outcomes, including operative time, blood losses during surgery, mortality, two-year tumor-free survival, and

percentage and type of complications were collected and analyzed. Not all outcomes were reported in each article.

Meta-Analysis

Meta-analysis was conducted with Review Manager 5.3 (RevMan 5.3) using the random-effects model to produce risk ratio (RR) for categorical variables and mean differences (MDs) for continuous variables, along with 95% confidence intervals (CI). We produced I^2 values to assess homogeneity. Publication biases were assessed using the funnel plot method.

Due to the scarcity of papers describing ablation procedures in children and the absence of studies comparing surgery or chemotherapy alone versus ablation, we included in the meta-analysis only papers describing the use of IR-guided embolization as adjunct to classic therapy (surgery/chemotherapy) versus classic therapy alone for the treatment of pediatric solid tumors. Outcomes measured included success rate, 2-year tumor-free survival, treatment complications, and tumor specific markers.

Two independent authors (E.Z. and V.M.) independently assessed study quality using the Newcastle–Ottawa scale (total 9 stars) and then came to a consensus for all papers included in the meta-analysis. Studies with low risk of bias were allocated > 7 stars, moderate risk with 4 to 6 stars, and high risk with < 3 stars.

All data are expressed as medians and interquartile range (IQR) unless otherwise stated. p -values of < 0.05 were considered statistically significant.

Results

Literature Research

Of 567 titles screened, 133 abstracts were analyzed, and 39 full-text articles were examined. Of these, 21 papers (451 infants) met our inclusion criteria (→ Fig. 1). Of the included articles, 12 were retrospective studies, seven prospective, and two randomized control trials. Of these, only six papers had a direct comparison between patients treated with IR-embolization versus not treated with IR and could thus subsequently be included in the meta-analysis.

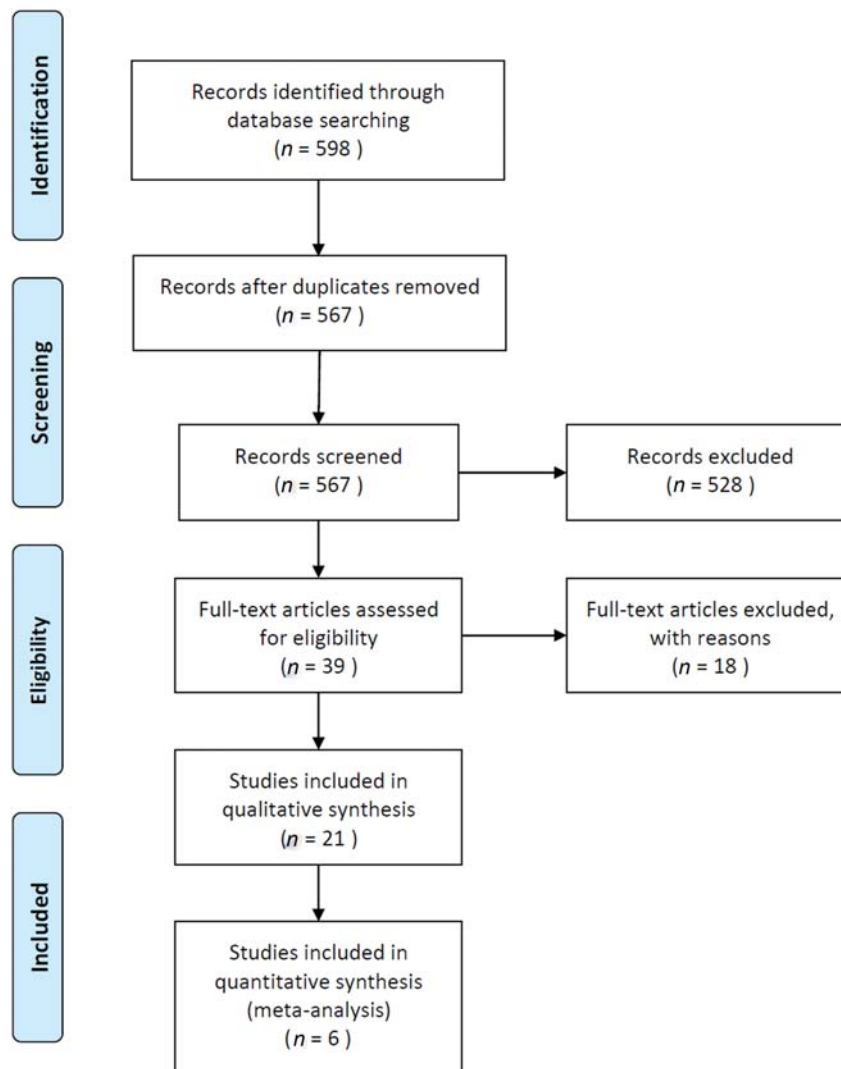


Fig. 1 Diagram of workflow in the systematic review and meta-analysis.

Study Characteristic: Systematic Review

A total of 451 patients were included in the study (range 5–66 depending on the paper); of those, 286 patients underwent an IR-procedure (range 3–46). Age at inclusion ranged from a minimum of 0 years (median 1–3 years, interquartile range [IQR] 0–325) to a maximum of 18 years (median 12 years, IQR 475–1,525). Mean duration of follow-up was 395 months (range 2–156).

A total of 259 tumors were treated overall with IR, mainly located in liver (15 papers), lungs (6), kidneys (5), brain (1), and soft tissues (2). Tumor type was mainly hepatoblastoma (12 papers), hepatocellular carcinoma (4), nephroblastoma (4), osteosarcoma (1), and others (four). In 18 studies IR was used to treat primary tumors, while in 9 studies was used to treat either metastatic or recurrent disease.

Only 10 papers out of 21 reported specifying inclusion criteria (–Table 1), and only three specify exclusion criteria. Included criteria were most commonly dimension and unresectability of the tumor, presence of stable haematological parameters (platelet and neutrophils count, creatinine), and absence of involvement of other organs (encephalitis, nodules or vascular involvement). Preinterventional biopsy

was performed in 12 cases, in 1 specifically not, not mentioned in the others.

A total of 329 procedures were performed (range, 5–66 depending on the paper), four papers describe thermal ablation (3 by radiofrequency and 1 by cryoablation), and 17 chemoembolization. In nine papers, IR was used as primary procedure to treat the tumor, while in 16, it was used as a rescue procedure for either unresectable tumors or relapse of preexisting disease.

In eight papers, IR was described as adjuvant therapy before surgery, in four, was described as rescue procedure following either surgery or chemotherapy, and in five, a combination of the two.

Five papers did not report the presence and number of complications; among the others, 17 patients were found to have major complications, mainly bone marrow suppression (7), embolism (3), pneumothorax (1), hemiparesis (1), cardiotoxicity (1), sepsis (1), gastric ulcer (1), and rib deformations (2), with an overall calculated risk of major complications of less than 6%. Seven papers reported no major complications. 136 patients were reported to have minor complications related to the procedure, mainly postablation syndrome (pain, fever, and weakness).

Table 1 Indications for IR-guided procedures

Author	Type of tumor, localization	Type IR-procedure	Indication to IR-procedure
Yevich et al	Osteosarcoma, lung	CT-thermal ablation (RFA, CA)	Locoregional primary cancer control; metastases limited to the lung; number < 5 nodules; size < 2 cm; technically treatable nodules
Tan et al	Hepatoblastoma, liver and lung	TACE	Unresectable (both lobes affected, hepatic vein and inferior vena cava involvement, multiple diffuse lesions, distant metastases.)
Wang et al	Hepatoblastoma, liver and lung	TACE + HIFU	Hepatoblastoma confirmed at biopsy; no history of encephalopathy; stable hematogenic parameters; no active infection
Zhang et al	Hepatoblastoma, liver	TACE	Hepatoblastoma stage III–IV
Zhang et al	Hepatocellular carcinoma, liver	RFA, TACE	Unresectable (extrahepatic metastasis, Child–Pugh C, poor general condition)
Li et al	Nephroblastoma, kidney	TACE	Size > 10 cm; periaortic lymph nodes involvement; inferior vena cava invasion; distal metastasis; diffuse anaplastic histology on preop biopsy
Xuewu et al	Hepatoblastoma, liver	TACE	Unresectable
Ohtsuka et al	Hepatoblastoma, liver	TACE	Patients with liver tumor; with/without distant metastases
Malogolowkin et al	Hepatoblastoma or hepatocellular carcinoma, liver	TACE	Unresectable liver tumor; age < 21 years at the time of original diagnosis, performance status < 2 (Karnofsky score, 70–90); life expectancy > 2 mo; full recovery from the toxic effects of prior therapy (neutrophil count > 1,000/mm ³ , platelet count > 100,000/mm ³ , normal serum creatinine, adequate liver function, normal coagulation profile)
Han et al	Hepatoblastoma, liver	TACE	Presence of extensive hepatic involvement with indistinct margins; involvement of the portal vein; involvement of adjacent organs

Abbreviations: CA, cryoablation; CT, computed tomography; RFA, radiofrequency ablation; TACE, trans-arterial chemoembolization.

Interestingly, two papers describing the role of computed tomography (CT)-guided radiofrequency tumor ablation reported local complete ablation following the procedure. In these reports, RFA was performed as palliative approach for metastatic pulmonary tumor in osteosarcoma⁹ or various localizations (lung, liver, and bone) with nonspecific primary tumor (osteosarcoma, nephroblastoma, hepatoblastoma, and others)¹⁰ and in both cases the authors report on absence of local recurrence following IR-guided procedure. We evaluated success according to percentage of reduction of the tumor and classified response as poor or good based on a reduction of less or more than 40%, respectively. The included papers reported wide range of success rate with about a quarter of the patients defined as good responders and the same amount defined as partially responders. Complete ablation was reported from 0 to 80% of patients with a reduction in the size of the tumor from 1 to 86%.

Meta-Analysis

Before analyzing the data, study quality was assessed using the Newcastle–Ottawa scale for cohort studies. In general, the quality of the studies included in the meta-analysis was rather satisfactory, with only two studies at medium risk of bias (4 stars) and all the others with low risk (7–8 stars each).

The most important methodological weakness, common to the two studies that received a low score, was noncomparability of the study group to controls; the control group was constituted of patients with primary resectable tumor while patients in the study group had mainly unresectable tumors. The follow-up time varied between studies being generally around two years. However, some studies did not report follow-up data on both of the groups.^{11,12} Even with the just mentioned limitations, we proceeded to the meta-analysis

including only the papers in which a precise extrapolation of the data was possible.

Six studies (240 patients, 127 treated with embolization) reported data on mortality (→ Fig. 2). There was a significant difference in the mortality between the study groups: hepatic tumors treated with IR had a mortality of 42.86% compared to 70.59% for controls ($p = 0.05$); renal tumors had a mortality of 5.43% in IR group compared to 72.42% for controls ($p < 0.005$). The overall mortality was 15.75% in the IR group compared to 46.90% in the controls (OR = 0.20; 95% CI = 0.09–0.46; $p < 0.005$). Furthermore, there was significant homogeneity between the studies ($I^2 = 0\%$; $p = 0.97$).

However, only three studies on renal tumors reported the 2-year tumor-free survival and were thus included for the subsequent analysis (→ Fig. 3). The 2-year tumor-free survival was significantly lower in control group compared to IR ($p < 0.005$), even though heterogeneity between the studies was slightly significant ($I^2 = 69\%$; $p = 0.04$).

The effect of IR-procedure on operative time was evaluated in two studies.^{13,14} Although one paper did detect significant reduction in operative time following TACE, the two studies were highly heterogeneous in respect of this parameter ($I^2 = 90\%$; $p = 0.001$), with an overall surgical time not significantly different between the two groups ($p = 0.25$, → Fig. 4).

Further comparative evaluations included histological assessment such as tumor cell degeneration and capsule thickening (→ Fig. 5). Tumor cell degeneration is usually classified with an index ranging from X1 (tumor cells actively undergoing mitosis) to X4 (tumor cells completely absent, tissue demonstrates scarring and calcifications).¹⁵ In the included studies, the presence of cells at X3 or X4 grade, majority or totality of tumor cells are necrotic, ruptured,

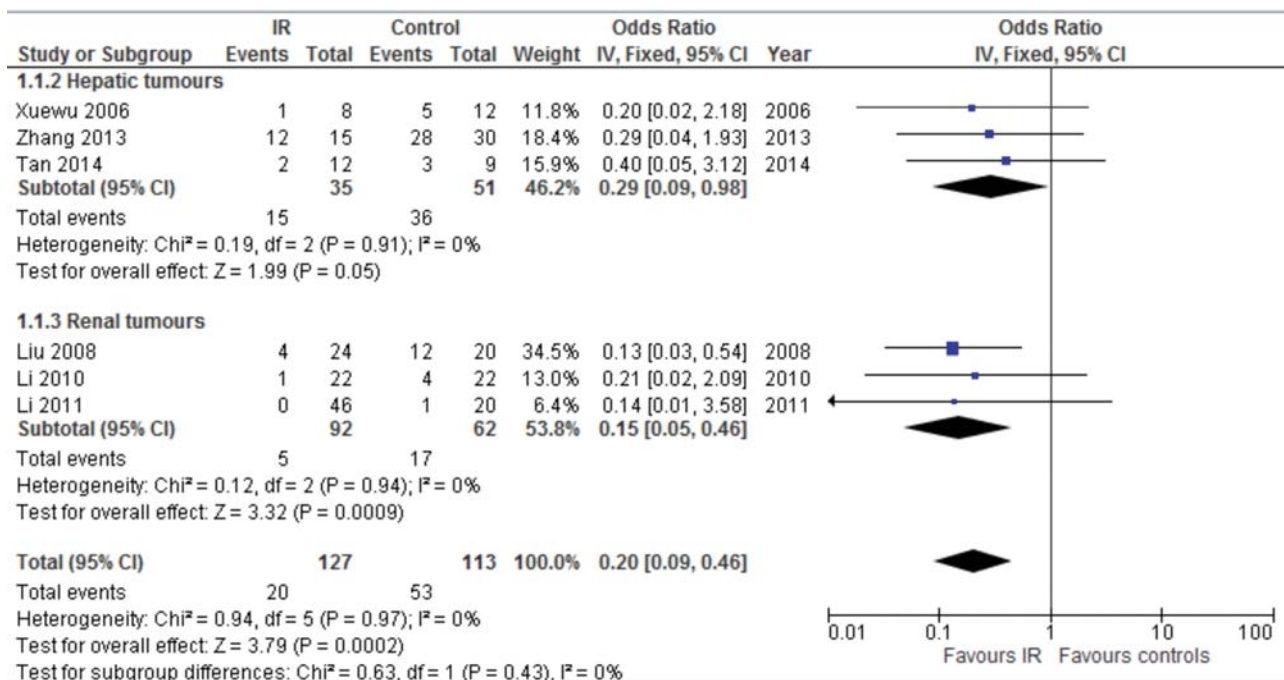


Fig. 2 Forest plot comparison of mortality in infants with hepatic tumors and renal tumors treated with IR-procedures versus surgery/chemotherapy/radiotherapy only. IR, interventional radiology.

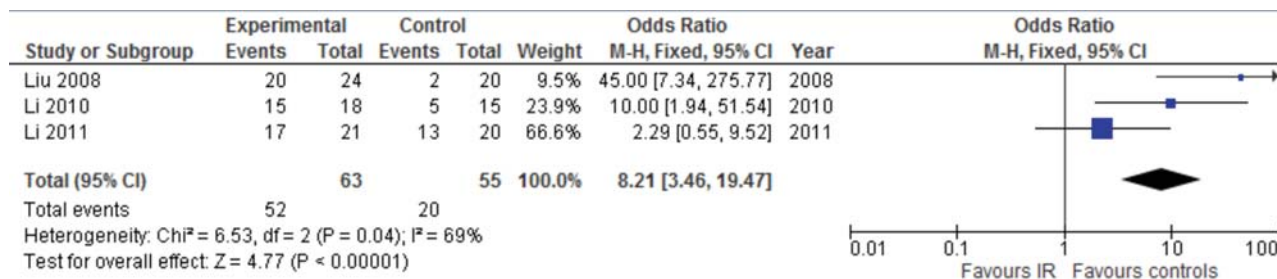


Fig. 3 Forest plot comparison of the 2-year tumor-free survival in infants treated with IR-procedures versus surgery/chemotherapy/radiotherapy only. IR, interventional radiology.

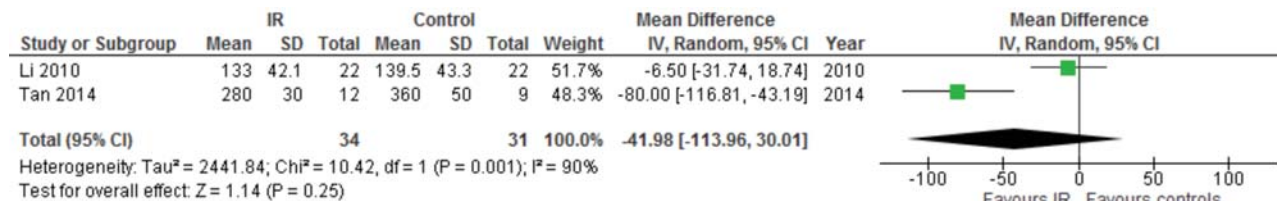


Fig. 4 Forest plot comparison of the surgical time for tumor resection in infants treated with IR-procedures versus surgery/chemotherapy/radiotherapy only. IR, interventional radiology.

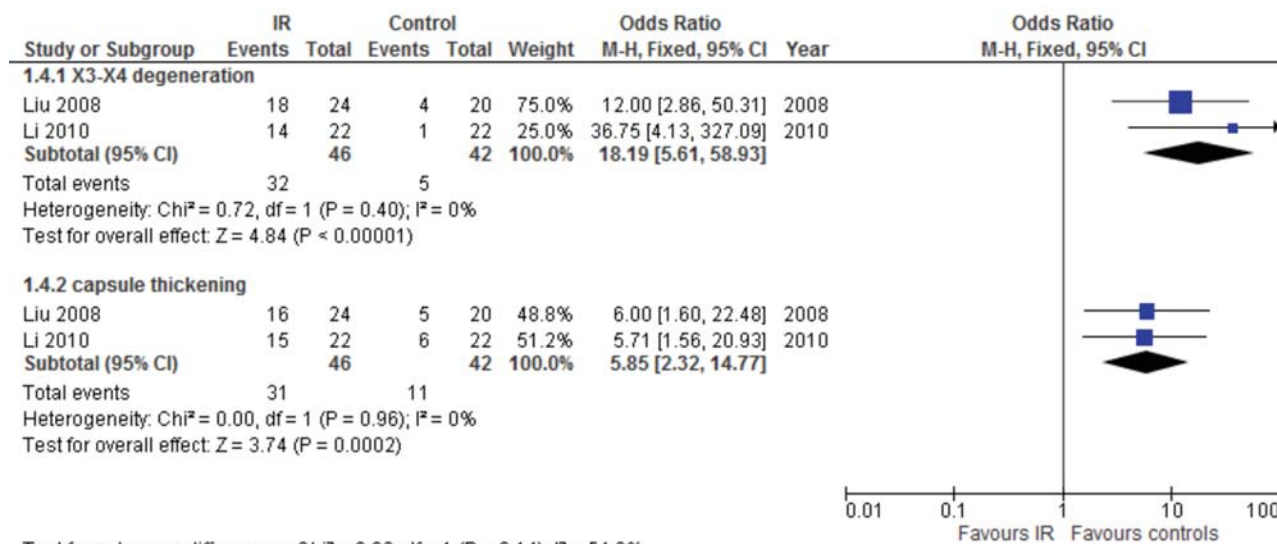


Fig. 5 Forest plot comparison of histological characteristics (X3–X4 degeneration and capsule thickening) in pediatric patients treated with IR-procedures versus surgery/chemotherapy/radiotherapy only. IR, interventional radiology.

and no longer visible, was higher in the IR-group ($p < 0.005$). Similarly, tumor capsule thickness over 3 mm was significantly higher in the IR-group ($p < 0.005$). Both evaluations are homogeneous with an overall $I^2 = 54$; 6%; and $p = 0.14$.

Discussion

Interventional radiology has an increasingly important role in both the diagnosis and management of pediatric solid tumors. IR-guided procedures are usually included in the treatment algorithm at the same level as more aggressive techniques such as surgical resection¹⁶ are often offered as an alternative in patients who are not good candidates for resection due to high

surgical risk or advanced disease. In this systematic review and meta-analysis, we reviewed the role of IR-guided procedures in pediatric oncology with a special interest on outcomes.

Local tumor ablation can be carried out with either the insertion of a probe directly within the neoplastic tissue, the delivery of substances through the vascular system or extracorporeal percutaneous focused treatments.¹⁷

Image-guided placement of probes can be used to ablate primary and metastatic tumors of liver, lung, kidney, bone, and others.¹⁸ In current clinical practice, tumor ablation through probe insertion can be divided, depending on the mechanism it uses to cause injury, into thermal therapies, chemical ablative techniques, and irreversible electroporation. Thermal

ablation is most frequently performed with radiofrequency, microwaves or interstitial laser thermotherapy and it heats the region of interest above a critical temperature to achieve cell death. Besides, thermal ablation could also be applied in cryoablation that, on the contrary, freezes the tumor. Chemical ablative techniques are typified by percutaneous ethanol injection, while irreversible electroporation alters the electrical conductivity and permeability of the cell membrane by means of high-voltage pulses, causing both cellular disruption and thermal damage.¹⁹ Among all those above mentioned techniques, the ones that are most commonly used in clinical setting are ablation, radiofrequency or laser, and transarterial chemoembolization.

RFA use has grown tremendously in the treatment of adult malignancies but has still quite few applications in pediatrics. Good indications could be the presence of deep lesions, with an expected difficulty in surgical removal, or the necessity of organ sparing procedures for significant tissue losses. How children adapt to heat deposition induced by ablation is still unknown; heating a large tumor in a small child raises the hypothetical possibility of dangerous hyperthermia as well as cryotherapy could induce hypothermia.²⁰ Further, studies should address those specific aspects, in the meantime, measures to combat overheating/cooling by using external body coolers/heater during the procedure.²¹ Other complications of RFA potentially include damage to neighboring organs or induction of tumor lysis syndrome, including fever, nausea, pain, and fatigue.²² Recently, new technologies, such as magnetic resonance imaging (MRI)²³ and computed tomography (CT)^{9,10} has been applied to IR-guided procedure to increase accuracy in targeting the lesion and thus also reducing the risk of damaging the healthy organ. These first reports focus on relatively small cohort of either primarily metastatic tumors or tumors with a deep localization. Unfortunately, due to the absence of a control group in all reports, a true comparison and thus inclusion in the metanalysis was not feasible, but the reported efficacy with high tumor/recurrence free survival is promising and worth further studies in this direction.

The treatment of hepatic tumors and among them hepatoblastoma, the most common malignant liver neoplasm in children, is still a matter of debate. Although surgical resection is the mainstay of curative therapy, only one-third to one-half of newly diagnosed patients have resectable disease at presentation often due to presence of metastatic or multifocal disease or the proximity to major vascular structures.²⁴ In nonresectable cases, chemotherapy has a crucial role in rendering the tumors amenable to surgical resection and has progressively led to improved prognosis and survival.²⁵ In an attempt to improve survival and reduce comorbidities related to systemic chemotherapy, highly practical, targeted, and effective alternatives have been recently applied to pediatric population, including TACE,^{26–29} percutaneous ablation therapy techniques, like RFA or percutaneous ethanol injection (PEI), and high-intensity focused ultrasound (HIFU) ablation, an extracorporeal treatment that can cause complete coagulation, necrosis of large lesions without surgical exposure or insertion of instruments.³⁰

Preoperative chemoembolization combined with short-term systematic chemotherapy has been proposed as valuable for reducing operative time, increase resection rate of the tumor, and ameliorate prognosis.^{12,31} In this meta-analysis, hepatic tumors treated with IR had a significant lower mortality (43%) compared to control groups (71%) when IR was not used.

These findings are possibly due to induction of tumor cell necrosis, degeneration and apoptosis, boost of interstitial fibrous tissue hyperplasia, and lymphocyte infiltration¹⁴ related to the cytotoxic effects of the chemotherapeutic drugs, antitumor effect of the embolic drugs, ischemia, and anoxia caused by embolism.³² In our meta-analysis, tumors in the IR-group had both increased interstitial fibrosis and increased capsule thickness. We speculate that these findings could potentially have the benefit on preventing tumor rupture and limiting tumor cell dissemination during surgical resection. Unfortunately, so far, the clinical application of these new technologies is limited, but some reports highlight that used alone or in combination they can achieve a better outcome in terms of tumor-free survival³³ and large-scale clinical trials are desirable to investigate whether the combined therapy may become a conventional treatment for children with hepatoblastoma.

Another good indication for IR-guided procedures could be metastatic lung localization in osteosarcomas, rhabdomyosarcomas, Wilms' tumor, and hepatoblastomas,¹⁷ especially in the setting of palliative care.³⁴ Due to the particular location within the rib cage and the presence of multiple lesions in the same patient, the treatment of choice for this type of lesions has been so far radiofrequency ablation, often CT-guided.^{9,10} Finally, angioembolization has been applied in the management of selected patients with nephroblastoma, neuroblastoma, paraganglioma, osteosarcoma, and sarcoma³⁵ as valuable alternative in case of unresectability or when the conventional therapies had failed as well as magnetic resonance-guided laser interstitial thermal therapy for brain tumors.²³

In this metanalysis, renal tumors mortality was highly reduced (5.43%) in IR group compared to control group (72%) in which IR was not used, highlighting the possible usefulness of these procedures as adjunct to conventional therapies.

Limitations

There are some limitations in the current study. From a qualitative point of view, many published cases are poorly described, in terms of both the technical aspects of the procedures and clinical outcomes, which make them difficult to compare and to drive conclusions. Moreover, most reports describe treatment with palliative intent in patients that in many cases have failed to respond to other available therapies. This selection for poor candidates may contribute to a failure to achieve similar results to those already reported in adults. In pediatrics, these results should be evaluated with caution, as treatment modality, drug doses, and type as well as surgical indications are continuously reassessed and

optimized. Moreover, specific value of IR-procedures is hard to determine as currently those are used mainly in combination with gold standard chemotherapy/surgical approach or whenever those first line approaches are not exploitable. Lastly, a proper meta-analysis is achievable only between patients treated with chemoembolization, since reported cases on ablation are scarce. Because pediatric cancer is relatively rare and indications for ablative therapies are few, the only way to evaluate individual modalities in specific clinical situations will be to develop multicenter international studies.

To summarize, based on the literature review and the meta-analysis, preoperative chemoembolization procedures undergoing subsequently surgical resection showed lower mortality and surgical time compared to the classic treatment (neoadjuvant chemotherapy and/or surgery), higher 2-year tumor-free survival, and better histological parameters ($p < 0.001$ for all) suggesting that IR guided therapies are promising in the field of pediatric solid tumors. However, the data are limited, highlighting the need for future prospective studies.

Conclusion

IR-guided procedures and preoperative chemoembolization in particular, are feasible and promising treatments for certain pediatric tumors and seems to be associated with lower mortality and better outcomes compared to surgery or chemotherapy alone. However, according to the data we extrapolated, the quality of evidence from the analyzed literature is suboptimal. Specific prospective trials focusing on IR in pediatric solid tumor oncology are essential to overcome limitations of the current literature and clarify efficacy, especially in early-stage tumors.

Conflict of Interest

None declared.

References

- Vogl TJ, Nour-Eldin NA, Hammerstingl RM, Panahi B, Naguib NNN. Microwave ablation (MWA): Basics, technique and results in primary and metastatic liver neoplasms - review article. *RoFo Fortschr Geb Rontgenstr Nuklearmed* 2017;189(11):1055–1066
- Kenny LM, Orsi F, Adam A. Interventional radiology in breast cancer. *Breast* 2017;35:98–103
- Gummadi S, Eisenbrey JR, Lyshchik A. Contrast-enhanced ultrasonography in interventional oncology. *Abdom Radiol (NY)* 2018;43(11):3166–3175
- Rosenthal DI, Hornicek FJ, Wolfe MW, Jennings LC, Gebhardt MC, Mankin HJ. Percutaneous radiofrequency coagulation of osteoid osteoma compared with operative treatment. *J Bone Joint Surg Am* 1998;80(06):815–821
- Thomas PE, Macicek SL. Catheter ablation to treat supraventricular arrhythmia in children and adults with congenital heart disease: what we know and where we are going. *Ochsner J* 2016;16(03):290–296
- Gómez FM, Patel PA, Stuart S, Roebuck DJ. Systematic review of ablation techniques for the treatment of malignant or aggressive benign lesions in children. *Pediatr Radiol* 2014;44(10):1281–1289
- Meyerson BA, Linderoth B. Mechanisms of spinal cord stimulation in neuropathic pain. *Neurol Res* 2000;22(03):285–292
- Formanek A, Probst P, Tadavarthy S, Castaneda-Zuniga WR, Amplatz K. (Transcatheter embolization [interventional radiology] in the pediatric age group and adolescent). *Ann Radiol (Paris)* 1979;22(2-3):150–158
- Yevich S, Gaspar N, Tselikas L, et al. percutaneous computed tomography-guided thermal ablation of pulmonary osteosarcoma metastases in children. *Ann Surg Oncol* 2016;23(04):1380–1386
- Botsa E, Poulou LS, Koutsogiannis I, et al. CT-guided radiofrequency tumor ablation in children. *Pediatr Radiol* 2014;44(11):1421–1425
- Zhang XF, Liu XM, Wei T, et al. Clinical characteristics and outcome of hepatocellular carcinoma in children and adolescents. *Pediatr Surg Int* 2013;29(08):763–770
- Liu WG, Gu WZ, Zhou YB, Tang HF, Li MJ, Ma WX. The prognostic relevance of preoperative transcatheter arterial chemoembolization (TACE) and PCNA/VEGF expression in patients with Wilms' tumour. *Eur J Clin Invest* 2008;38(12):931–938
- Tan X, Zhang J, Wen Z, et al. Preoperative transcatheter arterial chemoembolization of hepatoblastoma in infants. *J Vasc Interv Radiol* 2014;25(07):1029–1035
- Li JP, Chu JP, Oh P, et al. Characterizing clinicopathological findings of transarterial chemoembolization for Wilms tumor. *J Urol* 2010;183(03):1138–1144
- Tepper M, Vidone RA, Hayes MA, Lindenmuth WW, Kligerman MM. Preoperative irradiation in rectal cancer: initial comparison of clinical tolerance, surgical and pathologic findings. *Am J Roentgenol Radium Ther Nucl Med* 1968;102(03):587–595
- European Association for Study of Liver; European Organisation for Research and Treatment of Cancer. EASL-EORTC clinical practice guidelines: management of hepatocellular carcinoma. *Eur J Cancer* 2012;48(05):599–641
- Liu B, Zhou L, Huang G, et al. First experience of ultrasound-guided percutaneous ablation for recurrent hepatoblastoma after liver resection in children. *Sci Rep* 2015;5:16805
- Bittles MA, Hoffer FA. Interventional radiology and the care of the pediatric oncology patient. *Surg Oncol* 2007;16(03):229–233
- Goldberg SN, Grassi CJ, Cardella JF, et al; Society of Interventional Radiology Technology Assessment Committee and the International Working Group on Image-guided Tumor Ablation. Image-guided tumor ablation: standardization of terminology and reporting criteria. *J Vasc Interv Radiol* 2009;20(7, Suppl):S377–S390
- Hoffer FA, Campos A, Xiong X, Wu S, Oigbokie N, Proctor K. Core body temperature regulation of pediatric patients during radiofrequency ablation. *Pediatr Radiol* 2007;37(03):297–300
- Brown SD, vanSonnenberg E. Issues in imaging-guided tumor ablation in children versus adults. *AJR Am J Roentgenol* 2007;189(03):626–632
- Rhim H, Choi J, Kim Y, et al. Radiofrequency ablation of hepatic tumors: Post-ablation syndrome. *J Vasc Interv Radiol* 2000;11(Suppl.):271–272
- Tovar-Spinoza Z, Choi H. Magnetic resonance-guided laser interstitial thermal therapy: report of a series of pediatric brain tumors. *J Neurosurg Pediatr* 2016;17(06):723–733
- Perilongo G, Shafford E, Maibach R, et al; International Society of Paediatric Oncology-SIOPEL 2. Risk-adapted treatment for childhood hepatoblastoma. final report of the second study of the International Society of Paediatric Oncology-SIOPEL 2. *Eur J Cancer* 2004;40(03):411–421
- Zsíros J, Maibach R, Shafford E, et al. Successful treatment of childhood high-risk hepatoblastoma with dose-intensive multi-agent chemotherapy and surgery: final results of the SIOPEL-3HR study. *J Clin Oncol* 2010;28(15):2584–2590
- Arcement CM, Towbin RB, Meza MP, et al. Intrahepatic chemoembolization in unresectable pediatric liver malignancies. *Pediatr Radiol* 2000;30(11):779–785
- Czuderna P, Zbrzeźniak G, Narozanski W, Korzon M, Wyszomirska M, Stoba C. Preliminary experience with arterial chemoembolization for hepatoblastoma and hepatocellular carcinoma in children. *Pediatr Blood Cancer* 2006;46(07):825–828

- 28 Li JP, Chu JP, Yang JY, Chen W, Wang Y, Huang YH. Preoperative transcatheter selective arterial chemoembolization in treatment of unresectable hepatoblastoma in infants and children. *Cardiovasc Intervent Radiol* 2008;31(06):1117–1123
- 29 Oue T, Fukuzawa M, Kusafuka T, Kohmoto Y, Okada A, Imura K. Transcatheter arterial chemoembolization in the treatment of hepatoblastoma. *J Pediatr Surg* 1998;33(12):1771–1775
- 30 Wang S, Yang C, Zhang J, et al. First experience of high-intensity focused ultrasound combined with transcatheter arterial embolization as local control for hepatoblastoma. *Hepatology* 2014;59(01):170–177
- 31 Zhang Y, Zhang WL, Huang DS, et al. Clinical effectiveness of multimodality treatment on advanced pediatric hepatoblastoma. *Eur Rev Med Pharmacol Sci* 2014;18(07):1018–1026
- 32 Li MJ, Zhou YB, Huang Y, et al. A retrospective study of the preoperative treatment of advanced Wilms tumor in children with chemotherapy versus transcatheter arterial chemoembolization alone or combined with short-term systemic chemotherapy. *J Vasc Interv Radiol* 2011;22(03):279–286
- 33 Hoffer FA, Daw NC, Xiong X, et al. A phase 1/pilot study of radiofrequency ablation for the treatment of recurrent pediatric solid tumors. *Cancer* 2009;115(06):1328–1337
- 34 Krauel L, Albert A, Mora J, et al. Use of angioembolization as an effective technique for the management of pediatric solid tumors. *J Pediatr Surg* 2009;44(09):1848–1855
- 35 Gómez FM, Patel PA, Stuart S, Roebuck DJ. Systematic review of ablation techniques for the treatment of malignant or aggressive benign lesions in children. *Pediatr Radiol* 2014;44(10):1281–1289