

Concepts in Periodic Discharges: A Descriptive Study

Laxmi Khanna¹ Nandini Agarwal¹ Sabita Kandel¹

¹Department of Neurophysiology, Sir Ganga Ram Hospital, New Delhi, India

Address for correspondence Laxmi Khanna, MD, DNB (Neuro), SCE Neurology (UK), Department of Neurophysiology, Sir Ganga Ram Hospital, Old Rajinder Nagar, New Delhi 110060, India (e-mail: laxmikhanna@hotmail.com).

Int J Epilepsy 2018;5:68–74

Abstract

Introduction Periodic discharges are now known as the ictal–interictal continuum and represent ongoing injury in acute or chronic neurological illnesses.

Objective The aim of our study was to identify periodic discharges in patients who have undergone continuous bedside electroencephalography (EEG) monitoring and to classify the EEG according to the current American Clinical Neurophysiology Society terminology.

Materials and Methods The continuous bedside EEG records of intensive care patients admitted from August 2017 to July 2018 were analyzed. The clinical spectrum, the treatment, and outcome of each of these patients were monitored.

Results Fifty cases of periodic discharges (11 children, 39 adults) were identified over 1 year from 2017 to 2018. The clinical presentation included 32% seizures, 16% status epilepticus, 20% coma, 16% fever with altered sensorium, 8% abnormal behavior, 4% strokes, and 4% traumatic brain injury. The diagnosis was 20% autoimmune encephalitis, 8% herpes encephalitis, 20% multiorgan failure, 4% traumatic brain injury, 16% status epilepticus, 16% posthypoxic encephalopathy, 4% strokes, 4% intracerebral bleeds, 4% meningitis, and 4% severe dementia. Lateralized periodic discharges were identified in 20%, bilateral independent periodic discharges in 20%, and generalized periodic discharges in 60%. Fifty-six percent patients recovered with residual neurological deficits and 44% succumbed to their illness.

Conclusions Continuous bedside EEG monitoring has revolutionized the approach to seizures in critically ill patients. Despite a vigilant approach and diligent diagnosis of these abnormal rhythms, the mortality rate was 20% in patients with lateralized periodic discharges and 60% with bilateral and generalized periodic discharges ($p \leq 0.05$).

Keywords

- ▶ electroencephalogram
- ▶ encephalitis
- ▶ epilepsy
- ▶ periodic discharges
- ▶ stroke

Introduction

In 1950, Cobb et al described periodic discharges in the electroencephalographic (EEG) recordings of patients with subacute encephalitis.^{1,2} In 1964, Chatrian et al elaborated on the periodicity of sharp waves and spikes in periodic lateralized epileptiform discharges (PLEDs) and since then PLEDs have always been an enigma to the curious mind.^{1,2} Lateralized periodic discharges occur with a frequency of 0.4% to 1% in routine EEGs and are closely associated with seizures.³ However, with the use of continuous EEG monitoring in an intensive care setup, neurology has moved forward in leaps and bounds. In a busy tertiary care hospital equipped with a well-established intensive

care unit, lateralized periodic discharges are encountered in 6.2% to 8.6% of admissions and generalized periodic discharges are recorded in 1% of hospitalized patients.^{3,4}

Fifty patients who were admitted to the intensive care unit during the last year (Aug 2017–July 2018) had periodic epileptiform discharges in their bedside EEG records. This study is a retrospective analysis of the continuous EEG records in patients with ictal–interictal discharges.

The objectives of the study were to classify these abnormal periodic rhythms according to the current American Clinical Neurophysiology Society terminology, to correlate the EEG results with the fascinating clinical spectrum, to record the treatment with the outcome of each of these patients, and to review the current literature.

received

January 10, 2019

accepted after revision

May 5, 2019

DOI <https://doi.org/>

10.1055/s-0039-1692732

ISSN 2213-6320.

Copyright ©2018 Indian Epilepsy Society

License terms



Materials and Methods

The continuous EEG records of 300 patients admitted from August 2017 to July 2018 in the intensive care unit at Sir Ganga Ram Hospital, New Delhi, with seizures, status epilepticus, coma, strokes, head injury, encephalitis, meningitis, cerebral hemorrhage, traumatic brain injury, posthypoxic encephalopathy, and beclouded dementia were analyzed. Out of these, 50 patients who had periodic discharges in the bedside EEG records were included in this study. The duration of these bedside recordings varied from 6 to 24 hours and depended on the severity of the underlying illness. Video EEG recordings were done in all critically ill patients. After informed consent, the clinical details and inpatient records were analyzed. The EEGs of patients with metabolic encephalopathy and drug toxicities were excluded as the neurological impairment in these conditions was transient and reversible with appropriate treatment measures. A quantitative EEG analysis was not done as this facility was not available. A clear evolution of these periodic discharges from lateralized periodic to bilateral periodic discharges and generalized periodic discharges was recorded in critically ill patients suffering from herpes encephalitis, autoimmune encephalitis, hypoxic brain injury, and following status epilepticus.

Recording of the EEG

The bedside EEG recordings were performed in the intensive care unit. A 21-channel digital EEG recording was obtained by 10-20 system of electrode placement. Filter settings were between 0.3 and 70 Hz and paper speed was 30 mm/second.

Classification and Definition of the EEG Findings

For the purpose of this study, we classified the discharges as lateralized periodic discharges, bilateral independent periodic discharges, and generalized periodic discharges. Lateralized

periodic discharges were characterized by lateralized periodic or near periodic spikes or sharp wave complexes throughout most of the recording. Bilateral independent periodic discharges included bilateral asynchronous and asymmetric periodic spikes or sharp waves. Generalized periodic discharges were defined as the occurrence of diffuse, symmetric, and synchronous periodic complexes in 50% of a standard 30-minute EEG recording in both hemispheres. Acute disease: The duration of the illness is less than a month. Chronic disease: The duration of the illness is beyond 1 month.

Statistical Analysis

Descriptive summaries were reported as percentages for categorical variables and mean standard deviation for numerical variables. Statistical analysis was done by descriptive and inferential statistics using chi-squared test. The software used in the analysis was SPSS 22.0 version and GraphPad Prism 6.0 version and a $p < 0.05$ is considered as level of significance.

Results

The demographic profile included 40% females, 60% males, 22% children, and 78% adults. The spectrum of diseases causing the periodic discharges was expanded as 4% pyogenic meningitis, 8% herpes encephalitis, 20% autoimmune encephalitis, 4% intracerebral bleeds, 4% traumatic brain injury, 32% hypoxic encephalopathy, 20% multiorgan failure, and 4% beclouded dementia (→Fig. 1). The clinical presentation was 32% with seizures, 16% status epilepticus, 20% coma, 16% altered sensorium, 8% behavioral abnormalities, 4% hemiparesis, and 4% head injury (→Fig. 2). Lateralized periodic discharges were recorded in 20% patients, bilateral periodic discharges in 20% cases, and generalized periodic discharges in

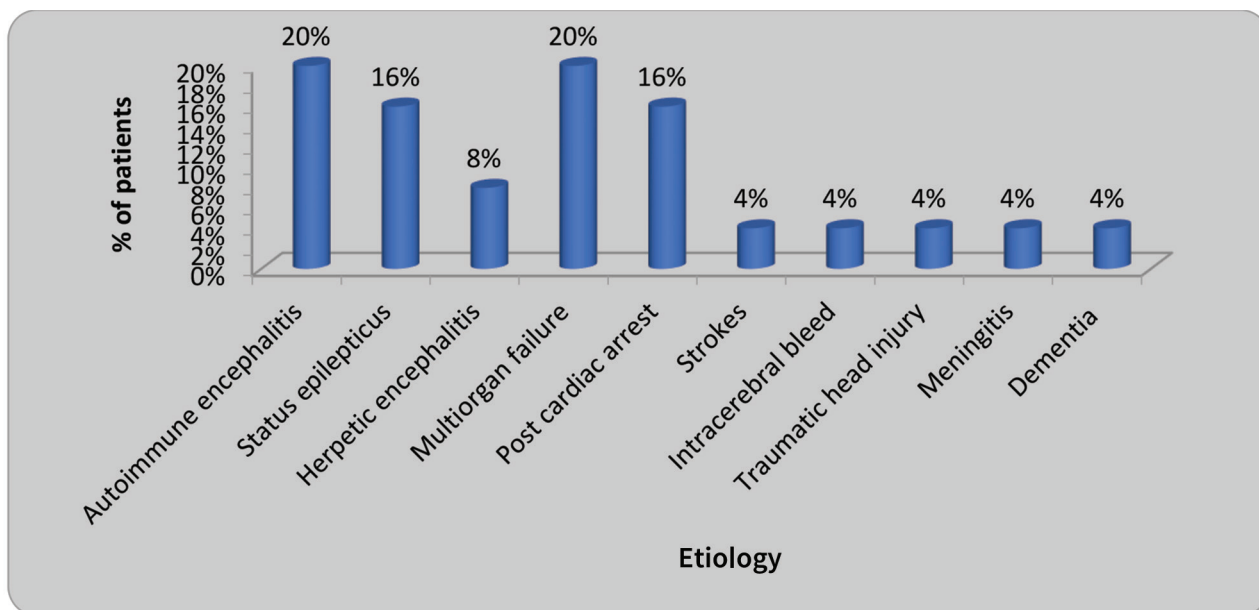


Fig. 1 Etiological factors in periodic discharges.

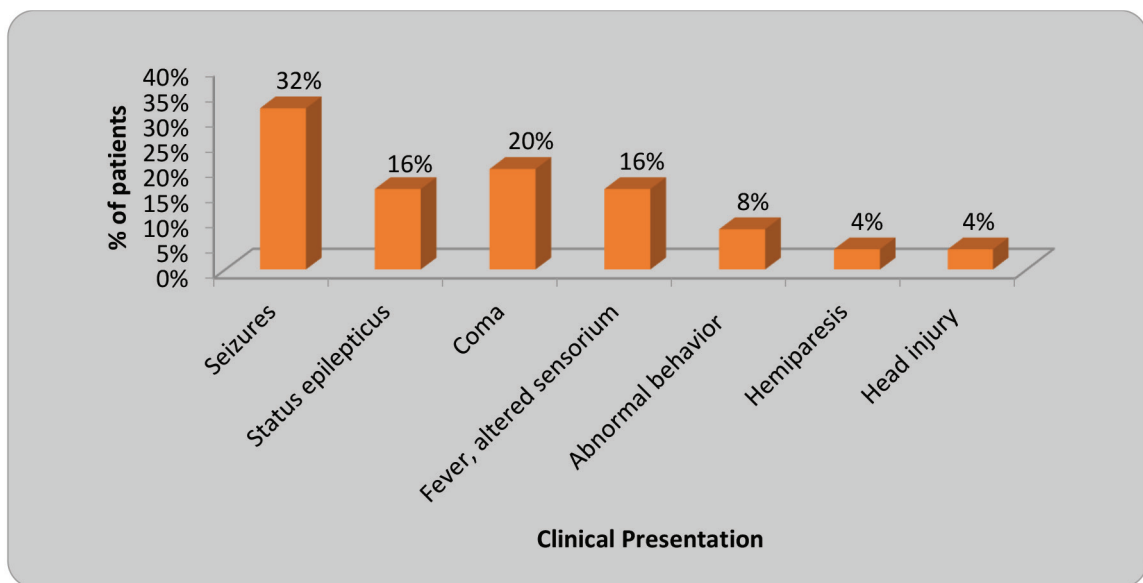


Fig. 2 Clinical presentation of the patients.

60% subjects (►Fig. 3A). Lateralized periodic discharges were recorded in strokes, herpes encephalitis, traumatic brain injury, and intracerebral hemorrhages (►Fig. 3B). Bilateral independent periodic discharges were recorded in cases of autoimmune encephalitis, pyogenic meningitis, and multiorgan failure (►Fig. 3B). Generalized periodic discharges were the hallmark of critical illnesses such as hypoxic encephalopathy, following a status epilepticus, multisystem failure, severe dementia, and autoimmune encephalitis (►Fig. 3B). ►Figure 4 shows the EEG findings in (1) lateralized periodic discharges, (2) bilateral independent periodic discharges, and (3) generalized periodic discharges. ►Figure 5 indicates the outcome with the mortality of the three groups of patients with periodic epileptiform discharges represented as percentage. The mortality was 60% in patients with bilateral independent and generalized periodic discharges and 20% in patients who presented with lateralized periodic discharges (►Fig. 5). Overall, 56% patients recovered and 44% expired (►Table 1). Periodic rhythms were associated with a high mortality rate ($p < 0.05$) with a poor prognosis for survival in all the patients studied (►Table 1).

Discussion

Periodic lateralized epileptiform discharges have a pleomorphic presentation that varies from ictal to interictal discharges with or without rhythmic activity.^{3,4} Based on these EEG findings, Reiher et al in 1991 classified periodic discharges into PLEDs proper and PLEDs plus.²⁻⁵ PLEDs proper had stable EEG patterns and were amenable to treatment.²⁻⁴ PLEDs plus with periodic rhythmic discharges were the sine qua non of acute or subacute brain impairment.^{3,4,6} These EEG findings were recorded in critically ill or comatose patients and were associated with a severe degree of cortical and subcortical dysfunction.²⁻⁴ Hirsch et al in 2005 proposed the concept of the ictal-interictal continuum and

since then periodic discharges are viewed as a spectrum of abnormalities that range from ictal discharges (PLEDs plus) to interictal discharges (PLEDs proper).^{4,6} These terminologies have undergone many revisions and in the recent years the American Clinical Neurophysiology Society has classified the abnormal patterns of the ictal-interictal continuum as generalized, bilateral independent, and lateralized periodic discharges.^{4,6}

In this article, we have included 50 patients admitted to the intensive care unit who had periodic discharges in their continuous bedside EEG recordings. These cases were categorized using the current classification system as 60% generalized, 20% bilateral independent, and 20% with lateralized periodic discharges. Lateralized periodic discharges were seen in emergencies such as cerebrovascular accidents, intracerebral hemorrhages, herpes simplex encephalitis, and following trauma. Untreated, these electrical patterns were associated with focal cortical or subcortical dysfunction that could progress to epilepsy.^{7,8} Bilateral independent periodic discharges represented a wider area of cortical damage and were associated with acute and subacute disease.^{5,7} These EEG findings were recorded in cases of meningitis, encephalitis, and multiorgan failure. Generalized periodic discharges were the consequence of extensive cortical and subcortical damage which occurred in severe encephalopathy or following a status epilepticus. Untreated, these electrographically heterogeneous rhythms led to subclinical seizures with a convulsive or a nonconvulsive status in critically ill patients.^{3,5,8}

Pathogenesis

Periodic discharges were the combined result of seizures, neuronal injury, and metabolic changes in damaged areas of the brain.^{6,9} Cerebral dysfunction increased the cortical excitability and triggered abnormal synchronized after-discharges.⁶ Generalized periodic discharges represented disruption of the interconnected cortical and subcortical

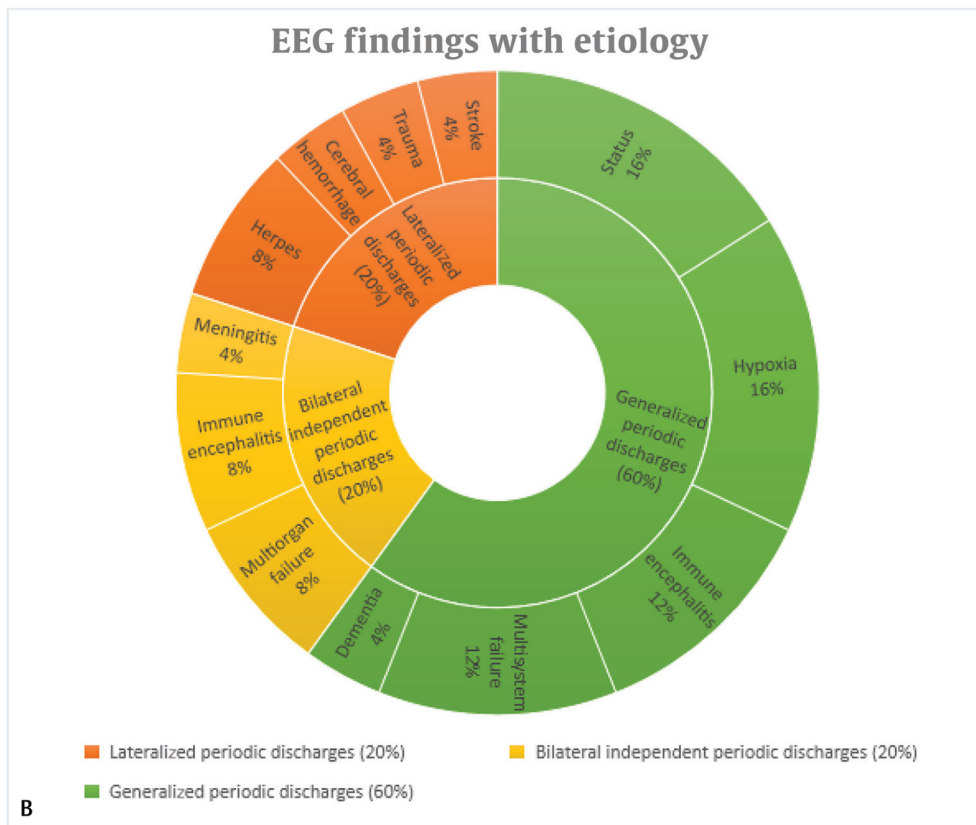
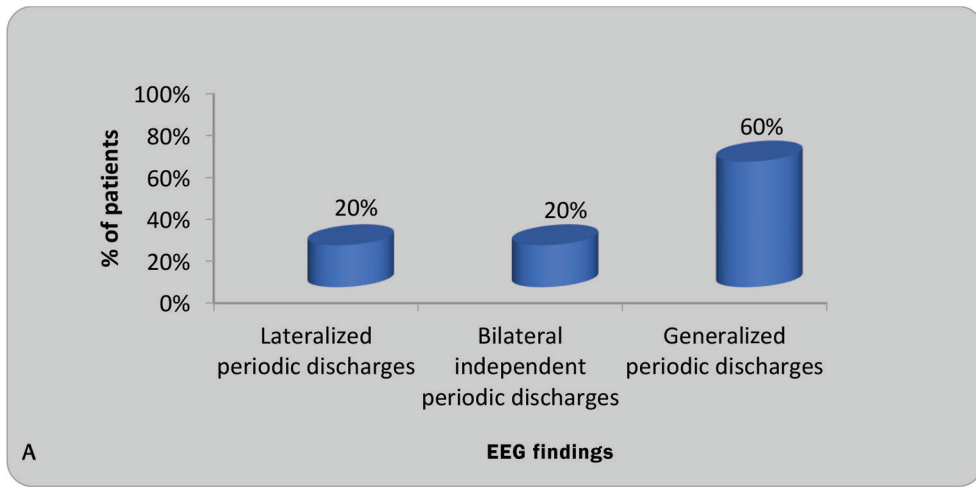


Fig. 3 (A) Electroencephalography (EEG) findings in the patients studied. (B) EEG findings with the underlying etiology.

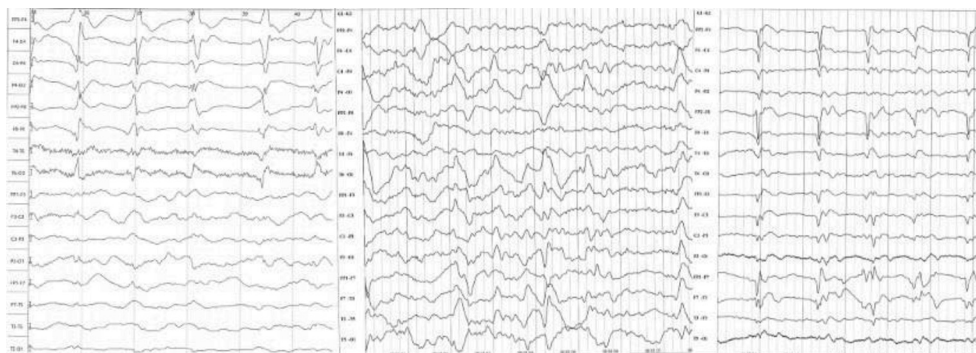


Fig. 4 Electroencephalography findings in (A) lateralized periodic discharges, (B) bilateral independent periodic discharges, and (C) generalized periodic discharges.

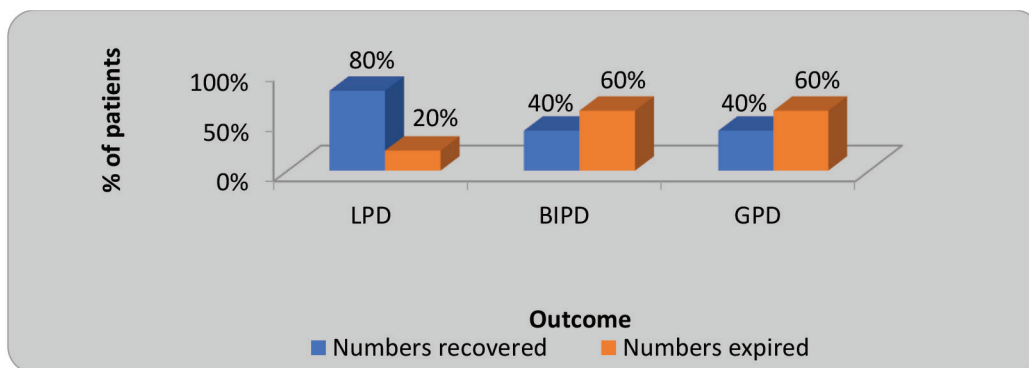


Fig. 5 The outcome with the mortality in percentage in the three groups of patients.

Table 1 Outcome of the three groups of patients

Total number of patients	Total—50	LPD—10	BIPD—10	GPD—30
Numbers recovered	28 (56%)	8 (80%)	4 (40%)	12 (40%)
Numbers expired	22 (44%)	2 (20%)	6 (60%)	18 (60%)
χ^2 -value		72 $p = 0.0001$, S	8.00 $p = 0.0047$, S	8.00 $p = 0.0047$, S

Abbreviations: BIPD, bilateral independent periodic discharges; GPD, generalized periodic discharges; LPD, lateralized periodic discharges.

networks.^{6,9} Kalamangalam and Slater postulated that periodic rhythms were generated by the synchronization of cortical macrocolumns that lead to increased connectivity across different spatial domains at intrinsic coupling frequencies.⁶ By a spectral condensation, several intrinsic cortical oscillators merged into one another and fired synchronously and periodically.⁶ Prolonged after-discharges caused the persistent firing of neurons for longer periods.⁶ At a critical coupling phase, there was increased synaptic connectivity, decreased inhibition, and the release of excitatory neurotransmitters between adjoining neurons leading to the propagation of periodic epileptiform discharges.^{6,9}

Periodic Discharges in Strokes

Acute ischemic strokes caused lateralized periodic discharges during the dynamic phase of the ischemic insult.^{7,8,10,11} Lateralized periodic discharges were the result of an external zone of hyperexcitability that led to synchronous and repetitive rhythms by the disruption of subcortical networks.⁷⁻¹⁰ Subcortical lesions damaged the underlying basal ganglia and the associated thalamocortical networks, resulting in reciprocal propagation of oscillations to widespread areas of the cerebral cortex.^{7,10} Acute ischemia resulted in neuronal injury and release of excitotoxic neurotransmitters such as glutamate, which triggered recurrent epileptiform discharges.⁷⁻¹⁰ Early onset seizures in cortical strokes increased the size of the infarct and the residual functional deficits.^{7,10,12} Hence, detection and treatment of seizures caused by lateralized periodic discharges in large cortical strokes could reduce the extent of neuronal damage and the post-stroke morbidity.^{7,10}

Intracerebral hemorrhages were complicated by seizures both in the acute phase and in the convalescent stage of

the illness.^{5,11} Early onset seizures in 3 to 40% cases were the result of structural and biochemical disruption of the neural networks.⁵ Late onset seizures that accounted for 2.3% to 31% cases were the result of scarring and gliosis of brain tissue.¹³ Claassen et al reviewed the continuous EEG records of 102 patients with intracerebral hemorrhage and recorded seizures in 31% cases.⁵ Periodic discharges were frequent in lobar intracerebral bleeds that were proximal to the cortex and were associated with a poor prognosis.⁵ We recorded lateralized periodic discharges in 4% cases of primary intracerebral hemorrhage.

Chronic Periodic Discharges

Chronic periodic discharges were the result of gliosis or a meningocerebral cicatrix that was caused by strokes.^{12,13} Alteration of membrane permeability, neuronal loss, and collateral sprouting contributed to hyperexcitability.¹³ Neuronal synchrony in the injured brain sustained periodic after-discharges in the damaged tissues.^{6,13} Embolic strokes contributed to periodic discharges more often than thrombotic strokes.¹² Téllez-Zenteno et al have reported a high incidence of chronic epilepsy and status epilepticus in cases of remote strokes and have emphasized on the use of antiepileptics in the treatment of seizures in patients with cortical strokes.^{2,12} Chronic periodic discharges were the result of unrecognized prolonged partial seizures in patients with underlying structural brain abnormalities.^{2,12} In our series of 50 hospitalized patients, there were 4% cases of post-stroke seizures who had lateralized periodic discharges in their EEG recordings.

Periodic Discharges in Viral Encephalitis

Herpes viral encephalitis is undoubtedly the commonest treatable cause of encephalitis in a busy neurology intensive

care unit with a reported incidence of one case per million per year.¹⁴ Early diagnosis and timely treatment reduced the neurological sequelae and hastened the functional recovery.^{14,15} Bedside EEG plays a pivotal role in the diagnosis of herpes viral encephalitis in the acute stage even before other test results are available.¹⁵ Lateralized periodic discharges were pathognomonic of acute herpes virus encephalitis in the critical care units.¹⁵ We recorded lateralized periodic discharges in 8% cases in this study.

Periodic Discharges in Autoimmune Encephalitis

In the present era of continuous bedside EEG monitoring and comprehensive medical care, autoimmune encephalitis and immune-mediated epilepsies have captured the limelight. With advanced diagnostic tests, one can diagnose these fascinating diseases that span all ages and have a varied presentation. In our case series, there were 20% cases of autoimmune encephalitis with EEG findings of bilateral independent periodic discharges and generalized periodic discharges. In N-methyl-D-aspartate encephalitis, a cytotoxic T cell-mediated injury of the affected neurons triggered immune-mediated neuronal damage with the release of excitatory neurotransmitters that increased the propensity for seizures.¹⁶ leucine-rich glioma inactivated 1 (LG1) antibody-mediated encephalitis presented in the elderly with hyponatremia, faciobrachial dystonic seizures, or generalized seizures.⁹ Autoantibodies directed against cell surface neuronal receptors or synaptic proteins contributed to receptor internalization, redistribution of synaptic transmission, and interference with ligand receptor interaction.⁹ In LG1 antibody encephalitis, the resulting neuronal damage manifested with a variety of seizure patterns including faciobrachial dystonic seizures, automatism, vocalizations, eye blinking, and dystonic posturing.^{9,17}

Periodic Discharges in Posthypoxic Coma

Posthypoxic brain damage after cardiac arrest is often encountered in the critical care units. With the advances in modern technology, the outcome of hypoxic brain insult has improved resulting in a better outcome. Multimodality monitoring with a multidisciplinary approach in comatose patients led to the early detection of hypoxic brain injury and the use of appropriate therapeutic strategies to prevent permanent brain damage.¹⁸ Continuous bedside EEG monitoring proved a valuable tool in the detection and follow-up of an electrographic status or a nonconvulsive status epilepticus.^{18,19} Immediate treatment with antiepileptics decreased the extent of neuronal damage, reduced the frequency of seizures, and prevented the development of pharmacoresistance.^{18,19} In our study, 16% patients underwent cardiopulmonary resuscitation following cardiac arrest. Cerebral hypoxia was associated with evolving generalized periodic discharges and a nonconvulsive status epilepticus.^{18,19} Nonconvulsive status epilepticus contributed to progressive neuronal injury, cerebral ischemia, and irreversible neuronal damage.^{18,19} This cycle of inevitable consequences was enhanced by a glutamate mediated excitotoxicity that resulted in the production of

generalized periodic discharges.⁹ Metabolic derangements resulted in microstructural changes, stimulation of post-synaptic receptors, impaired clearance of neurotransmitters, endothelial, and microglial activation.^{18,19} During an electrical status epilepticus, there was increased energy consumption by the hyperactive neurons resulting in a loss of neuronal integrity.¹⁸⁻²⁰ Thus, cerebral hypoxia increased the metabolic demands in a compromised brain leading to neuronal exhaustion, synaptic failure, and irreversible brain death.^{18,19} Bedside EEG monitoring was indispensable in the early detection of hypoxic encephalopathy and helped in monitoring the effect of therapy on the patient.

Periodic Discharges in Status Epilepticus

We detected electrographic status epilepticus in 16% critically ill patients admitted to the intensive care unit. Electrographic seizures and generalized periodic discharges were seen in cases of posthypoxic encephalopathy, status epilepticus, in multisystem failure, autoimmune encephalitis, and in end-stage dementia. Krish and Bazil in 2017 stressed the importance of early detection of subclinical seizures in the intensive care unit.²¹ Electrographic seizures could lead to a steady neurological decline and an increase in seizure burden.^{21,22} Prolonged nonconvulsive seizures could be an epiphenomenon of an underlying serious brain injury that progressed to neurological deterioration and irreversible brain damage.^{21,22} Li et al proved that periodic discharges were related to clinical seizures in 67% cases.²² Electrographic seizures were associated with unfavorable functional outcomes and worsening of the underlying neurological condition.²² Bilateral independent periodic discharges evolving to generalized periodic discharges were treated with first-line antiepileptics as there was a strong correlation with status epilepticus.^{21,22} Long-term outcome of periodic discharges depended on the neurological diagnosis, comorbidities, and the age of the patients.^{22,23} Uncontrolled seizures in comatose patients lead to metabolic derangements, cerebral ischemia, and progressive neurological decline.^{23,24} San-Juan et al emphasized on the poor prognosis of bilateral independent periodic discharges and generalized periodic discharges in patients with multifocal and diffuse cerebral injuries.²⁴

There have been similar case studies in patients with periodic discharges. Van Putten and Hofmeijer attributed selective synaptic failure and a disturbed excitation of inhibitory neurons as contributory factors to neuronal injury and a poor clinical outcome. Kate et al considered periodic discharges to be a surrogate marker of a high morbidity and mortality. San-Juan et al postulated that periodic discharges could be an age-related phenomenon with a high mortality in the acute phase of a neurological illness.²⁴

We recorded a high mortality in cases of bilateral independent and generalized periodic discharges. Our observations were in concordance with similar studies conducted by Fitzpatrick and Lowry who recorded a mortality of 27% with lateralized periodic discharges and 52% with bilateral independent and generalized periodic discharges.²⁵

Conclusion

In conclusion, continuous EEG monitoring in the intensive care unit is a vital tool for the early detection of periodic discharges. The mortality is high in patients with bilateral independent periodic discharges and generalized periodic discharges as these rhythms are associated with extensive cerebral dysfunction and a poor prognosis for survival.

Timely diagnosis and immediate treatment improved the clinical outcome and reduced the morbidity and mortality. Untreated, these rhythms could evolve further with a propensity to transform to a nonconvulsive status epilepticus. Antiepileptics are used in the treatment of evolving periodic discharges and in patients who present with seizures or status epilepticus. However, the routine use of antiepileptics in all cases is not advised as periodic rhythms could be a transient cerebral response to an acute neuronal injury caused by either inflammation or infection that subside on recovery.

Acknowledgments

We wish to acknowledge the help and support of our colleagues and the paramedical technicians without whom this article would have been impossible. We also wish to thank the Hospital management and the Senior Consultant of Neurophysiology for their constant guidance and support.

Conflict of Interest

None declared.

References

- 1 Chatrjian GE, Shaw CM, Leffman H. The significance of periodic lateralised epileptiform discharges in the EEG: an electrographic, clinical and pathologic study. *Electroencephalogr Clin Neurophysiol* 1964;17:177–193
- 2 Andraus ME, Andraus CF, Alves-Leon SV. Periodic EEG patterns: importance of their recognition and clinical significance. *Arq Neuropsiquiatr* 2012;70(2):145–151
- 3 Johnson EL, Kaplan PW. Population of the ictal-interictal zone: the significance of periodic and rhythmic activity. *Clin Neurophysiol Pract* 2017;2:107–118
- 4 Reiher J, Rivest J, Grand'Maison F, Leduc CP. Periodic lateralized epileptiform discharges with transitional rhythmic discharges: association with seizures. *Electroencephalogr Clin Neurophysiol* 1991;78(1):12–17
- 5 Claassen J, Jetté N, Chum F, et al. Electrographic seizures and periodic discharges after intracerebral hemorrhage. *Neurology* 2007;69(13):1356–1365
- 6 Kalamangalam GP, Slater JD. Periodic lateralized epileptiform discharges and afterdischarges: common dynamic mechanisms. *J Clin Neurophysiol* 2015;32(4):331–340
- 7 Kim BS, Sila C. Seizures in ischemic stroke. In: *Seizures in Cerebrovascular Disorders. A clinical guide.* New York, NY: Springer; 2015:17–29

- 8 Rodriguez Ruiz A, Vlachy J, Lee JW, et al; Critical Care EEG Monitoring Research Consortium. Association of periodic and rhythmic electroencephalographic patterns with seizures in critically ill patients. *JAMA Neurol* 2017;74(2):181–188
- 9 Aurangzeb S, Symmonds M, Knight RK, Kennett R, Wehner T, Irani SR. LGI1-antibody encephalitis is characterised by frequent, multifocal clinical and subclinical seizures. *Seizure* 2017;50:14–17
- 10 Camilo O, Goldstein LB. Seizures and epilepsy after ischemic stroke. *Stroke* 2004;35(7):1769–1775
- 11 Cruz-Flores S, Alshekhlee A. Seizures in intracerebral haemorrhage. In: M. Z. Koubeissi et al. eds. *Seizures in Cerebrovascular Disorders. A clinical guide.* New York: Springer; 2015: 31–40
- 12 Téllez-Zenteno JF, Pillai SN, Hill MD, Pillay N. Chronic PLEDs with transitional rhythmic discharges (PLEDs-plus) in remote stroke. *Epileptic Disord* 2007;9(2):164–169
- 13 Kate MP, Dash GK, Radhakrishnan A. Long-term outcome and prognosis of patients with emergent periodic lateralized epileptiform discharges (ePLEDs). *Seizure* 2012;21(6):450–456
- 14 Kennedy PGE. Viral encephalitis: causes, differential diagnosis, and management. *J Neurol Neurosurg Psychiatry* 2004;75(Suppl 1):i10–i15
- 15 Lai CW, Gragasin ME. Electroencephalography in herpes simplex encephalitis. *J Clin Neurophysiol* 1988;5(1):87–103
- 16 Sakakibara E, Takahashi Y, Murata Y, Taniguchi G, Sone D, Watanabe M. Chronic periodic lateralised epileptic discharges and anti-N-methyl-D-aspartate receptor antibodies. *Epileptic Disord* 2014;16(2):218–222
- 17 Lancaster E. The diagnosis and treatment of autoimmune encephalitis. *J Clin Neurol* 2016;12(1):1–13
- 18 van Putten MJ, Hofmeijer J. Generalised periodic discharges: pathophysiology and clinical considerations. *Epilepsy Behav* 2015;49:228–233
- 19 Sakellariou DF, Kostopoulos GK, Richardson MP, Koutroumanidis M. Topography of generalized periodic epileptiform discharges in postanoxic nonconvulsive status epilepticus. *Epilepsia Open* 2017;2(4):472–475
- 20 Witsch J, Frey HP, Schmidt JM, et al. Electroencephalographic periodic discharges and frequency-dependent brain tissue hypoxia in acute brain injury. *JAMA Neurol* 2017;74(3):301–309
- 21 Krish S, Bazil CW. Interpreting periodic and rhythmic electroencephalographic patterns in critically ill patients. *JAMA Neurol* 2017;74(2):150–151
- 22 Li HT, Wu T, Lin WR, et al. Clinical correlation and prognostic implication of periodic EEG patterns: a cohort study. *Epilepsy Res* 2017;131(March):44–50
- 23 Chong DJ, Hirsch LJ. Which EEG patterns warrant treatment in the critically ill? Reviewing the evidence for treatment of periodic epileptiform discharges and related patterns. *J Clin Neurophysiol* 2005;22(2):79–91
- 24 San-Juan OD, Chiappa KH, Costello DJ, Cole AJ. Periodic epileptiform discharges in hypoxic encephalopathy: BiPLEDs and GPEDs as a poor prognosis for survival. *Seizure* 2009;18(5):365–368
- 25 Fitzpatrick W, Lowry N. PLEDs: clinical correlates. *Can J Neurol Sci* 2007;34(4):443–450