

# Cephalometric and Pharyngometric Evaluation in Snoring Children with Sleep-Disordered Breathing and Adenotonsillar Hypertrophy Under an Orthodontic or Orthopedic Treatment

Walter Ribeiro Nunes Jr<sup>1</sup> David Gozal<sup>2</sup> Renata C. Di Francesco<sup>3</sup>

<sup>1</sup>Department of Otolaryngology, Universidade de São Paulo Faculdade de Medicina, São Paulo, Brazil

<sup>2</sup>Department of Child Health, School of Medicine, University of Missouri, Columbia, Missouri, United States

<sup>3</sup>Department of Pediatric Otolaryngology, Faculdade de Medicina da Universidade de São Paulo, Hospital das Clínicas, São Paulo, Brazil

Address for correspondence Walter Ribeiro Nunes Jr, DDS, MS, PhD, Department of Otolaryngology, Universidade de São Paulo Faculdade de Medicina, Av Angelica 1260, B 12, CEP 01228-100, Sao Paulo, SP, BRAZIL (e-mail: walternj@gmail.com).

J Child Sci 2019;9:e68–e74.

## Abstract

Altered craniofacial growth has been implicated in sleep-disordered breathing (SDB) in children. The authors aimed to evaluate the cephalometric measurements and pharyngeal dimensions related to SDB in snoring children with adenotonsillar hypertrophy (ATH) treated with an orthodontic and orthopedic oral appliance (OOA). Forty habitually snoring children, 6 to 9 years old with evidence of grade 3 to 4 ATH, maxillary constriction, and class II dental malocclusion were enrolled, with 24 children being treated with OOA, and 16 remaining untreated children as controls. All children underwent a cephalometric X-ray and acoustic pharyngometry for airway measurements at the start and 6 months after. Cephalometric measurements related to SDB reduced in the treated group ( $p < 0.01$ ) as follows: maxillary–mandibular relationship:  $-2.2 \pm 1.70^\circ$ ; maxillary–mandibular planes angle:  $-2.4 \pm 3.80^\circ$ ; and hyoid bone position:  $-4 \pm 3.8$  mm ( $p < 0.001$ ). OOA treatment revealed improvements in pharyngeal minimum cross-section area (MCA) ( $0.2 \pm 0.2$  cm<sup>2</sup>) and volume (V) ( $3.15 \pm 2.5$  cm<sup>3</sup>), while reductions in MCA ( $-0.2 \pm 0.3$  cm<sup>2</sup>) and in V ( $-1.25 \pm 1.3$  cm<sup>3</sup>) occurred in controls ( $p < 0.001$  vs. OOA). Six months of OOA treatment in snoring children with SDB promotes enlargement of the pharyngeal dimensions and beneficial cephalometric changes.

## Keywords


- ▶ child
- ▶ maxillofacial development
- ▶ orthodontics
- ▶ snoring
- ▶ tonsil


## Introduction


Adenotonsillar hypertrophy (ATH) and altered maxillofacial morphology are strongly associated with increased risk for developing sleep-disordered breathing (SDB) in children,<sup>1–3</sup>

with physiologic alterations, such as intermittent hypoxia and sleep fragmentation, that may result in a wide array of morbid consequences, including neurocognitive and behavioral deficits,<sup>4</sup> nocturnal enuresis, and cardiovascular and metabolic complications.<sup>5</sup>

The treatment of choice for SDB in children has traditionally consisted of surgical removal of the tonsils and adenoids (T&A).<sup>5</sup> However, previous studies have shown that among children who underwent T&A, a substantial proportion failed to display complete resolution of their respiratory disturbances

 Walter Nunes Jr's ORCID is <https://orcid.org/0000-0002-6575-7579>.

 David Gozal's ORCID is <https://orcid.org/0000-0001-8195-6036>.

 Renata Di Francesco's ORCID is <https://orcid.org/0000-0002-6375-6978>.

received  
January 11, 2019  
accepted after revision  
May 19, 2019

DOI <https://doi.org/10.1055/s-0039-1692987>.  
ISSN 2474-5871.

Copyright © 2019 Georg Thieme Verlag  
KG Stuttgart · New York



during sleep after surgery.<sup>5</sup> Maxillofacial disharmony can also be a significant predisposing factor in the development and progression of pediatric SDB.<sup>5</sup> Similarly, measurements of the cross-sectional area of the oropharynx can be useful in screening for SDB in both adult<sup>6</sup> and pediatric populations.<sup>7,8</sup> Cephalometric values commonly used in the evaluation of symptomatic patients include maxillary–mandibular planes angle (MMPA), maxilla–mandibular relationship (ANB), and hyoid bone position (H-ML).<sup>9–11</sup> Löfstrand-Tiderström and Hultcrantz<sup>12</sup> observed a reduction in the mandibular angle in 6-year-old children who underwent T&A without dental arch narrowing correction. In another study, the same authors<sup>13</sup> suggested that orthodontic intervention was required because there were no changes in maxillofacial development post-T&A.

Orthodontic and maxillofacial abnormalities related to pediatric obstructive sleep apnea syndrome are commonly left unattended even though they have a potential harmful impact on health.<sup>14</sup> Rapid maxillary expansion has been reported to achieve improvements in respiratory function, even during sleep, and functional appliances have recently been applied in children with SDB with favorable outcomes.<sup>15–18</sup> Myofunctional exercises are also recommended as complementary interventions.<sup>19</sup> However, the effect of an orthodontic and functional orthopedic oral appliance (OOA) treatment in habitually snoring children with ATH on airway growth has not been systematically examined.

The aim of this study was to evaluate the changes in pharyngeal dimensions and cephalometric measurements related to SDB in snoring children with ATH, and narrow maxillary arch before and 6 months after OOA treatment, and compare with those occurring in similar children matched for ATH and maxillofacial morphology, who did not undergo OOA treatment.

## Methods

The Ethics Committee approved the research protocol at the Hospital das Clínicas da Faculdade de Medicina da University of São Paulo (HC-FMUSP), and all legal caretakers provided signed informed consent. Forty children aged 6 to 9 years old who presented with a history of chronic snoring and mouth breathing due to tonsil and adenoid hypertrophy, and who were placed on the waiting list for T&A in the Department of Otolaryngology of the USP Medical School from 2008 to 2011 were included. We should emphasize that the mean waiting period for T&A at HC-FMUSP or anywhere else in the public health service in São Paulo is approximately 12 months. The trial design was parallel paired and randomized with an allocation ratio of 3:2. The sample size was determined according to convenience due to the strict inclusion criteria and considering previous publications with similar results.<sup>16,20</sup>

Eligibility criteria included: enlarged tonsil grades 3 or 4 according to the Brodsky grading scale,<sup>21</sup> obstructive adenoids (> 50%) as per lateral radiographic film,<sup>22</sup> constricted maxilla, class II malocclusion, and sleep disturbances including habitual snoring and witnessed apneas reported by parents and caregivers.<sup>23</sup> Exclusion criteria were previous orthodontic treatment, neurological diseases, or genetic syndromes.

Patients were randomly allocated to one of the groups (OOA:  $n = 24$  or Controls:  $n = 16$ ). The number of patients included initially in the study group was higher than the a priori cohort size estimates, and aimed to account for patients who may fail to complete the study.

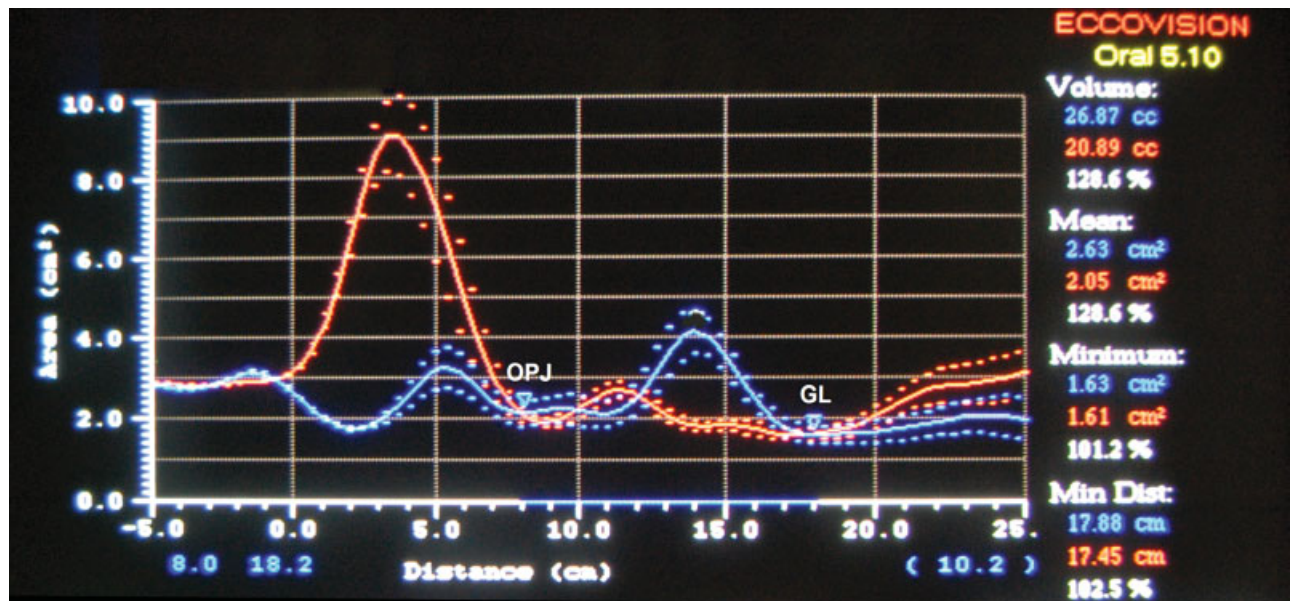
**Otolaryngology evaluation:** Otolaryngology evaluation included physical examination, pediatric sleep questionnaire (PSQ), fiberoptic nasopharyngoscopy, and lateral head radiograph. All subjects included in the study underwent a polysomnographic (PSG) diagnostic assessment that showed the presence of an obstructive apnea index > 1/hour total sleep time (TST) or an obstructive apnea–hypopnea index > 2/hour TST. These sleep disturbances are detrimental to children's health and development as described in the introduction.

**Acoustic pharyngometry:** Subjects seated in an upright position on a straight-back chair breathed through an acoustic pharyngometer (Sleep Group Solutions; Miami, Florida, United States). Subjects were instructed to pause the breathing at end-exhalation for acoustic measurement of upper airway minimal cross-sectional area (MCA). The MCA was measured between the oropharyngeal junction (OPJ) up to but excluding the glottis (GL). The total volume of the pharyngeal space (V) was also determined.<sup>6–8</sup> Parameters were calculated by the computer system that outputs the measurements of the oropharynx in between OPJ and GL: volume, mean area, MCA, and distance of MCA from incisor teeth contact. All patients from the treatment group had an extra register with the OOA appliance installed in the mouth. ▶ **Fig. 1** shows a representative output of the acoustic pharyngogram of one child from the treatment group overlapping the two pharyngograms and measurements registered at the start: in red color without the OOA in the mouth and blue color with the OOA installed.

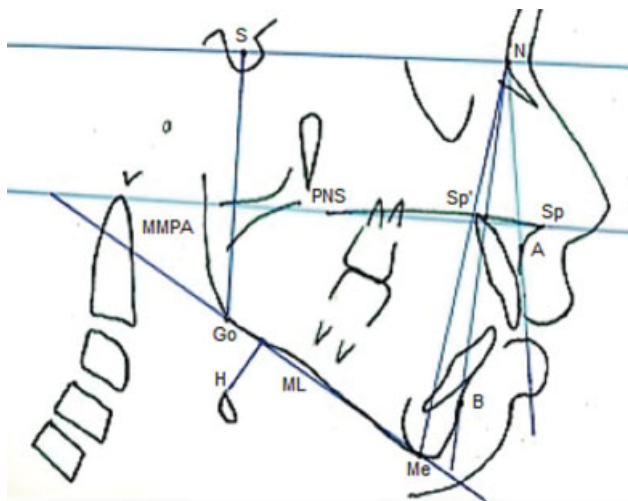
**Dental examination:** Maxillary arch constriction was defined by the presence of two or more maxillary posterior teeth in an edge-to-edge cuspal relationship with their antagonists or crossbite and based on the Korkhaus index for maxillary arch constriction.<sup>24</sup> Class II malocclusion was present when the inferior molar was positioned posterior to the upper molar cuspid reference.<sup>25</sup>

**Cephalometric evaluation:** All assessments were performed by the same operator who was blinded to the study in the Department of Radiology of HC-FMUSP. Lateral head X-rays were taken on a cephalostat in natural head position. A cephalometric evaluation was used to assess growth direction on values related to sleep apnea<sup>9–11</sup> by comparing the measurements (▶ **Fig. 2**).

**Oral appliance:** The appliance is designed to bring about orthopedic, functional, and orthodontic changes. It consisted of an acrylic palatal body with a tongue-guide hole at the papilla, a screw for active maxillary expansion, and a Hawley's vestibular arch with the possibility of orthodontic activation at the canine region for reducing incisors inclination when needed together with slowly removing the acrylic from behind the incisors at each appliance expansion screw activation. Retention clasps with connection tubes were attached to the upper molars. A removable lip bumper was connected to the molar clasps and placed between the lower



**Fig. 1** Representative output of acoustic pharyngogram before and after placement of the oral appliance.



**Fig. 2** Schematic of cephalometric measurements performed in the participants. SNA, anteroposterior position of the maxilla in relation to the anterior cranial base (the angle between the lines S-N and N-A). SNB, anteroposterior position of the mandible in relation to the anterior cranial base (the angle between the lines S-N and N-B). ANB, anteroposterior position of the mandible in relation to the maxilla (the angle between the lines A-N and N-B). MMPA, angle of the palatal line (anterior nasal spine [ANS] to posterior nasal spine [PNS]) with the mandibular line (Me-Go). S-Go/N-Me, total facial index (distance from S to Go divided by distance from N to Me). H-ML, hyoid bone position related to the mandibular line (length in mm). S-Go, distance from S to gonion (in mm).

lip and the lower anterior teeth to promote proper lip contact. On installation, a bite guide was molded with acrylic behind the upper incisors to place the lower incisors in a more anterior contact with the upper incisors favoring the advancement of the mandible to class I constructive bite. This bite guide was opened in the middle with a fine cutting disc to not interfere on maxillary expansion. Participants wore their appliances for a minimum of 4 hours during the day and

approximately 8 to 12 hours at night. Patients were instructed to maintain contact between the tongue and the hard palate inside the tongue-guide hole of the appliance always, even on opening the mouth and during swallowing. The expansion screw was activated with three-fourths turns (0.75 mm.) every 3 weeks. A total of 8 activations were completed during the 6-month study period, resulting in a total expansion between the upper first molars of approximately 6 mm.

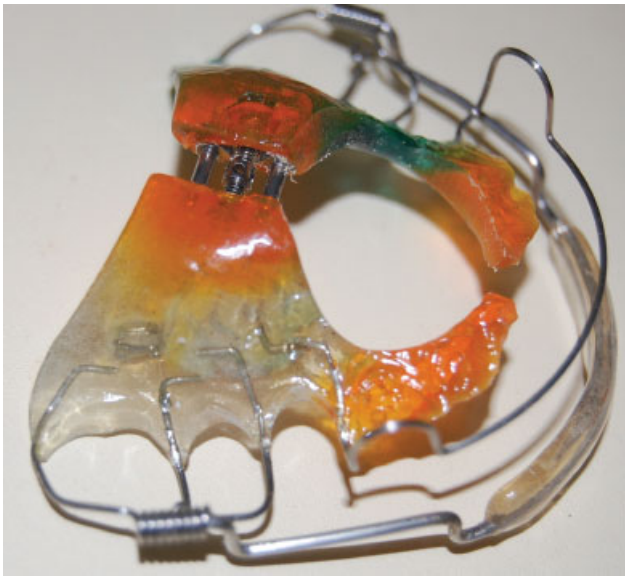The main goals of the appliance were maxilla transverse expansion combined with upper and anterior tongue repositioning and lip sealing. There was not one standard amount of bite opening and advancement, and the constructive bite was built for each patient bringing the lower incisors in close touch with the upper incisors. The hole at the papilla acted as a reminder for tongue positioning training, and the lower vestibular shield was used to help proper lip sealing supporting lower lip advancement. ▶ **Fig. 3** shows an example of the oral appliance Bioajusta X.

After 6 months, both groups underwent otorhinolaryngologic and dental exams, pharyngometry, and cephalometric evaluation.

**Data analysis:** Using statistical software (SPSS 15.0; Chicago, Illinois, United States), normality of data distribution was measured with the Kolmogorov–Smirnov test. Differences in mean and standard deviation for pharyngometric measurements between groups were compared using Student's unpaired *t*-tests. For the cephalometric values, analysis of variance (ANOVA) (repeated measures ANOVA test) was used to verify differences between groups and time points. Statistical significance was assumed at a two-tailed *p*-value of < 0.05.

## Results

A total of 114 children were assessed for eligibility from 2008 to 2011, and 74 were excluded for not meeting the inclusion



**Fig. 3** Example of the BioAjustax oral appliance used in the orthodontic and orthopedic appliance (OOA) treatment.

criteria. All eligible candidates who consented had normal body mass index (none were obese neither underweight), which remained stable during the study period. The 40 participants were followed during the study period, with no participants dropping out. The mean age was  $7.6 \pm 0.8$  years old for the treated group and  $7.5 \pm 0.9$  years old in the controls ( $p$ -value  $> 0.05$ ). The gender distribution between both groups was identical. Dental occlusions were considered as being improved in all the children treated, and no complaints of side effects were registered. The treated group achieved better improvements in respiratory symptoms as corroborated by the PSQ (**Table 1**), while none of the participants or their caregivers from the control group reported any improvements.

**Table 1** Respiratory symptoms from PSQ at the treated group

Symptoms	T1		T2		p-Value
	N	%	N	%	
Snoring					< 0.001
Always	15	62.5	0	0.0	
Frequent	8	33.3	0	0.0	
Occasional	1	4.2	6	25.0	
Rare	0	0.0	18	75.0	
Mouth breathing					< 0.001
Always	9	37.5	0	0.0	
Frequent	14	58.3	1	4.2	
Occasional	1	4.2	4	16.7	
Rare	0	0.0	19	79.2	
Total	24	100	24	100	

Abbreviation: PSQ, pediatric sleep questionnaire.  
Note: Wilcoxon test.

Pharyngometry-related findings are shown in **Table 2**. Significant improvements in airway volume (V) and MCA in the treated group emerged, while significant reductions in both MCA and V occurred in the controls ( $p < 0.001$ ). Fiberoptic nasopharyngoscopy confirmed the results measured by pharyngometry.

An illustrative example of lateral X-ray changes in airway caliber of a same child treated in 6 months comparison is shown in **Fig. 4**.

Cephalometric measurements related to sleep apnea on comparison between groups and time points (**Table 3**), showed reductions in anteroposterior position of maxilla (SNA) and increases in anteroposterior position of mandible (SNB) from T1 to T2 for the treatment group, which resulted in a significant decrease in ANB ( $p < 0.001$ ). The mean values for MMPA and H-ML increased from T1 to T2 in the control group ( $p < 0.001$ ), while the same measurements decreased in the treatment group ( $p < 0.001$ ).

Most children underwent surgery after the study as severe tonsils hypertrophy may interfere with orthodontic treatment stability. As mentioned earlier, public hospitals in São Paulo such as HC-FMUSP had a waiting time of approximately 12 months for adenotonsillectomy surgery at the time of the study. All children that performed the PSG after OOA treatment and surgery showed marked improvement.

## Discussion

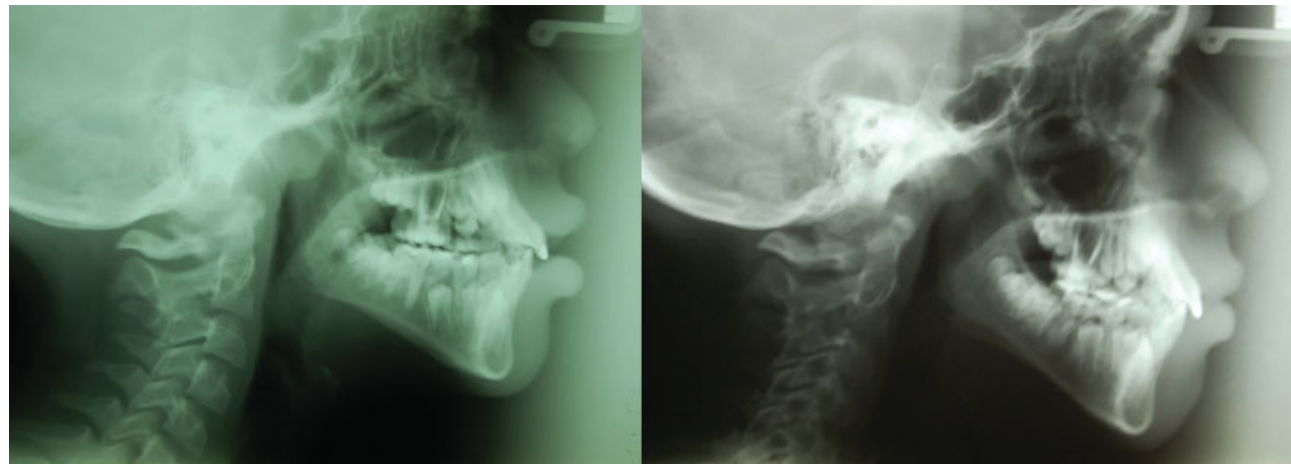
In children as well as in adults, an elongated face and a steeper mandibular plane are associated with smaller pharyngeal dimensions, which established early in life may predispose to higher SDB risk in later years.<sup>14</sup> Maxillary constriction also plays a role in the development of obstructive sleep apnea.<sup>1,10,11</sup> Remodeling of the maxillofacial structure can be achieved by the expansion of the maxillary arch, associated with the functional training with the OOA treatment may help to correct the tongue position, swallowing, and lip sealing, resulting in the rehabilitation of normal nasal function.<sup>20,26–28</sup> The distance between gonion and point S, and the total facial index (S-Go/N-Me) increased more in the treatment group. This outcome is possibly related to the normalization of pharyngeal dynamics and the favorable breathing pattern achieved in the treatment group with consequences for mandibular growth, probably by normalizing growth hormone status, similar to the growth redirection observed after surgery.<sup>2</sup> This could be related to a more intense bone formation at the mandibular ramus, reflecting an increase in the total facial index (S-Go/N-Me), thus helping normalize the ANB as indicated by the current results.

Acoustic pharyngometry is a potentially useful tool which enables longitudinal assessments of the changes in airway dimensions.<sup>29</sup> The MCA can be a valuable measurement for evaluating SDB risk factor in preadolescent children.<sup>7,8</sup> Both the MCA and the volume of the airway improved in the treatment group and decreased in the control group at the end of the study period. The pharyngograms shown in **Fig. 1**, comparing the patient with and without the

**Table 2** Acoustic pharyngometry measurements

Acoustic pharyngometry				
	T1	T2	Difference T2 – T1	p-Value
MCA (cm <sup>2</sup> ) OOA	1.14 ± 0.2	1.29 ± 0.2	+0.15 ± 0.2	< 0.001
MCA (cm <sup>2</sup> ) controls	1.46 ± 0.3	1.32 ± 0.3	-0.14 ± 0.2	< 0.001
Volume (cc) OOA	20.09 ± 2.8	23.24 ± 4.23	+3.15 ± 2.6	< 0.001
Volume (cc) controls	19.40 ± 2.5	18.02 ± 2.3	-1.25 ± 1.3	< 0.001

Abbreviations: MCA, minimum cross-section area; OOA, orthopedic oral appliance; SD, standard deviation.  
Note: Student's unpaired *t*-test (mean ± SD).



Lateral X-ray child at T1 beginning

Lateral X-ray same child at T2 ( after 6 months)

**Fig. 4** Example of changes in airway caliber after 6 months of orthopedic oral appliance (OOA) treatment in one child.**Table 3** Cephalometric assessments

Cephalometric measurements	Controls (N = 16)		OA treatment (N = 24)		p-Value
	T1	T2	T1	T2	
SNA	85.0 ± 3.2	85.5 ± 3.1	84.2 ± 3.1	83.1 ± 2.8	< 0.001
SNB	78.4 ± 2.7	78.3 ± 2.7	77.1 ± 2.9	78.3 ± 2.8	< 0.001
ANB	6.6 ± 1.6	7.1 ± 1.7	7.1 ± 1.8	4.9 ± 1.6	< 0.001
S-Go/N-Me	64.0 ± 3.1	63.9 ± 3.2	64.5 ± 3.1	66.2 ± 3.2	0.008
MMPA	28.3 ± 2.9	30.4 ± 2.8	31.3 ± 3.8	28.9 ± 3.8	< 0.001
H-ML	9.4 ± 4.1	10.7 ± 4.8	10.5 ± 3.0	6.5 ± 3.0	< 0.001
S-Go	69.1 ± 3.2	69.7 ± 3.2	69.8 ± 4.5	71.7 ± 4.5	< 0.001
ANOVA test (mean ± SD)					< 0.05

Abbreviations: ANB, maxilla–mandibular relationship; ANOVA, analysis of variance; H-ML, hyoid bone position; MMPA, maxillary–mandibular planes angle; SD, standard deviation; SNA, anteroposterior position of maxilla; SNB, anteroposterior position of mandible.

OOA in the mouth at the start, may help to visualize the modification on pharyngeal dynamics with the tongue repositioning. The modification obtained on oropharyngeal size and shape registered on the installation of the OOA, possibly contributed against its collapsibility during the treatment time, which may explain the improvements noted in the symptoms questionnaire of the treated patients answered by the parents/caregivers.<sup>30</sup>

The current findings concur with a previous similar study by Jena et al.<sup>31</sup> The anterior displacement of the tongue that was made possible by the maxillary expansion and the appliance tongue guide, influenced the position of the hyoid bone and consequently improved the morphology of the upper airways.<sup>6,20,31</sup> An upper and anterior position of the tongue may favor an improved airway growth.<sup>20</sup> Adequate breathing requires proper tongue positioning and lip contact.<sup>28</sup>

The positive impact of the OOA therapy on airway dimension despite concurrent ATH cannot be explained simply by skeletal changes, and we postulate that differences in the posture of the tongue caused by increased genioglossus muscle tone or soft tissue changes may have also contributed to forward positioning of the mandible during treatment.<sup>14,20,32</sup>

We could objectively demonstrate the morphological changes, and the results achieved can be related to the improvement of pharyngeal dynamics reflecting on a better breathing and sleep pattern.

Some limitations should be mentioned in this study: First, the number of subjects was relatively small (even though similar to previous similar publications),<sup>16,20</sup> and the follow-up period was relatively short, and dictated by the waiting times for T&A. Second, we did not conduct any comparisons with other treatment modalities, although previous publications show that at the 6 to 9 years old range surgery alone does not correct the dentofacial alterations.<sup>13–16,18,19,32,33</sup> Third, and perhaps most importantly, we do not know whether OOA treatment followed by T&A will result in better outcomes than T&A alone or T&A followed by OOA therapy. Other limitations are some missed polysomnography and nasoendoscopy data, and no drug-induced sleep endoscopy study to precisely detect the level of obstruction. These questions will have to await future studies that are clearly beyond the scope of the present trial. Since the control group presented worsening of the craniofacial characteristics and pharyngeal measurements, the possibility of enlarging pharyngeal dimensions at an early age together with normalized growth of the craniofacial skeleton should be viewed as a favorable approach in preventing sleep apnea later in life, an issue that will have to await longitudinal assessments.<sup>34</sup>

None of the children had temporomandibular joint or muscle pain that may happen in adults with mandibular advancement, since on children under orthopedic treatment constructive bite is common and well tolerated.

## Conclusion

Six months of OOA treatment in snoring children with SDB promotes enlargement of the pharyngeal dimensions and beneficial cephalometric changes.

**Conflict of Interest**  
None declared.

## References

- Katyal V, Pamula Y, Martin AJ, Daynes CN, Kennedy JD, Sampson WJ. Craniofacial and upper airway morphology in pediatric sleep-disordered breathing: systematic review and meta-analysis. *Am J Orthod Dentofacial Orthop* 2013;143(01):20–30.e3
- Peltomäki T. The effect of mode of breathing on craniofacial growth—revisited. *Eur J Orthod* 2007;29(05):426–429
- Nunes WR Jr, Di Francesco RC. Variation of patterns of malocclusion by site of pharyngeal obstruction in children. *Arch Otolaryngol Head Neck Surg* 2010;136(11):1116–1120
- Hunter SJ, Gozal D, Smith DL, Philby MF, Kaylegian J, Kheirandish-Gozal L. Effect of sleep-disordered breathing severity on cognitive performance measures in a large community cohort of young school-aged children. *Am J Respir Crit Care Med* 2016;194(06):739–747
- Marcus CL, Moore RH, Rosen CL, et al; Childhood Adenotonsillectomy Trial (CHAT). A randomized trial of adenotonsillectomy for childhood sleep apnea. *N Engl J Med* 2013;368(25):2366–2376
- Deyoung PN, Bakker JP, Sands SA, et al. Acoustic pharyngometry measurement of minimal cross-sectional airway area is a significant independent predictor of moderate-to-severe obstructive sleep apnea. *J Clin Sleep Med* 2013;9(11):1161–1164
- Monahan KJ, Larkin EK, Rosen CL, Graham G, Redline S. Utility of noninvasive pharyngometry in epidemiologic studies of childhood sleep-disordered breathing. *Am J Respir Crit Care Med* 2002;165(11):1499–1503
- Gozal D, Burnside MM. Increased upper airway collapsibility in children with obstructive sleep apnea during wakefulness. *Am J Respir Crit Care Med* 2004;169(02):163–167
- Bates C, Mc Donald J. The relationship between severity of OSAHS and lateral cephalometric radiograph values: a clinical diagnostic tool. *Surgeon* 2005;3:338–346
- Pirilä-Parkkinen K, Löppönen H, Nieminen P, Tolonen U, Pirtti-niemi P. Cephalometric evaluation of children with nocturnal sleep-disordered breathing. *Eur J Orthod* 2010;32(06):662–671
- Marino A, Ranieri R, Chiarotti F, Villa MP, Malagola C. Rapid maxillary expansion in children with obstructive sleep apnoea syndrome (OSAS). *Eur J Paediatr Dent* 2012;13(01):57–63
- Löfstrand-Tideström B, Hultcrantz E. The development of snoring and sleep related breathing distress from 4 to 6 years in a cohort of Swedish children. *Int J Pediatr Otorhinolaryngol* 2007;71(07):1025–1033
- Löfstrand-Tideström B, Hultcrantz E. Development of craniofacial and dental arch morphology in relation to sleep disordered breathing from 4 to 12 years. Effects of adenotonsillar surgery. *Int J Pediatr Otorhinolaryngol* 2010;74(02):137–143
- Huang YS, Guillemainault C. Pediatric obstructive sleep apnea and the critical role of oral-facial growth: evidences. *Front Neurol* 2013;3:184
- Katyal V, Pamula Y, Daynes CN, et al. Craniofacial and upper airway morphology in pediatric sleep-disordered breathing and changes in quality of life with rapid maxillary expansion. *Am J Orthod Dentofacial Orthop* 2013;144(06):860–871
- Huynh NT, Desplats E, Almeida FR. Orthodontics treatments for managing obstructive sleep apnea syndrome in children: a systematic review and meta-analysis. *Sleep Med Rev* 2016;25:84–94
- Idris G, Galland B, Robertson CJ, Farella M. Efficacy of a mandibular advancement appliance on sleep disordered breathing in children: a study protocol of a crossover randomized controlled trial. *Front Physiol* 2016;7:353
- Camacho M, Chang ET, Song SA, et al. Rapid maxillary expansion for pediatric obstructive sleep apnea: a systematic review and meta-analysis. *Laryngoscope* 2017;127(07):1712–1719
- Guillemainault C, Huang YS, Monteyrol PJ, Sato R, Quo S, Lin CH. Critical role of myofascial reeducation in pediatric sleep-disordered breathing. *Sleep Med* 2013;14(06):518–525
- Ciavarella D, Lo Russo L, Mastrovincenzo M, et al. Cephalometric evaluation of tongue position and airway remodelling in children treated with swallowing occlusal contact intercept appliance (S.O. C.I.A.). *Int J Pediatr Otorhinolaryngol* 2014;78(11):1857–1860
- Brodsky L, Koch RJ. Anatomic correlates of normal and diseased adenoids in children. *Laryngoscope* 1992;102(11):1268–1274
- Cohen D, Konak S. The evaluation of radiographs of the nasopharynx. *Clin Otolaryngol Allied Sci* 1985;10(02):73–78
- Chervin RD, Weatherly RA, Garetz SL, et al. Pediatric sleep questionnaire: prediction of sleep apnea and outcomes. *Arch Otolaryngol Head Neck Surg* 2007;133(03):216–222
- Sawchuk D, Currie K, Vich ML, Palomo JM, Flores-Mir C. Diagnostic methods for assessing maxillary skeletal and dental transverse deficiencies: a systematic review. *Korean J Orthod* 2016;46(05):331–342

- 25 Angle E. Treatment of Malocclusion of the Teeth. Philadelphia, PA: SS White Dental Manufacturing Co.; 1907
- 26 Defraia E, Marinelli A, Baroni G, Tollaro I. Dentoskeletal effects of a removable appliance for expansion of the maxillary arch: a postero-anterior cephalometric study. *Eur J Orthod* 2008;30(01):57-60
- 27 Moss ML. The functional matrix hypothesis revisited. 4. The epigenetic antithesis and the resolving synthesis. *Am J Orthod Dentofacial Orthop* 1997;112(04):410-417
- 28 Fränkel R. Lip seal training in the treatment of skeletal open bite. *Eur J Orthod* 1980;2(04):219-228
- 29 Molfenter SM. The reliability of oral and pharyngeal dimensions captured with acoustic pharyngometry. *Dysphagia* 2016;31(04):555-559
- 30 Rosen CL, Wang R, Taylor HG, et al. Utility of symptoms to predict treatment outcomes in obstructive sleep apnea syndrome. *Pediatrics* 2015;135(03):e662-e671
- 31 Jena AK, Singh SP, Utreja AK. Effectiveness of twin-block and Mandibular Protraction Appliance-IV in the improvement of pharyngeal airway passage dimensions in Class II malocclusion subjects with a retrognathic mandible. *Angle Orthod* 2013;83(04):728-734
- 32 Huynh NT, Morton PD, Rompré PH, Papadakis A, Remise C. Associations between sleep-disordered breathing symptoms and facial and dental morphometry, assessed with screening examinations. *Am J Orthod Dentofacial Orthop* 2011;140(06):762-770
- 33 Pirelli P, Saponara M, Guilleminault C. Rapid maxillary expansion (RME) for pediatric obstructive sleep apnea: a 12-year follow-up. *Sleep Med* 2015;16(08):933-935
- 34 Ngiam J, Cistulli PA. Dental treatment for paediatric obstructive sleep apnea. *Paediatr Respir Rev* 2015;16(03):174-181