


# Post-Treatment Classification for Acetabular Chondral Lesions in Hip Arthroscopy\*

## *Classificação pós-tratamento para lesões condrais acetabulares na artroscopia de quadril*

Giancarlo Cavalli Polesello<sup>1</sup>  Maria-Roxana Viamont-Guerra<sup>1</sup> Fábio Zego<sup>1</sup>  
Nayra Deise dos Anjos Rabelo<sup>1,2</sup> Walter Ricioli Junior<sup>1</sup> Marcelo Cavalheiro Queiroz<sup>1</sup>

<sup>1</sup>Hip Group, Orthopedics and Traumatology Department, Faculdade de Ciências Médicas da Santa Casa de São Paulo (FCMSCSP), Irmandade Santa Casa de Misericórdia, São Paulo, SP, Brazil

<sup>2</sup>Human Motion Analysis Laboratory, Rehabilitation Sciences Department, Universidade Nove de Julho - UNINOVE, São Paulo, SP, Brazil

Address for correspondence Giancarlo Cavalli Polesello, Rua Dr Cesário Mota Júnior, 112, Bairro Vila Buarque, São Paulo, SP, 01221-020, Brazil (e-mail: dot.quadril@hotmail.com).

Rev Bras Ortop 2019;54:679–684.

### Abstract

**Objective** To describe a postarthroscopic treatment classification system for acetabular chondral damage in the hip and to report the intraobserver and interobserver reliability of such classification.

**Methods** This is a retrospective review of ninety-nine digital video recordings made during arthroscopic surgery. Patients who underwent arthroscopic treatment for femoroacetabular impingement and evaluated at the hip arthroscopy outpatient clinic between March 2015 and March 2016 were included in the study. Patients with a history of previous hip surgery, radiologic evidence of advanced osteoarthritis (Tönnis grade > 2), who underwent labral resection, or whose digital recordings were incomplete or of insufficient quality for adequate review were excluded. Two orthopedic surgeons, who did not participate in the surgery, independently reviewed the video recordings and classified the remaining acetabular cartilage using the post-treatment classification system. Intraobserver and interobserver analysis was then conducted using intraclass correlation coefficient (ICC).

**Results** Excellent intraobserver reliability (ICC = 0.790;  $p < 0.001$ ) and interobserver reliability (ICC = 0.882;  $p < 0.001$ ) were observed. Both ICC values were statistically significant.

**Conclusion** The posttreatment classification of the remaining acetabular cartilage has excellent intra and interobserver reliability.

### Keywords

- ▶ arthroscopy
- ▶ hip injuries
- ▶ chondrocytes/ classification
- ▶ treatment outcome

### Resumo

**Objetivo** Descrever um sistema de classificação de tratamento pós-artroscópico para as lesões condrais acetabulares no quadril e relatar as confiabilidades intra e interobservador deste sistema.

\* Work performed at the Hip Group, Orthopedics and Traumatology Department, Irmandade Santa Casa de Misericórdia, Faculdade de Ciências Médicas da Santa Casa de São Paulo (FCMSCSP), São Paulo, SP, Brazil.

**Palavras-chave**

- ▶ artroscopia
- ▶ lesões do quadril
- ▶ condrocitos/classificação
- ▶ resultado do tratamento

**Métodos** Esta é uma revisão retrospectiva de 99 gravações de vídeo digital realizadas durante artroscopia. Os pacientes submetidos a tratamento artroscópico para impacto femoroacetabular e avaliados no ambulatório de quadril entre março de 2015 e março de 2016 foram incluídos no estudo. Foram excluídos os pacientes com histórico de cirurgia anterior do quadril, pacientes com evidência radiológica de osteoartrose avançada (Tönnis > 2), pacientes submetidos à ressecção labral ou aqueles cujas gravações digitais estavam incompletas ou de qualidade insuficiente para avaliação adequada. Dois ortopedistas, que não participaram da cirurgia, revisaram de forma independente as gravações de vídeo e classificaram a cartilagem acetabular remanescente usando o sistema de classificação pós tratamento. A análise intra e interobservador foi então realizada utilizando o coeficiente de correlação intraclass (CCI). **Resultados** Excelente confiabilidades intra (CCI = 0,790;  $p < 0,001$ ) e interobservadores (CCI = 0,882;  $p < 0,001$ ). Ambos os valores ICC foram estatisticamente significativos. **Conclusão** A classificação pós-tratamento da cartilagem acetabular remanescente possui excelente confiabilidade intra e interobservador.

**Introduction**

The acetabular femoral impingement (AFI) is a well-known cause of joint cartilage injuries in the hip.<sup>1</sup> These lesions occur mainly in the anterosuperior zone of the acetabulum.<sup>2,3</sup> Several classification systems have been used to describe the early acetabular chondral damage in the beginning of the surgical procedure, and each one of them has its own advantages and disadvantages.<sup>4-6</sup>

Some studies have used these classifications to correlate chondral acetabular damage with surgical outcomes.<sup>7-11</sup> These intraoperative classifications assess the cartilage appearance prior to treatment, and they do not reflect posttreatment reality, since the surgical procedure may alter the appearance and, therefore, the classification of the chondral lesion. As such, it is also important to classify the cartilage appearance after the treatment.

The goals of hip arthroscopy include to approach and resolve cartilage and lip injuries. Therefore, the quality of the cartilage can be evaluated and classified immediately after the surgical correction.

The present study aims to describe a classification system for acetabular chondral damage in the hip after arthroscopic treatment and to report the inter and interobserver reliability of such system. We hypothesize that this system can have good intra and interobserver agreement.

**Materials and Methods**

In this retrospective study of 99 cases, 2 independent orthopedic surgeons (MCQ, RVG) analyzed digital video recordings made during arthroscopic hip procedures. The review focused on the aspect of acetabular cartilage of the hip after surgical correction and before traction removal.

The study included patients who underwent arthroscopic treatment for AFI and were evaluated at the hip arthroscopy

outpatient clinic between March 2015 and March 2016. In order to homogenize the sample, the following exclusion criteria were used: patients with a history of hip surgery, radiographic evidence of arthrosis (Tönnis > 2), previous labral resection or whose digital recordings were incomplete or of insufficient quality for adequate evaluation (► **Fig. 1**). Since labral resection can modify the morphology of the chondrolabral junction, which would cause bias in the classification of the final appearance of the cartilage, we decided to exclude the few cases of laparoscopic resection from our casuistry.

All surgical procedures were performed by a single orthopedist, experienced in arthroscopy (GCP). The surgical procedure was performed in standard supine position.<sup>12</sup> Pincer type deformities were corrected, and acetabular cartilage defects were smoothed until border stabilization was achieved. Microfracture was performed on Outerbridge grade IV chondral lesions, well-delimited by healthy borders surrounding the articular cartilage, as well as intact subchondral bone and the ability of the patient to participate in the postoperative rehabilitation process.<sup>13</sup> Labral injuries were repaired with anchors.

**Posttreatment classification development**

Posttreatment classification was developed considering aspects of the acetabular cartilage remaining after arthroscopic resection of impingement lesions, acetabular labrum repair, and chondral disorders management. The posttreatment classification comprises 4 types (► **Table 1**).

Type is assigned immediately upon procedure completion, based on the appearance and quality of the remaining acetabular cartilage. In type 1, the remaining cartilage is normal and healthy-looking. In type 2, the remaining cartilage is abnormal with malacia, fibrillation, surface roughness or any change without subchondral bone exposure. In case of subchondral bone exposure, the classification depends on

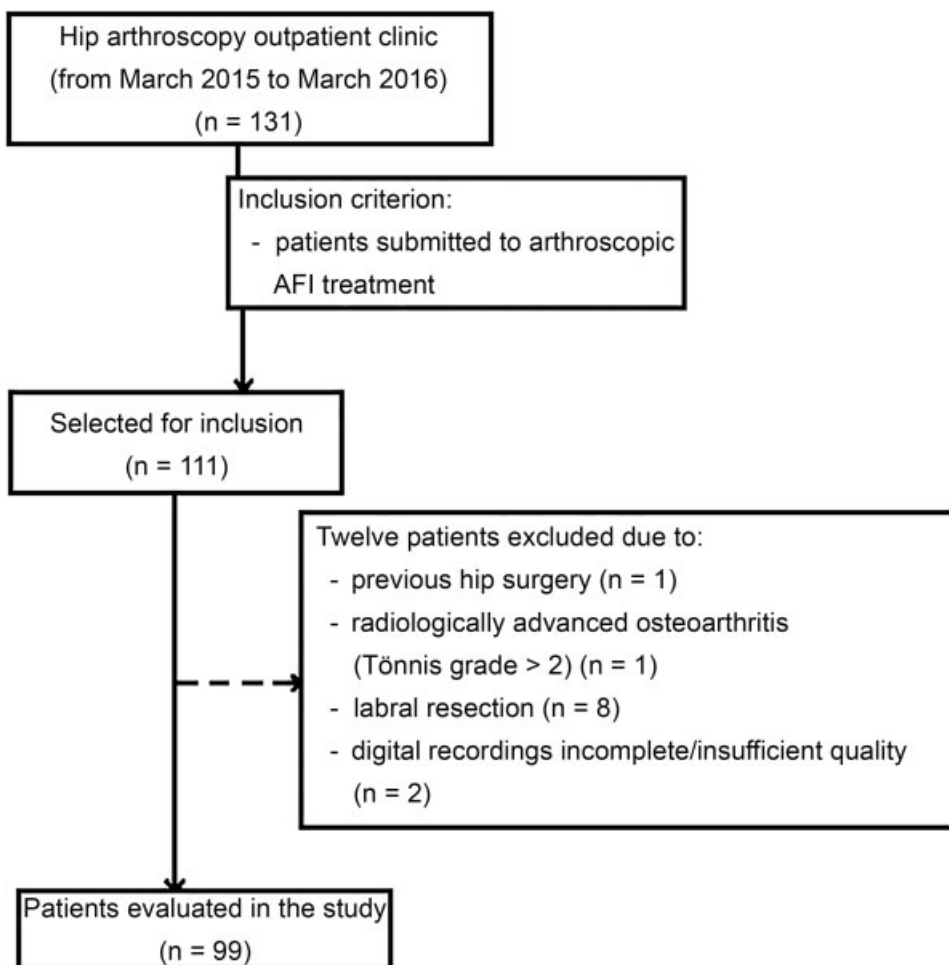


Fig. 1 Flow chart of the patients included in the study (OA: osteoarthritis).

Table 1 Posttreatment classification system

Type	Description of the remaining acetabular cartilage
1	The chondral lesion was completely removed, and the remaining cartilage appears normal
2	The remaining cartilage appears abnormal (surface roughness, malacia, fibrillation, surface roughness or any change without subchondral bone exposure)
3	Remaining area of exposed bone < 2 cm <sup>2*</sup>
4	Remaining area of exposed bone > 2 cm <sup>2</sup>

\*square centimeters.

the size of such exposure; if it is less than 2 cm<sup>2</sup>, the lesion is classified as type 3, and if it is greater than 2 cm<sup>2</sup>, the lesion is classified as type 4 (► Figs. 2–5).

**Video visual analysis**

Ninety-nine cases were selected for independent review by two orthopedists. Observer 1 was an orthopedist in the learning curve of hip arthroscopy, and observer 2 was an orthopedist experienced in hip arthroscopy. None of the observers participated in the surgical procedures of the

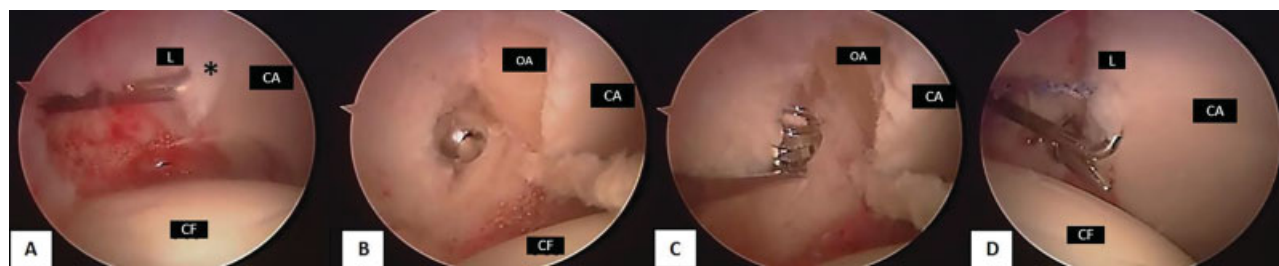
analyzed cases. The main surgeon did not participate in the video analysis for classification.

The posttreatment classification system was explained, and observers were instructed to focus their attention on the acetabular cartilage after conclusion of the entire arthroscopic procedure. They were also instructed to estimate the surface area of the exposed subchondral bone using the shaver blade tip as reference. When characteristics of several types were identified, observers were instructed to consider the worst remaining osteochondral aspect. Four weeks after the initial assessment, observer 1 reviewed each case again to determine intraobserver reliability.

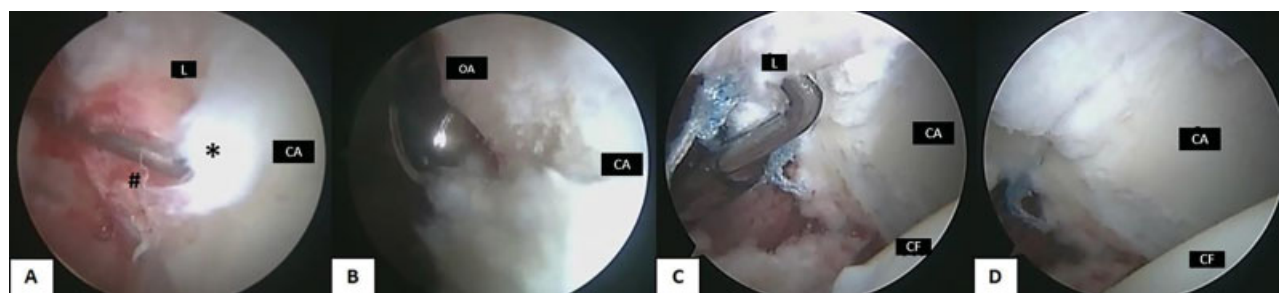
**Statistical analysis**

The interobserver analysis included a comparison between the values assigned by observer 1 and observer 2. The intraobserver analysis compared the values assigned at the first and second reviews by observer 1.

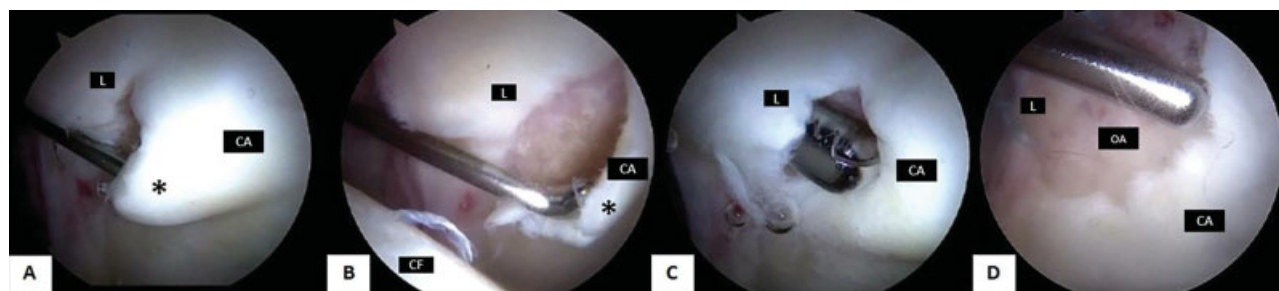
The intraclass correlation coefficient (ICC) was used to evaluate the intra and interobserver agreement of the post-treatment classification system. The statistical software SPSS version 22 (SPSS Inc., Chicago, IL, USA) was used for data analysis. Statistical significance was considered as *p* < 0.05. Intraclass correlation coefficient values were classified



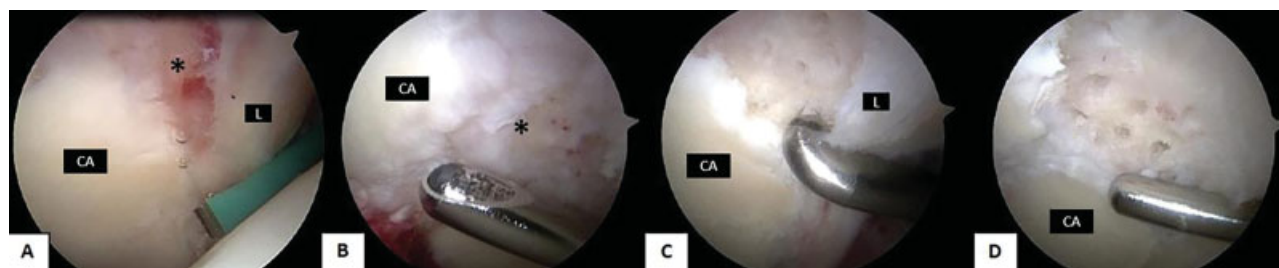
**Fig. 2** Arthroscopic images of the left hip showing the acetabular border. Note (A) the delaminated articular cartilage pushed with a probe at the beginning of the arthroscopic surgery. An acetabular osteoplasty (B, C) was performed with a burr. The remaining acetabular cartilage after AFI resection (D) has normal appearance at the end of the procedure and it is classified as type 1. Note that the appearance of the acetabular cartilage has changed. (FH, femoral head, AC, acetabular cartilage, L, labral, \*, lesion, AB, acetabular bone).



**Fig. 3** Arthroscopic images of the right hip showing the acetabular border. Note (A) the delaminated (\*) articular cartilage pushed with a probe and a chondrolabral junction injury (#) at the beginning of the arthroscopic surgery. An acetabular osteoplasty (B) was performed with a burr. The remaining acetabular cartilage after AFI resection (C, D) has abnormal appearance, with surface roughness and loss of cartilage thickness, but no evidence of subchondral bone exposure, being classified as type 2. Note that the appearance of the acetabular cartilage has changed. (FH, femoral head, AC, acetabular cartilage, L, labrum, \*, chondral lesion, chondrolabral lesion, AB, acetabular bone).



**Fig. 4** Arthroscopic images of the left hip showing the acetabular border. Note (A, B) the delaminated articular cartilage pushed with a probe at the beginning of the arthroscopic surgery. Cartilage debridement (C) was performed with a shaver and microfractures were made in the remaining area of subchondral bone exposure. This area measured less than 2 cm<sup>2</sup> (D); therefore, it was classified as type 3. Note that, at the end of the procedure, the alteration consists in the remaining area of exposed bone, which size was estimated in 4.5 mm using the tip of the shaver blade as reference. (FH, femoral head, AC, acetabular cartilage, L, labrum, \*, chondral lesion, AB, acetabular bone).



**Fig. 5** Arthroscopic images of the right hip showing the acetabular border. Note (A) lesion with subchondral bone exposure at the beginning of the arthroscopic surgery. Cartilage debridement (B) was performed with a shaver and microfractures (C) were performed on the remaining area of subchondral bone exposure. The final measurement of this exposed area was greater than 2 cm<sup>2</sup> (D); therefore, it was classified as type 4. Note that, at the end of the procedure, the alteration consists of a larger area of exposed bone, which size was estimated in 4.5 mm using the tip of the shaver blade as reference. (AC, acetabular cartilage, L, labrum, \*, chondral lesion)



**Table 2** Frequency of each chondral lesion type according to the posttreatment classification system, per observer

	Observer 1*		Observer 2*
	1 <sup>st</sup> evaluation	2 <sup>nd</sup> evaluation	
Type 1	17	20	17
Type 2	48	47	51
Type 3	22	26	23
Type 4	12	6	8

\*values indicate number of cases.

Interobserver intraclass correlation coefficient (ICC): 0.790 ( $p < 0.001$ );  
Interobserver ICC: 0.882 ( $p < 0.001$ ).

according to the description by Cicchetti,<sup>14</sup> in which values from 0.00 to 0.39 indicate very weak agreement, 0.40 to 0.59 indicate weak agreement, 0.600 to 0.750 indicate good agreement, and 0.75 to 0.99 indicate excellent agreement.

## Results

The sample consisted of 50 men (50.5%) and 49 women. The mean age of the patients at the time of surgery was 36.9 years-old (minimum 18, maximum 50 years-old). ► **Table 2** shows the distribution (per observer) of acetabular cartilage findings according to the new posttreatment classification system. The most commonly observed acetabular chondral classification was type 2, while the least common was type 4.

The posttreatment classification had excellent intraobserver reliability (ICC = 0.790;  $p < 0.001$ ) and excellent interobserver reliability (ICC = 0.882;  $p < 0.001$ ). Both ICC values were statistically significant.

## Discussion

The posttreatment classification system for AFI-related acetabular chondral presented excellent intra and interobserver relationships with an ICC of 0.790 for intraobserver analysis, and 0.882 for interobserver analysis, both with statistical significance ( $p < 0.001$ ).

The Outerbridge classification is often used to document cartilage lesions identified prior to arthroscopic treatment.<sup>6-8</sup> This classification system has been shown as moderately reliable for chondral and hip injuries, with strong intra and interobserver reliability.<sup>2,9,10,15</sup> However, since this classification system was originally described for the knee, instead of the hip, it does not consider loss of fixation or detachment of subchondral bone cartilage or the presence of cleavage at the chondrolabral joint, which are common in the hip. In addition, Outerbridge grade 4 does not consider the size of the exposed subchondral bone.<sup>2</sup>

The Beck classification system has been used to describe acetabular labrum and hip joint cartilage abnormalities.<sup>4,16</sup> Although initially described for hip dislocations during AFI treatment, it has also been applied to arthroscopic procedures.<sup>2,3</sup> This system reportedly has significant reliability.<sup>3</sup>

Konan et al<sup>5</sup> developed a classification for the chondral lesions found during hip arthroscopy considering its degree, zone and region, but its use was not generalized. The original paper reported high intra and interobserver reliability, while another study reported moderate reliability.<sup>2,5</sup>

All these classifications were used or proposed to evaluate acetabular chondral lesions identified at the beginning of surgery. To our knowledge, this is the first study considering the posttreatment aspects of acetabular cartilage. Pretreatment classifications are important in describing injuries and help to guide treatment. On the other hand, a posttreatment classification may be important to correlate the final quality of the cartilage with the outcomes, but this can only be proven over time in longitudinal studies.

These variables led us to formulate the value of a post-treatment classification. We have developed a simple and reproducible system that offers a different perspective to assess the appearance of acetabular cartilage and can be used to correlate postinterventional chondral surfaces characteristics with long-term prognosis.

During the development of the posttreatment classification, two categories were considered to differentiate the size of the remaining exposed bone area. In type 3, the estimated area presents less than 2 cm<sup>2</sup>, and in type 4, the estimated area is larger than 2 cm<sup>2</sup>. The size of 2 cm<sup>2</sup> was chosen since microfracture is recommended for lesions below this value.<sup>17-20</sup> Although there is no consensus in the literature on which type of arthroscopic procedure is suitable for various levels of subchondral bone exposure, types 3 or 4 lesions from this study were treated with microfracture.<sup>21</sup>

The present study has some limitations. Observers focused on posttreatment findings at the anterior and lateral cartilages, while posterior and inferior acetabular zones were not considered for classification. The distribution of the number of cases in each classification category was not homogeneous. Since this compromised the use of the kappa coefficient to evaluate inter and intraobserver reliability, ICC analysis was chosen. The authors suggest more studies using a greater number of cases with a homogeneous distribution of each classification type. The correlation of this classification with clinical-functional outcomes was not analyzed, but it will be studied in the future.

## Conclusion

This study demonstrates that it is possible to describe a posttreatment classification system for acetabular chondral lesions, with excellent intra and interobserver reliability.

### Conflicts of interest

The authors declare that there is no conflict of interest.

### Acknowledgment

The authors are grateful to Sharon Simmons (manuscript review), J. W. Thomas Byrd, MD (manuscript review), and Marcos Vinícius Amorim Freitas, MD (data collection) for their assistance.

## References

- 1 Johnston TL, Schenker ML, Briggs KK, Philippon MJ. Relationship between offset angle alpha and hip chondral injury in femoroacetabular impingement. *Arthroscopy* 2008;24(06):669-675
- 2 Amenabar T, Piriz J, Mella C, Hetaimish BM, O'Donnell J. Reliability of 3 Different Arthroscopic Classifications for Chondral Damage of the Acetabulum. *Arthroscopy* 2015;31(08):1492-1496
- 3 Nepple JJ, Larson CM, Smith MV, Kim YJ, Zaltz I, Sierra RJ, et al. The reliability of arthroscopic classification of acetabular rim labrochondral disease. *Am J Sports Med* 2012;40(10):2224-2229
- 4 Beck M, Kalhor M, Leunig M, Ganz R. Hip morphology influences the pattern of damage to the acetabular cartilage: femoroacetabular impingement as a cause of early osteoarthritis of the hip. *J Bone Joint Surg Br* 2005;87(07):1012-1018
- 5 Konan S, Rayan F, Meermans G, Witt J, Haddad FS. Validation of the classification system for acetabular chondral lesions identified at arthroscopy in patients with femoroacetabular impingement. *J Bone Joint Surg Br* 2011;93(03):332-336
- 6 Outerbridge RE. The etiology of chondromalacia patellae. *J Bone Joint Surg Br* 1961;43-B:752-757
- 7 MacDonald AE, Bedi A, Horner NS, de Sa D, Simunovic N, Philippon MJ, et al. Indications and outcomes for microfracture as an adjunct to hip arthroscopy for treatment of chondral defects in patients with femoroacetabular impingement: a systematic review. *Arthroscopy* 2016;32(01):190-200.e2
- 8 Filbay SR, Kemp JL, Ackerman IN, Crossley KM. Quality of life impairments after hip arthroscopy in people with hip chondropathy. *J Hip Preserv Surg* 2016;3(02):154-164
- 9 Streich NA, Gotterbarm T, Barié A, Schmitt H. Prognostic value of chondral defects on the outcome after arthroscopic treatment of acetabular labral tears. *Knee Surg Sports Traumatol Arthrosc* 2009;17(10):1257-1263
- 10 Kemp JL, Makdissi M, Schache AG, Pritchard MG, Pollard TC, Crossley KM. Hip chondropathy at arthroscopy: prevalence and relationship to labral pathology, femoroacetabular impingement and patient-reported outcomes. *Br J Sports Med* 2014;48(14):1102-1107
- 11 Schmaranzer F, Haefeli PC, Hanke MS, Liechti EF, Werlen SF, Siebenrock KA, et al. How Does the dGEMRIC Index Change After Surgical Treatment for FAI? A Prospective Controlled Study: Preliminary Results. *Clin Orthop Relat Res* 2017;475(04):1080-1099
- 12 Byrd JW. Hip arthroscopy. The supine position. *Clin Sports Med* 2001;20(04):703-731
- 13 Byrd JW, Jones KS. Microfracture for Grade IV Chondral Lesions of the Hip. *Arthroscopy* 2004;20(05):739-746
- 14 Cicchetti DV. Guidelines, criteria, and rules of thumb for evaluating normed and standardized assessment instruments in psychology. *Psychol Assess* 1994;6(04):284-290
- 15 Cameron ML, Briggs KK, Steadman JR. Reproducibility and reliability of the outerbridge classification for grading chondral lesions of the knee arthroscopically. *Am J Sports Med* 2003;31(01):83-86
- 16 Beck M, Leunig M, Parvizi J, Boutier V, Wyss D, Ganz R. Anterior femoroacetabular impingement: part II. Midterm results of surgical treatment. *Clin Orthop Relat Res* 2004;(418):67-73
- 17 Gudas R, Stankevicius E, Monastyreckiene E, Pranys D, Kalesinskas RJ. Osteochondral autologous transplantation versus microfracture for the treatment of articular cartilage defects in the knee joint in athletes. *Knee Surg Sports Traumatol Arthrosc* 2006;14(09):834-842
- 18 Miller BS, Steadman JR, Briggs KK, Rodrigo JJ, Rodkey WG. Patient satisfaction and outcome after microfracture of the degenerative knee. *J Knee Surg* 2004;17(01):13-17
- 19 Asik M, Ciftci F, Sen C, Erdil M, Atalar A. The microfracture technique for the treatment of full-thickness articular cartilage lesions of the knee: midterm results. *Arthroscopy* 2008;24(11):1214-1220
- 20 de Windt TS, Bekkers JE, Creemers LB, Dhert WJ, Saris DB. Patient profiling in cartilage regeneration: prognostic factors determining success of treatment for cartilage defects. *Am J Sports Med* 2009;37(Suppl 1):58S-62S
- 21 Chahla J, LaPrade RF, Mardones R, Huard J, Philippon MJ, Nho S, et al. Biological Therapies for Cartilage Lesions in the Hip: A New Horizon. *Orthopedics* 2016;39(04):e715-e723

**Erratum:** The name of Maria-Roxana Viamont-Guerra has been corrected as per Erratum published on October 22, 2019. DOI of the Erratum is 10.1055/s-0039-1698811.