


Neonatal Seizures—Are We there Yet?

Georgia Ramantani¹  Bernhard Schmitt¹ Barbara Plecko^{1,2} Ronit M. Pressler^{3,4} Gabriele Wohlrab¹
Katrin Klebermass-Schrehof⁵ Cornelia Hagmann⁶ Francesco Pisani⁷ Geraldine B. Boylan^{8,9}

¹Department of Neuropediatrics, University Children's Hospital, Zurich, Switzerland

²Department of Pediatrics and Adolescent Medicine, Medical University Graz, Graz, Austria

³Great Ormond Street Hospital for Children NHS Foundation Trust, London, United Kingdom

⁴UCL Great Ormond Street Institute for Child Health, London, United Kingdom

⁵Division of Neonatology, Pediatric Intensive Care and Neuropediatrics, Department of Pediatrics, Medical University Vienna, Vienna, Austria

⁶Department of Neonatology and Pediatric Intensive Care, University Children's Hospital, Zurich, Switzerland

⁷Child Neuropsychiatry Unit, University-Hospital of Parma, Parma, Italy

⁸Irish Centre for Fetal and Neonatal Translational Research (INFANT), University College Cork, Ireland

⁹Department of Pediatrics and Child Health, University College Cork, Cork, Ireland

Address for correspondence Georgia Ramantani, MD, PhD, Department of Neuropediatrics, University Children's Hospital Zurich, Steinwiesstrasse 75, 8032 Zurich, Switzerland (e-mail: georgia.ramantani@kispi.uzh.ch).


Neuropediatrics 2019;50:280–293.

Abstract

Neonatal seizures are the most prevalent and distinctive sign of neurologic dysfunction in early life and pose an immense challenge for clinicians. Improvements in neonatal care have increased the survival rate of extremely premature infants, considerably changing the spectrum of underlying etiologies, and instigating a gradual shift from mortality to morbidity. Recognizing neonatal seizures can be challenging due to variability in presentation but clinical features can often provide valuable clues about etiology. Yet, the majority of neonatal seizures are subclinical. Even though conventional electroencephalography (EEG) with simultaneous video detection of seizures still represents the diagnostic gold standard, continuous monitoring using a one- to two-channel amplitude-integrated EEG with concurrent unprocessed EEG can be crucial for early recognition and intervention. Furthermore, tremendous progress has been made in neuroimaging, and all infants with seizures should have a magnetic resonance imaging (MRI) to help identify the underlying etiology. While the majority of neonatal seizures are caused by hypoxic-ischemic events, stroke, hemorrhage, or infection, approximately 15% of patients will require more sophisticated algorithms for diagnostic workup, including metabolic and genetic screening. These recent developments have led to renew interest in the classification of neonatal seizures, which aim to help identify etiology and guide appropriate therapeutic and prognostic decisions. In this review, we outline recent progress made in the etiology, diagnosis, and treatment of neonatal seizures and highlight areas that deserve further research.

Keywords

- ▶ neonatal seizures
- ▶ outcome
- ▶ preterm
- ▶ term neonates

 Georgia Ramantani's ORCID is <https://orcid.org/0000-0002-7931-2327>.

received
October 16, 2018
accepted after revision
May 30, 2019
published online
July 24, 2019

© 2019 Georg Thieme Verlag KG
Stuttgart · New York

DOI <https://doi.org/10.1055/s-0039-1693149>.
ISSN 0174-304X.

Introduction

Seizure incidence is higher during the neonatal period than at any other time of life.¹ Neonatal seizures are the most common neurological emergency and are associated with a high risk of mortality and morbidity.²⁻⁴ Neonatal seizures occur in 1 to 3 per 1,000 live births,⁵⁻⁸ with substantially higher rates reported in premature neonates.⁹ Improvements in neonatal care over the last few decades have changed the spectrum of injury seen in the immature brain and have facilitated a decrease in mortality following neonatal seizures. However, the prevalence of long-term morbidity in survivors remains unchanged.^{10,11}

Neonatal seizures are unique, as the majority is symptomatic of brain injury occurring acutely in the perinatal period and only approximately 15% are related to an epilepsy syndrome, in stark contrast to seizures presenting later in infancy and childhood. Hypoxic-ischemic encephalopathy (HIE) in term neonates and intraventricular hemorrhage (IVH) in premature neonates are the most prevalent etiology. Other common causes are cerebral infarction, central nervous system (CNS) infection, brain malformation, or metabolic disorders.¹¹

In the past decade, tremendous progress has been made in the area of neonatal seizure detection and etiological classification using continuous neuromonitoring and advanced neuroimaging, in addition to clinical observation. Challenges in diagnostics have been met with the development of metabolic, as well as genetic, screening which carries the potential for rapid diagnosis and novel treatment options. In spite of increasing awareness about neonatal seizures and their dire consequences, including the high prevalence of cerebral palsy, developmental delay and postneonatal epilepsy, little progress has been made in the development of effective treatments. Randomized controlled trials have never been more urgent.

In this review, we highlight key areas of neonatal seizure diagnosis and treatment and identify the most imperative questions that still remain unanswered.

Classification of Neonatal Seizures

Neonatal seizures are often electrographic only (subclinical) or showing discreet clinical manifestations that can be difficult to differentiate from movements seen in sick preterm or term neonates.^{12,13} Hence, the need for electroencephalography (EEG) confirmation of neonatal seizures is widely accepted.^{6,12} However, this issue hinders the integration of neonatal seizures into a classification scheme serving all ages, which is reflected by the fact that, until recently, the International League Against Epilepsy (ILAE) seizure classification did not include neonatal seizures.^{14,15} It is not surprising, therefore, that other classifications have been published by neonatologists and pediatric neurologists which are unique to the neonatal period.^{13,16} However, these were based merely on clinical semiology,¹⁶ neglected electrographic-only seizures,¹⁶ and included both epileptic and nonepileptic events.^{13,16}

In 2014, a new taskforce on neonatal seizures was established by the ILAE (International League against Epilepsy-

Commission for terminology and classification). This taskforce has recently proposed a diagnostic framework based on the Mizrahi classification of neonatal seizures and the 2017 ILAE seizure classification,^{17,18} which consists of four domains: clinical presentation (high-risk or clinical suspicious events), diagnosis (with EEG), manifestation (with or without clinical manifestation), and seizure types with clinical signs (motor: automatisms, clonic, epileptic spasms, myoclonic, sequential, and tonic; non-motor: autonomic and behavioral arrest; and unclassified) or without clinical signs (electrographic only). This new classification, yet to be finalized, is expected to augment the diagnostic value of seizure semiology with respect to etiology and outcome of neonatal seizures. However, this novel framework will need to be tested on larger datasets to assert its applicability and validity.

Building a seizure classification tailored on neonatal age with detailed clinical-semiology features and characterization of specific electroclinical patterns will be the cornerstone in determining the etiology and, thus, the appropriate treatment in each neonate.

Does Seizure Semiology Reveal Seizure Etiology?

Recognizing seizures in the neonatal period can be challenging due to variability in their presentation.^{19,20} Premature neonates or those with severe encephalopathy are more likely to have electrographic-only seizures, particularly when antiseizure, sedative, or paralytic medications are administered. Clinical suspicion should be invariably verified by EEG recording, where possible, before treatment initiation.

A wide range of underlying causes gives rise to seizures in neonates but it should be noted that the majority of neonatal seizures is acute symptomatic²¹ and only approximately 15% of neonates have epilepsy as their seizure etiology. Despite the inherent complexity in this long list of causes, the timing and semiology of neonatal seizures can suggest the underlying etiology and help guide appropriate treatment options.

The timing of seizure onset provides the first indication of seizure etiology. HIE accounts for 60 to 65% of acute symptomatic neonatal seizures occurring in the first day of life, and most cases are evidenced by a complicated birth history. Neonatal seizures occurring up to 72 hours after birth are predominantly acute symptomatic, and may be associated with stroke or brain malformations, bacterial meningitis, intrauterine infection, IVH in preterm neonates, drug withdrawal, and metabolic disorders. Neonatal seizures occurring toward the end of the first week of life in otherwise healthy neonates with a family history of neonatal seizures may point to a genetic disorder; in particular to a self-limiting familial neonatal epilepsy.²²⁻²⁵ Pathogenic variants in two potassium channel subunit genes are associated with this epilepsy syndrome. Potassium voltage-gated channel subfamily KQT member 2 (KCNQ2) pathogenic variants are the most common, whereas KCNQ3 pathogenic variants are rare.^{22,26,27} Most patients with KCNQ2 pathogenic variants reach seizure freedom within the first year of life and remain seizure-free thereafter, but present with

moderate-to-severe developmental delay at follow-up.²⁸ Another autosomal dominant epilepsy syndrome presenting with neonatal seizures is the self-limiting familial neonatal-infantile epilepsy, associated with pathogenic variants in the sodium channel subunit gene *SCN2A*.^{29,30} Seizure onset in this disorder varies and seizures can start in the neonatal, as well as in the infantile period, whereas they generally stop by 12 months of age.²² Seizures in self-limiting familial neonatal or neonatal-infantile epilepsy, as recently characterized in a large cohort, may be focal or generalized clonic or tonic, often associated with apnoea, head or eye deviation, or staring.²²

Seizure semiology can provide valuable evidence regarding seizure etiology. True myoclonic seizures should raise suspicions of a metabolic disorder such as nonketotic hyperglycemia (NKH), propionic acidemia, and vitamin B₆-dependent epilepsy.^{31–33} Focal clonic seizures point to a focal cortical lesion, such as stroke, intracranial hemorrhage, and focal cortical dysplasia.^{13,34,35} Infants with tonic seizures should be suspected to have a genetic epilepsy syndrome (*KCNQ2*, *PEX*, *ARX*, *CDKL5*, *SPTAN*, *STXBP1*-related epilepsy, etc.) if the clinical history does not suggest a cortical malformation or an acute symptomatic etiology. Tonic seizures, evolving sequentially to encompass a sequence of a tonic followed by a myoclonic or clonic phase, are a hallmark of *KCNQ2*-related epilepsy, the most common genetic disorder associated with neonatal epilepsy.^{36–38} Epileptic spasms in neonates are rare, mostly found in metabolic disorders, such as vitamin B₆ dependent epilepsy that may present with sequential seizures encompassing spasms.^{25,39} However, epileptic spasms can also be caused by cortical malformations or early-onset epileptic encephalopathy.⁴⁰ Nearly, all seizure types have been reported in neonates with HIE but a large proportion will be electrographic only.^{13,41}

Overall, the variability of seizure types and the extensive list of etiologies pose a tremendous challenge to the diagnostic skills of even the most experienced clinicians. Yet, clinical features in neonatal seizures have the potential to help reveal the underlying etiology, particularly in centers with limited resources, where recommended diagnostic tools may be unavailable, facilitating the prompt implementation of a suitable treatment and, thus, improving outcomes.

Advances in genomic technologies are expected to disclose many other pathogenic variants associated with neonatal seizures. Furthermore, the introduction of the expanded newborn screening for metabolic disorders is bound to increase the rate of early etiologic diagnosis. These advances will serve to guide the appropriate management of neonatal seizures and thus improve their outcome.

Ictal and Interictal Electroencephalography

The majority of neonatal seizures are subclinical and thus best identified by their EEG signatures. An electrographic seizure is a sudden, abnormal EEG event defined by a repetitive, and evolving pattern with a voltage of > 2 μ V and a duration of > 10 sec.⁴² “Evolving” is defined as an unequivocal evolution in frequency, voltage, morphology, or location. An interval of at least 10 seconds is required to separate two distinct seizures.⁴² Nevertheless, cut-offs are arbitrary, and exceptions

to the rule may occur. For example, epileptic generalized myoclonic jerks are associated with discharges of < 10 seconds of duration. Brief rhythmic discharges of < 10 seconds of duration without clinical symptoms are considered nonictal, although they can have the same characteristics and bear the same risk for mortality and neurologic disability as electrographic seizures.⁴³ Other critical aspects are the demarcation of the onset and the end of the ictal discharge from interictal activity and the differentiation of seizures from seizure-like artifacts, physiological or pathological nonictal rhythmic patterns, or periodic patterns.⁴⁴

Electrographic seizures can be as follows:

- **Unifocal:** multiple seizures arise from a single region (► **Figs. 1, 2**).
- **Multifocal:** seizures originate from at least three independent foci with at least one in each hemisphere.
- **Lateralized:** seizures propagate within a single hemisphere.
- **Bilateral independent:** seizures occur simultaneously in two regions and begin, evolve, and behave independently.
- **Bilateral:** involvement of both hemispheres (► **Fig. 3**).
- **Migrating:** the seizure moves sequentially from one hemisphere to another.
- **Diffuse:** asynchronous involvement of all brain regions.

The morphology of ictal discharges consists of rhythmic spikes, sharp-waves, or rhythmic β , α , theta, or delta waves. In preterm neonates, rhythmic delta waves are the most common ictal pattern.⁴⁵ Focal clonic or focal tonic seizures exhibit focal EEG discharges, while generalized myoclonic jerks are associated with generalized bursts.¹³ Ictal EEGs are often focal in origin, while not necessarily corresponding to an underlying focal pathology.^{13,46,47} Status epilepticus is diagnosed when the summed duration of seizures comprises \geq 50% of an arbitrarily defined 1-hour epoch.⁴²

Background patterns in neonatal EEG provide a particularly valuable assessment of cerebral functioning following a variety of insults. A normal background pattern in an infant with unremarkable neurological examination and motor seizures may suggest self-limiting familial neonatal epilepsy.^{22,23} So-called periodic patterns are of uncertain significance. These are described as relatively uniform patterns with waveforms recurring at almost regular intervals without evolution, lasting > 10 seconds, presenting different morphologies, and focal, bilateral synchronous, bilateral asynchronous, or diffuse localizations.⁴²

An interictal burst-suppression pattern is a characteristic pattern of early-onset epileptic encephalopathy with onset in the first month of life, that is, Ohtahara's syndrome, or early infantile epileptic encephalopathy, and early myoclonic encephalopathy.^{48–51} Tonic seizures are the predominant seizure type in Ohtahara's syndrome, whereas myoclonic seizures are the predominant seizure type in early myoclonic encephalopathy. These epileptic encephalopathies were recently considered part of a spectrum, with a considerable overlap in clinical presentation and etiology.⁵² Known genetic causes of Ohtahara's syndrome and early myoclonic encephalopathy include brain malformations (e.g., polymicrogyria and lissencephaly), inborn errors of metabolism

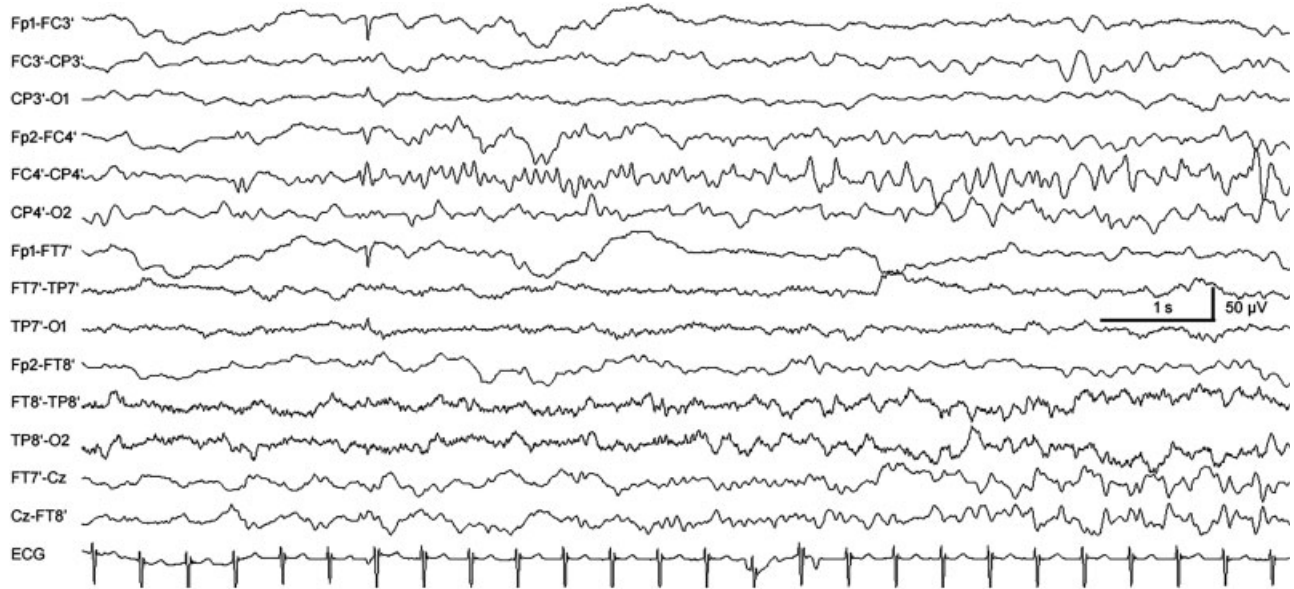


Fig. 1 Term neonate age 2 days, hypoxic-ischemic encephalopathy, focal clonic seizures involving the left arm and the left leg. The EEG seizure starts with rhythmic α waves evolving into irregular sharp theta waves and after 15 seconds (not shown) in rhythmic sharp waves. ECG, echocardiogram; EEG, electroencephalography.

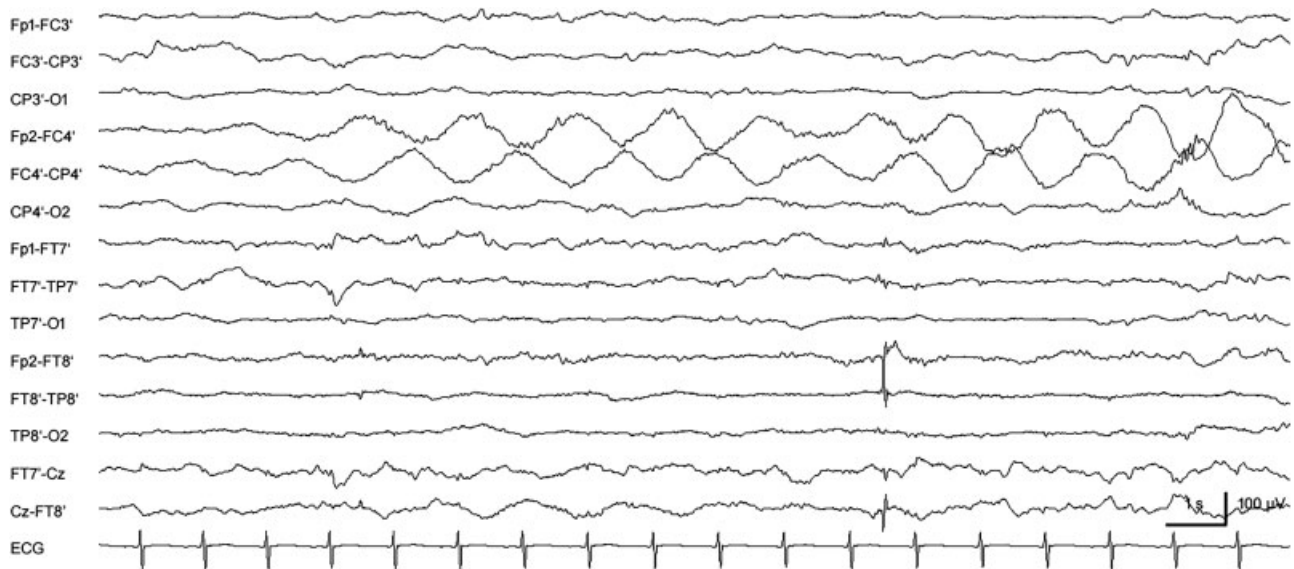


Fig. 2 Term neonate age 1 day, hypoxic-ischemic encephalopathy, focal clonic seizures involving the left arm and oral automatisms. The EEG seizure starts with rhythmic delta waves. EEG, electroencephalography.

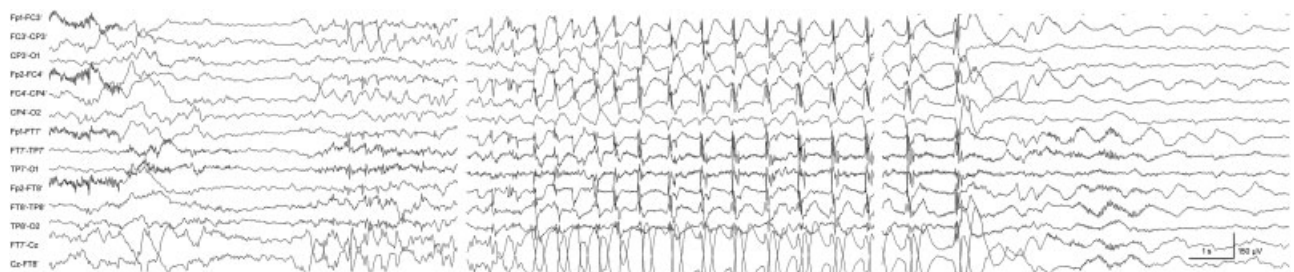


Fig. 3 Term neonate age 10 days, *STXBP1* encephalopathy, bilateral clonic seizures involving both arms and legs. The EEG seizure starts with bilateral amplitude reduction followed by bilateral parasagittal and generalized rhythmic spike waves with centromedian maximum.

(e.g., pyridoxine- and other vitamin-dependent epilepsies, mitochondrial disorders, and amino acidopathies), and other genetic etiologies (e.g., pathogenic variants in *ARX*, *GABRA1*, *KCNQ2*, *KCNT1*, *SCN2A*, *SIK1*, *SLC25A22*, and *STXBP1*).^{36,53–59} Overall, single gene variants underlie 20 to 40% of epileptic encephalopathies,^{60–63} with genetic testing reaching a yield of 83% in a recent study.²¹ The identification of these genetic etiologies may prove crucial for patients with early-onset refractory epilepsy who may profit from gene-based treatments in light of emerging precision medicine.⁶⁴

Long-term video-EEG monitoring in encephalopathic neonates, as well as in severely ill preterm neonates, will help to identify subtle seizures and initiate their prompt treatment, thus facilitating a better prognosis. Definition of distinct electroclinical phenotypes will delineate genetic encephalopathy and specific etiology-related syndromes, avoiding unnecessary testing and indicating specific therapeutic management.

Amplitude-Integrated Electroencephalography in Seizure Monitoring

While full video-EEG, difficult to implement on a 24/7 basis in nonexpert centers, remains the gold standard for neurophysiological monitoring, amplitude-integrated EEG (aEEG), displaying a time-compressed, one-or two-channel trend of the EEG, is increasingly utilized for long-term monitoring and continuous surveillance in the neonatal intensive care unit (NICU). This simplified monitoring enables the assessment of the background activity and facilitates the earlier recognition of state changes, although abnormal findings (especially suspected seizures) eventually require further investigation by more detailed full EEG.

Previous literature has shown an 80% correlation of seizure detection by aEEG compared with full EEG⁶⁵ when used by aEEG experts, underlining that although aEEG has a lower sensitivity than full EEG, aEEG-based seizure diagnosis is much more reliable than clinical diagnosis

alone.^{66,67} When nonexperts assessed the aEEG, results were, however, much poorer.⁶⁸ Seizures are more common over central cerebral regions and, if EEG electrodes cover this area, neonatal seizures can be identified in 70 to 80% of cases.⁶⁹ Seizures can be detected in the aEEG as “saw-tooth-like” augmentations of the baseline amplitude but should be confirmed by examination of the simultaneous raw-EEG trace to rule out any artifact (► Fig. 4). Thus, aEEG can facilitate the verification of “clinical seizure” diagnosis and detect subclinical seizures. Overall, aEEG is a useful aid for clinical decision making in the NICU, particularly when full EEG monitoring is either not feasible or not available. However, since most neonatal seizures are brief and focal, and many are low-amplitude, they may be missed by aEEG^{69–71} that is clearly not a very sensitive tool for seizure detection. On the other hand, recently developed automatic seizure detection algorithms are expected to enhance seizure detection considerably. It should, however, be noted that no single automated seizure detection system is reliable enough to substitute for an experienced electroencephalographer in the clinical setting. These algorithms are rather used to provide intuitive decision support to NICU personnel.^{72,73}

Seizure treatment studies that compared clinical diagnosis alone with aEEG-based continuous monitoring for seizure detection showed a lower injury score on MRI and a lower epilepsy incidence later in life when aEEG monitoring was available.^{74,75} The reduction of total seizure burden by optimized aEEG-guided treatment correlated with improved cognitive outcome in neonates suffering from hypoxic-ischemic encephalopathy.⁷⁶ In conclusion, aEEG has the potential to support the diagnosis and treatment of neonatal seizures, particularly in nonspecialist centers. Since EEG is particularly resource-intensive, a key area of high-priority research is optimizing seizure detection algorithms for use in clinical settings and automated seizure-burden analyses for use in future clinical treatment trials.

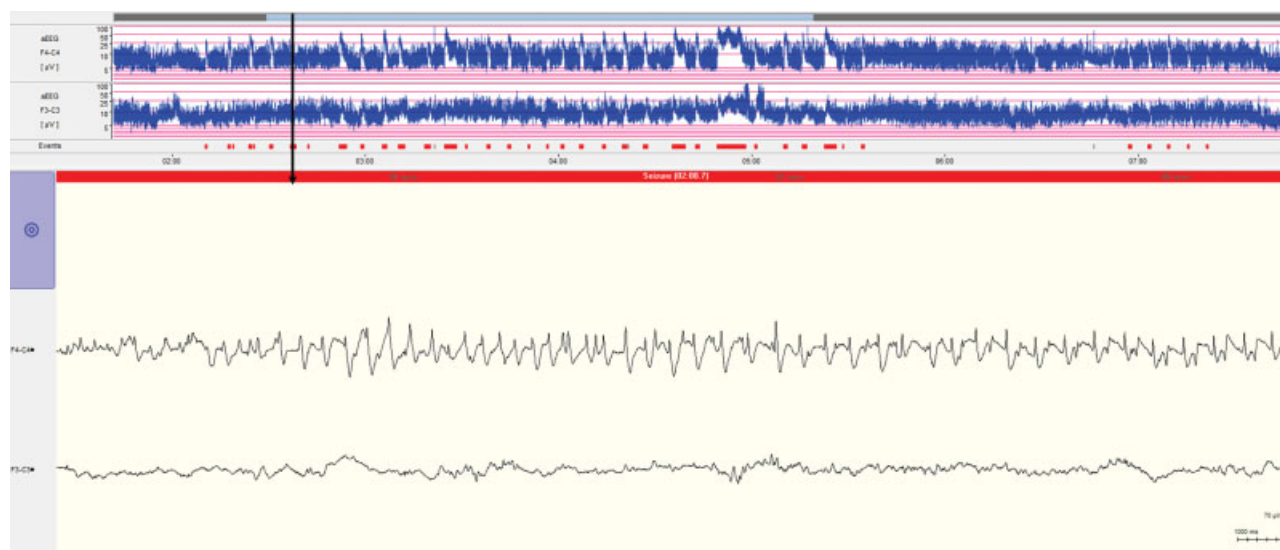


Fig. 4 aEEG (above) and EEG traces (below) depicting a seizure pattern in a neonate. The red blocks in the event line identify the seizures. aEEG, amplitude-integrated electroencephalography.

Neuroimaging of Neonatal Seizures

Neuroimaging techniques used in neonatal seizures include cranial ultrasound (cUS) and MRI. Although most NICUs use cUS as the method of choice, MRI is rapidly gaining ground with the majority of neonates with seizures or HIE in recent studies undergoing at least one MRI scan.^{77,78} The distinct advantages of cUS are the wider availability, the feasibility of bedside use in all neonates including those too unstable to be transported to the MRI unit, and its compatibility with minimal handling in very immature neonates. However, the acquisition of high-quality cUS images is user-dependent, thus posing clear limitations for the detection of specific brain injuries. On the other hand, MRI is not always available and requires a transfer of the neonate to a dedicated MRI unit. Nevertheless, MRI has been acknowledged as the optimal neuroimaging modality for neonatal seizures, particularly when age-appropriate acquisition protocols are applied.⁷⁹ Ultimately, a combination of these two techniques could provide the ideal tools to evaluate the underlying etiology.

The added value of MRI compared with cUS has been assessed in a large cohort of term and near-term infants with different seizure etiologies.⁸⁰ In all, but 6% of infants, the underlying etiology could be identified, helped significantly by MRI.⁸⁰ In 12% of infants, a diagnosis or significant imaging abnormalities would have been missed if only cUS rather than a combination of cUS and MRI had been used. As expected, MRI was most useful in diagnosing cerebral sinus venous thrombosis, some metabolic disorders, and cerebral dysgenesis.⁸⁰ Another study showed that the probability of neurodevelopmental impairment or recurrent seizures was low in the absence of significant cerebral lesions on MRI,⁸¹ highlighting the utility of MRI not only in identifying the cause of neonatal seizures but also in providing information on long-term outcome.

Magnetic resonance spectroscopy (MRS) can contribute information additional to conventional MRI in the evaluation of neonatal seizures by noninvasively measuring CNS metabolite levels such as N-acetylaspartate (NAA), choline, creatine, and lactate. Abnormal lactate, pyruvate, or amino acid peaks may point to inborn errors of metabolism,⁸² and MRS may guide the detection of mitochondrial disease in neonates with normal MRI.⁸³ Furthermore, MRS has the potential to contribute information relevant to prognosis in HIE.⁸⁴ Several studies have shown that lactate/creatine plus phosphocreatine, lactate/NAA, or lactate/choline-containing compounds peak-area ratios in HIE provide accurate prognostic markers of the severity of brain injury and subsequent neurodevelopmental outcome before changes are apparent on conventional MRI.⁸⁵⁻⁸⁹ However, obtaining and interpreting MRS remains very difficult for nonspecialist centers.

The rate of early diagnosis, especially of metabolic disease, is expected to increase with the further development of neuroimaging techniques. This will lead to early and thus more efficient management of treatable conditions.

Measuring the Efficacy of Neonatal Seizure Treatment

To date, few studies have used a standardized protocol for measuring seizure treatment efficacy in neonates. Many older studies relied on the clinical abolition of seizures only as a measure of treatment efficacy; this is clearly not adequate. aEEG efficacy measurement is better but there are some limitations already outlined that make aEEG inadequate for use in randomized controlled trials. Full EEG has been used in several small studies to measure treatment efficacy but the methods used were heterogeneous; information on the length of time it took for seizures to reduce or abate was rarely included, and the percentage change in seizures from baseline was not discussed. This issue makes a comparison between studies particularly challenging and a meta-analysis almost impossible. As a result, it has been difficult to progress studies of antiseizure medication treatment in neonates. Measuring treatment outcomes for neonatal seizures can also be difficult because of the natural history of neonatal seizures, and this can vary with etiology.⁹⁰

We advocate the use of seizure burden as the quantitative measure of choice when assessing antiseizure medication efficacy.⁹¹⁻⁹⁴ Seizure burden can be measured in minutes per hour and is a measure of the short-term intensity of seizures. Seizure detection algorithms are currently undergoing randomized trials, and there is no doubt that this technology will very soon make it easier to automatically calculate the on-going seizure burden and evolving seizure profile.^{95,96}

It has long been recognized that neonatal seizures evolve over time but very few studies have detailed the evolution of electrographic seizures in neonates and those that have, generally describe seizures in neonates with HIE.^{90,97-99} Lynch et al examined the temporal distribution of seizures in neonates with HIE and found that seizures had a short period of high-electrographic seizure burden near the time of seizure onset, followed by a longer period of low-seizure burden.⁹⁰

Neonatal seizure evolution does not only depend on etiology and factors, such as gestational age and treatment, are also important (→ Fig. 5). However, it is not known if earlier treatment of electrographic seizures will alter the course of the seizure evolution and result in less brain injury though some studies do indicate that a lower seizure burden is associated with less severe MRI severity scores and better outcomes.^{74,76,100} Due to logistic challenges in EEG monitoring and recruitment,¹² studies that aim to treat electrographic seizures immediately after onset are rare.^{74,76,93}

Understanding the impact of seizure burden on long-term neurodevelopmental outcomes is an area of priority research. The evaluation of antiseizure medication in neonates, within the context of their clinical picture, may help to conceive novel, more effective drugs, and treatment protocols.

Metabolic and Genetic Workup in Pharmacoresistant Neonatal Seizures

While most neonatal seizures are symptomatic, a subgroup of about approximately 15% represents distinct neonatal

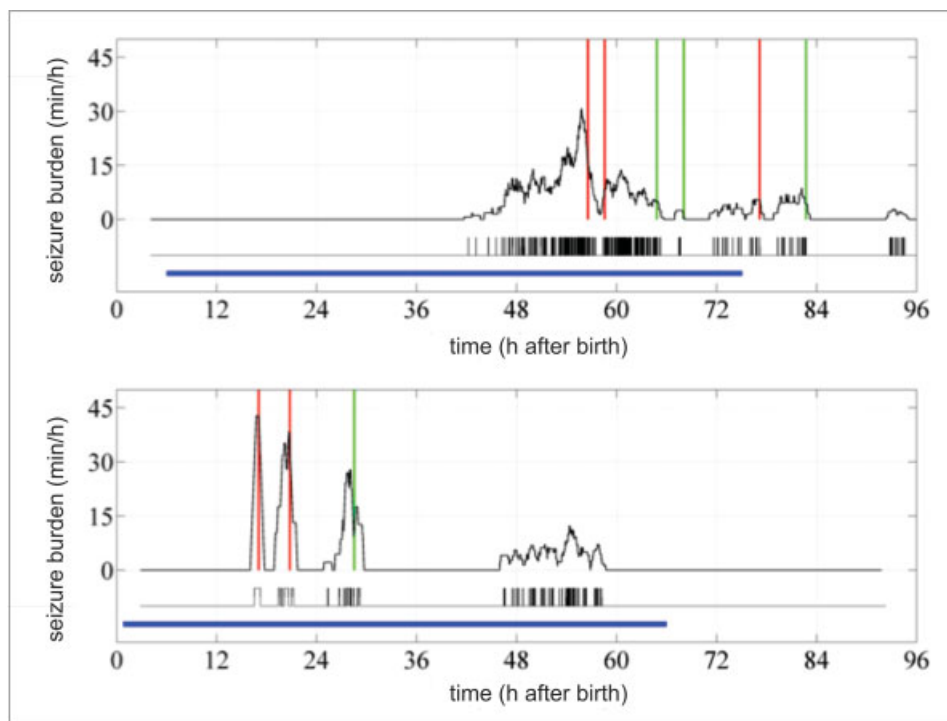


Fig. 5 Seizures in two neonates showing the evolving seizure burden. The red vertical lines indicate the administration of loading doses of phenobarbitone and the green vertical lines represent the administration of loading doses of a second line anticonvulsant (phenytoin or midazolam). The neonate in A has a total seizure burden of 243 minutes with 185 seizures; the neonate in B has a total seizure burden of 214 minutes with 56 seizures. The middle black trace denotes the neurophysiologist annotation of seizures, and the bottom blue trace denotes the period of therapeutic hypothermia. Both neonates had periods of status epilepticus, that is, seizure burden of > 30 minute/h. Reproduced from Boylan et al.¹²

epilepsy syndromes, related to either brain malformations or genetic etiologies.²¹ Within this subgroup, congenital brain malformations have been established in 41%, whereas genetic etiologies were identified in 42% of neonatal epilepsies,²¹ with an overlap of approximately 9% between structural and genetic causes. Inborn errors of metabolism, established on the grounds of clinical presentation and biochemical investigations, and often verified by genetic workup, represent a major challenge that needs to be identified, and addressed, quickly to avoid metabolic decompensation and enable counseling regarding recurrence risks and overall prognosis.^{101,102}

As early diagnosis enables specific treatment in some metabolic disorders¹⁰³ and may influence the choice of drugs in primary genetic conditions, a diagnostic algorithm should be in place in all neonatal units. This algorithm should include a standardized and well-documented vitamin B₆ trial (►Fig. 6) which may identify patients with defects in *ALDH7A1*,¹⁰⁴ *PNPO*,¹⁰⁵ the newly described *PLPBP* (previously named *PROSC*) gene,^{106,107} or rare cases of severe congenital hypophosphatasia.¹⁰⁸ These patients manifest with myoclonic seizures or a variety of other seizure types that are typically resistant to standard anticonvulsants and may be associated with a burst suppression pattern in EEG. Respective biomarkers can be used to guide further diagnostic workup of inborn errors of metabolism (►Table 1).

Patients with molybdenum cofactor deficiency (MocD) manifest with tonic-clonic seizures, poor feeding, and variable facial dysmorphic signs. In this disorder, neuroimaging is quite

specific, with findings ranging from cerebral edema to cystic leukoencephalopathy.¹⁰⁹ For MocD type A, substitution with purified cyclic pyranopterin monophosphate cPMP has proven effective but the window of opportunity is very short.¹¹⁰

The past decade has revealed a quickly growing number of genes that cause primary genetic early-onset epileptic encephalopathies.¹¹¹ Some may have suggestive semiology, such as sequential seizures in *KCNQ2* pathogenic variants, while in, for example, *STXBP1* pathogenic variants, broad phenotypic variability has been described.¹¹² Thus, many institutions have changed their policies by sequencing multiple genes in a panel approach or going for next-generation sequencing of the whole exome¹⁰² with a diagnostic yield of approximately 40% in patients with seizure onset < 2 months of age.¹¹³ As pathogenic variants in some genes occur de novo, while others are of Mendelian inheritance, an exact diagnosis is crucial for genotype-phenotype correlations¹¹⁴ and further family planning and counseling.

A detailed characterization of the electroclinical features associated with pathogenic genetic variants will help to refine the genotype-phenotype correlations that guide the increasingly applied genetic testing.

The Need for Trials in Neonatal Seizures

Considering that a high-seizure burden may aggravate long-term outcome, there is an urgent need to control prolonged or recurrent seizures. Nevertheless, there is still an open debate concerning the management of neonatal seizures.¹¹⁵

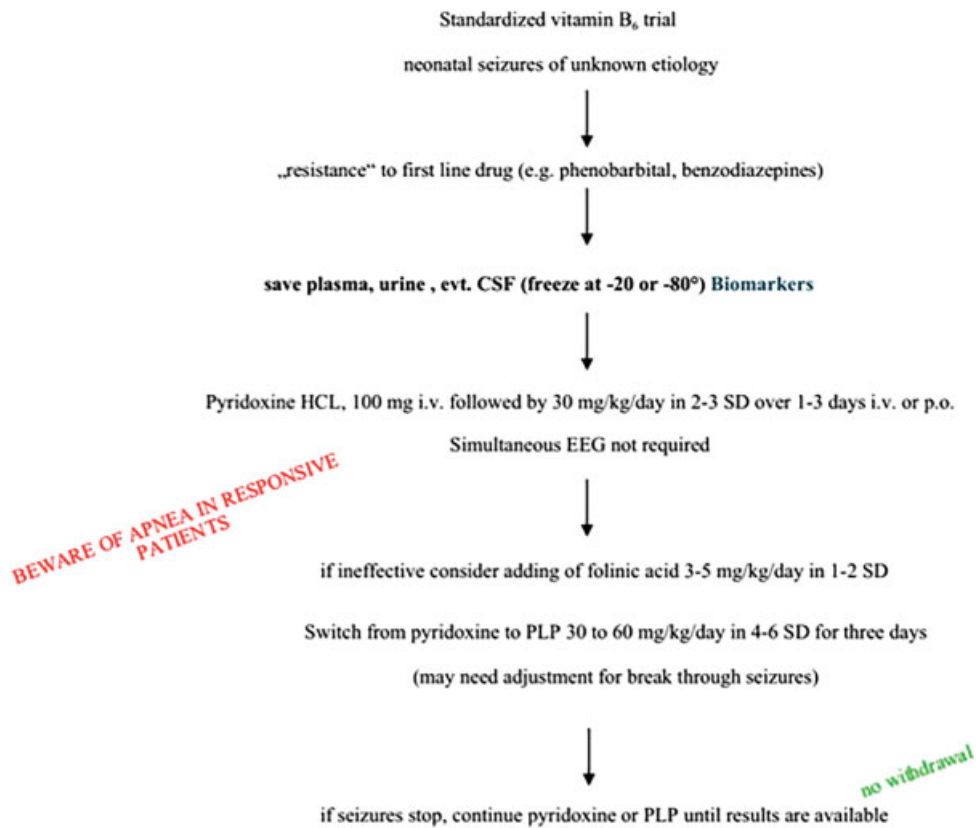


Fig. 6 Proposed algorithm for a standardized vitamin B₆ trial. The timing and switch from pyridoxine HCL to pyridoxal 5'-phosphate (PLP) is individual and should be considered after 24 hours on pyridoxine in case of persistent high seizure frequency. Improvement on EEG can lag markedly behind clinical improvement and is thus not a basis for initial decision-making. The algorithm does not exclude the simultaneous use of conventional anticonvulsants. CSF, cerebrospinal fluid; EEG, electroencephalography; SD, standard deviation.

Table 1 Common metabolic diseases associated with neonatal seizures, their metabolic and genetic biomarkers

Disease	Urine	Plasma	CSF	Gene
Antiquitin deficiency	↑ <u>AASA</u> , ↑ PA	↑ PA	↑ AASA, P6C, ↓ PLP, ↑ PA, sec NT abn.	<i>ALDH7A1</i>
PNPO deficiency	(Vanillactate)	<u>B₆ profile</u> ↑ <u>pyridoxamine</u>	↓ PLP, sec NT abnorm.	<i>PNPO</i>
Congenital Hypophosphatasia		↓ AP, <u>B₆ profile</u> , ↑ <u>PLP</u>	(↓ PLP ?)	<i>TNSALP</i>
MOCOD, ISOD	<u>Sulfocysteine</u> ↑ AASA, ↑ P6C	↓ Uric acid	↑ AASA, P6C ↓ PLP, ↑ PA	<i>MOCS1, MOCS2, GPNH</i>
NKH (non ketotic hyperglycinemia)		<u>Aminoacids (glycine)</u>	<u>Aminoacids (glycine)</u> <u>CSF/plasma >0.004</u>	4-enzyme cleavage system
Organoacidurias (e.g., D2HGA)	<u>Organic acid profile</u>	<u>Aminoacids</u>		...
CDG syndromes		<u>Transferrin isoelectric focusing</u>		Common in CDG type II
Zellweger Syndrome		<u>VLCFA, PA, phytanic acid, pristanic acid</u>		<i>PEX</i> genes 1–13
Adenylosuccinate lyase deficiency	<u>Purines</u>			<i>ADSL</i>

Abbreviations: CSF, cerebrospinal fluid. NKH, nonketotic hyperglycinemia; PLP, pyridoxal 5'-phosphate; CDG, congenital disorders of glycosylation; MOCOD, Molybdenum cofactor deficiency; ISOD, isolated sulfite oxidase deficiency; D2HGA-2, D-2-hydroxyglutaric aciduria; AASA, α-amino adipic semialdehyde; PA, propionic acid; P6C, Δ1-piperidine 6-carboxylic acid; AP, alkaline phosphatase; VLCFA, very long chain fatty acids; sec, secondary; NT, neurotransmitter.

Specific biomarkers in preferred material are underlined, while biomarkers in non-preferred material, inconsistent and/or secondary findings, are not.

As a first step, the underlying etiology of seizures must be established as soon as possible, since this can facilitate an etiological and effective treatment. As a second step, for symptomatic treatment, short-term or long-term therapy should be chosen, depending on the risk of seizure recurrence.

One of the major issues in the management of neonatal seizures is the lack of effective antiseizure drugs. In a Cochrane's review from 2004,¹¹⁶ only two randomized controlled trials could be identified, with the authors concluding that "there is little evidence from randomized controlled trials to support the use of any of the anticonvulsants currently used in the neonatal period." Phenobarbital, the most widely-used first-line drug in neonatal seizures, has a response rate of approximately 43% and phenytoin, as a second-line antiseizure medication, of 57%.⁹¹ Benzodiazepines and levetiracetam are commonly used as second- or third-line drugs. Lidocaine reached a response rate of 68% in full-term neonates with a higher response rate than midazolam as second-line antiseizure medication ($p = 0.049$).¹¹⁷ However, concerns have been raised regarding lidocaine toxicity, mainly in the form of cardiac arrhythmias, concerning 4.8% of neonates in a large study.¹¹⁸ In view of potential cardiac side effects, recent reviews warn against combining lidocaine with other cardiotoxic agents, for example, phenytoin.¹¹⁹ In three current studies, including a large cohort of 368 full-term and 153 preterm infants, lidocaine-associated cardiac events were rare, especially since the introduction of new reduced-dose regimens.¹²⁰⁻¹²² It should be noted that no specific antiseizure medication for preterm infants are indicated, despite the vast differences in pharmacokinetics, as well as in the maturation, of the CNS. Finally, although it has been long recognized that current treatments are ineffective as first-line medications for neonatal seizures, trials still focus on refractory neonatal seizures rather than on their initial treatment.

In 2009, the NEMO (neonatal seizure using medication off-patent) consortium set out to evaluate the loop diuretic bumetanide as a potential second-line treatment for neonatal seizures in a multicenter study across Europe. This study was, unfortunately, stopped early because of possible ototoxicity concerns and limited evidence for seizure reduction. In the past decade, several antiseizure medications, such as levetiracetam^{123,124} and topiramate,¹²⁵ have emerged as viable alternatives with the potential to address age-specific mechanisms and challenges. Two large randomized, controlled trials of bumetanide (NCT00830531) and levetiracetam (NEOLEV2: NCT01720667) are currently undergoing and are expected to yield more detailed data regarding the use of these antiseizure medications to treat neonatal seizures. The preliminary results of the first study, evaluating the efficacy of bumetanide as add-on therapy for refractory neonatal seizures, demonstrated an additional reduction in seizure burden attributable to bumetanide over phenobarbital.¹²⁶ The preliminary results of the second study, evaluating the efficacy and safety of levetiracetam compared with phenobarbital in the first-line treatment of neonatal seizures, supported a higher efficacy of phenobarbital compared with levetiracetam, but

this was associated with a higher rate of side effects.¹²⁷ While the final evaluation of these trials is still pending, it should be pointed out that their infrastructure involved the implementation of cutting-edge technology to provide continuous video EEG monitoring and real-time response to seizure detection.¹²⁸ Although this standard of care yet remains unfeasible in the standard clinical setting, the development of this framework opens up new perspectives for future research, as well as for optimizing the management of neonatal seizures.

Another critical issue in neonatal seizure management is the optimal duration of antiseizure medication therapy when seizures cease. A recent systematic review¹²⁹ suggests to wean medication to a single antiseizure medication before discharge or even withdraw medication altogether, if only single or rare seizures have occurred and the neonate has been seizure free for at least 48 to 72 hours and if the risk of recurrence is not felt to be unusually high. However, in a prospective multicenter study conducted in 2013 to 2015, the decision to send a neonate home on antiseizure medication correlated rather with the hospital of admission than with the seizure burden and the seizure etiology.¹³⁰ Phenobarbital, the most commonly prescribed first-line antiseizure medication for neonatal seizures, is often maintained for several months, due to fear of seizure recurrence after early discontinuation, although continued exposure to phenobarbital may have deleterious long-term effects on the developing brain.^{131,132}

Finally, it is still unclear if improved control of neonatal seizures has the potential to enhance long-term outcome, and this will remain an open issue until effective treatments are found. New generation antiseizure medication appears promising, considering the absence of proapoptotic properties.^{115,133} Moreover, the development of antiepileptogenic drugs in this vulnerable period of brain development may change the evolution of the disease. The need for randomized controlled studies in neonates has never been more urgent. In the next step, standardized treatment protocols of neonatal seizures, proving the precise timing, and indication for etiologic treatment are required.

Outcome of Neonatal Seizures

Mortality following neonatal seizures has decreased from 40 to 20% in the last few decades. However, the prevalence of long-term neurological sequelae in survivors remains unchanged at 30%.^{1,11} The incidence of postneonatal epilepsy,¹³⁴ cerebral palsy, and developmental delay is higher in preterm neonates,^{8,135} with a reported odds ratio of 14 (95% confidence interval [CI]: 2-86) per week of gestational age.¹³⁶ This shift from mortality to morbidity in the preterms poses a significant challenge for clinical management in the NICU.¹³⁷ In a recent study,¹³⁸ unfavorable outcome predictors in preterm neonates included low birth weight, low Apgar's score at 1 minute, abnormalities in the neurologic examination, pathologic EEG or cUS findings, and particularly neonatal status epilepticus (a rarity at low gestational ages).

Moreover, recent preclinical¹³⁹ and clinical^{140,141} studies in HIE have provided evidence that recurrent seizures themselves may amplify injury to the developing brain beyond that of the underlying etiology. Overall, experimental data support the belief that seizures in early life impede normal development and reduce the efficiency of cortical networks, even in the absence of cell loss.^{142,143} Permanent impairments in learning, memory, and cognition, as well as increased seizure susceptibility, may result from these seizure-induced changes in neuronal connectivity and receptor expression.^{144,145} Interestingly, animal models provide evidence that prolonged seizures or status epilepticus result in brain injury only in the presence of preexisting insults, such as those associated with HIE.¹⁴⁶ These observations are crucial in terms of neonatal seizure management but experimental data still awaits confirmation in prospective double-blind clinical studies. It should be noted that a 2016 Cochrane's review investigating prophylactic barbiturate use in HIE¹⁴⁷ reported a reduced risk of seizures but no reduction in neonatal mortality, whereas long-term outcomes were unavailable.

In the meantime, several, usually single-center, studies have sought to identify outcome predictors, mainly in the underlying etiology or specific seizure types and EEG patterns.¹⁰ Research on this topic is, however, impeded by the variable criteria of neonatal seizure identification and etiologic diagnosis throughout research studies,^{10,137} with preterm neonates constituting a particular challenge in this respect. Nevertheless, considerable efforts have been made to develop a robust scoring system/predictive model for neonatal seizures that would facilitate clinical decision.^{148–152} These models are yet to be validated in larger, representative contemporary cohorts, to promote their implementation in clinical practice.

The increased availability of continuous video-EEG and aEEG monitoring in diagnosis and treatment evaluation of neonatal seizures is offering more refined diagnostic and therapeutic approaches. Furthermore, biomarkers, such as semiology and EEG, are expected to play a new role in the context of genetic disease,²¹ and novel therapies^{123,124} deriving from laboratory research and aiming to minimize damage to the immature brain¹⁵³ are expected to improve long-term outcomes. Predictive models and scoring systems will have to adapt to this rapidly changing landscape of neonatal seizures and their outcomes.

The development of novel, disease-modifying, or antiepileptogenic therapies together with new neuroprotective agents will be crucial in improving the outcome of neonatal seizures.

Conclusion

Recent technological advances in diagnostics, including full EEG, aEEG, MRI, metabolic, and genetic testing, have improved seizure detection and etiologic classification in neonates. Meanwhile, ground-breaking preclinical research on the effects of seizures and antiseizure medication in the immature brain has improved our understanding of this complicated situation. However, little has changed in terms of treatment and, consequently, the long-term outcomes, with neonatal

seizures, continuing to pose a challenge for clinicians worldwide. Research must continue to facilitate the decoding of the mechanisms underlying neonatal seizures, advance their management by developing age-specific agents, and, ultimately, to improve long-term outcomes in affected infants.

Note

Part of this work was presented at the Symposium *Neonatal seizures—update*, in Zurich, Switzerland, June 24, 2016.

Funding

This work did not receive support from a grant or otherwise.

Conflicts of Interest

The authors have no conflict of interest to disclose.

References

- Volpe JJ. *Neurology of the Newborn*. 5th Edition. Philadelphia, PA: Elsevier Ltd.; 2008
- Pisani F, Cerminara C, Fusco C, Sisti L. Neonatal status epilepticus vs recurrent neonatal seizures: clinical findings and outcome. *Neurology* 2007;69(23):2177–2185
- Pisani F, Barilli AL, Sisti L, Bevilacqua G, Seri S. Preterm infants with video-EEG confirmed seizures: outcome at 30 months of age. *Brain Dev* 2008;30(01):20–30
- Berry K, Pesko MF, Hesdorffer DC, Shellhaas RA, Seirup JK, Grinspan ZM. An evaluation of national birth certificate data for neonatal seizure epidemiology. *Epilepsia* 2017;58(03):446–455
- Lanska MJ, Lanska DJ, Baumann RJ, Kryscio RJ. A population-based study of neonatal seizures in Fayette County, Kentucky. *Neurology* 1995;45(04):724–732
- Glass HC, Shellhaas RA, Wusthoff CJ, et al; Neonatal Seizure Registry Study Group. Contemporary profile of seizures in neonates: a prospective cohort study. *J Pediatr* 2016;174:98–103.e1
- Saliba RM, Annegers FJ, Waller DK, Tyson JE, Mizrahi EM. Risk factors for neonatal seizures: a population-based study, Harris County, Texas, 1992–1994. *Am J Epidemiol* 2001;154(01):14–20
- Ronen GM, Buckley D, Penney S, Streiner DL. Long-term prognosis in children with neonatal seizures: a population-based study. *Neurology* 2007;69(19):1816–1822
- Kohelet D, Shochat R, Lusky A, Reichman B; Israel Neonatal Network. Risk factors for neonatal seizures in very low birth-weight infants: population-based survey. *J Child Neurol* 2004;19(02):123–128
- Ramantani G. Neonatal epilepsy and underlying aetiology: to what extent do seizures and EEG abnormalities influence outcome? *Epileptic Disord* 2013;15(04):365–375
- Silverstein FS, Jensen FE. Neonatal seizures. *Ann Neurol* 2007;62(02):112–120
- Boylan GB, Stevenson NJ, Vanhatalo S. Monitoring neonatal seizures. *Semin Fetal Neonatal Med* 2013;18(04):202–208
- Mizrahi EM, Kellaway P. Characterization and classification of neonatal seizures. *Neurology* 1987;37(12):1837–1844
- Berg AT, Berkovic SF, Brodie MJ, et al. Revised terminology and concepts for organization of seizures and epilepsies: report of the ILAE Commission on Classification and Terminology, 2005–2009. *Epilepsia* 2010;51(04):676–685
- From the Commission on Classification and Terminology of the International League Against Epilepsy. Proposal for revised clinical and electroencephalographic classification of epileptic seizures. *Epilepsia* 1981;22(04):489–501

- 16 Volpe JJ. Neonatal seizures: current concepts and revised classification. *Pediatrics* 1989;84(03):422–428
- 17 Fisher RS, Cross JH, French JA, et al. Operational classification of seizure types by the International League against Epilepsy: position paper of the ILAE Commission for Classification and Terminology. *Epilepsia* 2017;58(04):522–530
- 18 Fisher RS, Cross JH, D'Souza C, et al. Instruction manual for the ILAE 2017 operational classification of seizure types. *Epilepsia* 2017;58(04):531–542
- 19 Sivaswamy L. Approach to neonatal seizures. *Clin Pediatr (Phila)* 2012;51(05):415–425
- 20 Nagarajan L, Palumbo L, Ghosh S. Classification of clinical semiology in epileptic seizures in neonates. *Eur J Paediatr Neurol* 2012;16(02):118–125
- 21 Shellhaas RA, Wusthoff CJ, Tsuchida TN, et al; Neonatal Seizure Registry. Profile of neonatal epilepsies: characteristics of a prospective US cohort. *Neurology* 2017;89(09):893–899
- 22 Grinton BE, Heron SE, Pelekanos JT, et al. Familial neonatal seizures in 36 families: clinical and genetic features correlate with outcome. *Epilepsia* 2015;56(07):1071–1080
- 23 Watanabe K. Seizures in the newborn and young infants. *Folia Psychiatr Neurol Jpn* 1981;35(03):275–280
- 24 Van Hove JLK, Lohr NJ. Metabolic and monogenic causes of seizures in neonates and young infants. *Mol Genet Metab* 2011;104(03):214–230
- 25 Ronen GM, Rosales TO, Connolly M, Anderson VE, Leppert M. Seizure characteristics in chromosome 20 benign familial neonatal convulsions. *Neurology* 1993;43(07):1355–1360
- 26 Zara F, Specchio N, Striano P, et al. Genetic testing in benign familial epilepsies of the first year of life: clinical and diagnostic significance. *Epilepsia* 2013;54(03):425–436
- 27 Soldovieri MV, Boutry-Kryza N, Milh M, et al. Novel KCNQ2 and KCNQ3 mutations in a large cohort of families with benign neonatal epilepsy: first evidence for an altered channel regulation by syntaxin-1A. *Hum Mutat* 2014;35(03):356–367
- 28 Pisano T, Numis AL, Heavin SB, et al. Early and effective treatment of KCNQ2 encephalopathy. *Epilepsia* 2015;56(05):685–691
- 29 Concolino D, Iembo MA, Rossi E, et al. Familial pericentric inversion of chromosome 5 in a family with benign neonatal convulsions. *J Med Genet* 2002;39(03):214–216
- 30 Vigeveno F. Benign familial infantile seizures. *Brain Dev* 2005;27(03):172–177
- 31 Nunes ML, Yozawitz EG, Zuberi S, et al; Task Force on Neonatal Seizures, ILAE Commission on Classification & Terminology. Neonatal seizures: is there a relationship between ictal electroclinical features and etiology? A critical appraisal based on a systematic literature review. *Epilepsia Open* 2019;4(01):10–29
- 32 Cusmai R, Martinelli D, Moavero R, et al. Ketogenic diet in early myoclonic encephalopathy due to non ketotic hyperglycinemia. *Eur J Paediatr Neurol* 2012;16(05):509–513
- 33 Porri S, Fluss J, Plecko B, Paschke E, Korff CM, Kern I. Positive outcome following early diagnosis and treatment of pyridoxal-5'-phosphate oxidase deficiency: a case report. *Neuropediatrics* 2014;45(01):64–68
- 34 Schulzke S, Weber P, Luetsch J, Fahnenstich H. Incidence and diagnosis of unilateral arterial cerebral infarction in newborn infants. *J Perinat Med* 2005;33(02):170–175
- 35 Low E, Mathieson SR, Stevenson NJ, et al. Early postnatal EEG features of perinatal arterial ischaemic stroke with seizures. *PLoS One* 2014;9(07):e100973
- 36 Weckhuysen S, Ivanovic V, Hendrickx R, et al; KCNQ2 Study Group. Extending the KCNQ2 encephalopathy spectrum: clinical and neuroimaging findings in 17 patients. *Neurology* 2013;81(19):1697–1703
- 37 Serino D, Specchio N, Pontrelli G, Vigeveno F, Fusco L. Video/EEG findings in a KCNQ2 epileptic encephalopathy: a case report and revision of literature data. *Epileptic Disord* 2013;15(02):158–165
- 38 Numis AL, Angriman M, Sullivan JE, et al. KCNQ2 encephalopathy: delineation of the electroclinical phenotype and treatment response. *Neurology* 2014;82(04):368–370
- 39 Schmitt B, Baumgartner M, Mills PB, et al. Seizures and paroxysmal events: symptoms pointing to the diagnosis of pyridoxine-dependent epilepsy and pyridoxine phosphate oxidase deficiency. *Dev Med Child Neurol* 2010;52(07):e133–e142
- 40 Milh M, Villeneuve N, Chouchane M, et al. Epileptic and nonepileptic features in patients with early onset epileptic encephalopathy and STXBP1 mutations. *Epilepsia* 2011;52(10):1828–1834
- 41 Mizrahi EM, Kellaway P. Diagnosis and Management of Neonatal Seizures. Philadelphia, PA: Lippincott-Raven Publishers; 1998
- 42 Tsuchida TN, Wusthoff CJ, Shellhaas RA, et al; American Clinical Neurophysiology Society Critical Care Monitoring Committee. American clinical neurophysiology society standardized EEG terminology and categorization for the description of continuous EEG monitoring in neonates: report of the American Clinical Neurophysiology Society critical care monitoring committee. *J Clin Neurophysiol* 2013;30(02):161–173
- 43 Nagarajan L, Palumbo L, Ghosh S. Brief electroencephalography rhythmic discharges (BERDs) in the neonate with seizures: their significance and prognostic implications. *J Child Neurol* 2011;26(12):1529–1533
- 44 Shewmon DA. What is a neonatal seizure? Problems in definition and quantification for investigative and clinical purposes. *J Clin Neurophysiol* 1990;7(03):315–368
- 45 Fenichel GM. Neonatal Neurology. 4th ed. London, United Kingdom: Churchill Livingstone; 2006
- 46 Scher MS, Hamid MY, Steppe DA, Beggarly ME, Painter MJ. Ictal and interictal electrographic seizure durations in preterm and term neonates. *Epilepsia* 1993;34(02):284–288
- 47 Nagarajan L, Ghosh S, Palumbo L. Ictal electroencephalograms in neonatal seizures: characteristics and associations. *Pediatr Neurol* 2011;45(01):11–16
- 48 Ohtahara S, Yamatogi Y. Ohtahara syndrome: with special reference to its developmental aspects for differentiating from early myoclonic encephalopathy. *Epilepsy Res* 2006;70(Suppl 1):S58–S67
- 49 Djukic A, Lado FA, Shinnar S, Moshé SL. Are early myoclonic encephalopathy (EME) and the Ohtahara syndrome (EIEE) independent of each other? *Epilepsy Res* 2006;70(Suppl 1):S68–S76
- 50 Yamatogi Y, Ohtahara S. Early-infantile epileptic encephalopathy with suppression-bursts, Ohtahara syndrome; its overview referring to our 16 cases. *Brain Dev* 2002;24(01):13–23
- 51 Beal JC, Cherian K, Moshe SL. Early-onset epileptic encephalopathies: Ohtahara syndrome and early myoclonic encephalopathy. *Pediatr Neurol* 2012;47(05):317–323
- 52 Olson HE, Kelly M, LaCoursiere CM, et al. Genetics and genotype-phenotype correlations in early onset epileptic encephalopathy with burst suppression. *Ann Neurol* 2017;81(03):419–429
- 53 Nakamura K, Kato M, Osaka H, et al. Clinical spectrum of SCN2A mutations expanding to Ohtahara syndrome. *Neurology* 2013;81(11):992–998
- 54 Pavone P, Spalice A, Polizzi A, Parisi P, Ruggieri M. Ohtahara syndrome with emphasis on recent genetic discovery. *Brain Dev* 2012;34(06):459–468
- 55 Saito H, Kato M, Mizuguchi T, et al. De novo mutations in the gene encoding STXBP1 (MUNC18-1) cause early infantile epileptic encephalopathy. *Nat Genet* 2008;40(06):782–788
- 56 Saito H, Kato M, Okada I, et al. STXBP1 mutations in early infantile epileptic encephalopathy with suppression-burst pattern. *Epilepsia* 2010;51(12):2397–2405
- 57 Marques I, Sá MJ, Soares G, et al. Unraveling the pathogenesis of ARX polyalanine tract variants using a clinical and molecular interfacing approach. *Mol Genet Genomic Med* 2015;3(03):203–214

- 58 Kodera H, Ohba C, Kato M, et al. De novo GABRA1 mutations in Ohtahara and West syndromes. *Epilepsia* 2016;57(04):566–573
- 59 Ohba C, Kato M, Takahashi N, et al. De novo KCNT1 mutations in early-onset epileptic encephalopathy. *Epilepsia* 2015;56(09):e121–e128
- 60 Allen NM, Conroy J, Shahwan A, et al. Unexplained early onset epileptic encephalopathy: exome screening and phenotype expansion. *Epilepsia* 2016;57(01):e12–e17
- 61 Allen AS, Berkovic SF, Cossette P, et al; Epi4K Consortium; Epilepsy Phenome/Genome Project. De novo mutations in epileptic encephalopathies. *Nature* 2013;501(7466):217–221
- 62 Veeramah KR, Johnstone L, Karafet TM, et al. Exome sequencing reveals new causal mutations in children with epileptic encephalopathies. *Epilepsia* 2013;54(07):1270–1281
- 63 Berg AT, Coryell J, Saneto RP, et al. Early-life epilepsies and the emerging role of genetic testing. *JAMA Pediatr* 2017;171(09):863–871
- 64 Epi PM; EpiPM Consortium. A roadmap for precision medicine in the epilepsies. *Lancet Neurol* 2015;14(12):1219–1228
- 65 Toet MC, van der Meij W, de Vries LS, Uiterwaal CSPM, van Huffelen KC. Comparison between simultaneously recorded amplitude integrated electroencephalogram (cerebral function monitor) and standard electroencephalogram in neonates. *Pediatrics* 2002;109(05):772–779
- 66 Murray DM, Boylan GB, Ali I, Ryan CA, Murphy BP, Connolly S. Defining the gap between electrographic seizure burden, clinical expression and staff recognition of neonatal seizures. *Arch Dis Child Fetal Neonatal Ed* 2008;93(03):F187–F191
- 67 Frenkel N, Friger M, Meledin I, et al. Neonatal seizure recognition—comparative study of continuous-amplitude integrated EEG versus short conventional EEG recordings. *Clin Neurophysiol* 2011;122(06):1091–1097
- 68 Rennie JM, Chorley G, Boylan GB, Pressler R, Nguyen Y, Hooper R. Non-expert use of the cerebral function monitor for neonatal seizure detection. *Arch Dis Child Fetal Neonatal Ed* 2004;89(01):F37–F40
- 69 Shellhaas RA, Soaita AI, Clancy RR. Sensitivity of amplitude-integrated electroencephalography for neonatal seizure detection. *Pediatrics* 2007;120(04):770–777
- 70 Shah DK, Mackay MT, Lavery S, et al. Accuracy of bedside electroencephalographic monitoring in comparison with simultaneous continuous conventional electroencephalography for seizure detection in term infants. *Pediatrics* 2008;121(06):1146–1154
- 71 Shellhaas RA, Barks AK. Impact of amplitude-integrated electroencephalograms on clinical care for neonates with seizures. *Pediatr Neurol* 2012;46(01):32–35
- 72 Temko A, Lightbody G. Detecting neonatal seizures with computer algorithms. *J Clin Neurophysiol* 2016;33(05):394–402
- 73 Shah DK, Boylan GB, Rennie JM. Monitoring of seizures in the newborn. *Arch Dis Child Fetal Neonatal Ed* 2012;97(01):F65–F69
- 74 van Rooij LGM, Toet MC, van Huffelen AC, et al. Effect of treatment of subclinical neonatal seizures detected with aEEG: randomized, controlled trial. *Pediatrics* 2010;125(02):e358–e366
- 75 Toet MC, Groenendaal F, Osredkar D, van Huffelen AC, de Vries LS. Postneonatal epilepsy following amplitude-integrated EEG-detected neonatal seizures. *Pediatr Neurol* 2005;32(04):241–247
- 76 Srinivasakumar P, Zempel J, Trivedi S, et al. Treating EEG seizures in hypoxic ischemic encephalopathy: a randomized controlled trial. *Pediatrics* 2015;136(05):e1302–e1309
- 77 Tekgul H, Gauvreau K, Soul J, et al. The current etiologic profile and neurodevelopmental outcome of seizures in term newborn infants. *Pediatrics* 2006;117(04):1270–1280
- 78 Barnette AR, Horbar JD, Soll RF, et al. Neuroimaging in the evaluation of neonatal encephalopathy. *Pediatrics* 2014;133(06):e1508–e1517
- 79 Weeke LC, Van Rooij LGM, Toet MC, Groenendaal F, de Vries LS. Neuroimaging in neonatal seizures. *Epileptic Disord* 2015;17(01):1–11, quiz 11
- 80 Weeke LC, Groenendaal F, Toet MC, et al. The aetiology of neonatal seizures and the diagnostic contribution of neonatal cerebral magnetic resonance imaging. *Dev Med Child Neurol* 2015;57(03):248–256
- 81 Osmond E, Billetop A, Jary S, Likeman M, Thoresen M, Luyt K. Neonatal seizures: magnetic resonance imaging adds value in the diagnosis and prediction of neurodisability. *Acta Paediatr* 2014;103(08):820–826
- 82 Zand DJ, Simon EM, Pulitzer SB, et al. In vivo pyruvate detected by MR spectroscopy in neonatal pyruvate dehydrogenase deficiency. *AJNR Am J Neuroradiol* 2003;24(07):1471–1474
- 83 Bianchi MC, Tosetti M, Battini R, et al. Proton MR spectroscopy of mitochondrial diseases: analysis of brain metabolic abnormalities and their possible diagnostic relevance. *AJNR Am J Neuroradiol* 2003;24(10):1958–1966
- 84 Rincon SP, Blitstein MBK, Caruso PA, González RG, Thibert RL, Ratai E-M. The Use of Magnetic Resonance Spectroscopy in the Evaluation of Pediatric Patients With Seizures. *Pediatr Neurol* 2016;58:57–66
- 85 Barkovich AJ, Baranski K, Vigneron D, et al. Proton MR spectroscopy for the evaluation of brain injury in asphyxiated, term neonates. *AJNR Am J Neuroradiol* 1999;20(08):1399–1405
- 86 Amess PN, Penrice J, Wylezinska M, et al. Early brain proton magnetic resonance spectroscopy and neonatal neurology related to neurodevelopmental outcome at 1 year in term infants after presumed hypoxic-ischaemic brain injury. *Dev Med Child Neurol* 1999;41(07):436–445
- 87 Hanrahan JD, Cox JJ, Azzopardi D, et al. Relation between proton magnetic resonance spectroscopy within 18 hours of birth asphyxia and neurodevelopment at 1 year of age. *Dev Med Child Neurol* 1999;41(02):76–82
- 88 Cheong JLY, Cady EB, Penrice J, Wyatt JS, Cox JJ, Robertson NJ. Proton MR spectroscopy in neonates with perinatal cerebral hypoxic-ischemic injury: metabolite peak-area ratios, relaxation times, and absolute concentrations. *AJNR Am J Neuroradiol* 2006;27(07):1546–1554
- 89 Fan G, Wu Z, Chen L, Guo Q, Ye B, Mao J. Hypoxia-ischemic encephalopathy in full-term neonate: correlation proton MR spectroscopy with MR imaging. *Eur J Radiol* 2003;45(02):91–98
- 90 Lynch NE, Stevenson NJ, Livingstone V, Murphy BP, Rennie JM, Boylan GB. The temporal evolution of electrographic seizure burden in neonatal hypoxic ischemic encephalopathy. *Epilepsia* 2012;53(03):549–557
- 91 Painter MJ, Scher MS, Stein AD, et al. Phenobarbital compared with phenytoin for the treatment of neonatal seizures. *N Engl J Med* 1999;341(07):485–489
- 92 Boylan GB, Rennie JM, Pressler RM, Wilson G, Morton M, Binnie CD. Phenobarbitone, neonatal seizures, and video-EEG. *Arch Dis Child Fetal Neonatal Ed* 2002;86(03):F165–F170
- 93 Pressler RM, Boylan GB, Marlow N, et al; NEONatal seizure treatment with Medication Off-patent (NEMO) consortium. Bumetanide for the treatment of seizures in newborn babies with hypoxic ischaemic encephalopathy (NEMO): an open-label, dose finding, and feasibility phase 1/2 trial. *Lancet Neurol* 2015;14(05):469–477
- 94 Abend NS, Gutierrez-Colina AM, Monk HM, Dlugos DJ, Clancy RR. Levetiracetam for treatment of neonatal seizures. *J Child Neurol* 2011;26(04):465–470
- 95 Mathieson SR, Stevenson NJ, Low E, et al. Validation of an automated seizure detection algorithm for term neonates. *Clin Neurophysiol* 2016;127(01):156–168
- 96 Efficacy of intravenous levetiracetam in neonatal seizures (NEOLEV2). Available from: <https://clinicaltrials.gov/ct2/show/NCT01720667>

- 97 Low E, Boylan GB, Mathieson SR, et al. Cooling and seizure burden in term neonates: an observational study. *Arch Dis Child Fetal Neonatal Ed* 2012;97(04):F267–F272
- 98 Wusthoff CJ, Dlugos DJ, Gutierrez-Colina A, et al. Electrographic seizures during therapeutic hypothermia for neonatal hypoxic-ischemic encephalopathy. *J Child Neurol* 2011;26(06):724–728
- 99 Glass HC, Wusthoff CJ, Shellhaas RA, et al. Risk factors for EEG seizures in neonates treated with hypothermia: a multicenter cohort study. *Neurology* 2014;82(14):1239–1244
- 100 Kharoshankaya L, Stevenson NJ, Livingstone V, et al. Seizure burden and neurodevelopmental outcome in neonates with hypoxic-ischemic encephalopathy. *Dev Med Child Neurol* 2016;58(12):1242–1248
- 101 Dulac O, Plecko B, Gataullina S, Wolf NI. Occasional seizures, epilepsy, and inborn errors of metabolism. *Lancet Neurol* 2014;13(07):727–739
- 102 Scheffer IE. Epilepsy genetics revolutionizes clinical practice. *Neuropediatrics* 2014;45(02):70–74
- 103 Campistol J, Plecko B. Treatable newborn and infant seizures due to inborn errors of metabolism. *Epileptic Disord* 2015;17(03):229–242
- 104 Stockler S, Plecko B, Gospe SM Jr, et al. Pyridoxine dependent epilepsy and antiquitin deficiency: clinical and molecular characteristics and recommendations for diagnosis, treatment and follow-up. *Mol Genet Metab* 2011;104(1,2):48–60
- 105 Mills PB, Camuzeaux SSM, Footitt EJ, et al. Epilepsy due to PNPO mutations: genotype, environment and treatment affect presentation and outcome. *Brain* 2014;137(Pt 5):1350–1360
- 106 Darin N, Reid E, Prunetti L, et al. Mutations in PROSC Disrupt Cellular Pyridoxal Phosphate Homeostasis and Cause Vitamin-B₆-Dependent Epilepsy. *Am J Hum Genet* 2016;99(06):1325–1337
- 107 Plecko B, Zweier M, Begemann A, et al. Confirmation of mutations in PROSC as a novel cause of vitamin B₆-dependent epilepsy. *J Med Genet* 2017;54(12):809–814
- 108 Baumgartner-Sigl S, Haberlandt E, Mumm S, et al. Pyridoxine-responsive seizures as the first symptom of infantile hypophosphatasia caused by two novel missense mutations (c.677T>C, p.M226T; c.1112C>T, p.T371I) of the tissue-nonspecific alkaline phosphatase gene. *Bone* 2007;40(06):1655–1661
- 109 Stence NV, Coughlin CR II, Fenton LZ, Thomas JA. Distinctive pattern of restricted diffusion in a neonate with molybdenum cofactor deficiency. *Pediatr Radiol* 2013;43(07):882–885
- 110 Schwahn BC, Van Spronsen FJ, Belaidi AA, et al. Efficacy and safety of cyclic pyranopterin monophosphate substitution in severe molybdenum cofactor deficiency type A: a prospective cohort study. *Lancet* 2015;386(10007):1955–1963
- 111 McTague A, Howell KB, Cross JH, Kurian MA, Scheffer IE. The genetic landscape of the epileptic encephalopathies of infancy and childhood. *Lancet Neurol* 2016;15(03):304–316
- 112 Stamberger H, Nikanorova M, Willemsen MH, et al. STXBP1 encephalopathy: A neurodevelopmental disorder including epilepsy. *Neurology* 2016;86(10):954–962
- 113 Trump N, McTague A, Brittain H, et al. Improving diagnosis and broadening the phenotypes in early-onset seizure and severe developmental delay disorders through gene panel analysis. *J Med Genet* 2016;53(05):310–317
- 114 Pisani F, Percesepe A, Spagnoli C. Genetic diagnosis in neonatal-onset epilepsies: Back to the future. *Eur J Paediatr Neurol* 2018;22(03):354–357
- 115 Pressler RM, Mangum B. Newly emerging therapies for neonatal seizures. *Semin Fetal Neonatal Med* 2013;18(04):216–223
- 116 Booth D, Evans DJ. Anticonvulsants for neonates with seizures. *Cochrane Database Syst Rev* 2004;(04):CD004218
- 117 Weeke LC, Toet MC, van Rooij LGM, et al. Lidocaine response rate in aEEG-confirmed neonatal seizures: Retrospective study of 413 full-term and preterm infants. *Epilepsia* 2016;57(02):233–242
- 118 van Rooij LGM, Toet MC, Rademaker KMA, Groenendaal F, de Vries LS. Cardiac arrhythmias in neonates receiving lidocaine as anticonvulsive treatment. *Eur J Pediatr* 2004;163(11):637–641
- 119 Donovan MD, Griffin BT, Kharoshankaya L, Cryan JF, Boylan GB. Pharmacotherapy for neonatal seizures: current knowledge and future perspectives. *Drugs* 2016;76(06):647–661
- 120 van den Broek MPH, Rademaker CMA, van Straaten HLM, et al. Anticonvulsant treatment of asphyxiated newborns under hypothermia with lidocaine: efficacy, safety and dosing. *Arch Dis Child Fetal Neonatal Ed* 2013;98(04):F341–F345
- 121 van den Broek MPH, Huitema AD, van Hasselt JGC, et al. Lidocaine (lignocaine) dosing regimen based upon a population pharmacokinetic model for preterm and term neonates with seizures. *Clin Pharmacokinet* 2011;50(07):461–469
- 122 Weeke LC, Schalkwijk S, Toet MC, van Rooij LGM, de Vries LS, van den Broek MPH. Lidocaine-associated cardiac events in newborns with seizures: incidence, symptoms and contributing factors. *Neonatology* 2015;108(02):130–136
- 123 Ramantani G, Ikonomidou C, Walter B, Rating D, Dinger J. Levetiracetam: safety and efficacy in neonatal seizures. *Eur J Paediatr Neurol* 2011;15(01):1–7
- 124 Fürwentsches A, Bussmann C, Ramantani G, et al. Levetiracetam in the treatment of neonatal seizures: a pilot study. *Seizure* 2010;19(03):185–189
- 125 Glass HC, Poulin C, Shevell MI. Topiramate for the treatment of neonatal seizures. *Pediatr Neurol* 2011;44(06):439–442
- 126 Soul JS, Bergin AM, Stopp C, et al. Randomized, controlled, double-blind trial of bumetanide for neonatal seizures. Abstract 2.426. Washington DC: 2017
- 127 Haas RH, Nespeca M, Rismanchi N, et al. Efficacy of intravenous levetiracetam in neonatal seizures: NEOLEV2—a multicenter, randomized, blinded, controlled phase IIb trial of the optimal dose, efficacy, and safety of levetiracetam compared with phenobarbital in the first-line treatment of neonatal seizures. In: E-PAS2019: 1770.1. Baltimore, MD: 2019. <https://app.core-apps.com/pas2019/abstract/286d6c3548dd83e5cc4e8edf1c3b8dc3>. Accessed July 19, 2019
- 128 Sharpe C, Davis SL, Reiner GE, et al. Assessing the feasibility of providing a real-time response to seizures detected with continuous long-term neonatal electroencephalography monitoring. *J Clin Neurophysiol* 2019;36(01):9–13
- 129 Slaughter LA, Patel AD, Slaughter JL. Pharmacological treatment of neonatal seizures: a systematic review. *J Child Neurol* 2013;28(03):351–364
- 130 Shellhaas RA, Chang T, Wusthoff CJ, et al; Neonatal Seizure Registry Study Group. Treatment duration after acute symptomatic seizures in neonates: a multicenter cohort study. *J Pediatr* 2017;181:298–301.e1
- 131 Farwell JR, Lee YJ, Hirtz DG, Sulzbacher SI, Ellenberg JH, Nelson KB. Phenobarbital for febrile seizures—effects on intelligence and on seizure recurrence. *N Engl J Med* 1990;322(06):364–369
- 132 Camfield CS, Chaplin S, Doyle AB, Shapiro SH, Cummings C, Camfield PR. Side effects of phenobarbital in toddlers; behavioral and cognitive aspects. *J Pediatr* 1979;95(03):361–365
- 133 Ikonomidou C, Turski L. Antiepileptic drugs and brain development. *Epilepsy Res* 2010;88(01):11–22
- 134 Andreolli A, Turco EC, Pedrazzi G, Beghi E, Pisani F. Incidence of epilepsy after neonatal seizures: a population-based study. *Neuroepidemiology* 2019;52(3,4):144–151
- 135 Yıldız EP, Tatlı B, Ekici B, et al. Evaluation of etiologic and prognostic factors in neonatal convulsions. *Pediatr Neurol* 2012;47(03):186–192
- 136 Shah DK, Zempel J, Barton T, Lukas K, Inder TE. Electrographic seizures in preterm infants during the first week of life are associated with cerebral injury. *Pediatr Res* 2010;67(01):102–106
- 137 Pisani F, Spagnoli C. Neonatal seizures: a review of outcomes and outcome predictors. *Neuropediatrics* 2016;47(01):12–19

- 138 Pisani F, Facini C, Pelosi A, Mazzotta S, Spagnoli C, Pavlidis E. Neonatal seizures in preterm newborns: a predictive model for outcome. *Eur J Paediatr Neurol* 2016;20(02):243–251
- 139 Nardou R, Ferrari DC, Ben-Ari Y. Mechanisms and effects of seizures in the immature brain. *Semin Fetal Neonatal Med* 2013;18(04):175–184
- 140 Glass HC, Glidden D, Jeremy RJ, Barkovich AJ, Ferriero DM, Miller SP. Clinical neonatal seizures are independently associated with outcome in infants at risk for hypoxic-ischemic brain injury. *J Pediatr* 2009;155(03):318–323
- 141 Miller SP, Weiss J, Barnwell A, et al. Seizure-associated brain injury in term newborns with perinatal asphyxia. *Neurology* 2002;58(04):542–548
- 142 Holmes GL. Effects of seizures on brain development: lessons from the laboratory. *Pediatr Neurol* 2005;33(01):1–11
- 143 Ben-Ari Y, Holmes GL. Effects of seizures on developmental processes in the immature brain. *Lancet Neurol* 2006;5(12):1055–1063
- 144 Brooks-Kayal AR. Rearranging receptors. *Epilepsia* 2005;46 (Suppl 7):29–38
- 145 Lee CL, Hannay J, Hrachovy R, Rashid S, Antalffy B, Swann JW. Spatial learning deficits without hippocampal neuronal loss in a model of early-onset epilepsy. *Neuroscience* 2001;107(01):71–84
- 146 Wirrell EC, Armstrong EA, Osman LD, Yager JY. Prolonged seizures exacerbate perinatal hypoxic-ischemic brain damage. *Pediatr Res* 2001;50(04):445–454
- 147 Young L, Berg M, Soll R. Prophylactic barbiturate use for the prevention of morbidity and mortality following perinatal asphyxia. *Cochrane Database Syst Rev* 2016;(05):CD001240
- 148 Pisani F, Sisti L, Seri S. A scoring system for early prognostic assessment after neonatal seizures. *Pediatrics* 2009;124(04):e580–e587
- 149 Garfinkle J, Shevell MI. Prognostic factors and development of a scoring system for outcome of neonatal seizures in term infants. *Eur J Paediatr Neurol* 2011;15(03):222–229
- 150 Anand V, Nair PMC. Neonatal seizures: predictors of adverse outcome. *J Pediatr Neurosci* 2014;9(02):97–99
- 151 Lai Y-H, Ho C-S, Chiu N-C, Tseng C-F, Huang Y-L. Prognostic factors of developmental outcome in neonatal seizures in term infants. *Pediatr Neonatol* 2013;54(03):166–172
- 152 Ellison PH, Largent JA, Bahr JP. A scoring system to predict outcome following neonatal seizures. *J Pediatr* 1981;99(03):455–459
- 153 Galanopoulou AS, Moshé SL. Neonatal and infantile epilepsy: acquired and genetic models. *Cold Spring Harb Perspect Med* 2015;6(01):a022707