



Evaluation of Clinical and Radiographic Results of Cemented Total Hip Arthroplasty in 477 Patients*

Avaliação dos resultados clínicos e radiográficos da artroplastia total cimentada do quadril em 477 pacientes

Guydo Marques Horta Duarte² Luiz Ronaldo Alberti¹

¹ Department of Surgery, Faculty of de Medicine, Universidade Federal de Minas Gerais, Belo Horizonte, MG, Brazil

² Hospital Governador Israel Pinheiro, Instituto de Previdência dos Servidores do Estado de Minas Gerais (IPSEMG), Belo Horizonte, MG, Brazil

Address for correspondence Guydo Marques Horta Duarte, PhD, Rua Ceará, 1152, apto. 301, Funcionários, Belo Horizonte, MG, 30150-311, Brazil (e-mail: guydomhd@gmail.com).

Rev Bras Ortop 2019;54:459–464.

Abstract

Objective The purpose of the present study was to evaluate retrospectively the clinical and radiographic results of total hip arthroplasty (THA) performed with the Exeter technique and using the Exeter prosthesis.

Methods Between March 2000 and December 2006, 504 THAs were performed in 477 patients, with several etiological diagnoses. A total of 260 surgeries were performed on the right side, 244 on the left side, and 27 were performed bilaterally. The mean age of the patients was 58.9 (17.7–86.8) years old, with a median of 69.0 years old. The preoperative planning was performed with appropriate templates. All of the surgeries were performed through the posterolateral approach with the patient placed on lateral decubitus. The clinical evaluation was performed according to the Harris hip score (HHS). In the radiographic evaluation, the bone cement interface in the three zones of DeLee and Charnley on the acetabular side and in the seven zones of Gruen on the femoral side were studied. Subsidence of the femoral component, presence of diaphyseal hypertrophy, and heterotopic ossification were also observed.

Results The mean follow-up of 441 surgeries (87.5%) was of 7.2 (1.0-16.6) years, with a median of 7.1 years. The incidence of complications was: dislocation, 3.2%; infection, 2.2%; peripheral nerve disorders 2.0%; thromboembolism 2.7%, acetabular cup loosening 2.0%; diaphyseal hypertrophy, 1.26%; distal migration of the femoral component between 2,0 mm and 2.9 mm, 0.5%; 1 case of aseptic loosening of the femoral component and 9 (1.8%) of the acetabular component. The mean HHS was mean 92.3 (50–100) points.


Keywords


- ▶ arthroplasty, replacement, hip
- ▶ hip prosthesis
- ▶ bone cement
- ▶ hip osteoarthritis
- ▶ hip joint

Introduction

In cemented total hip arthroplasty (THA), the interposition of an acrylic polymer, polymethylmethacrylate (PMMA), between the prosthetic components and the bone forms a composite. Definitive fixation results from growth and remodeling of

* Work performed at the Orthopedics Clinic of Hospital Governador Israel Pinheiro, IPSEMG, Belo Horizonte, MG, Brazil.

 Guydo Marques Horta Duarte's ORCID is <https://orcid.org/0000-0002-2154-2832>.

 Luiz Ronaldo Alberti's ORCID is <https://orcid.org/0000-0002-5229-3971>.

received
May 17, 2018
accepted
March 26, 2019

DOI <https://doi.org/10.1055/s-0039-1694045>.
ISSN 0102-3616.

Copyright © 2019 by Sociedade Brasileira de Ortopedia e Traumatologia. Published by Thieme Revnter Publicações Ltda, Rio de Janeiro, Brazil

License terms



Resumo

Palavras-chave

- ▶ artroplastia de quadril
- ▶ prótese de quadril
- ▶ cimentos para ossos
- ▶ osteoartrite do quadril
- ▶ articulação do quadril

Conclusion Cemented THA, with the methodology applied, proved to be an effective treatment for this group of patients. The results were satisfactory with acceptable complication rates.

Objetivo Avaliar os resultados da artroplastia total do quadril (ATQ) cimentada, com a utilização da técnica e prótese da escola Exeter.

Metódo Entre março de 2000 e dezembro de 2006, foram realizadas 504 ATQs em 477 pacientes, com diversos diagnósticos etiológicos, 260 à direita e 244 à esquerda, 27 bilaterais. A idade média foi de 58,9 (17,7–86,8) anos, com mediana de 69,0 anos. O planejamento radiográfico foi feito utilizando-se gabaritos apropriados. O acesso cirúrgico foi o posterolateral com o paciente em decúbito lateral. Para a avaliação clínica, foi utilizado o escore do quadril de Harris (EQH). Na avaliação radiográfica, foi estudada a interface osso cimento acetabular, nas três zonas de DeLee e Charnley e nas sete zonas de Gruen do lado femoral, a presença de migração distal do componente femoral, hipertrofia diafisária, e ossificação heterotópica.

Resultados O seguimento médio de 441 cirurgias (87,5%) foi de 7,2 (1,0–16,6) anos, com mediana de 7,1 anos. A incidência de complicações foi: luxação, 3,2%; infecção, 2,2%; tromboembolismo, 2,1%; disfunção de nervos periféricos 1,1%; hipertrofia diafisária, 1,5%; soltura do componente acetabular, 1,8%; migração distal do componente femoral entre 2,0 mm e 2,9 mm, 0,45%; 1 caso de soltura asséptica do componente femoral; e 1 caso de fratura da haste femoral. A pontuação média com o EQH foi de 92 pontos.

Conclusão A ATQ cimentada, com a metodologia utilizada, constituiu-se em uma opção eficaz para o tratamento deste grupo de pacientes, com resultados satisfatórios, com este tempo de seguimento.

the bone tissue around grooves and porosities created in the cement during the cementation technique, which mirrors the correctly prepared bone tissue.¹

After cementation, the bone tissue suffers reactions similar to those occurring during the healing process of a fracture. Therefore, the bone receiving the implant and providing its immediate stability is totally different from the one responsible for late stability after the interface remodeling phase. This variable, one of the main targets for cemented arthroplasty, is totally under the control of the surgeon through good cementation techniques and implant design choice.² As such, the success of cemented THA is highly dependent on the technique and implant type.³

The bone reacts to prosthetic implantation according to the Wolff law,⁴ that is, hypertrophy when submitted to mechanical stress, and atrophy in its absence. More physiological load transmissions by prosthetic system improve bone adaptation. This phenomenon is mainly dependent on implant design, surface polishing, composite/PMMA modulus of elasticity and its stability.⁵ The prosthetic system that best takes advantage of this bone tissue property is the cemented system, mainly because of its low modulus of elasticity.

Periodic clinical and radiographic monitoring after a THA is necessary to detect early changes in the bone/cement fixation interface on the acetabular and femoral sides. Since patients may remain asymptomatic for years, even during

periods of significant bone loss, early surgical revision is essential for bone stock preservation.⁶

The most important factors for a long durability of a cemented THA, with maintenance of the integrity of the fixation interfaces, are the meticulous observation to the surgical technique details, the implant quality, and the adhesion of the patients to postoperative protocols. Good technique means good results.⁷

Conditions that alter the acetabular shape and structure, causing concave or cavitory acetabular insufficiencies or volumetric increase of the acetabular cavity, which are not contained or segmental, as well as those characterized by the absence of one acetabular wall, must be treated simultaneously at the time of the arthroplasty through an associated acetabular bone reconstruction procedure. In acetabular defects, most authors agree that the component must be implanted in an anatomical position, repositioning the physiological center of hip rotation.^{7–11}

Total hip arthroplasty is a surgical procedure in constant evolution. The choice between different techniques and implants should be based on the most reliable test, which is the long-term clinical and radiographic outcomes, as those demonstrated in hip arthroplasty records from Norway¹² and in other relevant publications of results from other registries,¹³ showing the superior durability of cemented fixation in THA.

The present retrospective observational study of a cases series aims to report short- and medium-term outcomes of

cemented THA using the Exeter prosthesis and technique, all performed by the same surgeon, in an expressive group of populational-representative patients with several irreversible hip joint disorders requiring this type of procedure from a large hospital outpatient clinic.

Patients and Methods

The present study was registered in the Brazilian Committee for Research Ethics (CONEP, in the Portuguese acronym) and was approved by the Research Ethics Committee of our institution under the number 290/08-CAAE 0039.0.191.000-08.

A total of 504 THAs were performed in 477 patients, including 283 females and 194 males, 260 right hips and 244 left hips, from March 2000 to December 2006. Surgeries were bilaterally performed at different times in 27 patients. The mean age of the patients was 58.9 (17.7–86.8) years old, with a median value of 69.0 years old.

Exeter cemented prostheses (Stryker Orthopedics, Mahwah, NJ, USA) with 26 mm heads were used.

Thromboembolic phenomena prophylaxis was performed with unfractionated heparin, 5,000 IU every 12 hours by subcutaneous administration, or with low molecular weight heparin, 40 mg every 24 hours, also by the subcutaneous route, starting 12 hours before surgery and maintained until the 15th postoperative day.

A preoperative hip radiographic study was performed in anteroposterior (AP) view and 20% magnification for visualization of the proximal third of both femurs, with the lower limbs at an internal rotation of 15° and with the hip joint in AP and lateral views.

The preoperative radiographic planning (PRP) was performed using templates of the prosthetic components in 20% enlargement to determine the size and positioning of the acetabular components, the horizontal offset and dimension of the femoral component, the vertical offset to the upper end of the large trochanter, the cement mantle thickness and the intramedullary cement restrictor diameter.

Surgeries were performed using the posterior-lateral hip approach with the patient in lateral recumbency with pelvic supports.

In cases of peripheral acetabular insufficiency, acetabular defects were contained with metallic screens fixed with screws in the acetabular anterior and posterior walls and in the acetabular roof. The spongy graft obtained from the femoral head, chopped and ground, was vigorously impacted using the appropriate instruments.⁷⁻¹¹ Cavitary defects were also reconstructed with autologous, impacted cancellous bone graft.

Cephalothin was administered at a dose of 80 mg/kg/day by intravenous route, starting at anesthetic induction and maintained for 24 hours.

In patients with risk factors for heterotopic ossification, indomethacin was administered orally at a dose of 25 mg 3 times a day for 3 weeks. The classification of Brooker et al was used.¹⁴

All patients were instructed to return to the clinic for clinical and radiographic control at 6 weeks, 6 months and every 2 years postoperatively.

The patients were classified into infection risk categories (IRC) using the National Nosocomial Infection Surveillance (NNIS) methodology. This calculation generates only two results for a specific group of patients: either the infection rate is higher than expected, or equal to or lower than expected.¹⁵

In the postoperative radiographic evaluation, the integrity of the acetabular bone interfaces was observed in the three DeLee et al¹⁶ zones and in the seven Gruen¹⁷ zones on the femoral side. The presence of distal femoral component migration, diaphyseal hypertrophy and heterotopic ossification was also recorded. Components presenting contiguous radiolucent zones at the bone-cement interface in the three DeLee & Charnley zones and in the seven Gruen zones, with or without the presence of periprosthetic osteolysis, were considered loose.

The clinical results were assessed by the Harris hip score (HHS).¹⁸

Results

A total of 63 (13.2%) of the 477 patients did not return for follow-up.

The follow-up period of the 441 (87.5%) patients who returned to the outpatient clinic ranged from 1.0 year to a maximum of 16.6 years, with a mean value of 7.2 years and a median value of 7.1 years.

The preoperative etiological diagnosis of 477 patients is shown in ► **Table 1**.

A total of 98 arthroplasties (19.4%) were accompanied by the simultaneous reconstruction of acetabular insufficiencies.

The NNIS IRC score of the 504 surgeries is shown in ► **Table 2**.

The HHS ranged from 50 to 100 points, with an average value of 92.3 points.

The incidence of prosthesis dislocation in 504 arthroplasties was of 3.2% (16 surgeries).

The incidence of deep infections was of 2.2% (11 surgeries).

The incidences of femoral nerve and common fibular nerve dysfunction were, respectively, of 1.6% and 0.4%.

Deep venous thrombosis confirmed by ultrasound examination occurred in 3 patients (0.6%). The incidence of

Table 1 Etiological diagnosis in 477 patients

Preoperative diagnosis	n
Osteoarthritis	195 (40.9%)
Osteonecrosis	75 (15.7%)
Miscellaneous conditions	68 (14.3%)
Perthes disease sequelae	34 (7.1%)
Hip dysplasia sequelae	24 (5.2%)
Acetabular protrusion	24 (5.2%)
Rheumatoid arthritis sequelae	21 (4.4%)
Acetabular fracture sequelae	19 (3.2%)
Femoral neck fracture	18 (3.8%)

Table 2 Comparison between surgeon and expected rates

Procedure	Observed infections	Surgeries performed	NNIS rate	Expected infections
Arthroplasty - R 0	0	43	0.89	0.38
Arthroplasty - R 1	5	426	1.53	6.52
Arthroplasty - R 2,3	6	35	1.38	0.48
TOTAL	11	504	7.38	
Standardized Rate:	1.49			
0.9077 -> Infection number equal or lower than expected				

Abbreviations: NNIS, National Nosocomial Infection Surveillance; R, risk.

thromboembolism was 2.1% (10 patients), with 9 pulmonary cases and 1 encephalic case.

Six cases (1.2%) presented radiographic signs of demarcation in the acetabular bone-cement interface.

There were 9 cases (1.8%) of fixation loss with acetabular component loosening (1.8%). On the femoral side, it was observed in 1 case, 15 years after surgery, due to periprosthetic osteolysis induced by particles originating from polyethylene wear. Radiographic signs of demarcation in the bone-cement interface in the seven Gruen zones were not found in any other case.¹⁷

Signs of diaphyseal hypertrophy were recorded in 6 patients (1.3%) submitted to unilateral surgeries.

Signs of heterotopic ossification were observed in 22 postsurgical radiographic examinations, including 15 from type II and 7 from type III according to Booker et al.¹⁴

The femoral component of a male patient was fractured at the 33rd postoperative month due to the lack of proximal component fixation with distal fixation maintenance resulting from the fragmentation of the medial cement mantle in Gruen zone 7 and in part of zone 6.¹⁷ This fragmentation was attributed to successive falls related to alcoholism.

Distal stem migration was observed in 77 cases, with no pain complaint (► **Table 3**).

Discussion

The present study aimed to evaluate the clinical and radiographic results from THA in a population of patients of both genders, regardless of age group and with several etiological diagnoses. Those 477 individuals were representative of the population requiring this type of surgery regarding the pathological, socioeconomic, and cultural context. Since the outcomes from this procedure depend not only on technical, human and material resources, one would expect that they would be different if a specific portion of individuals with similar social, economic and pathological backgrounds were selected. The equally important variables which influenced the outcomes and were standardized in the studied group included the type of prosthesis, the quality of bone cement, the surgical technique, the cementation technique, and the surgeon.

The prevalence of THA complications has decreased over the years, with a consequent increase in durability, due to advances in surgical, anesthetic, materials and implant de-

Table 3 Stem subsidence in 77 arthroplasties

Stem subsidence (mm)	n
< 1.0	61 (44.5%)
1.0 to 1.9	14 (10.2%)
2.0 to 2.9	02 (1.5%)

sign techniques. However, poor component positioning, non-reestablishment of the hip biomechanical relationships, and limbs anisomelia (all dependent on the surgical technique and on PRP) remain important concerns.¹⁹ Thus, PRP is paramount in THA because it allows for a greater predictability of the outcomes and decreases the incidence of several complications. The first step in the arthroplasty technique is careful planning, with great attention to all clinical and radiographic findings details.

Cemented THA is highly dependent on the cementation technique and on the surgeon performing it.² To achieve a mechanically efficient interface, the bone tissue must be adequately prepared and rendered receptive to the cement using pulsatile lavage, hemostatic agents (such as an epinephrine or hydrogen peroxide solution) and hypotensive anesthesia, in order to reduce bleeding on both the acetabular and the femoral side. Cancellous bone preservation is also very important. Bone cement should be vigorously pressurized prior to, during, and after the insertion of the component, avoiding its mixture with blood or with other debris as much as possible. The pressurization must be maintained, with appropriate devices, until the end of the polymerization reaction, both on the acetabular and on the femoral side. Attention to all technical details is fundamental to achieve an efficient interface, both mechanically and histologically. The quality of cementation obtained in the immediate postoperative period,¹ analyzed radiographically, evidencing absence of demarcation lines at the bone-cement interface, has a predictive value of good prognosis, not requiring 15 to 20 years of follow-up to conclude that the procedure was successful.^{20,21}

Treatment of acetabular defects with the impacted graft technique allowed an anatomical reconstruction with reestablishment of biomechanical relationships (► **Figure 1**)

The overall incidence of infections after arthroplasties has decreased substantially from almost 10% in the 1970s to the current 0.3 to 1.5% because of the adoption of prophylactic measures, of identification and treatment of risk factors and

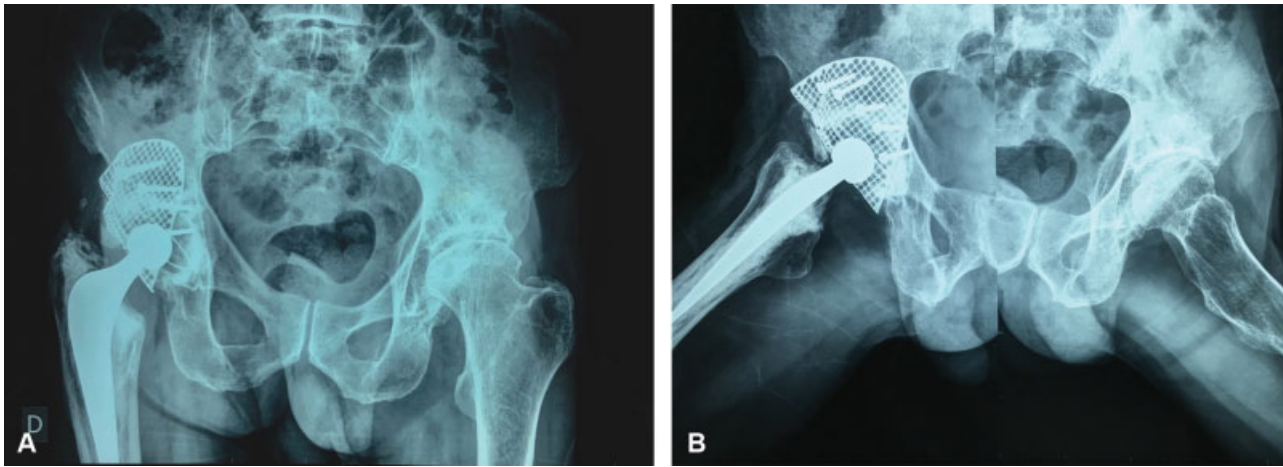


Fig. 1 Postoperative radiographs in anteroposterior and lateral view of a 61-year-old male patient with osteoarthritis secondary to Legg-Calvé-Perthes disease submitted to right acetabular peripheral segmental defect reconstruction and cemented total hip arthroplasty after 16 years of evolution.

of surgical technique improvements.²² In our study, the incidence of deep infections (2.2%) is slightly above the average described in the international literature. However, this infection index interpreted with the NNIS system methodology in our group of patients was considered equal to or lower than expected.

The incidence of peripheral nerve dysfunction (1.6%) agrees with literature reports.²³

The incidence of deep venous thrombosis, of 0.60%, was probably underestimated because the typical clinical picture often is not suggestive. The incidence of thromboembolism of 2.1% agrees with most published series.

Nine patients (1.8%) presented with loss of fixation of the acetabular component requiring surgical revision with acetabular component replacement. In six patients, bone cement

interface demarcation signals were observed without clinical manifestations.

A total of 3.0% issues were observed, with either acetabular component loosening or loosening signals, a case of femoral component stem fracture associated with several falls due to alcoholism, and a case of femoral component loosening due to osteolysis induced by particles generated at the joint interface; these problems indicate that technical improvements are required on the acetabular side despite the recent advances and good outcomes obtained so far.^{21,24,25} After 2006, the last year in which the patients of the present study were operated, there were very significant changes in the design of acetabular components, of instrumentation, and of surgical technique; as such, the current outcomes are superior in terms of fixation interface positioning and quality.

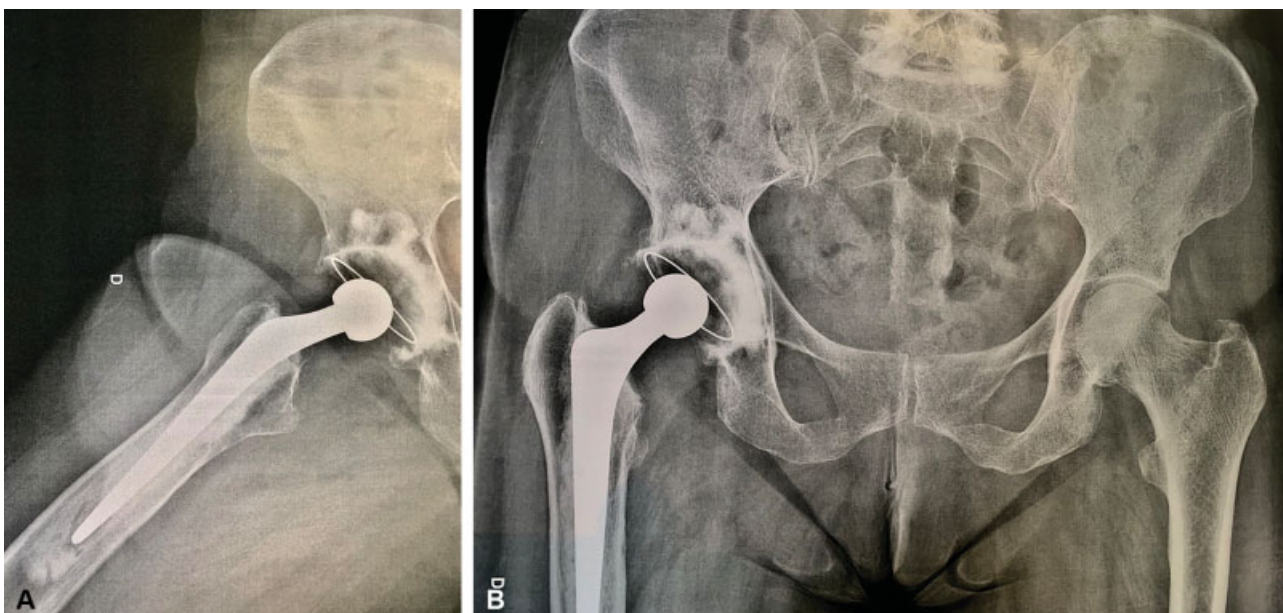


Fig. 2 Postoperative radiographs in anteroposterior and lateral view of a 59-year-old female patient submitted to a cemented total hip arthroplasty due to primary hip osteoarthritis after 16 years and 3 months of evolution.

Diaphyseal hypertrophy is a phenomenon associated with poor load transmission to the proximal femur with distal overload, which suffers hypertrophy, and it is associated with proximal pressurization insufficiency. Six cases were observed, with no clinical repercussion. Better cement pressurizing technique reduces the incidence of diaphyseal hypertrophy.²⁵

Medium- and long-term cemented THA outcomes with the type of prosthesis and technique described are consonant with those reported in the literature²⁵ and stimulate the continuity of its use. The correct application of all technical details produces good clinical and radiographic results that are sustained over the years (►Figure 2).

Conclusion

The results obtained in the present case series, with this follow-up period, confirm the effectiveness of cemented THA in patients requiring prosthetic hip replacement regardless of age and etiological diagnosis.

Conflicts of Interests

The authors have no conflicts of interests to declare.

References

- Jasty M, Maloney WJ, Bragdon CR, Haire T, Harris WH. Histomorphological studies of the long-term skeletal responses to well fixed cemented femoral components. *J Bone Joint Surg Am* 1990; 72(08):1220-1229
- Learmonth ID, Young C, Rorabeck C. The operation of the century: total hip replacement. *Lancet* 2007;370(9597):1508-1519
- Willert HG, Buchhorn GH. Interfaces in Total Hip Arthroplasty. In: Learmonth ID. *Interfaces in total hip arthroplasty*. Great Britain: Springer-Verlag; 2000:33-43
- Charnley J. *Biomechanics*. In: Charnley J. *Low friction arthroplasty of the hip*. Berlin: Springer-Verlag; 1979:332-344
- Lee C. The time-dependent properties of polymethylmethacrylate bone cement: the interaction of shape of femoral stems, surface finish and bone cement. In: Learmonth ID. *Interfaces in total hip arthroplasty*. Berlin: Springer-Verlag; 2000:11-9
- Gonçalves H, Honda E, Ono N. Análise da incorporação do enxerto ósseo acetabular. *Rev Bras Ortop* 2003;38(04):149-160
- Rosenberg WW, Schreurs BW, de Waal Malefijt MC, Veth RP, Slooff TJ. Impacted morsellized bone grafting and cemented primary total hip arthroplasty for acetabular protrusion in patients with rheumatoid arthritis: an 8- to 18-year follow-up study of 36 hips. *Acta Orthop Scand* 2000;71(02):143-146
- Alencar P, Klassen R, Dau L, Benato ML. Uso de enxerto autólogo de cabeça femoral em artroplastia total de quadril primária. *Rev Bras Ortop* 1999;34(9/10):499-504
- Bolder SB, Melenhorst J, Gardeniers JW, Slooff TJ, Veth RP, Schreurs BW. Cemented total hip arthroplasty with impacted morsellized bone-grafts to restore acetabular bone defects in congenital hip dysplasia. *J Arthroplasty* 2001;16(08, Suppl 1):164-169
- Welten ML, Schreurs BW, Buma P, Verdonschot N, Slooff TJ. Acetabular reconstruction with impacted morsellized cancellous bone autograft and cemented primary total hip arthroplasty: a 10- to 17-year follow-up study. *J Arthroplasty* 2000;15(07):819-824
- Schreurs BW, van Tienen TG, Buma P, Verdonschot N, Gardeniers JW, Slooff TJ. Favorable results of acetabular reconstruction with impacted morsellized bone grafts in patients younger than 50 years: a 10- to 18-year follow-up study of 34 cemented total hip arthroplasties. *Acta Orthop Scand* 2001;72(02):120-126
- Engesaeter LB, Furnes O, Havelin LI, Lie Sa, Volset SE. Survival of Total Hip Arthroplasties after DDH in the Norwegian Arthroplasty Register 1987-2004. *Hip Int* 2007;Suppl 5:119-119
- Kwon YM, Morshed S, Malchau H. Cemented or cementless stem fixation in THA: what is the current evidence? *Orthopedics* 2006; 29(09):793-794
- Brooker AF, Bowerman JW, Robinson RA, Riley LH Jr. Ectopic ossification following total hip replacement. Incidence and a method of classification. *J Bone Joint Surg Am* 1973;55(08):1629-1632
- NNIS System. National Nosocomial Infections Surveillance (NNIS) System Report, data summary from January 1992 through June 2003. *Am J Infect Control* 2003;31(08):481-498
- DeLee JG, Charnley J. Radiological demarcation of cemented sockets in total hip replacement. *Clin Orthop Relat Res* 1976;(121):20-32
- Gruen TA, McNeice GM, Amstutz HC. "Modes of failure" of cemented stem-type femoral components: a radiographic analysis of loosening. *Clin Orthop Relat Res* 1979;(141):17-27
- Harris WH. Traumatic arthritis of the hip after dislocation and acetabular fractures: treatment by mold arthroplasty. An end-result study using a new method of result evaluation. *J Bone Joint Surg Am* 1969;51(04):737-755
- Della Valle AG, Padgett DE, Salvati EA. Preoperative planning for primary total hip arthroplasty. *J Am Acad Orthop Surg* 2005;13(07):455-462
- Crites BM, Berend ME, Ritter MA. Technical considerations of cemented acetabular components: a 30-year evaluation. *Clin Orthop Relat Res* 2000;(381):114-119
- Warth LC, Callaghan JJ, Liu SS, Klaassen AL, Goetz DD, Johnston RC. Thirty-five-year results after Charnley total hip arthroplasty in patients less than fifty years old. A concise follow-up of previous reports. *J Bone Joint Surg Am* 2014;96(21):1814-1819
- Schmalzried TP. The infected hip: telltale signs and treatment options. *J Arthroplasty* 2006;21(04, Suppl 1):97-100
- DeHart MM, Riley LH Jr. Nerve injuries in total hip arthroplasty. *J Am Acad Orthop Surg* 1999;7(02):101-111
- Ranawat CS, Peters LE, Umlas ME. Fixation of the acetabular component. The case for cement. *Clin Orthop Relat Res* 1997; (344):207-215
- Fowler JL, Gie GA, Lee AJ, Ling RS. Experience with the Exeter total hip replacement since 1970. *Orthop Clin North Am* 1988;19(03): 477-489