Penetrating Injury Due to Bicycle Brake Handle Causing Middle Cerebral Artery Infarct

Gopalakrishnan Madhavan Sasidharan[1] Abhishek Chauhan[1]

[1]Department of Neurosurgery, Jawaharlal Institute of Post-graduate Medical Education and Research, (JIPMER), Pondicherry, India

Address for correspondence Gopalakrishnan Madhavan Sasidharan, MS, SSB, Second floor, Department of Neurosurgery, JIPMER, Pondicherry 605006, India (e-mail: gopalakrishnanms@gmail.com).

Indian J Neurotrauma 2018;15:67–69

Abstract

An 8-year-old boy was brought to the emergency room with history of fall from a bicycle he was riding. On examination, he had a swelling in the left orbit with a small laceration under the medial aspect of the left eyebrow. The Glasgow coma scale was E2M5V2. An emergency computed tomographic (CT) scan showed infarct causing mass effect in the territory of the left middle cerebral artery. CT angiogram showed that a branch of the middle cerebral artery was occluded at the end of track traversed by the bicycle brake handle. The patient underwent decompressive craniectomy. Initial methylmethacrylate cranioplasty had to be removed due to infection. Later, the patient underwent titanium cranioplasty. At last follow-up, he was going to school. Hemiparesis persisted. Children are vulnerable to penetrating injury by the relatively sharp brake handle when they fall from an adult bicycle. Previous reports include fatal injury by similar mechanism. In this case, it caused injury to the middle cerebral artery without causing bleed. Bicycle manufacturers could be advised to make the vehicle safer for children by twisting the end of the brake handle.

Keywords
- ► penetrating injury
- ► infarct
- ► cranioplasty
- ► bicycle brake handle injuries

Introduction

We present the case history of an 8-year-old boy who sustained a penetrating injury to the brain after falling from a bicycle. We describe potential design changes in brake handle to prevent such injuries.

Case Report

An 8-year-old boy was brought to the emergency department with a history of fall from his father's bicycle (►**Fig. 1**) when he was trying to ride it. The patient became unconscious immediately following the injury. In the emergency room, 4 hours after the trauma, he was noticed to have a mild swelling in the left eye around a small, barely visible laceration under the medial aspect of the left eyebrow. The periorbital swelling later increased dramatically in the postoperative period. The Glasgow coma scale was E2M5V2. An emergency computed tomographic (CT) scan showed a small right frontotemporal parenchymal hematoma and a subdural hematoma along with infarct in the territory of the right middle cerebral artery (MCA). The infarct and bleed caused mass effect and midline shift (►**Fig. 2**). CT angiogram showed that a MCA branch was occluded. A track was seen from the left orbit to the level of the MCA occlusion indicating the extent of penetration (►**Fig. 3**). There were no retained foreign bodies.

The patient underwent emergency decompressive craniectomy and evacuation of hematoma. He recovered in sensorium over the next few days. At the time of discharge, 16 days after the trauma, he was conscious and well oriented and was able to move proximal parts of his left-sided limbs (motor power was 2/5). His vision was defective in the injured eye with acuity of 3/60.

Later, the patient underwent acrylic implant cranioplasty but had to be taken down because of infection and cerebrospinal fluid leak. An autologous bone graft also got infected and had to be removed. Ultimately, he successfully underwent titanium cranioplasty. Hemiparesis improved with physiotherapy. Two years after the trauma, the patient is able to walk on his own and does well in school.

received
December 16, 2017
accepted after revision
December 24, 2018
published online
July 23, 2019

DOI https://doi.org/10.1055/s-0039-1694295
ISSN 0973-0508.

Fig. 1 The bicycle from which the child fell. The rod-like brake handle is just under 1 cm in diameter.

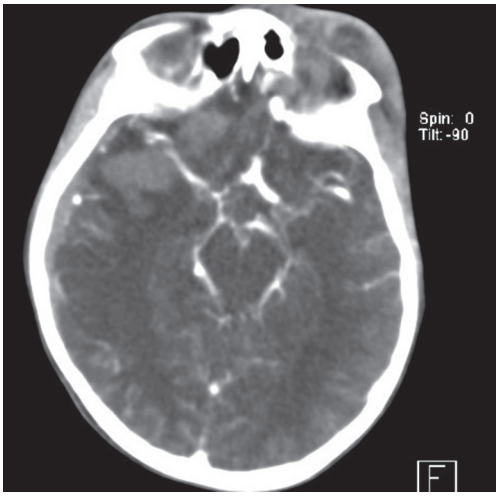

Fig. 2 CT angiogram showing abrupt cutoff of the right middle cerebral artery and the intracranial bleed and infarct that caused the mass effect.

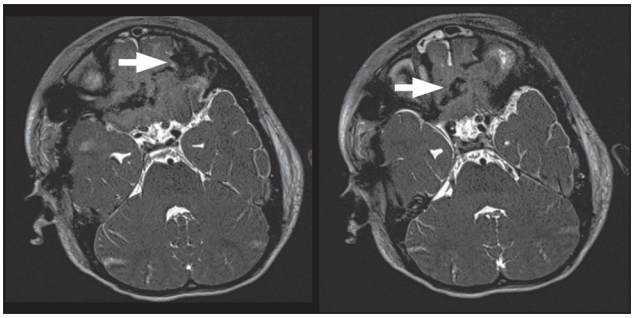

Fig. 3 MRI CISS image showing the track traveling from the left orbit toward the right middle cerebral artery (arrows indicate the track).

Discussion

A wide variety of objects is known to cause low-velocity, accidental penetrating injury to the brain through relatively thin parts of the skull such as the orbit roof and the temporal bone.[1]

In this particular case, the child sustained what the parents thought was a trivial injury when he fell from his father's bicycle. Mild swelling and a nondescript laceration below the medial aspect of the left eyebrow hid the extent of damage his brain sustained. The relatively sharp bicycle brake handle had penetrated the thin medial orbital wall and the anterior cranial fossa base to injure and occlude the opposite MCA. The injury caused a massive infarct. Though a decompressive craniectomy saved his life, he had to undergo multiple surgeries later since the initial attempts at cranioplasty developed infective complications.

As far as we know, there are only eight reported cases of penetrating brain trauma due to fall onto a bicycle brake handle.[2] Previous reports of bicycle brake handle injury suggest that it is likely to occur when children lose control of an adult bicycle. They fall face forwards on the upturned brake handle of an adult bicycle that typically has a metal rod as the bicycle brake handle. Four out of the six previous reports in children had a fatal outcome.[3-5] There is only one report of an adult woman sustaining transorbital bicycle brake handle injury. She succumbed suddenly despite presenting with an intact sensorium.

All previous reports, including one of ours, emphasize the relatively minor exterior wounds that such patients present with initially.

Bicycle brake handle injuries cannot be prevented by the use of open face bicycle safety helmets as they typically occur through the orbit. Serious thought should be given to redesigning low-cost adult bicycles that use a rod as the bicycle brake lever handle. A simple outward twist of the end of the handle should make it sufficiently blunt and large to prevent intrusion into the skull. An artistic rendering of the design we propose is illustrated here (►**Fig. 4**). In fact, we have written to major bicycle manufacturers and the Bureau of Indian Standards to make this simple and cost-effective change in design.

Fig. 4 An artistic rendering of the safety modification that we suggest.

Conclusion

Children are vulnerable to penetrating injury by the relatively sharp brake handle when they fall from an adult bicycle. External injuries may be very subtle in these cases. Bicycle manufacturers are encouraged to make a simple, cost-effective redesigning of the brake handle to prevent such injuries.

Conflict of Interest

None.

References

1 Kataria R, Singh D, Chopra S, Sinha VD. Low velocity penetrating head injury with impacted foreign bodies in situ. Asian J Neurosurg 2011;6(1):39–44

2 Poroy C, Cibik C, Yazici B. Traumatic globe subluxation and intracranial injury caused by bicycle brake handle. Arch Trauma Res 2016;5(3):e33405

3 Chattopadhyay S, Sukul B, Das SK. Fatal transorbital head injury by bicycle brake handle. J Forensic Leg Med 2009;16(6):352–353

4 Huiszoon WB, Noë PN, Manten A. Fatal transorbital penetrating intracranial injury caused by a bicycle hand brake. Int J Emerg Med 2012;5(1):34

5 Gopalakrishnan MS, Indira Devi B. Fatal penetrating orbitocerebral injury by bicycle brake handle. Indian J Neurotrauma 2007;4(2):123–124