A Histological and Clinical Evaluation of Plasma as a Graft Holding Solution and Its Efficacy in Terms of Hair Growth and Graft Survival

Anil Kumar Garg[1] Seema Garg[1]

[1]Rejuvenate Plastic, Cosmetic and Hair Transplant Centre, Indore, Madhya Pradesh, India

Address for correspondence Anil Kumar Garg, MS, MCh, Rejuvenate Plastic, Cosmetic and Hair Transplant Centre, 2/1 R.S. Bhandari Marg, Indore 452003, Madhya Pradesh, India (e-mail: anil@anilgarg.com).

Indian J Plast Surg 2019;52:209–215

Abstract

Background There is a time lag between hair follicle harvesting and implantation, during this time hair follicles suffer ischemic injury. We need a holding medium or a solution to minimize or neutralize ischemic injury.

Aims and Objective To evaluate plasma as a graft holding solution in terms of its efficacy in hair growth and hair graft survival.

Method and Material A split scalp study was performed. The left side was designated as the control area (Group A) where grafts implanted were kept in Ringer's lactate, and the right side behaved as the test area (Group B) and received grafts preserved in autologous plasma. The *p*-value was calculated.

Observations MTT staining for grafts stored in Ringer's lactate at 12 and 72 hours showed poor hair follicle cells' survival while grafts kept in plasma showed viable cells even after 72 hours.

The hair count and density in plasma group were significantly higher than those in the Ringer's lactate group. There was an improvement in hair thickness in both groups from 6 months to 12 months.

Conclusion Autologous plasma is an easily available graft holding solution. Platelets along with the plasma provide multiple growth factors promoting epithelialization, neovascularization, and action on hair follicle stem cells to improve growth. The fibrin coating around the graft makes it sticky and prevents dehydration. The split scalp controlled study certainly shows the advantages of using plasma over other extra cellular graft holding solutions.

Keywords
- graft holding solutions
- ischemic injury
- autologous plasma
- anagen effluvium
- fibrin scaffold

Introduction

The surgical trauma of hair transplantation triggers inflammation which is the first step in wound healing. The brunt of the biochemical changes has to be borne by the newly transferred grafts which are devoid of any blood supply. Graft survival is affected by a cascade of multiple factors including graft harvesting, dissection, manipulation during implantation, and ischemia/reperfusion injury following implantation in the body. The insults inflicted from these unfavorable factors add up leading to apoptosis which affects graft survival and the quality of hair regrowth. To achieve the best results we should focus on improving all the above-mentioned factors.

Grafts harvested and maintained out of the scalp are preserved in a holding solution until they are implanted. Thus, the holding solution plays a crucial role in the hair transplant procedure. An ideal holding solution should have the same osmolality as of the grafts cells, should prevent acidosis, provide energy to the cells, and prevent the release of free radicals. There are two types of holding solutions, extracellular and intracellular. Examples of extracellular solutions are normal saline, lactated Ringer's (RL), and plasma-like fluids.

published online
September 26, 2019

DOI https://doi.org/10.1055/s-0039-1696790
ISSN 0970-0358.

©2019 Association of Plastic Surgeons of India

License terms

The intracellular solutions are represented by hypothermosol. Extracellular holding solutions do not require chilling, which causes sodium pump failure leading to swelling of the cells, whereas intracellular holding solutions require chilling.[1]

At our center, we use autologous plasma with platelets as a graft holding solution during hair transplantation surgery. Clinical results have been evaluated with trichoscan analysis and supported by histological evaluation for graft viability. Previously the platelet-rich plasma to promote hair growth was used by Uebel.[2] The study was based on the hypothesis that platelets have growth factors that stimulate the stem cells of hair follicles.[2] Uebel[2] however did not do histological study.

Aims and Objective

To evaluate plasma as a graft holding solution in terms of its efficacy in hair growth and hair graft survival.

Method

A split scalp study was performed comparing hair grafts transplanted on the right and left frontotemporal areas selected as recipient sites in the same patient. The patients' were informed and consent was taken for the split scalp study. The left side was designated as the control area (Group A) and the right side behaved as the test area (Group B), for comparison of the results. The right frontotemporal area received grafts preserved in autologous plasma, while the left frontotemporal area received grafts preserved in RL. Both sides were implanted with grafts harvested with the same technique, with equal number of grafts of the same quality, and with the same implantation time. Grafts on both sides were implanted by two surgeons sharing similar experience and expertise using optical loupes for magnification.

The autologous plasma and the RL holding solutions with the grafts were maintained at a temperature of around 12 ± 2°C, whereas the room temperature was maintained around 18°C.

The following parameters were taken into consideration for the study:

- A histological study with MTT (3- (4,5-dimethylthiazol-2-yl)-2,5-diphenyltetrazolium bromide) stain (a colorimetric assay for assessing cell metabolic activity) to confirm the viability of cells in the grafts at 12 and 72 hours.
- Periodical postoperative patient follow-up with regular photographs and trichoscan evaluations to identify any event of anagen effluvium due to postsurgical shock loss.
- Trichoscan study for hair density was done at 3 months to check for hair growth.
- Hair thickness was assessed at 6 and 12 months to check for the quality of hair growth.

Preparation of Autologous Plasma

Preparation of autologous plasma was the first step before commencing the hair transplant. We collected 23 cc of blood from the patient in a syringe with 2 cc ACD (acid citrate dextrose) solution as an anticoagulant. The blood was transferred to a high-quality glass container designed by the author. The blood was centrifuged in a temperature-controlled (19°C) centrifuge machine at 5,000 RPM (rotations per minute; this RPM is default factory setting, and regularly it is calibrated) for 16 minutes. The process resulted in the separation of RBC at the bottom of the tube and plasma with platelets forming the upper fluid compartment. The 23 cc of blood yielded approximately 12 cc of plasma. Hence we can deduce that the platelet concentration was twice the normal basal levels of the patient. The laboratory further confirmed the platelet count ranging between 400,000 and 500,000/cumm. The plasma thus created was stored in a sterile stainless steel bowl (a Petri dish can also be used) maintaining a temperature of 12 ± 2°C on a cool gel pack ready to receive the grafts; the temperature of plasma was checked regularly.

The harvested grafts were divided randomly into two groups, with an equal number of grafts per side. Control group (A) grafts were stored in RL and test group (B) grafts were stored in plasma. Both graft holding solutions were maintained at the same temperature.

Grafts dipped in the plasma form a very loose clump. A trained assistant separates the individual graft from a small clump and places it on surgeon's hand to implant.

Six volunteer patients having similar grades of male pattern baldness were included in the study, with ages between 25 and 40 years. Grafts were implanted over the bilateral frontotemporal areas as planned. Grafts stored in plasma were implanted on the right frontotemporal side, while the grafts stored in RL were implanted on the left frontotemporal side. The same numbers of grafts were implanted with a standard density of 40 grafts/cm^2. Routine postoperative care of the donor and recipient areas was followed as per general guidelines for all hair-transplant patients.

The study was conducted as follows:

- The graft samples A and B were sent for MTT staining at 12 and 72 hours of graft holding time to determine viability of the cells.
- Patient follow-ups were conducted at 1, 2, 3, 4, 6, and 12 months after hair transplant.
- Photographs were taken for comparison of left and right frontotemporal areas with and without flash.
- Hair count and density were taken on both sides using trichoscan.
- At the 6 and 12 months follow-up, photographs and trichoscan for hair thickness were repeatedly taken for evaluation of terminal hair.

Observations

Observation of MTT Staining

- *MTT-staining at 12 hours*—grafts stored in the incubator at temperature 12 ± 2°C in RL showed poor staining,

while the grafts stored in the plasma holding solution were well stained, indicating good cell viability in the plasma group when compared with RL group. As MTT stains differentiate between live and dead cells, so it was selected for study.

- *MTT-staining at 72 hours*— (►**Figs. 1** and **2**) grafts stored in plasma showed good staining, while very poor staining of grafts of the RL group was observed (►**Figs. 3**–**5**).

Trichoscan Study

For thickness at 3 months: Trichoscan study done at 3 months after hair transplant for the hair count on the RL side showed an average of 1.3 (density: 4.4 grafts/cm^2), while on the plasma side the average hair count was 8.3 (density: 27.5 grafts/cm^2). Thus the plasma side had 68.75% hair growth while on RL side had only 11% hair growth. The hair count and density in the plasma group were significantly higher than those in the RL group (►**Fig. 6** and ►**Table 1**).

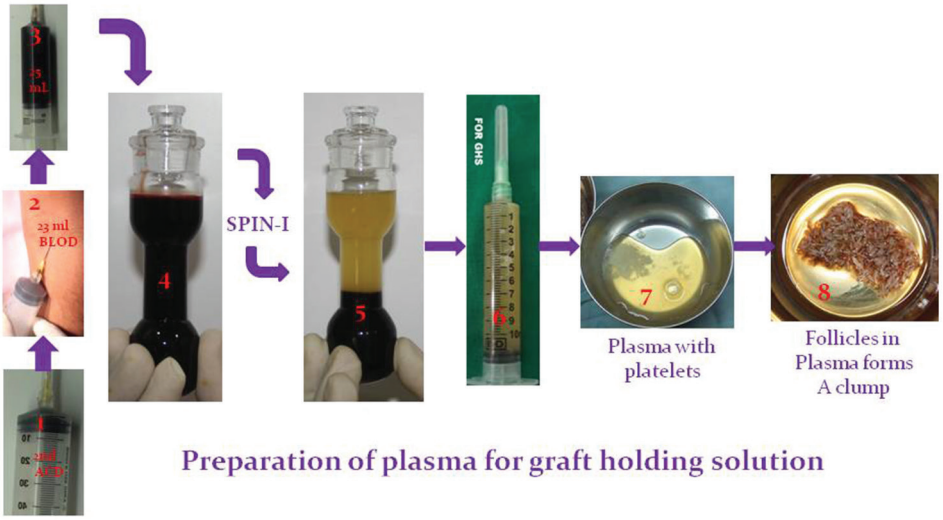

Fig. 1 Method of preparation of plasma for graft holding solution.

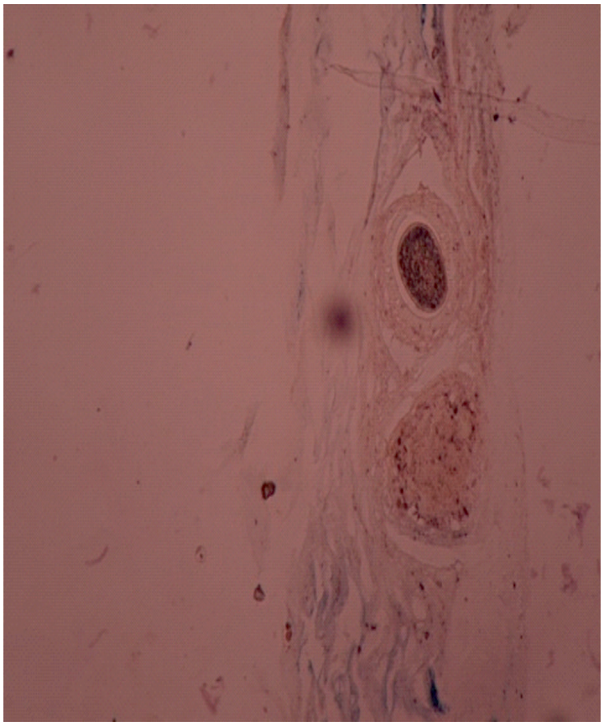

Fig. 2 MTT staining 12-hour medium A Ringer.

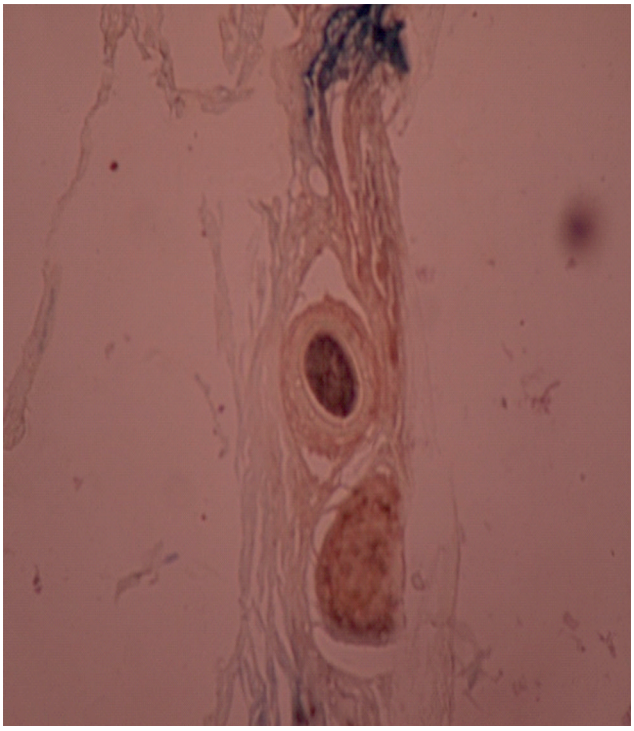

Fig. 3 MTT staining 12-hour medium B plasma.

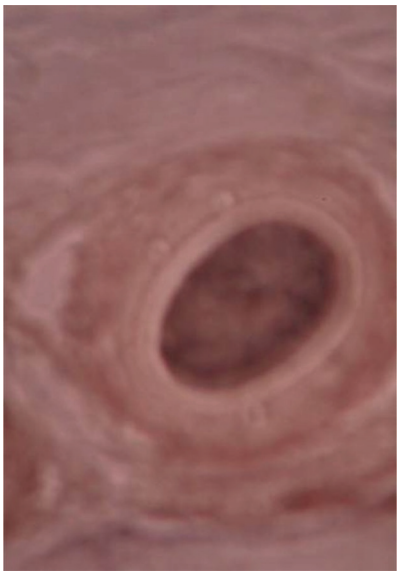

Fig. 4 MTT staining 72-hour medium A Ringer.

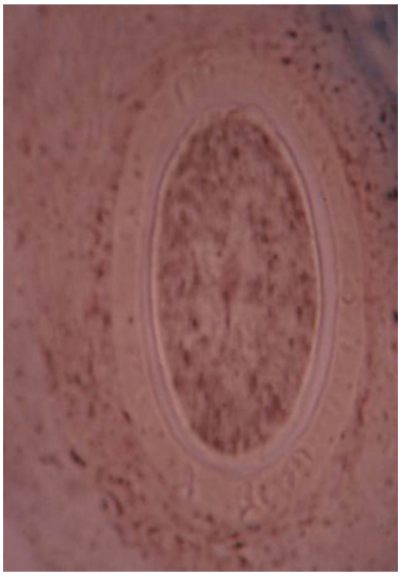

Fig. 5 MTT staining 72-hour medium B plasma.

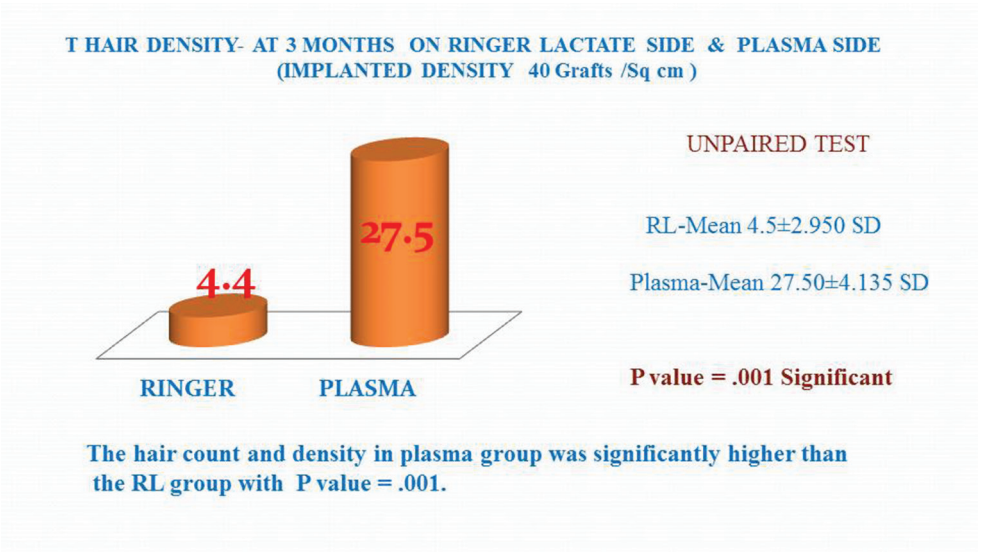

Fig. 6 Hair density comparison between control and test groups.

Table 1 Hair density at 3 months on Ringer's lactate and plasma sides (density of implanted hair: 40 grafts/cm^2).

	Hair count		Hair density per square cm		Average % of hair growth	
GH solution	RL	Plasma	RL	Plasma	RL	Plasma
Patient -1	2	9	6.6	29.7	110%	68.75%
Patient -2	1	10	3.3	33		
Patient -3	2	7	6.6	23.1		
Patient -4	0	8	0.0	26.4		
Patient -5	2	7	6.6	23.1		
Patient -6	1	9	3.3	29.7		
Average	1.3	8.3	4.4	27.5		

Abbreviations: GH, graft holding; RL, Ringer's lactate.

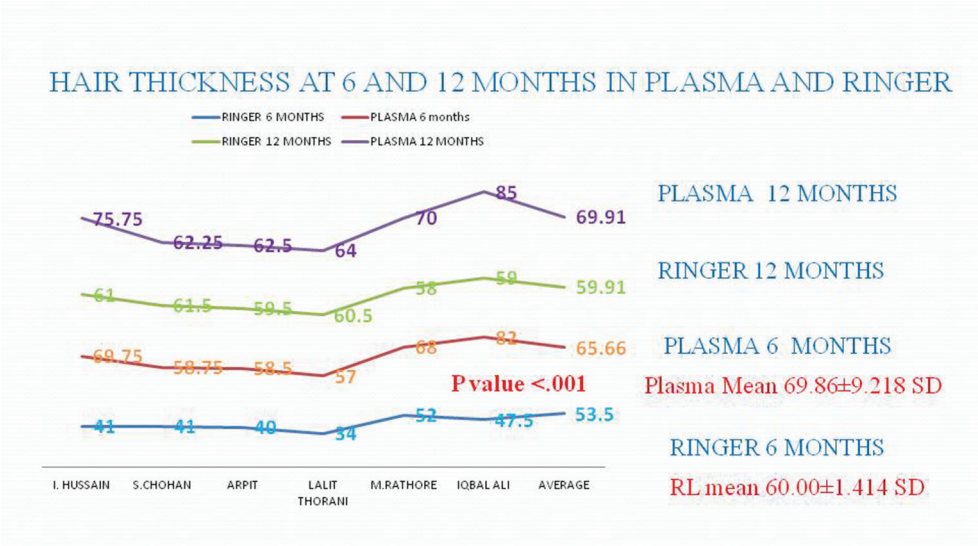

Fig. 7 Comparison of hair thickness in both groups at 6 months and 12 months. There was an improvement in hair thickness in both groups from 6 months to 12 months with a *p*-value of 0.002.

Fig. 8 After 50 days of hair transplant. After 50 days of hair transplant showing significant anagen effluvium on Ringer's lactate side while on plasma side implanted hair were still present.

Trichoscan Study for Hair Thickness

The hair thickness measured at 6 months after hair transplant by trichoscan showed an average of 53.5 µm on the RL side, while on the plasma side it was 65.66 µm, which was significantly higher. At the 12-month follow-up, the hair thickness measured was 60.6 µm on the RL side, while on the plasma side it was 66.125 µm. Details are mentioned in► **Fig. 7**.

Clinical Evaluation

Photographs of the right and left frontotemporal areas were taken at 50 and 120 days after the hair transplant for evaluation of hair growth and anagen effluvium.

At 50 days (►**Fig. 8**), on the test side (plasma side) implanted hair were present, while on the control side (RL) most of the implanted hair were lost as they underwent anagen effluvium. Photographs (►**Fig. 9**) taken at 120 days showed the difference in hair quality and density on the left and right frontotemporal regions.

Discussion

The most important benefit of an optimum graft holding solution would be an increase in hair yield from the transplanted grafts. The optimum holding solution would reduce the damage from reperfusion injury and free radical formation as well as from ionic imbalance and variation in osmolality created by the ischemic phase.

Holding solutions are formulated according to the composition of intracellular and extracellular body fluid environment and behave differently. An intracellular graft holding solution[1] needs chilling. They also do not assure protection from reperfusion injury[3] and are expensive. Extracellular solutions are widely used, economical, and do not need chilling. Intracellular fluids like hypothermosol with adenosine triphosphate (ATP) added have significant benefits when the graft holding time is more than 10 hours; however, this is a very rare situation as most hair-transplant procedures are complete within 4 to 6 hours.

Autologous plasma is an extracellular fluid which is isotonic with nutrients and platelet-derived growth factors. It is cost-effective and can be prepared by a surgeon or a pathologist. Drying and desiccation of grafts immersed in plasma is delayed, and the grafts look shiny and more hydrated even at the end of 4 hours holding time. Uebel[2,4] in his study had implanted grafts after keeping in plasma and reported 5 to 53% increase in hair count after 7 months of hair transplant.

MTT Assay

The MTT assay is a colorimetric assay for assessing cell metabolic activity. NAD (P)H-dependent cellular oxidoreductase

Fig. 9 Patient photographs after 4 months showing hair growth difference on left and right frontotemporal regions.

enzymes reflect the number of viable cells present under defined conditions. These enzymes are capable of reducing the tetrazolium dye MTT to its insoluble formazan.[5] Therefore the dye can detect metabolically active live cells. In our study samples of hair follicle grafts were sent for MTT histological assay to detect live cells. Results of staining showed that at 12 hours the plasma grafts were better stained than the RL grafts. Results at 72 hours staining were surprising. Plasma grafts showed good staining while RL grafts showed very poor staining indicating that the cells were viable in plasma grafts even at the end of 72 hours.

Trichoscan study done at 3 months for the hair count on the RL side showed an average of 1.3 (density: 4.4 grafts/cm^2), while on the plasma side the average hair count was 8.3 (density: 27.5 grafts/cm^2). Thus the plasma side had 68.75% hair growth, while on RL side only 11% hair growth. The unpaired test showed an RL mean of 4.5 ± 2.950 standard deviation (SD) and a plasma mean of 27.50 ± 4.135 SD with a *p*-value < 0.001, which is significant. This indicates that anagen effluvium on the plasma side was 31.25%, while on the RL side the effluvium was 89.00%. This shows that anagen effluvium was controlled by 58.75%, which is significant (*p*-value < 0.001).

In the first 7 days after hair transplantation, there is period of inflammatory response (involving neutrophils, eosinophils, macrophages, platelets, fibroblasts, and growth factors[2]) in which both erythema and edema occur followed by apoptosis and the grafted hair follicles, as well the existing hair follicles, may enter into an involution phase resulting in hair shedding. This process is triggered and propagated due to ischemia. The follicles become refractory and those that survive will regrow at the stimulus of the next growth cycle which begins after the third month and continues up to 7 months. Prevention of anagen effluvium can be achieved with prevention of apoptosis of the more metabolically active progeny of the stem cells. This observation may help us in the development of an ideal holding solution by further bioenhancement of platelet and plasma solution.

The hair thickness measured at 6 months by trichoscan showed average of 53.5 µm on the RL side, while on plasma side it was 65.66 µm, which was significantly higher. The unpaired test showed a group RL mean of 53.5 ± 6.377 SD and a group plasma mean of 65.67± 9.688 SD. The *p*-value was <0.001, which is very significant.

At the 12-month follow-up the hair thickness measured was 60.6 µm on the RL side, while on the plasma side it was 66.125 µm. The thickness of hair on the RL side increased in 12 months but was still less than that on the plasma side. The unpaired test showed a group RL mean of 60.00 ± 1.414 SD and a group plasma mean 69.86 ± 9.218 SD; the *p*-value was <0.001, which is very significant.

The hair diameter depends on several viable cells in the matrix. These are the mesodermal stem cells known to be very sensitive to ischemia. Ischemia leads to accumulation of free radicals and anaerobic metabolic pathways resulting in apoptosis of cells thereby affecting hair thickness. The hair thickness on the plasma graft side was better than that on the RL side. This may be because of the effect of multiple beneficial factors in the plasma holding solution.

Platelets are activated on contact with collagen around hair follicles resulting in the release of various platelet-derived growth factors.[6,7] Fibrinogen in plasma gets converted to fibrin which forms a mesh[2,4,8,9] in which platelets are trapped. This fibrin mesh with activated platelets forms a three-dimensional fibrin scaffold. The graft so covered by this scaffold is implanted back in the scalp. Platelet-rich fibrin was first described by Dohan et al in France.[10,11] Fibrin glue along with skeletal myoblasts in the fibrin scaffold preserve the cardiac function after myocardial infarction.[12] In vitro prefabrication of human cartilage is created in shapes using fibrin glue and human chondrocytes.[13] Long-term regeneration of human epidermis is achieved on third degree burns transplanted with autologous cultured epithelium grown on a fibrin matrix.[13] There is a definite role of the fibrin matrix in angiogenesis.[14]

Conclusion

Autologous plasma is an easily available graft holding solution. It is isotonic in nature having nutrient growth factors as well as the advantage of fibrin. Platelets along with the plasma provide multiple growth factors promoting epithelialization, neovascularization, and action on hair follicle stem cells to improve growth. The improved growth has been noted in this study. The fibrin coating around graft makes it sticky and prevents dehydration. The growth factors and nutrients successfully prevent the anagen effluvium and shock loss post hair transplant. The thickness of hair and yield of the graft are also better in plasma as compared with those in RL. The probable explanation of the improved results is availability of various nutrients, fibrin, and multiple growth factors in plasma. The split scalp controlled study certainly shows the advantages of using plasma over other extracellular graft holding solutions.

Conflict of Interest

The authors have no conflict of interest.

References

1 Cole JP, Internet website posting. Available at https://www.forhair.com/optimal-holding-solution-and-temperature-for-hair-follicle/. Accessed August 8, 2019
2 Uebel CO. A new advance in baldness surgery using platelet-derived growth factor. Hair Transplant Forum Int 2005;15(3):77–84
3 Cooley J. Ischemia reperfusion injury and graft storage solutions. Hair Transplant Forum Intl 2004;13(4):121–127
4 Uebel CO, da Silva JB, Cantarelli D, Martins P. The role of platelet plasma growth factors in male pattern baldness surgery. Plast Reconstr Surg 2006;118(6):1458–1466, discussion 1467
5 MTT assay. Available at: https://en.wikipedia.org/wiki/MTT_assay. Accessed August 8, 2019
6 Yun SH, Sim EH, Goh RY, Park JI, Han JY. Platelet activation: the mechanisms and potential biomarkers. BioMed Res Int 2016;2016:9060143
7 Xu Xr, Zhang Silva D, Oswald BE et al. Platelets are versatile cells: new discoveries in hemostasis, thrombosis, immune responses, tumor metastasis and beyond. Crit Rev Clin Lab Sci 2016;53(6):409–430
8 Miao Y, Sun YB, Sun XJ, Du BJ, Jiang JD, Hu ZQ. Promotional effect of platelet-rich plasma on hair follicle reconstitution in vivo. Dermatol Surg 2013;39(12):1868–1876
9 Greco J. Preliminary experience and extended applications for the use of autologous platelet rich plasma in hair transplantation surgery. Hair Transplant Forum Int 2007;17(4):131–132
10 Dohan DM, Choukroun J, Diss A, et al.Platelet-rich fibrin (PRF): a second-generation platelet concentrate. Part I: technological concepts and evolution. Oral Surg Oral Med Oral Pathol Oral Radiol Endod 2006;101(3):e37–e44
11 Sunitha Raja V, Munirathnam Naidu E. Platelet-rich fibrin: evolution of a second-generation platelet concentrate. Indian J Dent Res 2008;19(1):42–46
12 Christman KL, Fok HH, Sievers RE, Fang Q, Lee RJ. Fibrin glue alone and skeletal myoblasts in a fibrin scaffold preserve cardiac function after myocardial infarction. Tissue Eng 2004;10(3–4):403–409
13 Ting V, Sims CD, Brecht LE, et al. In vitro prefabrication of human cartilage shapes using fibrin glue and human chondrocytes. Ann Plast Surg 1998;40(4):413–420
14 van Hinsbergh VW, Collen A, Koolwijk P. Role of fibrin matrix in angiogenesis. Ann N Y Acad Sci 2001;936:426–437