

Basal Cisternostomy in Traumatic Brain Injury: An Idea whose Time has Come?

Nishant Goyal¹ Punit Kumar¹ Jitender Chaturvedi¹ Saquib Azad Siddiqui² Deepak Agrawal³

¹Department of Neurosurgery, All India Institute of Medical Sciences, Rishikesh, Uttarakhand, India

²Department of Neurosurgery, All India Institute of Medical Sciences, Patna, India

³Department of Neurosurgery, All India Institute of Medical Sciences, New Delhi, India

Address for correspondence Nishant Goyal, MBBS, MCh, Department of Neurosurgery, All India Institute of Medical Sciences, Veerbhadra Road, Rishikesh 249203, Uttarakhand, India (e-mail: drnishantgoyal@gmail.com).

Indian J Neurotrauma:2020;17:3–5

Abstract

Keywords

- ▶ basal cisternostomy
- ▶ traumatic brain injury
- ▶ head injury
- ▶ decompressive craniectomy
- ▶ glymphatic pathway

Traumatic brain injury is associated with high morbidity and mortality. Since the introduction of decompressive craniectomy more than a century ago, no major surgical advancement has been introduced in this field in spite of neurosurgery having seen a sea change in general. Basal cisternostomy, introduced recently, is said to have great promise. In this regard, neurosurgeons need to understand the theory behind the recently introduced basal cisternostomy and whether it holds any merit or not.

Introduction

Traumatic brain injury (TBI) is one of the leading causes of morbidity and mortality among children and young adults worldwide. About 1.7 million cases of TBIs occur in the United States every year with one head injury maintaining cost of \$4 million/year, and around 150,000 total deaths due to TBIs in India.¹ Raised intracranial pressure (ICP) is a major culprit in the pathophysiology of traumatic brain injury and current managements are targeted at reducing the same. Initially, medical management has tried to decrease raised ICP including proper neck positioning to prevent venous congestion, hyperventilation, cerebral decongestants, and sedation. In cases of raised ICP refractory to all these measures or cases where patient's presenting features and CT findings indicate impending herniation due to raised ICP, a surgical procedure is warranted.

The surgical procedures currently performed with the aim to reduce the increased intracranial pressure include external ventricular drain (EVD) insertion and decompressive craniectomy (DHC). EVD insertion is useful in a very small subset of patients where there is substantial ventriculomegaly while increasing the risk of external infection. On the other hand, in spite of relying on DHC for a long period now, DHC has failed to show much survival benefits as compared with the

patients undergoing medical management as shown in the recently concluded DECRA trial.²

In this scenario, basal cisternostomy that incorporates knowledge of skull base and microvascular surgery has emerged as a worthy option that warrants exploration.^{3,4}

Pathophysiology

Causes of Edema in Head Injury

Patients with traumatic brain injury present a rapid cytotoxic edema at the core of the injury, whereas the surrounding tissue may first develop ionic and later vasogenic edema.^{5,6} Cytotoxic brain edema is characterized by intracellular water accumulation in the neurons, astrocytes, and microglia irrespective of the integrity of the vascular endothelial wall. Water enters the central nervous system through aquaporin 4 (AQP4) located in perivascular astrocyte foot processes. Ionic edema is caused by increased cell membrane permeability for ions, ionic pump failure due to energy depletion, and cellular reabsorption of osmotically active solutes.^{7,8} Vasogenic brain edema is caused by mechanical or autodigestive disruption or functional breakdown of the endothelial cell layer of brain vessels. Disintegration of the cerebral vascular endothelial wall allows for uncontrolled ion and protein transfer from the intravascular to the extracellular/interstitial brain compartments with ensuring water accumulation.⁹

Glymphatic Pathway

An experimental study has demonstrated a paravascular pathway termed as “glymphatic” pathway, which is a brain-wide network of paravascular channels that facilitates cerebrospinal fluid (CSF) flow from the subarachnoid space through the brain parenchyma and clearance of interstitial solutes. It is structurally located between glial end-foot processes and vascular cells of arterioles, capillaries, and veins. The glymphatic pathway allows CSF influx along almost all penetrating arteries (through the so-called Virchow–Robin spaces which communicate to the above mentioned space from the cisterns) and efflux along some large and deep veins.¹⁰ It was demonstrated that there is up to 60% reduction in activity of glymphatic pathway following experimental TBI, thus contributing toward development of brain edema formation.¹¹

Studies suggest that edema formation is also associated with CSF entrance into the brain parenchyma via the low-resistance para-arterial space or decreased interstitial fluid efflux or a combination of the two processes. Glymphatic removal of excess of interstitial fluid is likely decreased following injury or infarction. Shift of CSF from the cerebral cisterns to the brain parenchyma leads to a severe brain swelling.

How Basal Cisternostomy Works

Traumatic subarachnoid hemorrhage often associated with severe head trauma results in decreasing the CSF outflow thereby resulting in increased intracisternal pressure. Thus, a pressure gradient is created between the high-pressure cisterns and low-pressure brain parenchyma. This is postulated to be one of the reasons for rapid fluid shift.

Therefore, if the cisterns are opened and the subarachnoid blood is released from there, the intracisternal pressure that was raised secondary to the head injury will decrease and become equal to the atmospheric pressure. Thus, the

pressure gradient that had been created will reverse allowing for a “back-shift” of CSF through the Virchow–Robin spaces, thereby decreasing the intracranial pressure (ICP; ► Fig. 1).

Operative Technique of Basal Cisternostomy

After a standard curvilinear fronto-temporo-parietal question mark incision, fronto-temporo-parietal craniotomy is made.

Principal steps for basal cisternostomy can be summarized in the following steps:

- Drilling the sphenoid ridge until the orbitomeningeal arteries are encountered.
- Identification of the superior orbital fissure and the orbitomeningeal band.
- Division of the meningo-orbital band, which marks the lateral edge of the superior orbital fissure.
- Exposing the inferior aspect of the anterior clinoid process.
- Elevation of the temporal lobe from the superior orbital fissure exposing the anterior clinoid process;
- Elevation of the frontal lobe from the anterior clinoid process, which can easily be removed.
- Opening the dura.
- Identification and opening of the inter-optic, opticocarotid, and lateral carotid cisterns.
- Approaching the membrane of Lilliequist through the opticocarotid window or the lateral carotid window.
- Drilling the posterior clinoid process in case of difficulty in opening the membrane of Lilliequist
- The cisternal spaces are thoroughly irrigated with normal saline to clear out the subarachnoid blood blocking the cisterns.
- A cisternal drain is placed in the basal cisterns and exited from an opening separate from the main incision.

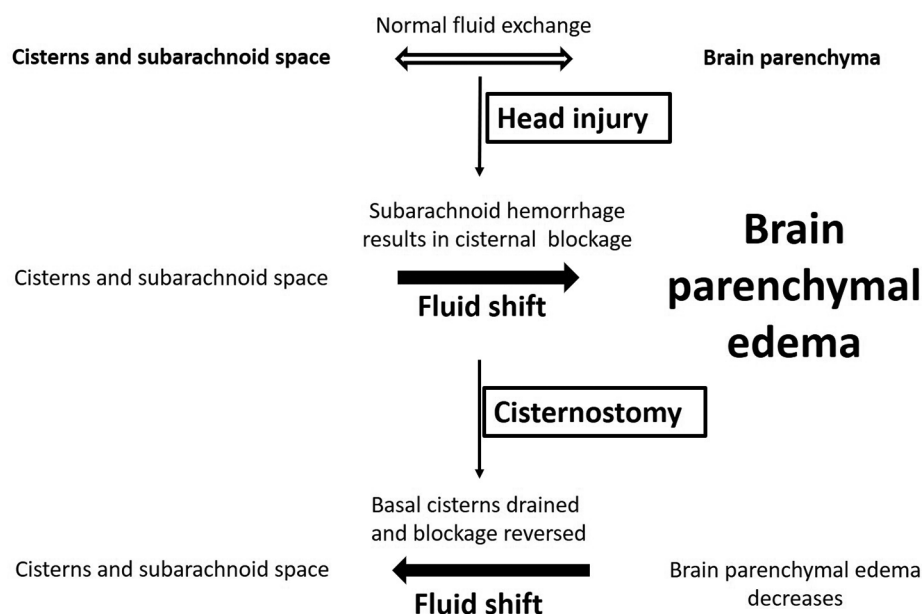


Fig. 1 Pathophysiology of brain edema in traumatic brain injury and its reversal by basal cisternostomy.

As soon as the inter-optic cistern is opened and CSF drained, the brain becomes lax. According to Cherian et al, there is a “2-minute” window for this step to be performed before the brain starts to bulge. The egress of the CSF from the inter-optic cistern makes the brain lax, allowing for the subsequent steps to be performed. It should be noted that the posterior clinoid process rarely needs to be drilled to approach the Lilliequist membrane. The basal cisternostomy part of the procedure after dural opening takes approximately 10 to 20 minutes extra.¹²

Literature on Basal Cisternostomy

Literature on basal cisternostomy in head injury is very limited. The paucity of literature may be attributed to the nonavailability of experienced neurosurgeons at late hours of night when most of these head trauma patients present to the emergency. In a study conducted by Cherian et al, the basal cisternostomy was initially performed in conjunction with DHC and as the surgeon’s experience increased, they started doing craniotomy and cisternostomy. In this study, the brain became lax following cisternostomy and the bone flap was repositioned without further complications.³ According to the authors, the major limitation in performing cisternostomy is the thorough acquaintance with the brain anatomy and good clinical experience since opening of the cisterns in a tight and swollen TBI affected brain is surgically challenging.

According to Cherian et al, the average time for cisternostomy from dural opening is approximately 20 minutes with extra time needed in case of posterior clinoid drilling or any other additional unforeseen circumstances. In this study, the authors performed cisternostomy in over 1,000 cases and found that it significantly decreased the intraoperative brain swelling, mortality, and morbidity.³ In this study, for severe head injuries, the mortality for cisternostomy was 13.8%, for DHC was 34.8%, and for DHC in conjunction with cisternostomy was 26.4%. Mean Glasgow Outcome Scale (GOS) at 6 weeks was 2.8 for DHC-treated patients, 3.7 for DHC with cisternostomy, and 3.9 for cisternostomy alone, respectively, in severe head injured patients. In their study, cisternostomy was also performed in the mild and moderate head injury group as a prophylactic measure in patients with acute subdural hemorrhage associated with mass effect and midline shift.³ In the published literature, the study by Cherian et al appears to be the only major study. However, this study is fraught with some major limitations, which are as follows:

- There is no information about the preoperative conditions (GCS, pupillary status) and any radiological information provided, so the homogeneity of the study groups cannot be verified.
- Results were not statistically supported.

- Follow-up period was limited for 6 weeks only while most TBI studies report outcome at 6 to 12 months.

Thus, it is clear that a randomized controlled trial needs to be performed where the neurosurgeons experienced in vascular neurosurgery are available for performing basal cisternostomy for all cases of head injury refractory to medical management. Only then the real worth of basal cisternostomy would be judged. Until then, the question whether the time has come to replace the age-old DHC with basal cisternostomy remains unanswered.

Conclusion

Although the pathophysiology behind the basal cisternostomy appears appealing, more robust data are required for its real worth to be proven or disproven.

Conflict of Interest

None declared.

References

- 1 Mahapatra AK, Patnaik A, Introduction. In: Mahapatra AK, Kamal R, eds. Textbook of Head Injury. 4th edition. New Delhi: CBS Publications; 2014;1–11
- 2 Cooper DJ, Rosenfeld JV, Murray L, et al. DECRA Trial Investigators; Australian and New Zealand Intensive Care Society Clinical Trials Group. Decompressive craniectomy in diffuse traumatic brain injury. *N Engl J Med* 2011;364(16):1493–1502
- 3 Cherian I, Yi G, Munakomi S. Cisternostomy: Replacing the age old decompressive hemicraniectomy? *Asian J Neurosurg* 2013;8(3):132–138
- 4 Grasso G. Surgical treatment for traumatic brain injury: is it time for reappraisal? *World Neurosurg* 2015;84(2):594
- 5 Marmarou A. A review of progress in understanding the pathophysiology and treatment of brain edema. *Neurosurg Focus* 2007;22(5):E1
- 6 Simard JM, Kent TA, Chen M, Tarasov KV, Gerzanich V. Brain oedema in focal ischaemia: molecular pathophysiology and theoretical implications. *Lancet Neurol* 2007;6(3):258–268
- 7 Stiefel MF, Tomita Y, Marmarou A. Secondary ischemia impairing the restoration of ion homeostasis following traumatic brain injury. *J Neurosurg* 2005;103(4):707–714
- 8 Unterberg AW, Stover J, Kress B, Kiening KL. Edema and brain trauma. *Neuroscience* 2004;129(4):1021–1029
- 9 DeWitt DS, Prough DS. Traumatic cerebral vascular injury: the effects of concussive brain injury on the cerebral vasculature. *J Neurotrauma* 2003;20(9):795–825
- 10 Iliff JJ, Wang M, Liao Y, et al. A paravascular pathway facilitates CSF flow through the brain parenchyma and the clearance of interstitial solutes, including amyloid β . *Sci Transl Med* 2012;4(147):147ra111
- 11 Iliff JJ, Chen MJ, Plog BA, et al. Impairment of glymphatic pathway function promotes tau pathology after traumatic brain injury. *J Neurosci* 2014;34(49):16180–16193
- 12 Cherian I, Bernardo A, Grasso G. Cisternostomy for traumatic brain injury: Pathophysiologic mechanisms and surgical technical notes. *World Neurosurg* 2016;89:51–57