

Original Article

Comparison of preoperative infraorbital block with peri-incisional infiltration for postoperative pain relief in cleft lip surgeries

V. Gaonkar, Swati R. Daftary

Department of Anaesthesia, Lokmanya Tilak Munciple Medical College and General Hospital, Mumbai - 400 022, India.

Address for correspondence: Dr. Swati R. Daftary, 1/262, Ashirwad, Dr. Annie Besant Road, Prabhadevi, Mumbai - 400 025, India.
E-mail: srdaftary@yahoo.com

ABSTRACT

In this prospective, randomized study, children undergoing cleft lip surgery were either given infra-orbital nerve block (n=25) or peri-incisional infiltration (n=25) pre-operatively with 0.25% bupivacaine in 1:2,00,000 adrenaline.

The overall course of anesthesia in both the groups was smooth, with excellent hemodynamic stability, indicating better pain relief during the intra-operative period. The concentration of the anesthetic agent required was reduced and recovery from anesthesia was rapid and complete. There was excellent postoperative analgesia. The children were calm and comfortable postoperatively.

We conclude that infra-orbital nerve block with 0.25% bupivacaine with adrenaline provides more prolonged analgesia than peri-incisional infiltration in cleft lip repair. Infra-orbital block given by modified approach is easy to perform and free of side-effects.

KEY WORDS

Surgery: Cleft lip; Pain relief: Infraorbital block, peri-incisional infiltration.

INTRODUCTION

Anesthesia for cleft lip surgery has undergone a major change from the now primitive methods of chloroform (1847) and open ether technique (1930) to controlled ventilation using muscle relaxants.^{1,2} However, cleft lip surgery and surgery involving the lower eyelid, cheek, upper lip and alae-nasi are associated with appreciable postoperative pain in children.

Adequate postoperative analgesia in children is a vital

part of peri-operative care, as postoperative pain can have adverse physiological and psychological effects. Good pain relief minimizes the oxygen requirement, reduces cardio-respiratory demands, and promotes early ambulation and recovery.

Regional block given preoperatively in combination with general anesthesia (GA) provides good preemptive analgesia. It is associated with perioperative hemodynamic stability, rapid and complete recovery and reduced analgesic requirement in the postoperative period.

At our institute, we carried out a prospective study in 50 pediatric patients undergoing repair of primary cleft lip, or corrective surgeries like cleft rhinoplasty to compare two different techniques of regional block, infraorbital block and peri-incisional infiltration with GA for their effectiveness in postoperative pain relief. We used Hanallah's objective pain scale to assess pain relief in these pediatric patients.

MATERIALS AND METHODS

Fifty pediatric patients of ASA Class I admitted to the hospital for repair of cleft lip or secondary surgeries of lip were studied. Patients were randomly allocated to receive either preoperative bilateral infra-orbital block with 0.25% bupivacaine-adrenaline (1:200000) (n=25) or peri-incisional infiltration with 0.25% bupivacaine-adrenaline (1:200000). These groups were called "Group I" or "Group P" respectively. Each patient underwent a thorough pre-anesthetic evaluation. The anesthesia procedure was explained to the parents/guardian and informed, valid consent was obtained from them. Oral atropine 0.03 mg/kg was given half an hour before induction after confirming 6 hours of starvation.

Anesthesia was induced with halothane (0.5 to 2.5%) in nitrous oxide (50%) and oxygen (50%) using Jackson-Rees modification of Ayer's T-piece. Once the patient was sleeping, intravenous access was secured using a 22G/24G cannula and Isolyte P (IV fluid) was started. After switching off halothane and nitrous oxide, thiopentone sodium was administered intravenously in a dose of 5 mg/kg followed by suxamethonium in a dose of 2 mg/kg after confirming the feasibility and adequacy of ventilation. After inflation of the patient's lungs with 100% oxygen, an orotracheal oxford tube / RAE (South polar) tube of an appropriate size was passed under direct laryngoscopy. Bilateral equal and clear air entry was confirmed on auscultation and the tube was fixed. The patient was placed on warming mattress to prevent hypothermia. An oropharyngeal pack was inserted after positioning the patient for surgery. Anesthesia was maintained with nitrous oxide (60%), oxygen (40%) and halothane (1%) and vecuronium with intermittent positive pressure ventilation using Jackson Rees circuit.

Patients either received bilateral infra-orbital block (1 ml each) or peri-incisional infiltration with 0.25% bupivacaine in 1:200000 adrenaline after confirming negative aspiration for blood. Infra-orbital block was given at a point on an imaginary line connecting the pupil and angle of the mouth which was bisected by the perpendicular dropped from the alae nasi (Figure 1). In Group P the surgeon infiltrated the incision with the same solution and the quantity of solution required was noted. Surgeons also infiltrated additional saline adrenaline (1:100000) in the operative area in all the patients as and when required to reduce oozing, not exceeding the dose of adrenaline 10 mcg/kg body weight/hr. Additional requirement of adrenaline thus required was noted in mcg/kg.

Intraoperatively ECG, SpO₂, NIBP and Temperature were monitored. Maintenance IV fluid required was calculated as per body weight formula. Parameters like pulse rate, BP and oxygen saturation were noted down as baseline and every 10 minutes intra-operatively for a period of one hour and thereafter every 15 minutes for 2 hours. Duration of surgery and intra-operative complications if any (hypotension, cardiac arrhythmias, bupivacaine toxicity, bleeding) were noted.

Post-operative pain relief scoring was measured according to Hanallah's ten-point score for a total

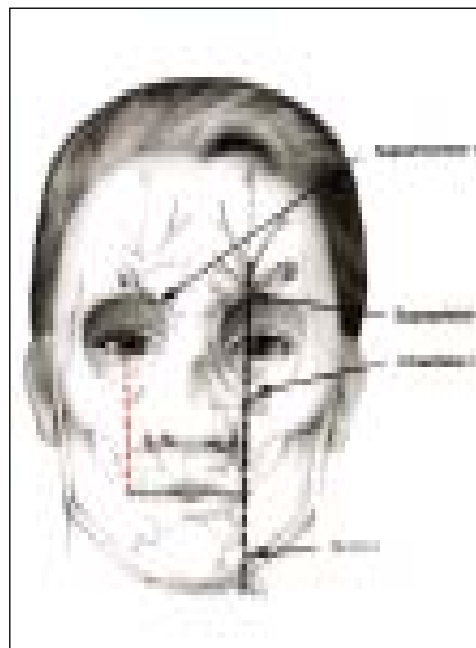


Figure 1: Red lines showing marking for modified Infraorbital block

period of 36 hours and time to rescue analgesic was noted. Syrup paracetamol was given as a rescue analgesic.

The duration of surgery and time to first analgesic were compared between the two groups using analysis of variance. Pain scores were compared by Kruskal-Wallis analysis of variance. A value of $P < 0.05$ was considered statistically significant.

RESULTS

In this prospective, randomized study, 50 children belonging to ASA Class I, undergoing cleft lip surgery were given either bilateral infraorbital block (n=25) or peri-incisional block (n=25) preoperatively. Table 1 shows that both the groups were comparable with respect to the age and weight of the patients and duration of the surgery.

Figure 2 depicts mean intra- and postoperative heart rate (HR) and systolic blood pressure (BP) readings of both the groups. It shows a steady rise in the HR and systolic BP in both the groups for the first 20 min and 10 min respectively. However, there was no statistically significant difference between the two groups.

Peri-operative oxygen saturations were maintained at 99-100% in both the groups and were comparable.

Table 1: Demographic data

	Group I Mean ± SD n=25	Group P Mean ± SD n=25
Age in months Range: 4 - 72	20.28 ± 23.76	22.24 ± 20.88
Weight in Kg	7.71 ± 3.15	8.73 ± 2.47
Duration of surgery in minutes	104.4 ± 18.1	109.8 ± 23.61

Group I – Infra-orbital block

Group P – Peri-incisional block




Figure 2: Graph showing perioperative hemodynamics in both the groups

HR (I) = Perioperative HR of Group I (Infraorbital block)

HR (P) = Perioperative HR of Group P (Peri-incisional block)

SBP (I) = Perioperative systolic BP of Group I

SBP (P) = Perioperative systolic BP of Group P

Post-operative pain relief in both the groups was comparable in the first 24 hours except at 6 hours, where patients in Group P had lower pain scores ($P < 0.05$) compared to Group I. Postoperative pain relief was of significantly longer duration in Group I as compared to Group P as seen from Table 2. Further, Group P required a significantly lesser dose of adrenaline as compared to Group I.

DISCUSSION

The use of local nerve blocks for postoperative pain relief in infants and children has gained popularity in recent years, as it provides a worthwhile pain-free period and avoids the complications of opioid analgesics. Surgery for repair of cleft lip is a common procedure in infants and young children in India. Bilateral infra-orbital nerve block¹ provides sensory blockade of the upper lip, side of nose, mucous membrane lining the nasal vestibule and the skin of the lower eyelids. We designed a study to evaluate the efficacy of bilateral infra-orbital nerve block for relief of pain following repair of cleft lip and to compare it with the commonly practiced peri-incisional infiltration.

Bupivacaine was chosen, as lignocaine has been shown to lead to a shorter pain-free period.² We gave bupivacaine 0.25% with 1:200000 adrenaline preoperatively for intra- as well as postoperative analgesia. If postoperative analgesia is the only objective, then 0.125% bupivacaine with adrenaline given at the end of the surgery may be adequate. A study by Prabhu *et al*¹ showed that postoperative infraorbital block with 0.125% bupivacaine provides pain relief for 8 hours while Nicodemus *et al*³ used 0.5% bupivacaine in postoperative infraorbital block with pain relief for almost 20 hours.

Adrenaline was added to 0.25% bupivacaine in our study

Table 2: Comparison of time to first analgesic and dose of adrenaline used

	Group I Mean ± SD n =25 each	Group P Mean ± SD n =25 each
Time to first analgesic (hours)	29.00 ± 2.08	24.08 ± 1.82*
Adrenaline used (mcg/kg)	5.60 ± 1.84	4.67 ± 1.20*

* $P < 0.01$

to delay the absorption and hence prolong the effect, reduce the circulatory bupivacaine levels, detect intravascular injection and counteract the vasodilatation caused in the area by blocked sympathetic nerves. In our hospital, plastic surgeons regularly mark out the cleft lip correction and infiltrate the incision with saline adrenaline (1:100,000). The maximum quantity allowed is 1 ml/kg of 1:100,000 adrenaline saline (i.e. 10 mcg/kg). We decided to use this practice of infiltration and accordingly designed our study in which instead of saline adrenaline (1:100,000) in Group P our plastic surgeons did peri-incisional infiltration with 0.25% bupivacaine with adrenaline (1:200,000) up to 1 ml/kg and Group I received bilateral infra-orbital block with 0.25% bupivacaine with adrenaline (1:200,000) 1 ml on each side preoperatively.

Conventional infraorbital nerve block⁴ may be associated with injury to the nerve or accompanying artery or puncturing the floor of the orbit. We avoided these complications by a modified approach where the block is given lower down as shown in Figure 1. None of the patients of Group I had failed block. None of the patients had any complications related to the simultaneous use of halothane and adrenaline with bupivacaine.

In our study, the groups were compared with respect to age, weight, the duration of surgery, perioperative pulse rate, systolic blood pressure and oxygen saturation, post-operative pain scores, dose of adrenaline required excluding the first dose and time to first analgesic. The age, weight and duration of surgery were comparable in both the groups as shown in Table 1. Patients of both the groups were haemodynamically stable throughout the perioperative period as shown in Figure 2. The difference was not statistically significant. This indicated good pain relief in all the patients in the absence of additional analgesics. Temperature and oxygen saturation were maintained within normal limits in all the patients.

The amount of adrenaline used was significantly less ($P<0.05$) in Group P, after omitting the first dose as shown in Table 2. The decreased requirement of additional adrenaline in the peri-incisional group was

because of local vasoconstriction. In Group I, the block causes sympathetic blockade and resultant vasodilatation, leading to increased oozing. Additional adrenaline requirement though more in Group I, was within safe dose limit.

Hannallah's pain scores were noted in both groups. Hannallah's pain discomfort scale⁵ considers six parameters like blood pressure, crying, movement, agitation, posture and verbalization. When the total pain score is more than 7 (maximum score=12), twice during a five-minute period, additional analgesia is needed. Both groups had lower resting values which denote good analgesia. Qualitative pain relief was better with peri-incisional infiltration as at all times more patients in Group P had lower scores. The difference was not statistically significant except at 6 hours postoperatively when pain relief in Group P was found to be better (76%) as compared to Group I (48%). The duration of analgesia in both the groups showed a significant difference. Group I had good pain relief (score<4) for up to 29 hours whereas Group P had it up to 24 hours. Thus it was seen that infra-orbital block patients had delayed time to first analgesic as compared to the peri-incisional infiltration patients ($P<0.05$). None of the patients had suture line healing problems.

CONCLUSION

We conclude that modified infra-orbital nerve block is easy to perform and is free of complications. Bilateral infra-orbital block given with 0.25% bupivacaine in 1:200000 adrenaline provides more prolonged analgesia than peri-incisional infiltration in cleft lip repair. The quality of analgesia and the operative field provided by peri-incisional infiltration is better compared to infra-orbital nerve block. Additional adrenaline infiltration is required with infra-orbital block for a dry field, but requirements are within the safe dose limit and do not cause any side-effects.

We recommend the use of either bilateral infra-orbital block or peri-incisional infiltration with 0.25% bupivacaine in 1:200000 adrenaline preoperatively for cleft lip surgery to provide good perioperative analgesia lasting up to 24 hours.

REFERENCES

1. Prabhu KP, Wig J, Grewal S. Bilateral infra-orbital nerve block is superior to peri-incisional infiltration for analgesia after repair of cleft lip. *Scand J Plast Reconstr Surg Hand Surg* 1999;33:83-7.
2. Datta A, Ahuja S, Krishnan A. Infra-orbital nerve block for relief of postoperative pain following cleft lip surgery in infants. *Anaesthesia* 1994;49:441-4.
3. Nicodemus HF, Ferrer MJ, Decastro L, et al. Bilateral infraorbital block with 0.5% bupivacaine as postoperative analgesia following cheiloplasty in children. *Scand J Plast Reconstr Surg Hand Surg* 1991;25:253.
4. Tucker JH and Flynn JF. Head and neck regional blocks. In: Brown DL, editor. *Regional Anesthesia and Analgesia*. Philadelphia: W B Saunders Company; 1996. p. 240-53.
5. Hanallah RS, Broadman LM, Belman AB. Comparison of caudal and ilioinguinal / iliohypogastric nerve blocks for control of post orchiopexy pain in pediatric ambulatory surgery. *Anesthesiology* 1987;66:832-4.