

## Original Article

# Different levels of undermining in face lift - experience of 141 consecutive cases

**Pietro Panettiere, Lucio Marchetti, Danilo Accorsi, Giovanni-Alberto Del Gaudio**

Università degli Studi di Bologna, Dipartimento di Discipline Chirurgiche, Rianimatorie e dei Trapianti, Clinica Chirurgica IV, Italy.

**Address for correspondence:** Pietro Panettiere, Università degli Studi di Bologna, Dipartimento di Discipline Chirurgiche, Rianimatorie e dei Trapianti, Clinica Chirurgica IV, Policlinico S. Orsola, via Massarenti, 9, 40128 Bologna (Bo), Italy. E-mail: prof.panettiere@jumpy.it

### ABSTRACT

**Context:** The most revolutionary concept in rhytidectomy is the role of Sub Muscular Aponeurotic System (SMAS), even if many alternative approaches have been proposed. The main aim of face lift is to bring back the time, preventing the “lifted-face” appearance. **Settings and Design:** The authors present their personal experience with different levels of undermining, i.e. subperiosteal forehead lift, subcutaneous midface lift with SMAS plication and platysmal suspension, and discuss the anatomical and biomechanical elements of rhytidectomy. **Results:** Optimal aesthetic results were achieved by repositioning the neck, face and forehead tissues in a global and harmonious fashion, without distorting face characteristics and disguising surgery trails as much as possible. **Conclusions:** Different levels of undermining can give good and stable aesthetic results minimizing the risks and preventing face distortion.

### KEY WORDS

Lifting, SMAS, platysma, face, neck, forehead, rhytidectomy.

### INTRODUCTION

The acknowledgment of the role played by the Sub Muscular Aponeurotic System (SMAS) radically changed the approach to rhytidectomy. Each face layer suffers from aging effects differently depending on its biomechanical features, on its location and on the presence of anatomical suspension points. The technique proposed by us aims at correcting face-aging effects by individually repositioning the neck, face and forehead layers in a harmonious fashion, preventing face distortion.

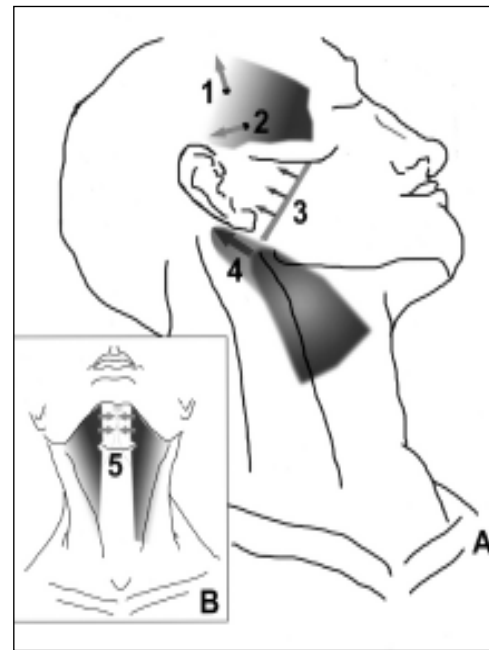### MATERIALS AND METHODS

From 1996 to 2001, 141 consecutive patients (average age 55 years, range 45-77 years, 137 women, 4 men) underwent face-neck-lift. The main associated factors were smoking (27% were heavy smokers) and moderate hypertension (12%). Fourteen surgeries (10%) were secondary procedures. All patients presented with face ptosis, associated with neck laxity in 125 patients (89%), brows descent in 24 (17%), blepharocalasis in 87 (62%) and perioral wrinkling in 25 (18%).

Under general anesthesia, a standard incision was

performed and the SMAS was exposed by a delicate subcutaneous dissection of the cheeks extending superiorly to the zygomatic arch, medially to the nasolabial fold, and caudally connecting to the neck dissection plane. The subcutaneous dissection plane was always as close as possible to the SMAS to preserve the superficial vascular net. The undermining continued cephalad just superficial to the temporalis fascia, extending medially to the *orbicularis oculi* muscle. All the patients received forehead undermining: 24 patients (with evident eyebrows descent) underwent a coronal subperiosteal lift, while the others received a blind dissection subperiosteal forehead lift. Forehead periosteum elevation was extremely easy even if performed by blind dissection, using an endoscopic dissector. No particular care was required at this level, besides when reaching the orbital margins, where the supraorbital artery and nerve were protected by simply keeping one finger delicately pressed against the supraorbital notch. Undermining extended beyond the orbital margin in all patients, until reaching the *orbicularis oculi* muscle. When glabellar wrinkling was evident, procerus and corrugator supercilii muscles were also divided. The superficial temporalis fascia was then suspended to the deep temporalis fascia by two non-absorbable stitches (4.0 Polypropilene) directed respectively cephalad and posteriorly (Figure 1, A1-2) in order to prevent eye profile distortion.

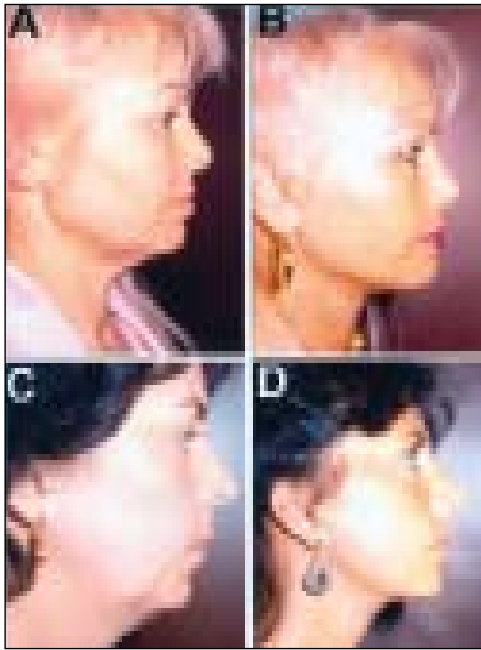The neck was widely undermined, preceded by reduced pressure submental liposuction when necessary. When marked neck tissue laxity was present, the platysma was released from the sternocleidomastoid muscle and dissected for about 5 to 6 cm, and its margin was secured with non-absorbable (5.0 Polypropylene) stitches to the mastoid eminence (Figure 1, A4). After both sides had been properly exposed, a 2 cm wide SMAS band from the zygomatic eminence to the ear lobule insertion (Figure 1, A3) was either resected or plicated (depending on the amount of tissue to be redistributed) and sutured with non-absorbable stitches (5.0 Polypropylene). The traction vector was therefore directed from the oral rim to the auricularis tubercle in the midface and from the thyroïdal cartilage to the mastoid eminence in the neck. SMAS treatment was always performed after both sides had been fully dissected, in order to calibrate and balance the tension,



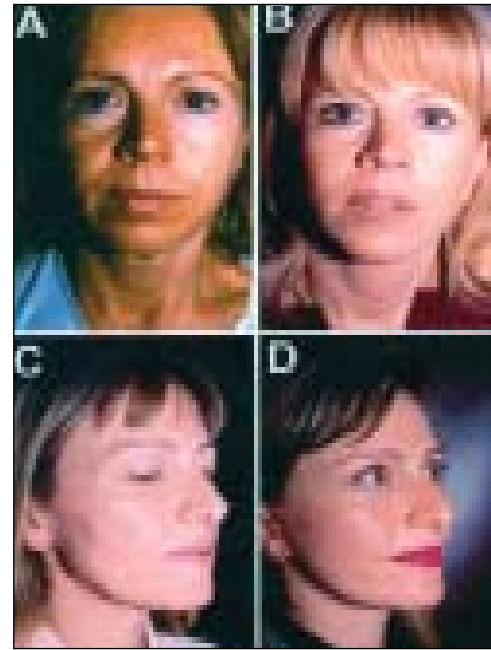**Figure 1:** A: a schematic representation of the triplanar dissection and tension lines. 1 and 2: sutures of the temporalis fascia. 3: SMAS section line and tension direction. 4: platysmal tensioning direction. B: (in the cartouche) treatment of platysmal bands.

also keeping in mind the anesthesia-induced relaxation. Platysmal bands were treated by excising two muscular triangles (about 1.5 cm long) near the hyoid bone (Figure 1, B5) and then approximating and suturing the bands in their supra-hyoid tract. Skin resection and sutures completed the procedure as usual. All procedures were performed by the senior author and only the superficial sutures were a “four hands work”. The average surgery time was  $175 \pm 25$  minutes, excluding the time required for major associated procedures. Blood pressure was strictly monitored (NIBP) during the operation and for the first six hours after surgery, keeping a slight hypotension during undermining, and resuming the preoperative values when performing hemostasis. The undermined areas were dressed using an adhesive sponge (Reston®) to prevent postoperative hematomas. A subcutaneous suction drainage was kept in place for 24 hours, while the slightly compressive elastic dressing was removed six days after surgery. All patients received antibiotics for five days.

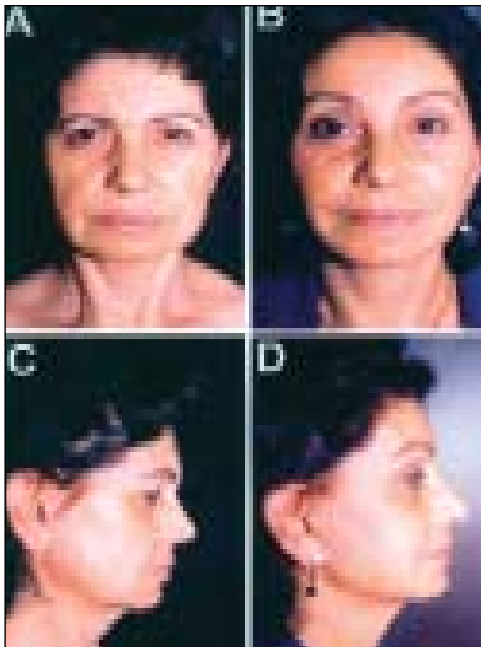All the 141 patients underwent a face-neck lift associated [in 125 patients (89%)] with platysmal suspension (Figure 2-3) or platysmal bands treatment (Figure 3, 4 A-B). Coronal forehead lift was performed



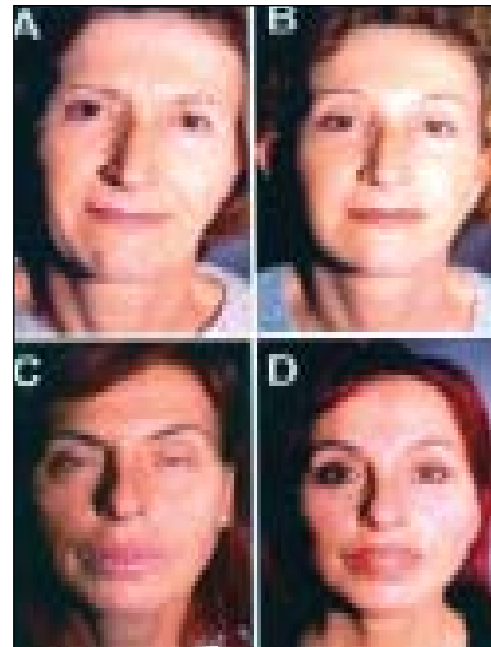
**Figure 2:** A: preoperative; face and neck ptosis with abnormal submental angle. B: five months after face and neck lifting with SMAS treatment, platysmal suspension and blepharoplasty. A good correction of ptosis was achieved and the normal submental angle was restored. C: preoperative; face and neck ptosis with extreme abnormality of submental angle. D: one year after face and neck lifting with SMAS and platysmal suspension, mandible's profile correction and blepharoplasty. An optimal submental angle was achieved.



**Figure 4:** A: preoperative; face and neck ptosis with moderate platysmal bands. B: 18 months after face and neck lifting with platysmal band treatment and blepharoplasty. C: preoperative; marked face and neck ptosis, and severe perioral wrinkling. D: six months after face and neck lifting, perioral dermabrasion and blepharoplasty.



**Figure 3:** A: preoperative; severe complete face ptosis with glabellar wrinkling and evident platysmal bands. B: three months after endoscopic brows lifting with procerus muscle and corrugator supercillii muscles division, and face and neck lifting with platysmal band correction. C: preoperative lateral view of the same patient, showing an abnormal submental angle. D: three months after surgery, the normal submental angle was restored.



**Figure 5:** A: preoperative; a complete face ptosis is evident with marked nasolabial folds and glabellar wrinkling. B: three months after coronal subperiosteal lifting with procerus muscle and corrugator supercillii muscles division and face and neck lifting. A good correction of the nasolabial fold was also achieved. C: preoperative; a severe brows laxity with glabellar wrinkling and face ptosis are present. D: three months after coronal subperiosteal lifting and face and neck lifting with procerus muscle and corrugator supercillii muscles division.

in 24 patients (17%) (Figure 5), upper eyelid blepharoplasty in 87 patients (62%, Figure 2 A-B, 4 A-B) and lower lid blepharoplasty in 39 patients (28%) (Figure 4 C-D). Seven patients with blepharocalasis and huge lower lids fat pads (5%) received delayed lower lid blepharoplasty (about six months after face lift), in order to obtain better fat resection and prevent hollow eyes formation. Perioral dermabrasion was carried out in 16 patients (11%, Figure 4 C-D), submental liposuction in 11 (8%), synchronous rhinoplasty in 11 (8%) and mandibular profile correction in four (3%, Figure 2 C-D). Only face lift was performed in 38 patients (27%), face lift with or without synchronous blepharoplasty in 99 (70%), while face lift with other associated procedures (submental liposuction, perioral dermabrasion, rhinoplasty or mandibular profile correction) in 42 patients (30%).

## RESULTS

Edema and postoperative hematomas were significantly reduced and well hidden by camouflage make-up seven or ten days after surgery in all cases. All patients requested analgesics for no more than two days.

A small 3 to 4 mm wide, cutaneous necrosis in the preauricular area occurred in one patient (a secondary lifting in a heavy smoker), and was resolved by necrosectomy, a minimal undermining and re-suture in an outpatient setting. A transitory unilateral facial nerve weakening occurred in one patient receiving associated mandibular profile correction. The overall complications rate was 1.4%.

The one-year follow-up standard pictures were examined by two independent, well-trained plastic surgeons. They were asked to assess the appropriateness of the lift and the naturalness of the aspect. They considered the results in 96% of the patients as satisfactory. In three patients (2.1%) insufficient flattening of the nasolabial folds occurred, while perioral wrinkling persisted in two patients (1.4%); in one patient (0.7%) a minimal variation of the ear slope occurred. All defects were mild or moderate and no patient asked for revision surgery.

No significant difference was found in the overall aesthetic results between the patients receiving face lift only (with or without blepharoplasty) and those receiving associated procedures (rhinoplasty, submental liposuction, mandibular profile correction or perioral dermabrasion). The complications rate was higher in the latter group (2% vs. 1%), but no significant difference was found when the chi-square test was applied. No significant difference was found in the overall aesthetic results between patients receiving coronal lifting and those receiving blind forehead dissection.

The average follow-up was 58 months (range: 26 - 95 months, dropout: 8%). The degree of satisfaction was very high and the majority of the patients required no further treatment. In eight patients (6%), fillers injection for superficial wrinkling was performed (minimum 51 months after surgery).

## DISCUSSION

The aim of face-neck lift is to rejuvenate the face and the neck, avoiding the so-called "face-lifted" appearance,<sup>1</sup> whilst minimizing the risks.

Our approach to performing a face lift is based on biomechanical and anatomical considerations. The periosteum undergoes no aging-related plastic event but it can preserve the tension applied to it due to its very high breaking strength and its scarce or null stress-relaxation effect. The way that overlaying structures follow periosteal stretching depends on the thickness and the number of the superimposing planes. SMAS stretching is the basis for modern rhytidectomy surgery. It is its high-stretch resistance and its scarce extensibility which makes SMAS tensing relatively stable over time.<sup>2</sup> Skin breaking strength is high, but its strong plastic properties can rapidly reset stretching effects. In our opinion, skin undermining should be wide (i.e. if an envelope is wider than its content, it should be trimmed to fit it) and as close to the SMAS as possible, in order to preserve the fine and rich superficial vascular net. The lateral part of the face is supplied by arteries passing through the SMAS. Nevertheless, subcutaneous undermining seems to

have no effect on the vitality of the skin flap.<sup>3,4</sup> In our experience, no ischemic lesion occurred when no specific risk factor was present (secondary lifting, heavy smokers) perhaps because of the accurate skin dissection that preserved the superficial vascular net.

In the neck area, the distance between fix anchoring points and superficial layers is much higher than in the face, and all structures act essentially as bridges between the mandible and the hyoid bone, the sternum and the clavicle. Relaxation is more evident in the sector between the chin and the hyoid bone, where the platysma plays an essential role. In the technique we are proposing, the excess of laxity is redistributed laterally and superiorly, harmonizing the platysmal tension with SMAS stretching in the midface, and thus restoring the submental angle. When platysmal bands are evident, the excision of two small tissue triangles improves the results by increasing the length of platysmal medial margins.

The effect of gravity on the tissues cannot be simplified as a vertical drop, thus different resistance and elasticity, fixed points (the lateral aspect of the nose, the anterior profile of the ear), and less sliding areas (the malar eminence) should be considered. The resulting vectors are therefore differently directed in each area. The three-zone undermining technique stems from these considerations. The temporalis fascia tensioning during subperiosteal forehead lifting determines a good distension of the lateral part of the midface and prevents the eye profile distortion, with optimal tissue redraping and no need of supplementary scars<sup>5</sup> or subperiosteal midface undermining.<sup>1,6</sup>

The medial portion of the SMAS has a much more scattered and irregular collagen architecture and exhibits greater distensibility.<sup>7</sup> In our technique, the SMAS is either resected or plicated more medially than in traditional techniques, in order to take full advantage of this peculiarity.

The basic concept of both composite flaps<sup>8</sup> and subperiosteal rhytidectomy is to maintain the physiologic relationships between planes.<sup>9</sup> But the aging process does not act “en-bloc”: the skin, the SMAS and the underlying muscles have different elastic

features and are relatively free to slide reciprocally. So, in our opinion, “en-bloc” corrections cannot reset the relationships among the planes, but they simply reposition all the layers a bit cephalad, so that those undergoing less creeping could result excessively high and those more relaxed could appear as insufficiently corrected.

The cornerstones of our approach to face lift are:

- individual repositioning of each plane
- taking advantage of the biomechanical features of each layer and
- harmonization of the forehead, the face and the neck

We agree with Hamra<sup>1</sup> in pointing out that forehead undermining is wrongly considered optional<sup>10</sup> thus exposing to the risk of the so-called “lifted-face” appearance. In our experience, forehead undermining associated with temporal fascia tensioning prevented the distortion of the eye profile. Further considerations should be made about associated lower lid blepharoplasty. We found accurate fat pads trimming much more difficult during face lift, because repositioning of the face tissues can give a distorted perception of the lower lids. Delayed lower lid blepharoplasty was therefore preferred when huge fat pads were present, preventing, in our experience, hollow eyes formation.

Our experience shows that good results can be achieved with different levels of undermining. Complication rates are comparable to or even lower than other techniques<sup>11-13</sup> and the duration of the surgery was acceptable. Associated procedures did not seem to influence either the results or the complication rates.

## REFERENCES

1. Hamra ST. Prevention and correction of the “face-lifted” appearance. *Facial Plast Surg* 2000;16:215-29.
2. Har-Shai Y, Sela E, Rubinstien I, Lindenbaum ES, Mitz V, Hirshowitz B. Computerized morphometric quantitation of elastin and collagen in SMAS and facial skin and the possible role of fat cells in SMAS viscoelastic properties. *Plast Reconstr Surg* 1998;102:2466-70.
3. Whetzel TP, Stevenson TR. The contribution of the SMAS to the blood supply in the lateral face lift flap. *Plast Reconstr Surg*

- 1997;100:1011-8.
4. Schuster RH, Gamble WB, Hamra ST, Manson PN. A comparison of flap vascular anatomy in three rhytidectomy techniques. *Plast Reconstr Surg* 1995;95:683-90.
  5. Hamra ST. Frequent face lift sequelae: Hollow eyes and the lateral sweep: Cause and repair. *Plast Reconstr Surg* 1998;102:1658-66.
  6. Heinrichs HL, Kaidi AA. Subperiosteal face lift: A 200-case, 4-year review. *Plast Reconstr Surg* 1998;102:843-55.
  7. Hagerty RC, Scioscia PJ. The medial SMAS lift with aggressive temporal skin takeout. *Plast Reconstr Surg* 1998;101:1650-6.
  8. Hamra ST. The deep-plane rhytidectomy. *Plast Reconstr Surg* 1990;86:53-61.
  9. Hamra ST. Composite rhytidectomy. *Plast Reconstr Surg* 1992;90:1-13.
  10. Carbonell A, Olveda J. Segmental stepwise lift: Two years of experience. *Aesthetic Plast Surg* 2002;26:105-13.
  11. Ivy EJ, Lorenc ZP, Aston SJ. Is there a difference? A prospective study comparing lateral and standard SMAS face lifts with extended SMAS and composite rhytidectomies. *Plast Reconstr Surg* 1996;98:1135-43.
  12. Finger ER. A 5-year study of the transmalar subperiosteal midface lift with minimal skin and superficial musculoaponeurotic system dissection: A durable, natural-appearing lift with less surgery and recovery time. *Plast Reconstr Surg* 2001;107:1273-83.
  13. Hobar PC, Flood J. Subperiosteal rejuvenation of the midface and periorbital area: A simplified approach. *Plast Reconstr Surg* 1999;104:842-51.

## Announcement

**9<sup>th</sup> Congress of Asian Pacific Section of IPRAS  
hosted by the Association of Plastic Surgeons of India  
19<sup>th</sup> to 23<sup>rd</sup> March 2005**

**Hotel Taj Mahal**  
Mumbai, India

Web Site: [www.apc-ipras2005.com](http://www.apc-ipras2005.com)

or Contact *Organising Secretary*:

**Dr. Mukund Thatte**  
at [mthatte@vsnl.com](mailto:mthatte@vsnl.com)

---

*Event Managers*

Travel Corporation (India) Pvt. Ltd.  
Chander Mukhi, Nariman Point,  
Mumbai - 400 021.

Tel: (022) 22021881 / 22027120

Fax: (022) 22029424

E-mail: [conf@tci.co.in](mailto:conf@tci.co.in)

[www.tciconferences.com](http://www.tciconferences.com)