

Basal Cell Adenoma of the Upper Lip from Minor Salivary Gland Origin

Elia Maria Minicucci^a
Eloisa Bueno Pires de Campos^a
Silke Anna Thereza Weber^b
Maria Aparecida Custodio Domingues^c
Daniel Araki Ribeiro^d

ABSTRACT

Basal cell adenoma is an uncommon benign salivary gland neoplasm, presenting isomorphic basaloid cells with a prominent basal cell layer. Taking into account that basal cell adenomas represent 1% of all salivary gland tumors, being the majority of cases in the parotid glands, the goal of this paper is to report a case of basal cell adenoma of the upper lip arising from minor salivary gland. (Eur J Dent 2008;2:213-216)

Key words: Basal cell adenoma; Minor salivary gland; Immunohistochemistry.

INTRODUCTION

Salivary gland tumors are uncommon and constitute 2–6.5% of all head and neck neoplasms.¹ Particularly, tumors of minor salivary gland origin account for less than 25% of all salivary neoplasms.²

Basal cell adenoma is a benign epithelial neoplasm with a uniform histologic appearance

dominated by basaloid cells. According to its morphology at microscopical levels, basal cell adenoma has been classified as solid (monomorphic), trabecular, tubular and membranous.³ However, basal cells are found in several primary salivary gland tumors either as a major component present in a mixture of cells types or as pure basal cell neoplasms.⁴ In this regard, the distinction between the true neoplasm and other primary tumors with basal cell features pose diagnostic sometimes difficult.⁵

In this current paper, we were able to report a case of basal cell adenoma from labial salivary gland origin in a Caucasian woman diagnosed by means of histopathological evaluation and confirmed by immunohistochemistry.

CASE REPORT

A 51-years-old Brazilian Caucasian woman was admitted in the Stomatology Service of the Department of Dermatology and Radiotherapy

- ^a Department of Dermatology and Radiotherapy, Botucatu Medical School, Sao Paulo State University, SP, Brazil.
 - ^b Department of Ophthalmology and Otorhinolaryngology, Botucatu Medical School, Sao Paulo State University, SP, Brazil.
 - ^c Department of Pathology, Botucatu Medical School, Sao Paulo State University, SP, Brazil.
 - ^d Department of Biosciences, Federal University of Sao Paulo, UNIFESP, Santos, SP, Brazil.
- Corresponding author: Daniel Araki Ribeiro, DDS, PhD
Departamento de Biociências Av. Ana Costa, 95
Vila Mathias, Santos – SP, Brazil
Zip code: 11060-001 Phone: + 55 13 32222048
Fax: + 55 13 32222048
E-mail: daribeiro@unifesp.br

at the Hospital of the Botucatu Medical School in 2006 with a painless swelling in the upper lip. Intraoral examination revealed a hardened delimited nodule of 4 cm in diameter, presenting violet color covering normal mucosa with no ulceration (Figure 1). She related that the lesion began 5 years ago, being its development slow, progressive and painless. The clinical diagnostic was established as pleomorphic adenoma or vascular neoplasms. After that, an excisional biopsy was carried out by a dentist under local anesthesia and the specimen was put into 10% buffer formalin. During the surgery, the behavior of lesion was similar to vascular neoplasm, in which there was bleeding when the capsule of the lesion was ruptured.

The specimen underwent histotechnical procedures and was stained with hematoxylin and eosin (H.E.). Microscopically, the tumor is composed of isomorphic basaloid cells with a prominent basal cell layer, a distinct basement membrane-like structure and no mucoid stromal component as in pleomorphic adenomas (Figure 2). In order to confirm the diagnosis on H.E. slides, immunohistochemistry was performed in this case. Thus, serial sections of 4 µm were deparaffinized in xylene and rehydrated in graded ethanol, then pretreated in a microwave (Electrolux, SP, Brazil) with 10mM citric acid buffer (pH=6) for 3 cycles of 5 min each at 850 W for antigen retrieval. They were pre-incubated with 0.3% hydrogen peroxide in PBS for 5 min for inactivation of endogenous peroxidase, and then blocked with 5% normal goat serum in PBS for 10 min. The specimens were then incubated with anti-cytokeratin 7 polyclonal antibody (Santa Cruz

Biotechnology, USA) at a concentration of 1:100 or anti-calponin (Santa Cruz Biotechnology, USA) at 1:200 concentrations. Incubation was carried out overnight at 4°C within the refrigerator. This was followed by two washes in PBS for 10 min. The sections were then incubated with biotin-conjugated secondary antibody anti-rabbit IgG (Vector Laboratories, Burlingame, CA, USA) at a concentration of 1:200 in PBS for 1 h. After that, the sections were washed twice with PBS followed by the application of preformed avidin biotin complex conjugated to peroxidase (Vector Laboratories, Burlingame, CA, USA) for 45 min. The bound complexes were visualized by the application of a 0.05% solution of 3-3'-diaminobenzidine solution, and counterstained with Harrys hematoxylin. For control studies of the antibodies, the serial sections were treated with rabbit IgG (Vector Laboratories, Burlingame, CA, USA) at a concentration of 1:200 in place of the primary antibody.

The immunohistochemical findings showed expressivity either to cytokeratin (Figure 3) or to calponin (Figure 4). Both immunomarkers showed a strong pattern in tumor cells. Taken as a whole, these findings supported the final diagnosis of basal cell adenoma in the upper lip. No recurrences were detected up to now (six months after surgery).

DISCUSSION

Salivary gland tumors are uncommon, comprising less than 3% of all head and neck tumors.⁶ The majority of salivary gland tumors were located in the parotid gland.^{7,8} These neoplasms point out predominance of benign over

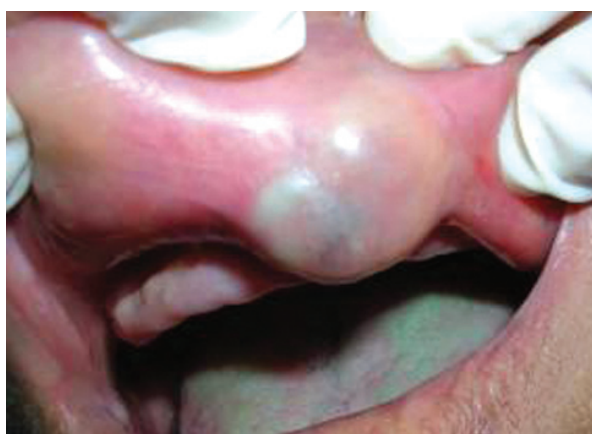

Figure 1. Clinical presentation of basal cell adenoma.

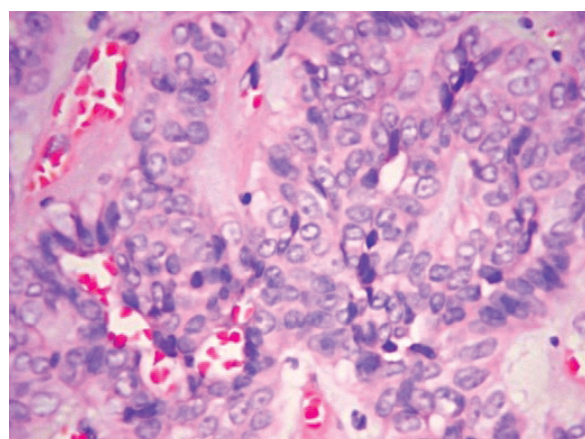


Figure 2. Photomicrography of basal cell adenoma (H.E. stain, x100 magnification).

malignant tumors.⁹ In most studies, pleomorphic adenoma is the most common minor salivary gland tumors⁹ with a incidence ranging from 33% to 70% of all and from 70.6% to 100% of benign tumors,^{10,11} with incidence for about 33% of total.⁶ With respect to basal cell adenoma, it is an uncommon benign salivary gland neoplasm and the majority of cases arise in the parotid gland of elderly patients.¹² Herein, the goal of this paper is to report a case of basal cell adenoma arising from minor salivary gland of the upper lip.

Microscopically, minor salivary glands tumors constitute a heterogeneous group of neoplasms with great histomorphologic variation.¹³ Regarding basal cell adenomas, they may present form solid trabecular structures and cords of neoplastic epithelial cells with peripheral layer of cell demonstrating palisading. The stroma may be quite vascular, but it does not have the myxoid quality seen in pleomorphic adenoma. In this report, basal cell adenoma was classified as solid variant consisting of uniform-appearing with small cells (Figure 2). These

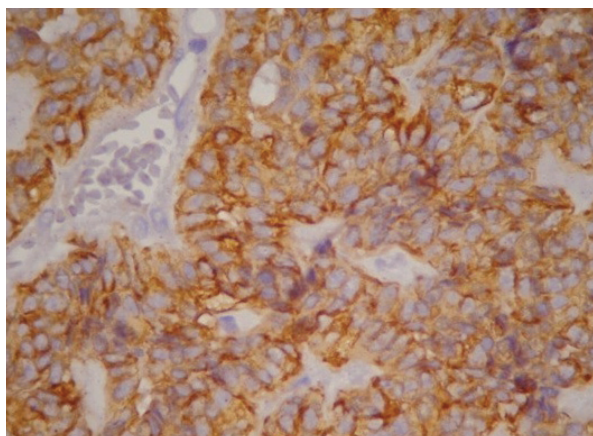


Figure 3. Immunohistochemistry for cytokeratin 7 (x100 magnification).

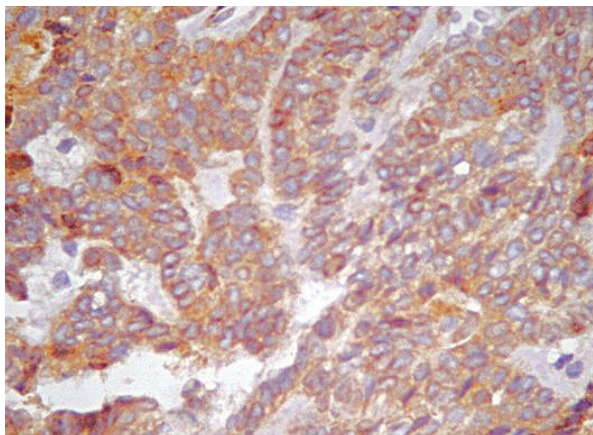


Figure 4. Immunohistochemistry for calponin (x100 magnification).

were arranged in large compact aggregates in which the outer layer is palisaded. In addition, intercellular deposits and basiquamous whorls in the globular ends of epithelial islands were found. It is important to stress that challenges to microscopic diagnosis include biphasic differentiation of salivary gland tumors even to the point of hybrid tumors with features of two different, well-defined tumor entities.¹⁴ With few immunohistochemical markers available for differentiation of tumors, accurate diagnosis of minor salivary gland tumor may be quite difficult. In order to help the histopathological diagnosis, we decided to use the immunohistochemistry. Such data have demonstrated strong positivity for calponin antibody (Figure 3), a marker of myoepithelial cells, and cytokeratin (Figure 4), an immunomarker for epithelial cells. Therefore, this emphasizes its epithelial and glandular origin.

Most studies have shown that minor salivary gland tumors are more common in females than males with a male-to-female ratio ranging from 1:1.02 to 1:2.0.² Moreover, major studies have also reported that the palate was the most common site for minor salivary gland tumors and that approximately 40–80% of all tumors occurred in this site.¹ In this case, the patient was female and the upper lip was the site of involvement of basal cell adenoma.

Altogether, this report supports the belief that the precise identification of lesions in the upper lip is important, particularly because basal cell adenoma has a potential to malignancy, as for example the conversion to basal cell adenocarcinoma.

REFERENCES

1. Leegaard T, Lindeman H. Salivary gland tumors: clinical picture and treatment. *Acta Otolaryngol Suppl* 1969;263:155-159.
2. Evenson JW, Cawson RA. Tumours of the minor (oropharyngeal) salivary glands: a demographic study of 336 cases. *J Oral Pathol* 1985;14:500-509.
3. De Souza SC, Soares de Araújo N, Correa A. Immunohistochemical aspects of basal cells adenoma and canalicular adenoma of salivary glands. *Oral Oncol* 2001;37:365-368.
4. Klijanienko J, El-Neggar AK, Vielh P. Comparative cytologic and histologic *Diagn Cytopathol* 1999;21:30-34.

5. Seifert G. Classification and differential diagnosis of clear and basal cell tumors of the salivary glands. *Semin Diagn Pathol* 1996;13:95-103.
6. Van der Wal JE, Snow GB, Van der Wal I. Histological reclassification of 101 intraoral salivary gland tumours (new who classification). *J Clin Pathol* 1992;45:834-835.
7. Ito FA, Ito K, Vargas PA, Almeida OP, Lopes MA. Salivary gland tumors in a Brazilian population: a retrospective study of 496 cases. *Int J Oral Maxillofac Surg* 2005;34:533-536.
8. Satko I, Longauerova P. Salivary tumors in the stomatological clinics in Bratislava. *J Craniomaxillofac Surg* 2000;28:56-61.
9. Vargas PA, Gerhard R, Araujo Filho VJF, Castro IV. Salivary gland tumors in a Brazilian population: a retrospective study of 124 cases. *Rev Hosp Clin Fac Med Sao Paulo* 2002;57:271-276.
10. Loyola AM, Araújo VC, Sousa SC, Araujo NS. Minor salivary gland tumors. A retrospective study of 16 cases in a Brazilian population. *Eur J Cancer B Oral Oncol* 1995;31B:197-201.
11. Riviera-Bastidas H, Ocanto RA, Acevedo AM. Intraoral minor salivary gland tumors: A retrospective study of 62 cases in a Venezuela population. *J Oral Pathol Med* 1996;25:1-4.
12. Huvos AG, Paulino, AFG. Salivary glands. In: Sterberg SS (ed). *Diagnostic surgical pathology* (ed 3). Philadelphia, pa. Lippincott Wilkins & Wilkins, 1999, pp. 853-884.
13. Yih WY, Kratochvil FJ, Stewart CB. Intraoral minor salivary gland neoplasms: review of 213 cases. *J Oral Maxillofac Surg* 2005;63:805-810.
14. Seifert G, Donath K. Hybrid tumors of salivary glands. Definition and classification of five cases. *Eur J Cancer B Oral Oncol* 1996;32B:251-259.