

Impacted Primary Tooth and Tooth Agenesis: A Case Report of Monozygotic Twins

A. Zeynep Zengin^a
A. Pinar Sumer^a
Emine Karaarslan^b

ABSTRACT

In the present report, a case of 19 year-old monozygotic twin brothers with similar tooth agenesis and impacted primary teeth is presented. Both twins (HDH, DHH) had agenesis of ten and eleven teeth (respectively), third molars excluded, consistent with oligodontia and both had four impacted primary teeth and the permanent successors of all these primary teeth were congenitally missing. The occurrence of similarly located tooth agenesis and primary impacted teeth in monozygotic twins may suggest the influence of genetic factors in their etiology. In addition, primary tooth impaction may be related to congenitally missing tooth. (Eur J Dent 2008;2:299-302)

Key words: Monozygotic twins; Hypodontia; Oligodontia; Impaction.

INTRODUCTION

Impaction of primary tooth is considered to be rare.¹ The impaction may be primary, meaning that the teeth never have been erupted or it may be secondary, meaning that the teeth after eruption are reimpacted.² Mainly, the local and genetic theories have attempted to clarify the causal agents in the etiology of infraocclusion.

^a Department of Oral Diagnosis and Radiology, Faculty of Dentistry, University of Ondokuz Mayıs, Samsun, Turkey.

^b Department of Restorative Dentistry, Faculty of Dentistry, University of Ondokuz Mayıs, Samsun, Turkey.

■ Corresponding author: A. Zeynep Zengin, Ondokuz Mayıs Üniversitesi, Dishekimliği Fakültesi Oral Diagnoz ve Radyoloji Anabilim Dalı 55139 Kurupelit, Samsun, Turkey. Phone: +90 362 3121919-3012 Fax: +90 362 4576032 E-mail: dtzeynep78@hotmail.com

The presence of familial recurrence of the defect³ and the expression of this anomaly in monozygotic twins⁴ supported the hypothesis of genetic origin. Local contributing factors of impacted primary teeth include: odontomas, ankylosis, congenitally missing permanent teeth, defects in the periodontal membrane, trauma, injuries of the periodontal ligament, precocious eruption of the first permanent molar, defective eruptive force or a combination of these factors.^{5,6} Ankylosis has probably a leading role in the etiopathogenesis of impaction.¹ However, in some cases, etiology of tooth impaction is unknown or may to have inheritance basis.⁵

The expression of developmentally missing teeth may range from the absence of one or a few teeth (hypodontia), to the absence of numerous teeth (oligodontia), or to the failure of all teeth

to develop (anadontia).⁷ Oligodontia can occur as an isolated nonsyndrome condition or as a part of a syndrome like Down syndrome, Ectodermal dysplasia and Rieger syndrome.⁸ These dental anomalies are frequently encountered in different individuals and it is rare to see them together in an otherwise physically normal child. The present case report describes similar tooth agenesis and impacted primary teeth in a monozygotic twin.

CASE REPORT

A 19 year-old male patient was referred to the Oral Diagnosis and Radiology Clinic because of delayed teeth eruption and malocclusion. His medical and family history was noncontributory to the oral findings. There was no reported history of orofacial trauma. It was learned he had a twin brother.

Extraoral clinical examination showed normal development and was noncontributory. On the intraoral clinic examination bilateral primary maxillary canines and the cusp of impacted primary maxillary left second molar were observed. Bilateral permanent maxillary canines, all second premolars, all second and third molars were not evident clinically. The panoramic radiograph confirmed that these teeth were congenitally absent. No evidence of cysts, odontoma, supernumerary teeth or other abnormalities were noted on the radiograph. However, bilateral impacted primary second maxillary and mandibular molars were observed on the panoramic radiograph (Figure 1).

DHH, the monozygotic twin brother of HDH, was invited for intraoral examination. Extraoral clinical examination did not show development anomaly and was noncontributory to the oral findings. Beside of occlusal carious lesions on 26

and 36, primary right first and second maxillary molars were observed infraoccluded on intraoral clinical examination. Primary right maxillary canine was present. Bilateral permanent maxillary canines, all second premolars, right first maxillary premolar and all second and third molars were not evident clinically. The panoramic radiograph confirmed that these teeth were congenitally absent. Also the radiograph showed impacted primary left second maxillary molar and primary left second mandibular molar (Figure 2). His medical and family history was noncontributory, also. There was no reported history of orofacial trauma.

After the clinical and radiographic evaluations, a treatment plan was made, for both cases. The treatment was consisted of routine treatment procedures of caries on permanent teeth and the extraction of the impacted primary teeth because of infraocclusion, root resorption and caries. The twins also enrolled for orthodontic and prosthetic treatment for esthetics, oral health and function.

DISCUSSION

Many studies on the prevalence of hypodontia have been performed in Caucasian populations in North America, Australia and Europe, the prevalence of oligodontia is estimated to be 0,14%.⁹ The lateral incisors and second premolars in both maxilla and mandible were the most commonly absent teeth.¹⁰ Endocrine, local, environmental and hereditary factors play role in their etiology. Studies have identified genes causing absence of teeth in generations of non syndrome patients. The mutations in the genes of PAX9¹¹ are demonstrated to be associated with oligodontia.

The variable expression of hypodontia

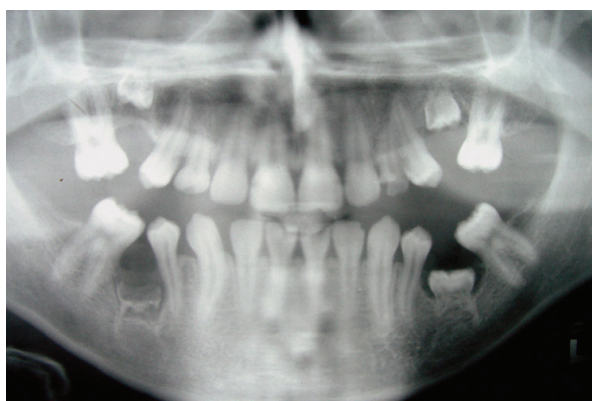

Figure 1. The panoramic radiograph of Twin HDH.

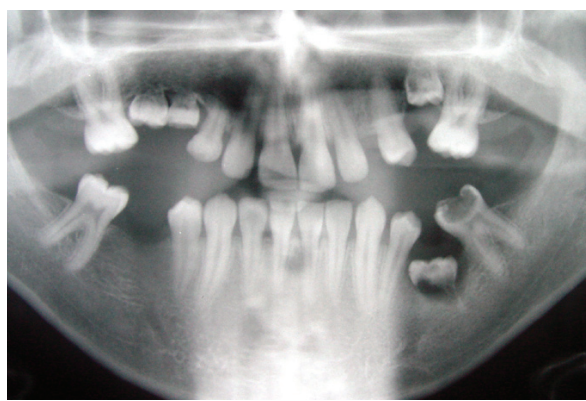


Figure 2. The panoramic radiograph of Twin DHH.

in monozygotic twins has previously been reported^{12,13} and the hereditary nature of hypodontia is revealed in familial and twin studies.¹⁴ Markovic¹⁵ found a high rate of concordance for hypodontia in monozygous twin pairs, while dizygous twin pairs he observed were discordant. Nik-Hussein and Salcedo¹³ described a case of identical twins where double teeth with hypodontia were found. Oikarinen et al⁴ reported a similar dentitions and impacted second and third molars in a monozygotic twin consisting with a hereditary influence. Monozygotic twins (HDH, DHH) reported here had agenesis of ten and eleven teeth (respectively), third molars excluded, consistent with oligodontia. The similarities in the agenesis of permanent teeth have suggested the possibility of a genetic influence. Additionally, environmental factors may also play a role because minor differences in the dentitions of twins were observed.

Other than the tooth agenesis, each of the twins has primary tooth impaction. The incidence of primary tooth impaction is twice as common in the mandible as in the maxilla and the most commonly affected teeth are mandibular second molars.⁶ The siblings of affected children are likely to also be affected in about 18% of cases, and in monozygotic twins there is a high rate of concordance indicating a significant genetic component in the etiology.¹⁶ In the present case each of the twins had four impacted primary teeth and the permanent successors of all these primary teeth were congenitally missing.

The combination of infraocclusion of primary molars and agenesis of the permanent successor is rare¹⁷ and researchers have indicated a relationship of 17%.¹⁸ This combination affects alveolar bone growth and occlusal disturbances such as mesial tipping of the permanent first molar.^{18,19} Antoniades et al⁶ analyzed 28 cases of submerged teeth, in 17 orthodontic patients and in their study congenital absence of the successor tooth was observed in 52% of the total cases. It is apparent from the present twin that impaction of primary teeth was associated with agenesis in their permanent successors.

Diagnostic criteria of impacted primary teeth include the age of the patient, condition and occlusal status of the infraoccluded tooth, root resorption and alveolar bone levels.¹⁹

Kuroi¹⁷ reported that no primary molars in infraocclusion with agenesis of the successor exfoliated spontaneously in contrast to primary molars for which the successor was present. Treatment methods for impacted primary teeth are extraction and observation with or without surgical removal.⁵ Delaying extraction increases the risk of additional alveolar bone loss and overeruption of the opposing teeth.²⁰

Because tooth agenesis causes poor esthetics, functional problems and some oral health problems like food packing,²¹ the management of tooth agenesis involves a multidisciplinary approach. The prosthetic rehabilitation of patient with higher number of absent teeth as oligodontia is likely to become more comprehensive. But the distribution and types of missing teeth are also relevant. When anterior teeth are missing, esthetic features of treatment became more important.⁹ The aims of treatment include improving esthetics, oral health, function and obtaining stable results. In the reported case, twins were enrolled for orthodontic treatment after surgically removed the impacted primary teeth and restorations for caries.

CONCLUSIONS

There is considerable evidence suggesting that genes play a significant role in the etiology of many dental anomalies.¹⁴ In the present study, the occurrence of similarly located tooth agenesis and primary impacted teeth in monozygotic twins suggest the influence of genetic factors in their etiology. Additionally, in the limits of present findings it is possible to.

REFERENCES

1. Bianchi SD, Rocuzzo M. Primary impaction of primary teeth: a review and report of three cases. *J Clin Pediatr Dent* 1991;15:165-168.
2. Rasmussen P, Kotsaki A. Inherited primary failure of eruption in the primary dentition: report of five cases. *ASDC J Dent Child* 1997;64:43-47.
3. Kuroi J. Infraocclusion of primary molars: an epidemiologic and familial study. *Community Dent Oral Epidemiol* 1981;9:94-102.
4. Oikarinen V, Guven O, Silaste H. Similarly impacted second and third maxillary and mandibular molars in a pair of monozygotic twins. *Dentomaxillofac Radiol* 1990;19:133-134.

5. Otsuka Y, Mitomi T, Tomizawa M, Noda T. A review of clinical features in 13 cases of impacted primary teeth. *Int J Paediatr Dent* 2001;11:57-63.
6. Antoniadis K, Kavadia S, Milioti K, Antoniadis V, Markovitsi E. Submerged teeth. *J Clin Pediatr Dent* 2002;26:239-242.
7. Stuart CW, Micheal JP. Oral Radiology Principles and Interpretation 4thed. Philadelphia, Mosby, Inc, 2000, pp. 305.
8. Gorlin RJ: Syndromes of the Head and Neck. New York, Oxford University Press, 2001.
9. Polder BJ, Van't Hof MA, Van der Linden FP, Kuijpers-Jagtman AM. A meta-analysis of the prevalence of dental agenesis of permanent teeth. *Community Dent Oral Epidemiol* 2004;32:217-226.
10. Créton MA, Cune MS, Verhoeven W, Meijer GJ. Patterns of missing teeth in a population of oligodontia patients. *Int J Prosthodont* 2007;20:409-413.
11. Klein ML, Nieminen P, Lammi L, Niebuhr E, Kreiborg S. Novel mutation of the initiation codon of PAX9 causes oligodontia. *J Dent Res* 2005;84:43-47.
12. Kindelan JD, Rysiecki G, Childs WP. Hypodontia: genotype or environment? A case report of monozygotic twins. *Br J Orthod* 1998;25:175-178.
13. Nik-Hussein NN, Salcedo AH. Double teeth with hypodontia in identical twins. *ASDC J Dent Child* 1987;54:179-181.
14. Mossey PA. The heritability of malocclusion: part 2. The influence of genetics in malocclusion. *Br J Orthod* 1999;26:195-203.
15. Markovic MD. Hypodontia in twins. *Swed Dent J Suppl* 1982;15:153-162.
16. Helpin ML, Duncan WK. Ankylosis in monozygotic twins. *ASDC J Dent Child* 1986;53:135-139.
17. Kuroi J, Thilander B. Infraocclusion of primary molars and the effect on occlusal development, a longitudinal study. *Eur J Orthod* 1984;6:277-293.
18. Winter GB, Gelbier MJ, Goodman JR. Severe infraocclusion and failed eruption of deciduous molars associated with eruptive and developmental disturbances in the permanent dentition: a report of 28 selected cases. *Br J Orthod* 1997;24:149-157.
19. Sidhu HK, Ali A. Hypodontia, ankylosis and infraocclusion: report of a case restored with a fibre-reinforced ceromeric bridge. *Br Dent J* 2001;191:613-616.
20. Atwan S, DesRosiers D. Infraocclusion of lower primary molar with other familial dental anomalies: report of case. *ASDC J Dent Child* 1998;65:272-275, 230.
21. Kau CH, Hunter ML, Lewis B, Knox J. Tooth agenesis: a report of missing molars in two generations. *Int J Paediatr Dent* 2003;13:342-347.