Viral Encephalitis: A Hard Nut to Crack

Alka Shukla[1] Mayank Gangwar[1] Sonam Rastogi[1] Gopal Nath[1]

[1]Department of Microbiology, Viral Research and Diagnostic Laboratory, Institute of Medical Sciences, Banaras Hindu University, Varanasi, India

Address for correspondence Gopal Nath, MD, PhD, Department of Microbiology, Viral Research and Diagnostic Laboratory, Institute of Medical Sciences, Banaras Hindu University, Varanasi, India (e-mail: gopalnath@gmail.com).

Ann Natl Acad Med Sci (India) 2019;55:98–109

Abstract

Viral encephalitis is inflammation of brain that manifests as neurological complication of viral infections. There are quite a good number of viruses, for example, human herpes virus, Japanese encephalitis, and enteroviruses that can result in such a dreadful condition. Geographical location, age, gender, immune status, and climatic conditions also contribute to the establishment of this disease in an individual. Clinical signs and symptoms include fever, headache, altered level of consciousness, changed mental status, body ache, seizures, nausea, and vomiting. Effective management of this disease relies on timely diagnosis that in turn depends on apt and suitable investigation techniques. Traditional investigations have thinned out these days owing to the fact that advanced molecular technologies have been introduced to the diagnostic field. Treatment of viral encephalitis mainly involves symptomatic relieve from fever, malaise, myalgia along with measures to reduce viral load in the patient. This review mentions about all the possible aspects of viral encephalitis starting from etiology to the management and preventive measures that include immunization and vector control.

Keywords
- encephalitis
- viral infection
- pathogenesis
- molecular techniques
- management

Introduction

Central nervous system (CNS) is apex authority system of human body and hence it is secured within an exceedingly sophisticated barrier system. This highly complex barrier system sometimes fails to protect CNS and a wide variety of pathologic elements especially viruses manage to reach out CNS.[1] CNS infection is a broad term that might include one or combination of following anatomical sites: meninges (meningitis), brain (encephalitis), and spinal cord (myelitis), or simultaneously in multiple regions (meningoencephalitis, encephalomyelitis).[2]

What Is Encephalitis?

The word "Encephalitis" is an amalgamation of two words, one being a Greek word "enkephalon" that means brain and the other one is a Latin word "itis" that means pertaining to inflammation. Thus, encephalitis stands for inflammation of the brain.[3] To be more precise, it refers to inflammation of brain parenchyma and is usually associated with a spectrum of signs and symptoms including fever, headache, clouding of consciousness, seizures, personality change, focal neurological deficits, and coma.[4-9] Sometimes it can also be associated with brain dysfunction and noteworthy morbidity and mortality.[10] Statistic data suggest that ~5 to 10 per 100 000 residents per year suffer from encephalitis in urban countries; and is one of the alarming threats to the society.[11-13]

A syndrome that is present worldwide and is often associated with encephalitis is "Acute encephalitis syndrome" (AES).[14] It is mainly caused by viral infection and presents with acute-onset of certain symptoms such as fever, altered mental status and/or seizures, disorientation, delirium, or coma in a patient irrespective of his age. AES is a huge burden to public health, as it frequently leads to considerable morbidity and mortality.[5,14-17]

There are over 100 factors that can cause encephalitis.[18] Inflammation of parenchymal tissue may result due to direct infection, or due to a postinfectious process, or due to a noninfectious condition such as anti-N-methyl-d-aspartate receptor (NMDA) encephalitis associated with antibodies against subunits of the NMDA receptor.[9,19,20] For convenience of description, various causes can be grouped under two broad categories: (a) infectious etiological factors that include various microbes and (b) noninfectious etiological factors that

DOI https://doi.org/10.1055/s-0039-1697767
ISSN 0379-038X.

©2019 National Academy of Medical Sciences (India)

License terms

include chemicals and antibodies. ►**Table 1** enumerates various causative agents of encephalitis.[5,7,14,21-23] Since among all, viral infection of CNS is a major cause of encephalitis[1,24-26] this review will revolve mainly around viral encephalitis (VE). This review will shed some light on detailed profile of VE including its etiological agents, epidemiology, pathogenesis, clinical signs and symptoms, current diagnostic aids, management, and its preventive measures.

Viral Encephalitis

Though VE is an unusual complication of viral infection, viral infection is one of the prime causes of encephalitis.[27-30] Literature reports around 100 viruses that are believed to cause encephalitis.[31] Viral infection can strike any part of CNS, but it often causes meningitis and encephalitis. The ambit of vital findings includes fever, headache, altered mental status, sometimes accompanied by seizures and focal neurologic abnormalities.[32]

Table 1 Various causative agents of encephalitis

Infectious etiological factors	Noninfectious etiological factors
Bacterial • *Mycobacterium tuberculosis* • *Mycoplasma pneumoniae* • *Listeria monocytogenes* • *Borrelia burgdorferi* • *Brucella* species • *Leptospira* species • *Legionella* species • *Tropheryma whipplei* (Whipple's disease) • *Nocardia actinomyces* • *Treponema pallidum* • *Salmonella typhi* • Rickettsiae causing Rocky Mountain spotted fever Endemic and epidemic typhus Q fever Ehrlichiosis	Chemical/toxins Immune-mediated disorders • Anti-N-methyl-d-aspartate receptor encephalitis • Antibodies against voltage-gated potassium channel complex
Fungal • *Cryptococcus* • Aspergillosis • Candidiasis	
Parasitic • Human African trypanosomiasis • Cerebral malaria • *Toxoplasma gondii* • Schistosomiasis • *Naegleria fowleri* • *Balamuthia mandrillaris* • *Acanthamoeba* spp. • *Baylisascaris procyonis*	
Viral causes (mentioned in ►**Table 2**)	
Prions causing • Creutzfeldt-Jakob disease	

Etiology and Epidemiology

A wide variety of viruses that are presented in ►**Table 2** have been implicated to cause encephalitis.[6,21,26,33-40] Fortunately with increased vaccination rates and discovery of new vaccines, the rates of encephalitis due to previously common pathogens including measles (Morbillivirus), mumps (Rubulavirus), and poliovirus (Picornavirus) have declined over the past 60 years.[25,41] On the basis of etiology and pathogenesis, in general VE can be divided into four classes based on causes and pathogenesis[42]:

- Acute VE
- Postinfectious encephalomyelitis
- Slow viral infections of CNS
- Chronic degenerative diseases of CNS

Ascertainment of accurate epidemiology of VE is next to impossible because of variation in climatic and geographic conditions across the world. The annual cases of VE have been reported within the range of 7/100000 to 1/ 500000.[26,39,43,44]

Globally, majority of studies have concluded that herpes simplex virus (HSV) is the most prevalent cause of VE.[4,12,25,43,45-56] The pathogenic agents of VE vary from country to country. In Western countries such as France, England, and the United States, human simplex virus-1(HSV-1) has come up as the most prominent cause of sporadic VE.[39] West Nile virus (WNV) is the most common cause of epidemic encephalitis in the United States.[4,12,21,39,45,57-60] The available data also suggests that in Asian countries the primary pathogen of VE is Japanese encephalitis virus (JEV).[61-63] In a year, ~10,000 patients suffer from encephalitis caused due to JE.[64,65]

Table 2 Some important etiological agents of viral encephalitis

- *Human herpes simplex virus* (HSV)*:* HSV-1, HSV-2, Varicella-Zoster virus, cytomegalovirus, Epstein–Barr virus, human herpes virus 6 and 7
- *Adenoviruses:* serotypes 1, 6, 7, 12, 32
- *Influenza A*
- *Parvovirus (B19)*
- *Astroviruses*
- *Enteroviruses*: EV 9,70 and 71, echo- and coxsackieviruses, poliovirus
- *Measles, mumps, and rubella viruses*
- *Rhabdoviruses*: Australian bat *lyssaviruses*, rabies
- *Flaviviruses:* Japanese B encephalitis, West Nile encephalitis virus, dengue virus, Powassan virus, and Zika viruses
- *Tick-borne encephalitis viruses*
- *Bunyaviruses*: Toscana virus, La Crosse strain of California virus
- *Reoviruses*: Colorado tick fever virus
- *Retroviruses*: Human immunodeficiency virus
- *Alphaviruses*: Chikungunya virus, Venezuelan equine, eastern equine, western equine.
- *Henipavirus*: Nipah virus, Hendra virus
- *Bornavirus*: Variegated squirrel bornavirus 1 virus

To contradict above statement, a study done among Chinese children suffering from VE has reported that JEV was least involved in causing this disease.[40] Following herpes group of viruses, Varicella zoster virus (VZV) is the second most common cause of VE.[4,24,43,45,46,49,52-54,66,67] Literature has documented that around 1.8 cases per 10 000 cases of varicella zoster infection have led to VE.[68]

Apart from aforementioned viruses, human enteroviruses are also one of the prominent causes of VE in world.[46,55,62,63,69-71] Enteroviruses have many serotypes among which, enterovirus 17 has gained more attention because of its vital role in causing VE.[72] In India, JE has claimed more number of VE cases to its credit and is followed by herpes viruses, enterovirus, measles virus, mumps virus, dengue, Chandipura virus, and Rubella virus.[73-76]

The spectrum of severity of this disease is influenced by various following factors:

Age and gender variation: The highest incidence of VE is seen among younger age group patients and elderly people.[4,39,49,77,78] Studies have reported that number of male patients diagnosed with VE is more when compared with female patients. Verma et al reported that JE had more inclination toward male who belonged to younger or older age groups.[79]

Role of immune status: Patients who have compromised immune system are at greater risk of acquiring disseminated disease with the incidence upto 36%.[65] Immunocompromised patients are exclusive victims of cytomegalovirus infection, though VZV infection has also been reported.[39,80]

Seasonal distribution of VE and meningitis: Certain viruses have specific favorable set of atmospheric conditions for its growth and proliferation. Therefore, it blooms out in certain sessions and causes more damage. Human enteroviruses infection is believed to be more pervasive in summer and autumn, thus resulting frequent number of cases of VE during this session of the year.[40]

Pathogenesis

The first step toward VE begins with breach in CNS protective barriers. There are essentially two routes mentioned below through which viruses can gain access to the CNS and cause infection.[2,5,81]

1. Through blood supply:
   a. By directly damaging endothelial cells and creating passage through the junctions.[25]
   b. Or through anatomic structures that are less secured and have low strength defense such as the choroid plexus and circumventricular organs.[82,83]
   c. Or with the assistance of infected hematopoietic cells ("Trojan horses").[84,85]
2. By infecting peripheral sensory or motor nerves.

Following viral invasion in CNS, monocytes sneak into the infected CNS area and get transformed into required cell forms, for example, dendritic cell, macrophage, and microglial cells. Presence of Ly6C^{hi} monocyte in inflamed area of CNS is considered as pathognomonic finding of VE. These transformed cells aim at limitation and depopulation of viral components by assisting in antigen presentation and T cell stimulation. It also helps in producing numerous proinflammatory mediators and reactive oxygen species.[86] Pathogenic component that has reached CNS damages the nerve cells that results in disease and thus emergence of clinical symptoms. Apoptosis of nerve cells is causative factor of HSV-induced encephalitis.[25] ►**Fig. 1** illustrates pathogenesis of VE in brief.[87-90]

Clinical Signs and Symptoms of Viral Encephalitis

Emergence of clinical signs and symptoms mainly hinges upon type of viral infection, immune status, and age of the individual. As mentioned before, younger and elder people manifest more severe form of encephalitis compared with others.[21] Cardinal signs and symptoms are fever, headache, altered level of consciousness, changed mental status, nausea, and vomiting. When cortex is involved, seizures are one of the prominent findings.[39,91,92]

Findings associated with this disease can be grouped into following categories[21,93]:

1. Cognitive dysfunction: acute memory loss, speech, and orientation disturbance.
2. Behavioral changes: disorientation, hallucinations, psychosis, personality changes, and agitation.
3. Focal neurological abnormalities: ataxia, anomia, dysphasia, and hemiparesis.
4. Pyramidal signs: brisk tendon reflexes and extensor plantar responses.
5. Cranial nerve abnormalities: oculomotor and facial nerves are mainly involved.
6. Involuntary movements: myoclonus and tremors.
7. Seizures (may or may not be associated with the disease).

Diagnosis

Correct diagnosis guides into successful management of any disease. It starts with the observation of patient right from the moment when he walks into the clinic or hospital. Obtaining complete and precise patient's history is a key step toward unveiling hidden disease. In case of neuronal disorders, as patient is in a state of disturbed mental status, it is always better to approach patient's relative to seek his history. Following things should be asked for:

- Geographic and seasonal factors: certain viral diseases are more prevalent in certain season and in certain geographical area. For example, JE is endemic in Asian countries and spreads mainly in summer season.[21,94,95]
- Foreign travel or migration history. Any recent visit to area that is affected with VE should be considered into the account.
- Contact with animals (e.g., farm house) or insect bites.
- Immune status. Immunosuppressed individuals are more susceptible to certain specific encephalitis; for example, cytomegalovirus-induced encephalitis.[21]
- Occupation. People who work in farm, especially paddy fields, are more prone to JEV.

After proper case history, general examination has to be performed that must be followed by relevant investigations.

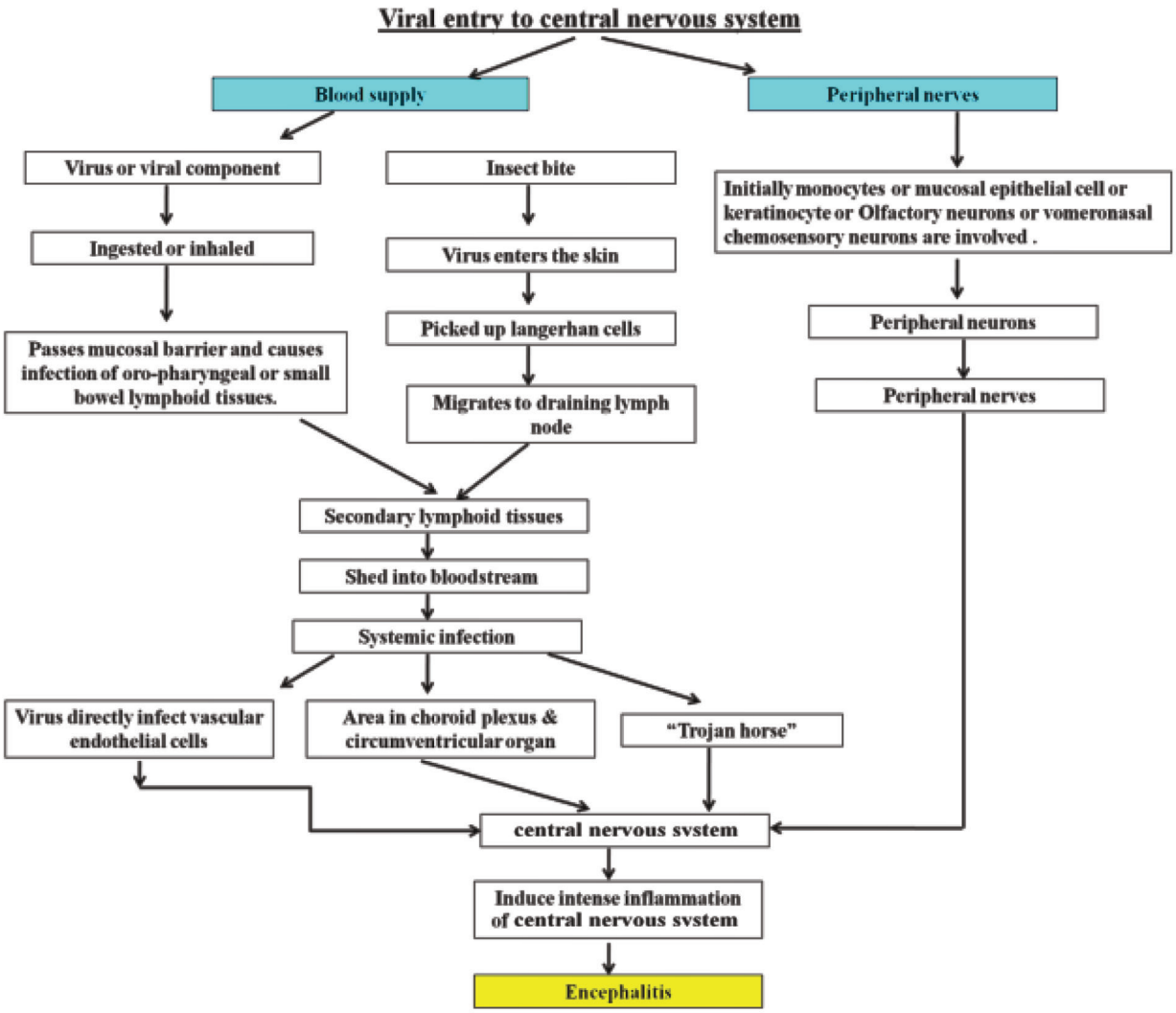

Fig. 1 Nutshell of pathogenesis of viral encephalitis.

General Examination

Most of the patients who are suffering from VE are bound to show up with mucosal or cutaneous lesions owing to viral infections. For example, herpes virus and varicella zoster infections often lead to skin rashes.[21] Therefore, thorough examination of patient's body is an important part of diagnosis.

Investigations

Once clinician suspects VE, various investigations are recommended to confirm the provisional diagnosis. Previously certain techniques such as viral cultures and immunological assays were commonly looked upon for carrying out investigations on suspected cases. But recently polymerase chain reaction (PCR) has dramatically restructured viral diagnostics by enhancing recognition sensitivity and specificity.[96] ►**Table 3** presents certain criteria proposed by International Encephalitis Consortium to define encephalitis case.[7,9,97,98]

Blood and Serological Tests

In VE, there is marked lymphocytosis that is evident on complete blood picture evaluation.[70] Serological investigations such as enzyme-linked immunosorbent assay (ELISA) to detect antibodies and antigenic components can also help in taking diagnosis to further level. But available literature indicates that for ELISA, cerebrospinal fluid (CSF) sample should be preferred over serum samples as specific activity (antigen binding per mole) of immunoglobulin M in CSF is believed to be greater than that of the serum. Thus, for diagnosis of VE by ELISA, CSF offers both superior sensitivity and specificity over that of serum.[79]

Direct Detection of Virus in CSF

Direct detection of virus by employing electron microscope has been mentioned in previous studies. Results obtained through electron microscopy were not much promising, hence resulted in its limited use in investigations.[99]

Table 3 Criteria to define encephalitis

Major criterion (required)	Minor criteria (2 required for possible encephalitis; ≥3 required for probable or confirmed encephalitis)
• Change in mental status of patient which lasts for more than 24 hours, for example, alteration in consciousness level or in personality	• Documented fever ≥38°C (100.4°F) within the 72 hour before or after presentation • Generalized or partial seizures not fully attributable to a pre-existing seizure disorder • New onset of focal neurologic findings • CSF WBC count ≥5/cubic mm • Abnormality of brain parenchyma on neuroimaging suggestive of encephalitis that is either new from prior studies or appears acute in onset • Abnormality on electroencephalography that is consistent with encephalitis and not attributable to another cause

Abbreviations: CSF, cerebrospinal fluid; WBC, white blood cell.

Electroencephalography and Neuroimaging

Electroencephalography helps to mark epileptic seizures and it is helpful in differentiating encephalitis from generalized encephalopathy.[100] In case of herpes simplex encephalitis (HSE), periodic lateralized epileptiform discharges is a specific finding.

Neuroimaging also helps in detecting neuronal diseases as brain imaging is one of the important investigations. Magnetic resonance is preferred in case of acute encephalitis. Certain specific neuroimaging findings may assist to provide clue toward the etiology; for example, HSE causes frontotemporal changes along with small hemorrhagic lesions in the limbic system,[101] JE often presents with thalamic hemorrhage, and Eastern equine encephalitis results in disseminated lesions in the brainstem and basal ganglia.[21] Blood flow evaluation with the help of technetium-labeled hexamethylpropyleneamine oxime and single photon emission computed tomography provides critical information and hint of HSE.[102,103]

Cerebrospinal Fluid Analysis

CSF is checked for cell constituents including its morphology, protein, and glucose levels. CSF profiles of these elements often indicate basic character and severity of CNS infection. Out of 100 viral encephalitis patients, 90 exhibit abnormal CSF findings that consist of marked lymphocytic pleocytosis (>5 lymphocytes/mm^3), slight elevation in protein content (little above than 40 mg/dL),[7] whereas glucose level remains unchanged.[32,103,104] In enteroviral encephalitis and HSE, presence of neutrophils dominates the picture.[105,106] Unlike bacterial encephalitis, opening pressure of CSF remains normal in VE. Sometimes HSE exhibits increased level of erythrocytes in CSF (>500/mm^3) suggestive of intracerebral hemorrhage.[7] Sometimes abnormal lymphocytes have been encountered in CSF of Epstein–Barr virus (EBV) or cytomegalovirus-induced encephalitis.[107] In later stages of HSE, glucose level of CSF usually decreases.[108] A few recent researches have revealed that there is alteration in inflammatory cytokine levels in CSF. Interferon-γ and interleukin-6 (IL-6) levels are higher in initial stage of the disease but as the diseases progresses, tumor necrosis factor-α, IL-2, and soluble CD8 levels get elevated.[109]

Aforementioned data concludes that these CSF findings are not completely reliable for definite diagnosis, and thus various serological assays and genome analyses come into the picture.

Cerebrospinal Fluid Assays

It has been reported that in CNS infections intrathecal antiviral antibodies are been produced by choroid plexus. CSF assay proves its importance in diagnosing diseases where direct viral detection is not easy. This process involves demonstration of any of the following three antibodies, IgG, IgA, or IgM antibody, and it is considered as evidence of CNS infection even in the cases where blood–brain barrier is intact.[110] Government of India has set certain criteria to diagnose acute encephalitis, out of which, if IgM antibodies have been detected against a virus or its component in CSF, it is considered as causative factor of the disease.[111] The existence of a large number of constantly evolving viral serotypes can render antibody-based detection nearly impossible. Also, to present with detectable number of antibodies, CSF requires a period of minimum 1 week, which makes it less useful in early detection of disease.[108]

Brain Biopsy

It used to be a "gold standard" in diagnosis infectious encephalitis. It was advised frequently for detection of acute encephalitis in olden days with its sensitivity being 95% and specificity being above 99%. Histological findings reveal presence of inflammatory cells entrapping blood vessels, neuronal loss, and gliosis.[112] In case of HSE, temporal lobe region displays necrotic area. At microscopic level, certain viral inclusion bodies pertaining to specific viral infections can be observed, for example, intracytoplasmic eosinophilic Negri bodies in rabies, intranuclear Cowdry type A inclusions in herpes, and intranuclear inclusions in subacute sclerosing panencephalitis caused due to measles[112-115].

One of the main concerns associated with this investigation is invasive surgical approach that can lead to permanent neuronal damage.[4,45,69,97,116-118] After newer antiviral drugs came into the picture (e.g., Acyclovir), the trend of brain biopsy started to decline. In present scenario, it is contemplated when surgical decompression is a part of treatment for elevated intracranial pressure.[21] Brain biopsy may sometimes be necessary to confirm the diagnosis in cases where symptoms are worsening and treatment is not working.

Molecular Techniques

Before introduction of nucleic acid amplification technique, virus isolation through cell culture was considered as "gold standard" for isolation of viral component.[119,120] ►**Table 4** presents a list of trending molecular assay methods being employed to detect viral components.

Ligase Chain Reaction

It amplifies the nucleic acid instead of nucleotides. Ligase chain reaction (LCR) uses two enzymes: a deoxyribonucleic acid (DNA) polymerase (used for initial template amplification and then inactivated) and a thermostable DNA ligase. The concept of LCR relies on ligation of adjacent two synthetic oligonucleotide primers, which distinctively hybridize to one strand of the target DNA. This allows the differentiation of DNA sequences that are dissimilar even in a single base pair and thus this method is more specific than PCR.[121]

Polymerase Chain Reaction

PCR helps in detection of specific nucleic acid present in CSF by amplifying the target nucleotides. It is truly helpful in cases of HSV, VZV, cytomegalovirus, and EBV-induced encephalitis. If it is performed by experts, it delivers 100% specificity and >90% sensitivity.[108] CSF PCR withholds its sensitivity even after short courses of antiviral therapy.

Merits of PCR over other investigations are:

- Its high sensitivity.
- It can be accomplished in short duration of time (within 6–8 hours).
- It needs small quantity of sample (100–300 µL).[7]
- It is exclusively specific for particular set of genomes.

There are certain limitations of conventional PCR; for example, the maximum number of viruses detectable in a single assay is relatively small. To distinguish various viral subtypes or genera, supplementary steps, for example, restriction enzyme analysis, sequencing, or hybridization blotting of the PCR product, are needed. Although PCR gives promising results, its availability in every diagnostic laboratory is not obvious. Thus, initial serological assays screening is recommended before sending the samples to higher laboratories.[56,122]

Table 4 Nucleic acid amplification methods

Target-amplification techniques
• Polymerase chain reaction • Ligase-chain reaction • Isothermal transcription-based amplification methods: Transcription-mediated amplification Nucleic acid-based sequence amplification • Strand displacement amplification • Loop-mediated isothermal amplification
Signal-based amplification methods
• Branched deoxyribonucleic acid method • Hybrid capture assay

Reverse Transcription PCR

When ribonucleic acid (RNA) viruses have to be traced out, reverse transcription PCR comes into picture. It is similar to conventional PCR except for the first step where complimentary DNA (cDNA) is formulated out of RNA. It can be performed using two-step method or single-step method. In two-step procedure, reverse transcription of RNA occurs in the presence of reverse transcriptase enzyme that is followed by amplification of cDNA in the presence of different DNA polymerase enzyme. On the other hand, in single-step procedure, single thermostable enzyme that possesses both reverse transcriptase and DNA polymerase activity is used.[7]

Real-Time PCR

In real-time PCR, a fluorescent signal is released during each round of PCR amplification. It has produced good results in detecting WNV, Saint Louis encephalitis virus, and dengue virus) nucleic acid from different types of samples.[123,124] A comparative study to evaluate three diagnostic tests to detect JEV has been done. The study concluded that real-time PCR is more, sensitive, and specific method when compared with IgM antibody capture ELISA (MAC ELISA) and virus cultivation technique.[79] Ledermann et al in 2011 had conducted a study on horses and showed that real-time PCR can detect viral nucleic acid in samples that had very low viral load. Thus, it can help in detecting viral components in early stages of infection when viral load is less.[125] Real-time PCR has following merits over regular PCR technique[126]:

- Risk of contamination is reduced.
- Quantification of target is easy.
- Sensitivity is high.
- Reproducibility is high.
- Multiplexing can be considered.

Multiplex PCR

Main objective of multiplex PCR is to detect more than one target simultaneously. It is helpful in diagnosing diseases that have multiple etiologies.[127] Thus, it can assist in detection of etiology in case of VE. The challenge that is posed in this technique is the difficulty in designing compatible multiplex primer sets.

Other Nucleic Acid Amplification Methods

Transcription-Based Amplification Methods

There are two wildly known methods that follow this approach[128]:

I. Nucleic acid sequence-based amplification (NASBA) and
II. Transcription-mediated amplification.

Unlike conventional PCR, these procedures do not require wide range of temperature as these are isothermal reactions. When compared with conventional PCR, amount of amplified nucleic acid copies generated is more in these procedures. NASBA amplifies RNA thus it eliminates one step of cDNA synthesis that is needed in conventional PCR.[7]

Loop-Mediated Isothermal Amplification
It is also an isothermal reaction. It utilizes an enzyme with strand displacement property along with four primers out of which two are inner and two are outer primers. These primers recognize six different sites in the target nucleic acid and thus make it more specific reaction/assay.[7,129,130]

New Emerging Techniques
To overcome the constraints of available techniques, newer procedures such as microarray and multianalyte flow cytometry are being proposed.

Microarray
It is a genomic approach to assist viral detection. DNA microarray is capable of detecting around 100 viruses simultaneously.[96] A DNA microarray (also commonly known as DNA chip or biochip) is a collection of microscopic DNA spots attached to a solid surface. Generally nucleic acid (DNA, cDNA, or an oligonucleotide) microarrays are mottled onto a solid matrix at low density. The solid matrix is usually a glass slide.[131] A DNA microarray has been employed in investigations of VE with sensitivity being 93% and specificity being 100%.[132]

Multianalyte Flow Cytometry
This technique can systematically differentiate between equally sized particles on the basis of their internal properties. Therefore, it can be employed in designing immunoassays, Western blot-like antibody assays, and nucleic acid hybridization assays.[133] It is one of the new emerging approaches to detect multiple targets such as antibody, antigen, or nucleic acid.[7] There is not much data available on role of this technique in diagnosis of VE and thus further research in this area is recommended.

Specimens Other than CSF and Blood in the Investigation of Encephalitis
Specimens such as blood CSF have been routinely used in carrying out investigations of VE. Literature suggests that enteroviral infections have a replicative stage that occurs in throat and gastrointestinal tract. Thus, during this phase viruses can be obtained from specimens collected from these locations. Availability of viral component can be observed up to 4 to 8 weeks from throat samples and up to 11 weeks from stool samples. This extended duration of availability of viruses provides more time to conduct investigations.[7,134] In cases of viral infections that cause vesicle eruptions, the aspirate of vesicle can be used to carry out PCR.[100]

Management

Patients suffering from VE generally need intensive care.[135] Over the period of time, with advent of newer diagnostic techniques, drugs and clinical setups, management of VE has took a major leap.[100,136]

Essentially, while dealing with VE, following three parameters are to be addressed.

1. The need of antiviral or immune modifier drugs to arrest the infection.
2. To keep a check on symptoms and sufferings of patients; for example, to manage seizures, phenytoin and low dosage of benzodiazepines can be used.[100]
3. To prevent any late deleterious outcome of the disease; for example, certain drugs can result in nephrotoxicity and raise serum liver enzymes.[21]

The detailed available drugs have been mentioned in the ►**Table 5**, which are frequently used in VE therapy.[65,135-138]

Acyclovir is advised to combat HSE and VZE. It hinders viral DNA synthesis and thus halts virus replication.[21,65,139] This drug is more effective when administered in early stages of disease.[31,42,140] Lately, one more therapeutic strategy that has shown favorable results has emerged out. It implicates induction of histocompatible, virus-specific T cells into immunocompromised person suffering from infections such as cytomegalovirus and EBV.[141,142]

Table 5 Drugs used in treating viral encephalitis

Drugs	Dosage[a] and recommendations
Acyclovir	For adult, intravenous: 10 mg/kg every 8 hour For neonatal herpes simplex encephalitis is 60 mg/kg/d
Valacyclovir	1000 mg every 8 hour
Ganciclovir	Intravenous: 5 mg/kg every 12 hour. Recommended against cytomegalovirus infection
Valganciclovir	900 mg twice daily (induction) 900 mg once daily (maintenance/prophylaxis)
Foscarnet	Intravenous: 90 mg/kg every 12 hour or 60 mg/kg every 8 hour (induction). Recommended against cytomegalovirus infection
Cidofovir	Intravenous: 5 mg/kg weekly for 2 weeks (induction), then once every 2 week (maintenance)
Immunoglobulin	Intravenous: 400–500 mg/kg daily or every other day
Interferon-α	Assists in restriction of viral replication and is recommended against arbovirus infections. For example, West Nile virus or St. Louis encephalitis virus
Corticosteroids	To control raised intracranial pressure. It is also recommended when disease is accompanied by vasculitis. Prednisone equivalent dose of 1 mg/kg daily should be considered

[a]Dosage must be adjusted according to renal function.

Prognosis

There has been a marked improvement in prognosis of this disease in the past decades. Acyclovir intravenous therapy has decreased the mortality risk from 70 to 20%.[136,143,144] But still the satisfactory level of results has not been obtained. Approximately, up to 10% of the cases suffer from reactivation of the disease after completion of antiviral therapy.[100] A large section of patients, who manages to recover from VE, often complains of symptoms suggestive of permanent neurologic damage.[145-148] Prognosis of this infection also relies on age and immune status of the patient, etiology, and severity of the disease. Recovery from severe HSE often leaves the patient with symptoms such as seizures and anomia.[7] Patients of younger and older age groups are at greater risk to sustain permanent neuronal damage.

Vaccines and Other Preventive Measures

Prevention is always better than cure; thus, infections against which vaccines are available should be prevented by providing proper immunization to the suspected population. There has been an observable fall in number of new cases of JE after the development of JE vaccine.[149] Along with JE, vaccinations targeting polio, rabies, influenza, VZ, tick-borne encephalitis virus, mumps, measles, and rubella have also been introduced and have resulted in decline in incidences of related encephalitis cases.[135,150] Preventive vaccines against certain viruses such as WNV, dengue virus, and Zika virus are under investigations.[135] Along with immunization, measures to control vector population (e.g., mosquitoes) must be promoted.

Conclusion

Among all CNS infections, VE has always managed to keep itself in limelight. Recent past decades have certainly witnessed a marked improvement in diagnosis of VE but still a considerable number of patients go undiagnosed of exact etiology. VE is still one of the major threats to global health. Interestingly, molecular techniques have contributed in unveiling many hidden aspects of VE; hence, the upcoming techniques such as multianalyte flow cytometry and microarrays must be further researched to make them useful in diagnostic investigations. For a better management, it is recommended that upcoming investigations must have more inclination toward prevention of disease rather than treatment aspect.

Funding

The authors gratefully acknowledge the support provided by Department of Health Research under the Ministry of Health & Family Welfare (Government of India), New Delhi, India, and Indian Council of Medical Research (ICMR) in the form of establishment of state level Viral Research and Diagnostic Laboratory network under scheme 5066.

Conflict of Interest

None declared.

References

1 Romero JR, Newland JG. Viral meningitis and encephalitis: traditional and emerging viral agents. Semin Pediatr Infect Dis 2003;14(2):72–82
2 Swanson PA, II. McGavern DB. Viral diseases of the central nervous system. Curr Opin Virol 2015;11:44–54
3 Solomon T, Hart IJ, Beeching J. Viral encephalitis: a clinician's guide. Practical Neurology 2007;7:288-305
4 Granerod J, Ambrose HE, Davies NW, et al. UK Health Protection Agency (HPA) Aetiology of Encephalitis Study Group. Causes of encephalitis and differences in their clinical presentations in England: a multicentre, population-based prospective study. Lancet Infect Dis 2010;10(12):835–844
5 Kennedy PG. Viral encephalitis: causes, differential diagnosis, and management. J Neurol Neurosurg Psychiatry 2004;75(Suppl 1):i10–i15
6 Kennedy PGE, Quan PL, Lipkin WI. Viral encephalitis of unknown cause: current perspective and recent advances. Viruses 2017;9(6):138
7 Mutton K, Guiver M. Laboratory techniques for human viral encephalitis diagnosis. Infect Disord Drug Targets 2011;11(3):206–234
8 Bennett JE, Dolin R, Blaser MJ. Mandell, Douglas, and Bennett's Principles and Practice of Infectious Diseases. Philadelphia, PA: Churchill Livingstone/Elsevier; 2010
9 Vigevano F, De Liso P. Differential Diagnosis. In: Yamanouchi H, Moshé S, Okumura A. eds. Acute encephalopathy and encephalitis in infancy and its related disorders. Elsevier Inc.;2018
10 Flamand L. Human Herpes viruses HHV-6A, HHV-6B & HHV-7. Burlington: Elsevier Science;2014
11 Jmor F, Emsley HC, Fischer M, Solomon T, Lewthwaite P. The incidence of acute encephalitis syndrome in Western industrialised and tropical countries. Virol J 2008;5:134–146
12 Vora NM, Holman RC, Mehal JM, Steiner CA, Blanton J, Sejvar J. Burden of encephalitis-associated hospitalizations in the United States, 1998-2010. Neurology 2014;82(5):443–451
13 Graus F, Titulaer MJ, Balu R, et al. A clinical approach to diagnosis of autoimmune encephalitis. Lancet Neurol 2016;15(4):391–404
14 Jain P, Jain A, Kumar A, et al. Epidemiology and etiology of acute encephalitis syndrome in North India. Jpn. J Infect Dis 2014;67(3):197–203
15 Beig FK, Malik A, Rizvi M, Acharya D, Khare S. Etiology and clinico-epidemiological profile of acute viral encephalitis in children of western Uttar Pradesh, India. Int. J Infect Dis 2010;14(2):e141
16 Ghosh S, Basu A. Acute encephalitis syndrome in India: the changing scenario. Ann Neurosci 2016;23(3):131–133
17 Joshi R, Kalantri SP, Reingold A, Colford JM, Jr. Changing landscape of acute encephalitis syndrome in India: a systematic review. Natl Med J India 2012;25(4):212–220
18 Parpia AS, Li Y, Chen C, Dhar B, Crowcroft NS. Encephalitis, Ontario, Canada, 2002-2013. Emerg Infect Dis 2016;22(3):426–432
19 Barry H, Byrne S, Barrett E, Murphy KC, Cotter DR. Anti-N-methyl-d-aspartate receptor encephalitis: review of clinical presentation, diagnosis and treatment. BJPsych Bull 2015;39(1):19–23
20 Florance NR, Davis RL, Lam C, et al. Anti-N-methyl-D-aspartate receptor (NMDAR) encephalitis in children and adolescents. Ann Neurol 2009;66(1):11–18
21 Chaudhuri A, Kennedy PGE. Diagnosis and treatment of viral encephalitis. Postgrad Med J 2002;78(924):575–583
22 Lancaster E. The diagnosis and treatment of autoimmune encephalitis. J Clin Neurol 2016;12(1):1–13
23 Stone MJ, Hawkins CP. A medical overview of encephalitis. Neuropsychol Rehabil 2007;17(4-5):429–449

24 Barbadoro P, Marigliano A, Ricciardi A, D'Errico MM, Prospero E. Trend of hospital utilization for encephalitis. Epidemiol Infect 2012;140(4):753–764
25 Shives KD, Tyler KL, Beckham JD. Molecular mechanisms of neuroinflammation and injury during acute viral encephalitis. J Neuroimmunol 2017;308:102–111
26 Boucher A, Herrmann JL, Morand P, et al. Epidemiology of infectious encephalitis causes in 2016. Med Mal Infect 2017;47(3):221–235
27 Kumar S, Pandey AK, Gutch M, et al. Acute viral encephalitis clinical features and outcome: experience from a tertiary center of North India. Ann Trop Med Public Health 2015;8:262–266
28 Johnson RT, Mims GA. Pathogenesis for viral infections of the nervous system. N Engl J Med 1968;278(2):84–92
29 Mims CA, Pathogenesis of Infectious Disease. London: Academic Press; 1977
30 Grifffin DE, Viral infections of central nervous system. In: Galasso JE, Whitley RJ, Marigan TC, eds. Antiviral Agents and Viral Disease of Man. 3rd edition. New York: Raven Press; 1990 461–495
31 Whitley RJ, Gnann JW. Viral encephalitis: familiar infections and emerging pathogens. Lancet 2002;359(9305):507–513
32 Debiasi RL, Tyler KL. Molecular methods for diagnosis of viral encephalitis. Clin Microbiol Rev 2004;17(4):903–925
33 Kennedy PG. Viral encephalitis. J Neurol 2005;252(3):268–272
34 Raine CS, Fields BN. Reovirus type 3 encephalitis–a virologic and ultrastructural study. J Neuropathol. Exp Neurol 1973;32(1):19–33
35 Chua KB, Goh KJ, Wong KT, et al. Fatal encephalitis due to Nipah virus among pig-farmers in Malaysia. Lancet 1999;354(9186):1257–1259
36 de Jong MD, Bach VC, Phan TQ, et al. Fatal avian influenza A (H5N1) in a child presenting with diarrhea followed by coma. N Engl J Med 2005;352(7):686–691
37 Warrell MJ, Warrell DA. Rabies and other lyssavirus diseases. Lancet 2004;363(9413):959–969
38 Quan PL, Wagner TA, Briese T, et al. Astrovirus encephalitis in boy with X-linked agammaglobulinemia. Emerg Infect Dis 2010;16(6):918–925
39 Solomon T, Michael BD, Smith PE, et al. National Encephalitis Guidelines Development and Stakeholder Groups. Management of suspected viral encephalitis in adults-Association of British Neurologists and British Infection Association National Guidelines. J Infect 2012;64(4):347–373
40 Ai J, Xie Z, Liu G, et al. Etiology and prognosis of acute viral encephalitis and meningitis in Chinese children: a multicentre prospective study. BMC Infect Dis 2017;17(1):494
41 Go YY, Balasuriya UBR, Lee C-K. Zoonotic encephalitides caused by arboviruses: transmission and epidemiology of alphaviruses and flaviviruses. Clin Exp Vaccine Res 2014;3(1):58–77
42 Whitley RJ. Viral encephalitis. N Engl J Med 1990; 323(4):242–250
43 Huppatz C, Durrheim DN, Levi C, et al. Etiology of encephalitis in Australia, 1990-2007. Emerg Infect Dis 2009;15(9):1359–1365
44 Granerod J, Tam CC, Crowcroft NS, Davies NW, Borchert M, Thomas SL. Challenge of the unknown. A systematic review of acute encephalitis in non-outbreak situations. Neurology 2010;75(10):924–932
45 Mailles A, Stahl J-P; Steering Committee and Investigators Group. Infectious encephalitis in France in 2007: a national prospective study. Clin Infect Dis 2009;49(12):1838–1847
46 de Ory F, Avellón A, Echevarría JE, et al. Viral infections of the central nervous system in Spain: a prospective study. J Med Virol 2013;85(3):554–562
47 Lee T-C, Tsai C-P, Yuan C-L, et al. Encephalitis in Taiwan: a prospective hospital-based study. Jpn J Infect Dis 2003;56(5-6):193–199
48 Khetsuriani N, Holman RC, Anderson LJ. Burden of encephalitis-associated hospitalizations in the United States, 1988-1997. Clin Infect Dis 2002;35(2):175–182
49 Davison KL, Crowcroft NS, Ramsay ME, Brown DW, Andrews NJ. Viral encephalitis in England, 1989-1998: what did we miss? Emerg Infect Dis 2003;9(2):234–240
50 Trevejo RT. Acute encephalitis hospitalizations, California, 1990-1999: unrecognized arboviral encephalitis? Emerg Infect Dis 2004;10(8):1442–1449
51 Mehal JM, Holman RC, Vora NM, Blanton J, Gordon PH, Cheek JE. Encephalitis-associated hospitalizations among American Indians and Alaska Natives. Am J Trop Med Hyg 2014;90(4):755–759
52 Kelly TA, O'Lorcain P, Moran J, et al. Underreporting of viral encephalitis and viral meningitis, Ireland, 2005-2008. Emerg Infect Dis 2013;19(9):1428–1436
53 Quist-Paulsen E, Kran AM, Dunlop O. Wilson J, Ormaasen V. Infectious encephalitis: a description of a Norwegian cohort. Scand. J Infect Dis 2013;45(3):179–185
54 Rantalaiho T, Färkkilä M, Vaheri A, Koskiniemi M. Acute encephalitis from 1967 to 1991. J Neurol Sci 2001;184(2):169–177
55 Frantzidou F, Kamaria F, Dumaidi K. Skoura L, Antoniadis A, Papa A. Aseptic meningitis and encephalitis because of herpesviruses and enteroviruses in an immunocompetent adult population. Eur. J Neurol 2008;15(9):995–997
56 Mawuntu AHP, Bernadus JBB, Dhenni R, et al. Detection of central nervous system viral infections in adults in Manado, North Sulawesi, Indonesia. PLoS One 2018;13(11):e0207440
57 Stahl JP, Mailles A, Dacheux L, Morand P. Epidemiology of viral encephalitis in 2011. Med Mal Infect 2011;41(9):453–464
58 George BP, Schneider EB, Venkatesan A. Encephalitis hospitalization rates and inpatient mortality in the United States, 2000-2010. PLoS One 2014;9(9):e104169
59 Whitley RJ. Herpes simplex encephalitis: adolescents and adults. Antiviral Res 2006;71(2-3):141–148
60 Singh TD, Fugate JE, Rabinstein AA. The spectrum of acute encephalitis: causes, management, and predictors of outcome. Neurology 2015;84(4):359–366
61 Le VT, Phan TQ, Do QH, et al. Viral etiology of encephalitis in children in southern Vietnam: results of a one-year prospective descriptive study. PLoS Negl Trop Dis 2010;4(10):e854
62 Joshi R, Mishra PK, Joshi D, et al. Clinical presentation, etiology, and survival in adult acute encephalitis syndrome in rural Central India. Clin Neurol Neurosurg 2013;115(9):1753–1761
63 Olsen SJ, Campbell AP, Supawat K, et al. Thailand Encephalitis Surveillance Team. Infectious causes of encephalitis and meningoencephalitis in Thailand, 2003-2005. Emerg Infect Dis 2015;21(2):280–289
64 Centers for Disease Control and Prevention Japanese Encephalitis Virus. 2015
65 Bookstaver PB, Mohorn PL, Shah A, et al. Management of viral central nervous system infections: a primer for clinicians. J Cent Nerv Syst Dis 2017;9:1179573517703342
66 Kaewpoowat Q, Salazar L, Aguilera E, Wootton SH, Hasbun R. Herpes simplex and varicella zoster CNS infections: clinical presentations, treatments and outcomes. Infection 2016;44(3):337–345
67 Mailles A, Vaillant V, Stahl J-P. [Infectious encephalitis in France from 2000 to 2002: the hospital database is a valuable but limited source of information for epidemiological studies]. Med Mal Infect 2007;37(2):95–102
68 Centers for Disease Control and Prevention, Varicella. In: Hamborsky J, Kroger A, Wolfe S, eds. Epidemiology and Prevention of Vaccine-Preventable Diseases, 13th edition. Washington, DC: Public Health Foundation; 2015
69 Glaser CA, Honarmand S, Anderson LJ, et al. Beyond viruses: clinical profiles and etiologies associated with encephalitis. Clin Infect Dis 2006;43(12):1565–1577

70 Koskiniemi M, Rantalaiho T, Piiparinen H, et al. Study Group. Infections of the central nervous system of suspected viral origin: a collaborative study from Finland. J Neurovirol 2001;7(5):400–408
71 Child N, Croxson MC, Rahnama F, Anderson NE. A retrospective review of acute encephalitis in adults in Auckland over a five-year period (2005-2009) J Clin Neurosci 2012;19(11):1483–1485
72 Jain S, Patel B, Bhatt GC. Enteroviral encephalitis in children: clinical features, pathophysiology, and treatment advances. Pathog Glob Health 2014;108(5):216–222
73 Tiwari JK, Malhotra B, Chauhan A, et al. Aetiological study of viruses causing acute encephalitis syndrome in North West India. Indian J Med Microbiol 2017;35(4):529–534
74 Rathore SK, Dwibedi B, Kar SK, Dixit S, Sabat J, Panda M. Viral aetiology and clinico-epidemiological features of acute encephalitis syndrome in eastern India. Epidemiol Infect 2014;142(12):2514–2521
75 Saxena V, Dhole TN. Preventive strategies for frequent outbreaks of Japanese encephalitis in Northern India. J Biosci 2008;33(4):505–514
76 Saxena SK, Mishra N, Saxena R, Singh M, Mathur A. Trend of Japanese encephalitis in North India: evidence from thirty-eight acute encephalitis cases and appraisal of niceties. J Infect Dev Ctries 2009;3(7):517–530
77 Olson LC, Buescher EL, Artenstein MS, Parkman PD. Herpesvirus infections of the human central nervous system. N Engl J Med 1967;277(24):1271–1277
78 Kulkarni MA, Lecocq AC, Artsob H, Drebot MA, Ogden NH. Epidemiology and aetiology of encephalitis in Canada, 1994-2008: a case for undiagnosed arboviral agents? Epidemiol Infect 2013;141(11):2243–2255
79 Verma RK, Singh DP, Yadav R, Rawat R. Comparative evaluation of antigen detection ELISA and reverse transcriptase PCR in acute stage of Japanese encephalitis prevalent in endemic areas of North-Eastern part of Uttar Pradesh, India. Int J Res Med Sci 2015;3(11):3217–3223
80 Granerod J, Ambrose HE, Davies NW, et al. The aetiology of encephalitis in England: a multi-centre prospective study. Lancet Infect Dis 2010;10:835–844
81 Swanson II, Phillip A. & McGavern, Dorian. (2015). Portals of Viral Entry into the Central Nervous System. 10.1201/b19299-3
82 van Den Pol AN, Mocarski E, Saederup N, Vieira J, Meier TJ. Cytomegalovirus cell tropism, replication, and gene transfer in brain. J Neurosci 1999;19(24):10948–10965
83 Wolinsky JS, Baringer JR, Margolis G, Kilham L. Ultrastructure of mumps virus replication in newborn hamster central nervous system. Lab Invest 1974;31(4):403–412
84 Clay CC, Rodrigues DS, Ho YS, et al. Neuroinvasion of fluorescein-positive monocytes in acute simian immunodeficiency virus infection. J Virol 2007;81(21):12040–12048
85 Tabor-Godwin JM, Ruller CM, Bagalso N, et al. A novel population of myeloid cells responding to coxsackievirus infection assists in the dissemination of virus within the neonatal CNS. J Neurosci 2010;30(25):8676–8691
86 Terry RL, Getts DR, Deffrasnes C, van Vreden C, Campbell IL, King NJ. Inflammatory monocytes and the pathogenesis of viral encephalitis. J Neuroinflammation 2012;9:270
87 Tyor W, Harrison T. Mumps and rubella. Handb Clin Neurol 2014;123:591–600
88 Jubelt B, Lipton HL. Enterovirus/picornavirus infections. Handb Clin Neurol 2014;123:379–416
89 Griffin DE. Measles virus and the nervous system. Handb Clin Neurol 2014;123:577–590
90 King NJC, Getts DR, Getts MT, Rana S, Shrestha B, Kesson AM. Immunopathology of flavivirus infections. Immunol Cell Biol 2007;85(1):33–42
91 Dando SJ, Mackay-Sim A, Norton R, et al. Pathogens penetrating the central nervous system: infection pathways and the cellular and molecular mechanisms of invasion. Clin Microbiol Rev 2014;27(4):691–726
92 Johnson RT. The pathogenesis of acute viral encephalitis and postinfectious encephalomyelitis. J Infect Dis 1987;155(3):359–364
93 Steiner I, Budka H, Chaudhuri A, et al. Viral meningoencephalitis: a review of diagnostic methods and guidelines for management. Eur J Neurol 2010;17(8):999–e57
94 Davis LE, Acute viral meningitis and encephalitis. In: Kennedy PGE, Johnston RT, eds. Infections of the Nervous System. London: Butterworths; 1987:156–176
95 Fischer M, Lindsey N, Staples JE, Hills S; Centers for Disease Control and Prevention (CDC). Japanese encephalitis vaccines: recommendations of the Advisory Committee on Immunization Practices (ACIP) MMWR Recomm Rep 2010;59(RR-1):1–27
96 Wang D, Coscoy L, Zylberberg M, et al. Microarray-based detection and genotyping of viral pathogens. Proc Natl Acad Sci U S A 2002;99(24):15687–15692
97 Venkatesan A, Tunkel AR, Bloch KC, et al. International Encephalitis Consortium. Case definitions, diagnostic algorithms, and priorities in encephalitis: consensus statement of the international encephalitis consortium. Clin Infect Dis 2013;57(8):1114–1128
98 Britton PN, Eastwood K, Paterson B, et al. Australasian Society of Infectious Diseases (ASID)Australasian College of Emergency Medicine (ACEM)Australian and New Zealand Association of Neurologists (ANZAN)Public Health Association of Australia (PHAA). Consensus guidelines for the investigation and management of encephalitis in adults and children in Australia and New Zealand. Intern Med J 2015;45(5):563–576
99 Anon. Virus diagnostic scanning electronmicroscopy. Lancet 1988;1(8600):1436–1437
100 Solomon T, Hart IJ, Beeching NJ. Viral encephalitis: a clinician's guide. Pract Neurol 2007;7(5):288–305
101 Schroth G, Gawehn J, Thron A, Vallbracht A, Voigt K. Early diagnosis of herpes simplex encephalitis by MRI. Neurology 1987;37(2):179–183
102 Launes J, Nikkinen P, Lindroth L, Brownell AL, Liewendahl K, Iivanainen M. Diagnosis of acute herpes simplex encephalitis by brain perfusion single photon emission computed tomography. Lancet 1988;1(8596):1188–1191
103 Launes J, Sirén J, Valanne L, et al. Unilateral hyperfusion in brain-perfusion SPECT predicts poor prognosis in acute encephalitis. Neurology 1997;48(5):1347–1351
104 Davis LE. Diagnosis and treatment of acute encephalitis. Neurologist 2000;6:145–159
105 Koskiniemi M, Vaheri A, Taskinen E. Cerebrospinal fluid alterations in herpes simplex virus encephalitis. Rev Infect Dis 1984;6(5):608–618
106 Modlin JF, Dagan R, Berlin LE, Virshup DM, Yolken RH, Menegus M. Focal encephalitis with enterovirus infections. Pediatrics 1991;88(4):841–845
107 Tyler KL, Aseptic meningitis, viral encephalitis and prion diseases. In: Fauci AS, Braunwald E, Isselbacher KJ, et al, eds. Harrison's Principle of Internal Medicine, 14th edition. New York: McGraw Hill; 1998 2439–2451
108 Baringer JR, Herpes simplex virus encephalitis. In: Davis LE, Kennedy PGE, eds., Infectious Diseases of the Nervous System. Oxford: Butterworth-Heinemann; 2000 139–164
109 Kamei S, Taira N, Ishihara M, et al. Prognostic value of cerebrospinal fluid cytokine changes in herpes simplex virus encephalitis. Cytokine 2009;46(2):187–193
110 Sharief MK, Thompson EJ. A sensitive ELISA system for the rapid detection of virus specific IgM antibodies in the cerebrospinal fluid. J Immunol Methods 1990;130(1):19–24

111 Government of India. Guidelines on clinical management of acute encephalitis syndrome including Japanese Encephalitis. August 2009. Directorate of National Vector Borne Disease Control Programme, Directorate General of Health Services, Ministry of Health & Family Welfare
112 Booss J, Esiri MM, Pathological features of encephalitis in humans. In: Viral Encephalitis in Humans. Washington, DC: ASM Press; 2003:3–19
113 Bentivoglio M. Intraneuronal inclusion bodies: from Negri bodies to proteasomal dysfunction. Rend Fis Acc Lincei 2003;14:263–279
114 White CL, III. Taxy JB. Early morphologic diagnosis of herpes simplex virus encephalitis: advantages of electron microscopy and immunoperoxidase staining. Hum Pathol 1983;14(2):135–139
115 Dubois-Dalcq M, Coblentz JM, Pleet AB. Subacute sclerosing panencephalitis. Unusual nuclear inclusions and lengthy clinical course. Arch Neurol 1974;31(6):355–363
116 Kolski H, Ford-Jones EL, Richardson S, et al. Etiology of acute childhood encephalitis at The Hospital for Sick Children, Toronto, 1994-1995. Clin Infect Dis 1998;26(2):398–409
117 Ball R, Halsey N, Braun MM, et al. VAERS Working Group. Development of case definitions for acute encephalopathy, encephalitis, and multiple sclerosis reports to the vaccine: adverse event reporting system. J Clin Epidemiol 2002;55(8):819–824
118 Sejvar JJ, Kohl KS, Bilynsky R, et al. Brighton Collaboration Encephalitis Working Group. Encephalitis, myelitis, and acute disseminated encephalomyelitis (ADEM): case definitions and guidelines for collection, analysis, and presentation of immunization safety data. Vaccine 2007;25(31):5771–5792
119 Rowley AH, Whitley RJ, Lakeman FD, Wolinsky SM. Rapid detection of herpes-simplex-virus DNA in cerebrospinal fluid of patients with herpes simplex encephalitis. Lancet 1990;335(8687):440–441
120 Echevarría JM, Casas I, Tenorio A, de Ory F, Martínez-Martín P. Detection of varicella-zoster virus-specific DNA sequences in cerebrospinal fluid from patients with acute aseptic meningitis and no cutaneous lesions. J Med Virol 1994;43(4):331–335
121 Wiedmann M, Wilson WJ, Czajka J, Luo J, Barany F, Batt CA. Ligase chain reaction (LCR)–overview and applications. PCR Methods Appl 1994;3(4):S51–S64
122 Liolios L, Jenney A, Spelman D, Kotsimbos T, Catton M, Wesselingh S. Comparison of a multiplex reverse transcription-PCR-enzyme hybridization assay with conventional viral culture and immunofluorescence techniques for the detection of seven viral respiratory pathogens. J Clin Microbiol 2001;39(8):2779–2783
123 Johnson BW, Russell BJ, Lanciotti RS. Serotype-specific detection of dengue viruses in a fourplex real-time reverse transcriptase PCR assay. J Clin Microbiol 2005;43(10):4977–4983
124 Lanciotti RS, Kerst AJ. Nucleic acid sequence-based amplification assays for rapid detection of West Nile and St. Louis encephalitis viruses. J Clin Microbiol 2001;39(12):4506–4513
125 Ledermann JP, Lorono-Pino MA, Ellis C, et al. Evaluation of widely used diagnostic tests to detect West Nile virus infections in horses previously infected with St. Louis encephalitis virus or dengue virus type 2. Clin Vaccine Immunol 2011;18(4):580–587
126 Klein D. Quantification using real-time PCR technology: applications and limitations. Trends Mol Med 2002;8(6):257–260
127 Corless CE, Guiver M, Borrow R, Edwards-Jones V, Fox AJ, Kaczmarski EB. Simultaneous detection of Neisseria meningitidis, Haemophilus influenzae, and Streptococcus pneumoniae in suspected cases of meningitis and septicemia using real-time PCR. J Clin Microbiol 2001;39(4):1553–1558
128 Nolte F, Caliendo A, Molecular detection and identification of microorganisms. In: Murray P, Baron E, Jorgensen J, Landry M, Pfaller M, eds. Manual of Clinical Microbiology. 9th ed. Washington, DC: ASM Press; 2007 1: 218–244
129 Parida M, Sannarangaiah S, Dash PK, Rao PV, Morita K. Loop mediated isothermal amplification (LAMP): a new generation of innovative gene amplification technique; perspectives in clinical diagnosis of infectious diseases. Rev Med Virol 2008;18(6):407–421
130 Mori Y, Notomi T. Loop-mediated isothermal amplification (LAMP): a rapid, accurate, and cost-effective diagnostic method for infectious diseases. J Infect Chemother 2009;15(2):62–69
131 Mikhailovich V, Gryadunov D, Kolchinsky A, Makarov AA, Zasedatelev A. DNA microarrays in the clinic: infectious diseases. BioEssays 2008;30(7):673–682
132 Boriskin YS, Rice PS, Stabler RA, et al. DNA microarrays for virus detection in cases of central nervous system infection. J Clin Microbiol 2004;42(12):5811–5818
133 Varro R, Chen R, Sepulveda H, Apgar J. Bead-based multianalyte flow immunoassays: the cytometric bead array system. Methods Mol Biol 2007;378:125–152
134 Chung PW, Huang YC, Chang LY, Lin TY, Ning HC. Duration of enterovirus shedding in stool. J Microbiol Immunol Infect 2001;34(3):167–170
135 Tyler KL, Tyler MD. Acute viral encephalitis. N Engl J Med 2018;379(6):557–566
136 Domingues RB. Treatment of viral encephalitis. Cent Nerv Syst Agents Med Chem 2009;9(1):56–62
137 Enting R, de Gans J, Reiss P, Jansen C, Portegies P. Ganciclovir/foscarnet for cytomegalovirus meningoencephalitis in AIDS. Lancet 1992;340(8818):559–560
138 Balfour HH Jr. Antiviral drugs. N Engl J Med 1999;340(16):1255–1268
139 Sonneville R, Klein I, de Broucker T, Wolff M. Post-infectious encephalitis in adults: diagnosis and management. J Infect 2009;58(5):321–328
140 Sköldenberg B, Forsgren M, Alestig K, et al. Acyclovir versus vidarabine in herpes simplex encephalitis. Randomised multicentre study in consecutive Swedish patients. Lancet 1984;2(8405):707–711
141 Tzannou I, Papadopoulou A, Naik S, et al. Off-the-shelf virus-specific T cells to treat BK virus, human herpesvirus 6, cytomegalovirus, Epstein-Barr virus, and adenovirus infections after allogeneic hematopoietic stem-cell transplantation. J Clin Oncol 2017;35(31):3547–3557
142 Davies SI, Muranski P. T cell therapies for human polyomavirus diseases. Cytotherapy 2017;19(11):1302–1316
143 Whitley RJ, Lakeman F. Herpes simplex virus infections of the central nervous system: therapeutic and diagnostic considerations. Clin Infect Dis 1995;20(2):414–420
144 Raschilas F, Wolff M, Delatour F, et al. Outcome of and prognostic factors for herpes simplex encephalitis in adult patients: results of a multicenter study. Clin Infect Dis 2002;35(3):254–260
145 Utley TF, Ogden JA, Gibb A, McGrath N, Anderson NE. The long-term neuropsychological outcome of herpes simplex encephalitis in a series of unselected survivors. Neuropsychiatry Neuropsychol Behav Neurol 1997;10(3):180–189
146 McGrath N, Anderson NE, Croxson MC, Powell KF. Herpes simplex encephalitis treated with acyclovir: diagnosis and long term outcome. J Neurol Neurosurg Psychiatry 1997;63(3):321–326
147 McArthur JC. HIV dementia: an evolving disease. J Neuroimmunol 2004;157(1-2):3–10

148 Ito Y, Kimura H, Yabuta Y, et al. Exacerbation of herpes simplex encephalitis after successful treatment with acyclovir. Clin Infect Dis 2000;30(1):185–187
149 Yang Y, Liang N, Tan Y, Xie Z. Epidemiological trends and characteristics of Japanese encephalitis changed based on the vaccination program between 1960 and 2013 in Guangxi Zhuang Autonomous Region, southern China. Int. J Infect Dis 2016;45:135–138
150 Koskiniemi M, Vaheri A. Effect of measles, mumps, rubella vaccination on pattern of encephalitis in children. Lancet 1989;1(8628):31–34