

Osteochondroma of the Coronoid Process and Joint Formation with Zygomatic Arch (Jacob Disease): Report of a Case

Ahmet Yesildag^a
Murat Yariktas^b
Fehmi Doner^b
Gulsen Aydin^c
Mehmet Munduz^a
Ummuhan Topal^a

ABSTRACT

Jacob disease is a rare condition consisting of pseudo joint formation between enlarged mandibular coronoid process and the inner surface of the zygoma. We report a 16-years-old male patient with Jacob disease who presented with restricted mouth opening and swelling of the right zygoma. In this report, clinical, radiological, and histopathological findings of the Jacob disease and its surgical approach are discussed. [Eur J Dent 2010;4:91-94]

Key words: Mandible; Osteochondroma; Jacob disease; Computed tomography.

- ^a Department of Radiology, Medical Faculty, Suleyman Demirel University, Isparta, Turkey.
- ^b Department of Otolaryngology, Medical Faculty, Suleyman Demirel University, Isparta, Turkey.
- ^c Department of Pathology, Medical Faculty, Suleyman Demirel University, Isparta, Turkey.

■ Corresponding author: Ahmet Yesildag
Modernevler Mah, 142. cad.
Coskun sitesi. A-blok. No: 25 Daire: 8
Isparta, Turkey.
Fax: +90 246 2371762
E-mail: ahmetysd@hotmail.com

INTRODUCTION

Jacob disease is a new joint formation between enlarged coronoid process and the zygoma.¹ Despite hyperplasia of the coronoid process of the mandible was first described by Langenbeck in 1853, the joint formation between the coronoid process and the zygoma was defined later by Oscar Jacob in 1899.^{2,3} Enlargement of coronoid process has been sporadically reported in the lit-

erature but only a few report of Jacob disease has been reported.

Osteochondroma, exostosis, osteoma, hypertrophy, hyperplasia and developmental anomalous may cause coronoid process enlargement.^{4,5} Osteochondroma is uncommon in the craniofacial skeleton. However osteochondroma of the coronoid process is even more rare.^{6,7}

Jacob disease related to coronoid process osteochondroma has also been reported very small number in the literature. In this report, we present a case of Jacob disease due to osteochondroma of coronoid process including all criteria such as clinical, radiological, surgical and histopathological.

CASE REPORT

A 16-year-old man admitted to our clinic with a 1-year history of progressive limitation in mouth opening and a painless swelling in the right zygomatic region. He was initially misdiagnosed by dentists as having a right temporomandibular joint (TMJ) ankylosis. Physical examination showed a 3x2 cm swelling in the right zygomatic arch and facial asymmetry. Protrusion was 7 mm with deviation to the right, and right lateral excursion was 8 mm and the interincisal mouth opening

width was 12 mm. He had no previous history of trauma in the facial area.

The panoramic radiographs revealed an enlarged and distorted right coronoid process. Computed tomography scans of zygomaticocoronoid region were obtained in both axial and coronal planes. The coronal images showed an irregular bony outgrowth from lateral aspect of the superior portion of the right coronoid process to inner surface of the zygomatic arch. Axial (Figure 1) and 3D reconstruction (Figure 2) images showed a mushroom shaped bony outgrowth of coronoid process with pseudo joint formation between the coronoid process and the inner surface of the zygomatic arch. Zygomatic arch was curved laterally by this bony outgrowth. These features of the images made suspicion of osteochondroma. The core needle biopsy was obtained percutaneously from mass and osteochondroma diagnosis was made.

An operation with external approach via modified hockey stick incision was performed under general endotracheal anesthesia. The right coronoid process was cut horizontally at 1.5 cm below the tumor margin. The zygomatic arch was cut

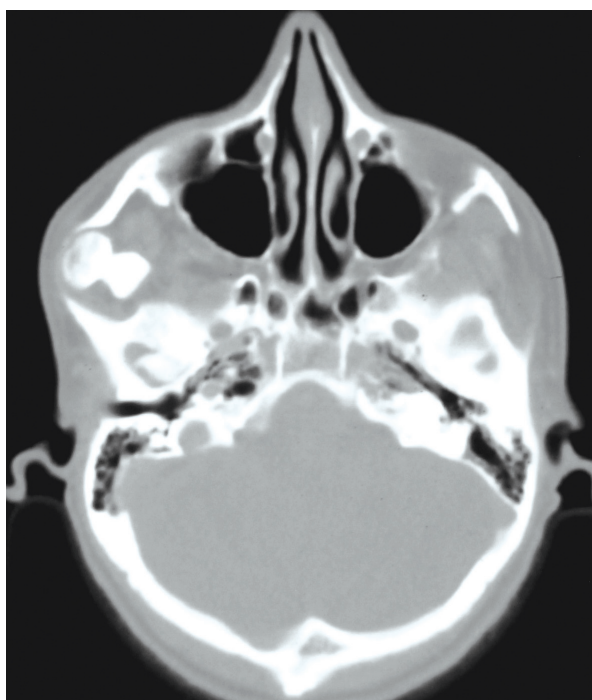


Figure 1. Axial CT image at the level of the zygomatic arch shows a mushroom-shaped osteochondroma of right coronoid process and the extent of the mass into inner surface of the zygomatic arch.

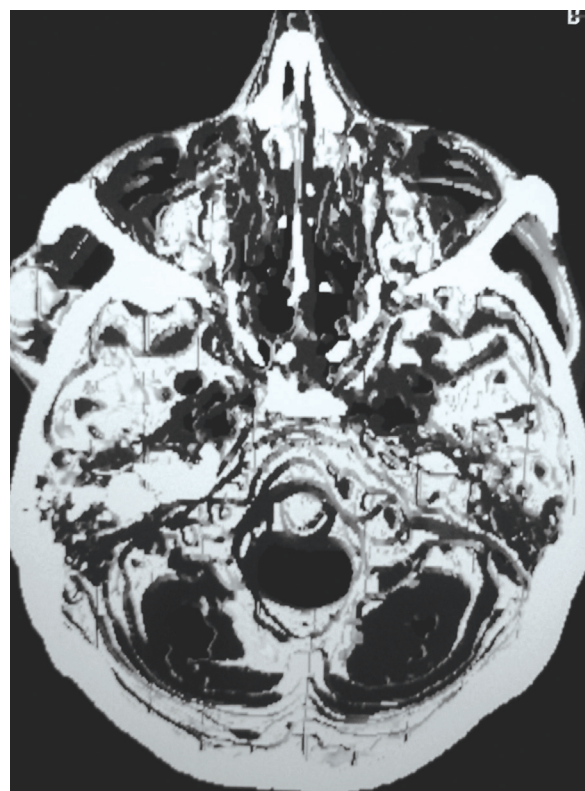


Figure 2. Three-dimensional reformatted image shows a new joint formation between the mushroom-shaped osteochondroma of right coronoid process and inner surface of the zygomatic arch.

partially and smoothed for irregular bony surface. The defect area was closed with pedicled flap of temporalis muscle. The specimen was mushroom-shaped and, measured 24 mm x 18 mm x 23 mm. Pathologic examination showed typical histological characteristics with the mass to be composed of bone covered by a cap of cartilage, and showed fibrous, cartilaginous, and bony elements which were irregularly arranged. Synovial tissue was attached to the hyperplastic coronoid process (Figure 3). This finding confirmed osteochondroma and indicated that the present case has a new joint formed between the right coronoid process and zygoma (Jacob Disease). After surgery, interincisal opening of 50 mm was achieved in 7th day and 52 mm in 14th month. Facial asymmetry and swelling in the right zygomatic arch were also improved.

DISCUSSION

Coronoid process enlargement is a condition that can result from exostosis, osteoma, osteochondroma, chondroma, hyperplasia and developmental anomalous.^{4,5} Coronoid hyperplasia is an infrequent condition that might be unilateral or bilateral.⁸ However, Jacob disease is more rare than isolated coronoid hyperplasia.⁹ Escuder i de la Torre et al² reviewed only 12 cases of Jacob disease and added two cases of their own until 2001. A few cases has been added to English literature from 2001 to now.⁹⁻¹¹

Osteochondroma is benign exostosis with cartilaginous components. The causative factor is unknown but is thought to be related to periosteal activity that forms abnormal foci of the metaplas-

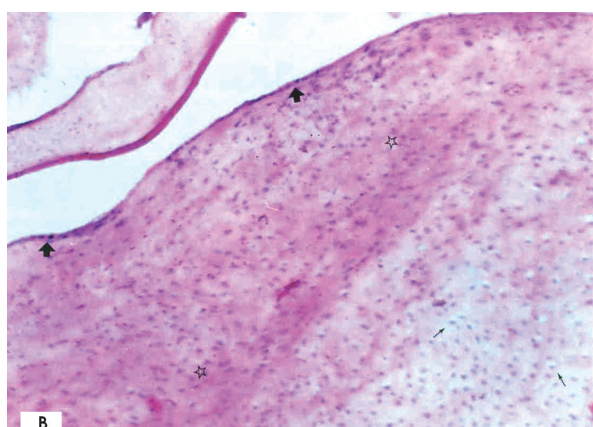


Figure 3. Photomicrograph showing fibrous tissue (asterisks) covered synovial epithelium (arrowheads) and continuity of cartilaginous element (thin arrows).

tic cartilage.^{4,7} Numerous factors have been suggested in the pathogenesis of coronoid process osteochondroma but nothing has been suggested regarding the pathogenesis of the new joint formation between osteochondromas of the coronoid process and the zygomatic arch (Jacob Disease).^{1,5}

Mushroom-shaped osteochondroma of the coronoid process that lead to a new joint formation in the zygomatico-coronoid region was described with all properties including clinical, radiological, histopathological and surgical in this case report. Only two similar cases have been reported previously.^{10,11} Differential diagnosis of this entity can be made from panoramic radiograph and CT imaging, and careful clinical examination.^{5,12,13} CT scan, especially with 3D reconstruction, is a very useful method for the diagnosis of Jacob disease.^{2,9-11} CT images can show more detailed bony growth of coronoid process and its relationship between coronoid and zygoma. In addition, these images provide important information to surgeon for biopsy and surgery. Although preoperative the core needle biopsy is very important for differential diagnosis (malignant or benign) and especially to plan the surgery, we couldn't determine it to diagnose osteochondroma of coronoid process preoperatively, in the literature. In our case, the core needle biopsy was easily obtained percutaneously from mass and a diagnosis osteochondroma was made preoperatively, and we planned the operation with respect to preoperative histopathologic diagnosis.

Most of the patients with coronoid process osteochondroma firstly admitted to a dentist, and they were initially misdiagnosed as a TMJ disorder and managed as such.^{1,2} The main reason of this condition may probably be not to take CT. We claimed that TMJ ankylosis of our case was a misdiagnosis.

The surgical approaches to treat this disease have either been intraoral, external, or a combination of both.^{6,12,14} The intraoral approach eliminates a skin scar and the risk of facial nerve damage, but the occasional herniation of the buccal fat pad into the surgical site if the dissection is extended too far superiorly and medially.⁴ In some cases, the size and bulbous nature of the exostosis may prevent withdrawal through the space between the temporal bone and zygomatic arch, so that an external approach is indicated.¹² Some authors

prefer the direct external approach such as coronal and face-lift incision which preserves the facial nerve fibers.^{1,12,14} We performed an extra oral approach via a modified hockey stick incision that gives excellent access and a good cosmetic result, and protects the facial nerve from damage.

CONCLUSIONS

CT imaging is an important tool in patients who presented with zygomatic swelling and limited mouth opening. CT imaging with 3D reconstruction can diagnose the Jacob disease with showing relationship between enlarged coronoid and zygomatic arch. CT imaging can be used as a guide for planning the core needle biopsy and surgical approach in the preoperative period.

REFERENCES

1. Hernandez-Alfaro F, Escuder O, Marco V. Joint formation between an osteochondroma of the coronoid process and the zygomatic arch (Jacob disease): report of case and review of literature. *J Oral Maxillofac Surg* 2000;58:227-232.
2. Escuder i de la Torre O, Vert Klok E, Mari i Roig A, Mommaerts MY, Pericot i Ayats J. Jacob's disease: report of two cases and review of the literature. *J Craniomaxillofac Surg* 2001;29:372-376.
3. Jacob O. Une cause rare de constriction permanente des machoires. *Bull et Mem de la Societe Anatomique de Paris* 1899;1:917-919.
4. Meyer RA. Osteochondroma of coronoid process of mandible: report of case. *J Oral Surg* 1972;30:297-300.
5. Totsuka Y, Fukuda H, Iizuka T, Shindoh M, Amemiya A. Osteochondroma of the coronoid process of the mandible. Report of a case showing histological evidence of neoplasia. *J Craniomaxillofac Surg* 1990;18:27-32.
6. Kerscher A, Piette E, Tideman H, Wu PC. Osteochondroma of the coronoid process of the mandible. Report of a case and review of the literature. *Oral Surg Oral Med Oral Pathol* 1993;75:559-564.
7. McGuire MH, Mankin HJ, Schiller AL. Benign cartilage tumors of bone. In: Everts CMC editor. *Surgery of the musculoskeletal system*. 2nd ed. New York-Edinburg-London-Melborn: Churchill Livingstone; 1990:4720-4725.
8. Colquhoun A, Cathro I, Kumara R, Ferguson MM, Doyle TC. Bilateral coronoid hyperplasia in two brothers. *Dentomaxillofac Radiol* 2002;31:142-146.
9. Akhan H, Mehreliyeva N. The value of three-dimensional computed tomography in diagnosis and management of Jacob's disease. *Dentomaxillofac Radiol* 2006;35:55-59.
10. Roychoudhury A, Gupta YK, Parkash H, Karak AK. Jacob disease: report of a case and review of the literature. *J Oral Maxillofac Surg* 2002;60:699-703.
11. Emekli U, Aslan A, Onel D, Cizmeci O, Demiryont M. Osteochondroma of the coronoid process (Jacob's disease). *J Oral Maxillofac Surg* 2002;60:1354-1356.
12. Ramon Y, Horowitz I, Oberman M, Freedman A, Tadmor R. Osteochondroma of the coronoid process of the mandible. *Oral Surg Oral Med Oral Pathol* 1977;43:692-697.
13. Goudot P, Guilbert F, Buthiau D, Auriol M. Value of modern imagery in the study of coronoid-malar malformations. Apropos of 2 cases. *Rev Stomatol Chir Maxillofac* 1989;90:424-427.
14. Chen PK, Chang SC, Huang F, Chen YR, Yeow VK, Williams WG. Transzygomatic coronoidectomy through an extended coronal incision for treatment of trismus due to an osteochondroma of the coronoid process of the mandible. *Ann Plast Surg* 1998;41:425-429.