

Functional Treatment of an Asymmetry Case Having Left Side Paralysis: A Case Report

Meliha Rubenduz^a
Ozge Uslu^b

ABSTRACT

This case report presents the results of functional and myofunctional treatment of a 9-year, 5-month-old male patient with laterognathy, facial asymmetry and dentofacial deformity. The patient had a history of herpes encephalitis at age 8.5 months and palsy on the left side in early childhood, and his left side remained paralyzed as a sequela. The patient had dentoalveolar asymmetry with a Class I right and Class III left canine relation, a 1.5 mm midline deviation, anterior cross-bite, an overjet of -3 mm and an overbite of 3 mm. The dentoalveolar and facial asymmetries were corrected using a modified removable appliance, with an acrylic vestibular shield inserted on the right side to guide the mandible in the upper arch and an acrylic plate with artificial teeth in the lower arch. The patient was instructed to practice myofunctional exercises regularly. In total, treatment, including observation, was completed in a period of 2 years and 10 months, at which time, a marked correction in facial asymmetry and profile and improvement in smile esthetics could be observed. (Eur J Dent 2010;4:341-347)

Key words: Facial asymmetry; Functional treatment; Laterognathy; Myofunctional exercises.

INTRODUCTION

Asymmetry of the face and dentition is a natural phenomenon. Facial asymmetry, defined as a difference in the size or shape of the sides of the face, is correlated with facial harmony.¹ The etiological factors of facial asymmetries and their

mechanisms are not completely understood;² however, it is well known that facial deformities are often exacerbated by growth.³ Facial asymmetries can be classified as either developmental (agenesis, hypoplasia, or hyperplasia of the facial bones) or acquired (resulting from trauma, infection, or functional shifts).² A number of variables obtained from frontal cephalograms can be used to distinguish types of asymmetry, and these distinctions can be helpful in diagnosis and treatment planning.⁴ In patients with hemimandibular hyperplasia or hypoplasia, for example, the dimensions of the two halves of the base of the mandible are unequal. With lateromandibulism, the mandible is shifted to one side, although both halves of the base may have equal dimensions.⁶ While man-

- ^a Professor, Ankara University, School of Dentistry, Department of Orthodontics, Ankara, Turkey.
- ^b Research Assistant, Ankara University, School of Dentistry, Department of Orthodontics, Ankara, Turkey

- Corresponding author: Ozge Uslu
Ankara University, Faculty of Dentistry,
Department of Orthodontics,
Besevler, 06500, Ankara, Turkey.
Phone: +90 312 2122708
Fax: +90 312 2130960
E-mail: dtozgeuslu@gmail.com

mandibular asymmetry is a common finding in individuals with a normal facial appearance,⁵ severe asymmetry can cause both esthetic and functional problems. Orthodontic treatment is necessary to correct mandibulofacial asymmetry, the most common cause of which is condylar asymmetry.^{7,8}

This report presents the functional and myofunctional treatment of a patient with laterognathism, facial asymmetry and dentofacial deformity.

CASE REPORT

A 9-year, 5-month-old male patient was referred to the university dental clinic for orthodontic treatment with the chief complaint of mandibular deviation. His medical history revealed herpes encephalitis at 8.5 months and palsy on the left side in early childhood that had resulted in paralysis of his left side as a sequela. The patient's left extremities remained weak, and he had cardiovascular problems for which he was receiving treatment.

Extraoral examination revealed a left ear deformity; exophthalmic eyes; significant facial asymmetry, with the dimensions of the left side smaller

than those of the right side; and midface growth deficiency (Figure 1). Intraoral findings included dentoalveolar asymmetry with a Class I right and Class III left canine relation, a 1.5 mm midline deviation, anterior cross-bite, an overjet of -3 mm and an overbite of 3 mm (Figure 2). The mandibular first molars were congenitally absent, and the maxillary first molars had large caries. Eruption of the permanent teeth was late, and alveolar development was insufficient. The findings of pre-treatment lateral and postero-anterior cephalometric analysis are presented in Table 1. The patient was in the PP2= skeletal growth stage, and hand-wrist radiographs indicated he had completed 75.2% of his growth (Figure 3).

Orthodontic treatment objectives included correction of dental and facial asymmetry, correction of anterior crossbite, guidance of eruption and alignment of the permanent teeth.

Teeth eruption was stimulated by using an acrylic lower plate with artificial posterior teeth (Figure 4). The vestibular arch of the lower plate was activated to retrude the lower incisors. A modified upper removable appliance was used to

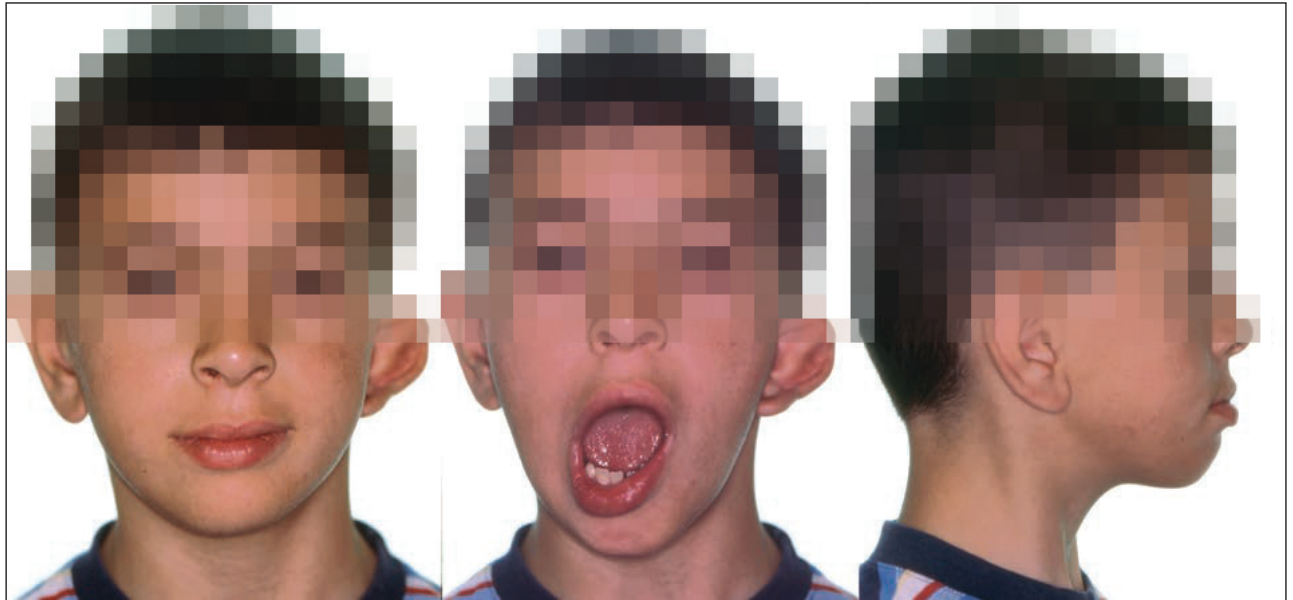

Figure 1. Pre-treatment extraoral photographs

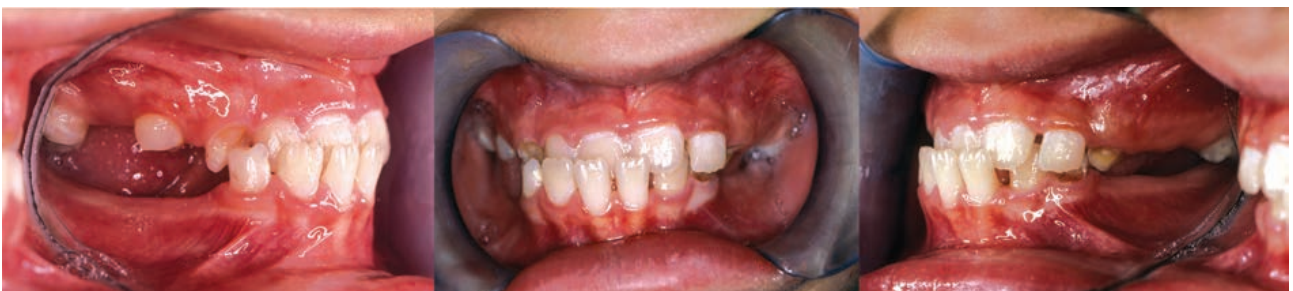

Figure 2. Pre-treatment intraoral photographs

correct the dentoalveolar and facial asymmetry. The appliance was fabricated to allow for a 3 mm mandibular shift and 4 mm bite opening. Point-shaped acrylics were added to correct the dental midline and protrude the upper incisors, and an

acrylic shield was incorporated into the right vestibular area to guide the mandible.

The patient was also instructed to practice myofunctional exercises (smile exercises, cheek inflating, cheek stretching and lip stretching) 3 times a day for a minimum of 3 minutes to achieve facial improvement.

Treatment, including observation, covered a period of 2 years and 10 months. A marked correction in facial asymmetry and profile was observed; and smile esthetics improved. The patient continues to use the appliance at night for retention.

Class III latero-occlusion treated with an upper removable appliance resulted in a Class I molar occlusion, an ideal overjet and overbite and correction of facial asymmetry (Figure 5). The patient was in the MP3= growth stage at the end of functional treatment (Figure 6). Postero-anterior cephalometric measurements were shown in Figure 7. Bjork's structural superimpositions indicated forward rotation of the mandible, mild protrusion of the upper incisors, ideal positioning of the lower incisors and eruption of the lower second molars. Changes were also observed in the soft-tissue profile (Figure 7).

DISCUSSION

The management of asymmetry cases involves some of the most challenging treatment planning decisions orthodontists may face.⁹ Clinical exami-

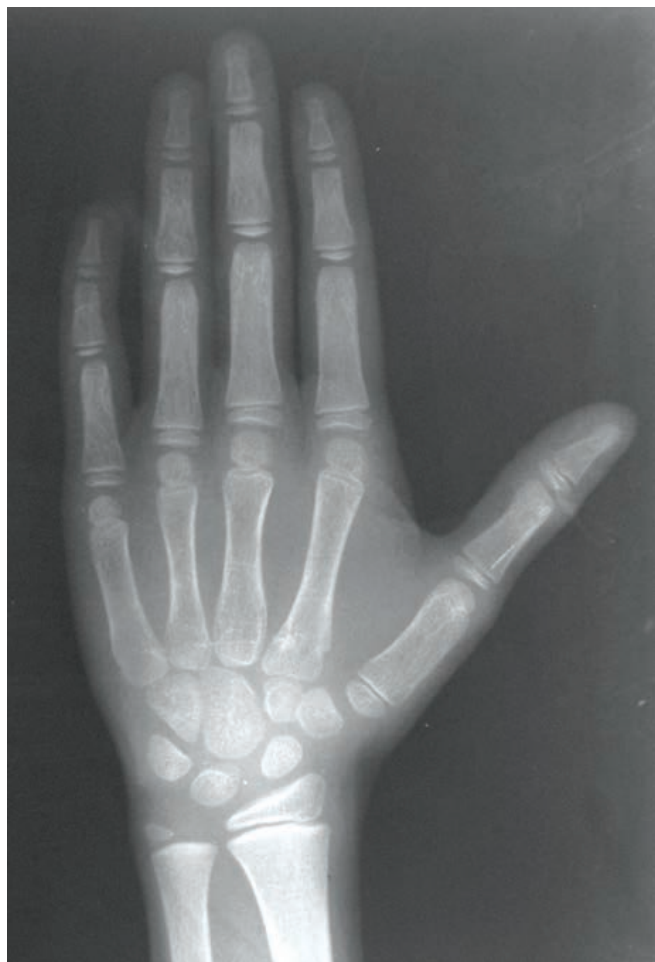

Figure 3. Pre-treatment hand-wrist radiograph.

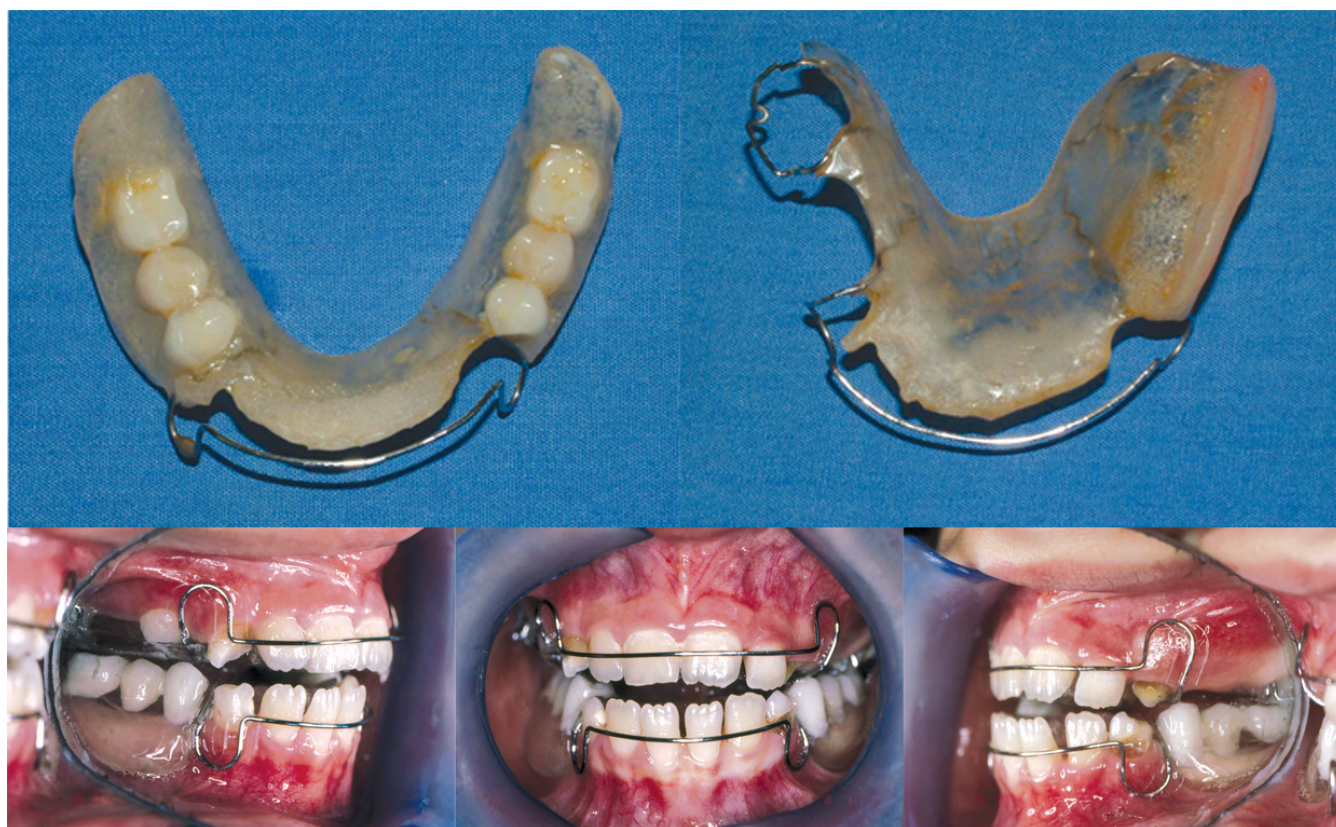

Figure 4. Removable appliances inserted in the mandibular and maxillary arches.

nation of the transverse functional relationship is an easy process that consists of observing the position of the midline as the teeth are brought together from the rest position to habitual occlusion.¹⁰ While mild deviations caused by functional shifts can be corrected with minor occlusal adjustments, severe deviations need orthodontic treatment and surgery to achieve tooth alignment. Dental asymmetries can often be corrected by orthodontic and orthognathic surgical treatment using symmetric extraction sequences and asymmetric mechanics. Depending upon the growth potential of the case, occlusal splints, rapid maxillary expansion, or orthognathic surgery may be indicated. Mandibular asymmetry can also be corrected using miniscrews,^{11,12} whereas soft-tissue asymmetries can be treated with augmentation or reduction surgery.¹

Cross-bite cases with lateral shifting of the mandibular midline can be differentiated as either latero-occlusion or laterognathy. With latero-occlusion, the midline shift can only be observed in the occlusal position, whereas with laterognathy, the midline shift can be observed in both the occlusal and postural positions. Without treatment, cross-bite and latero-occlusion during the growth period can lead to asymmetric jaw growth.¹³ Some authors believe that severe cases of laterognathy cannot be successfully treated with a functional appliance and that surgery is the only alternative,¹⁰ whereas others have reported improvements using a functional appliance during the early growth stages.¹⁴ In severe cases of hemifacial microsomia, orthopedic surgery may be required to correct growth imbalance.¹⁵

The size and orientation of human jaw mus-

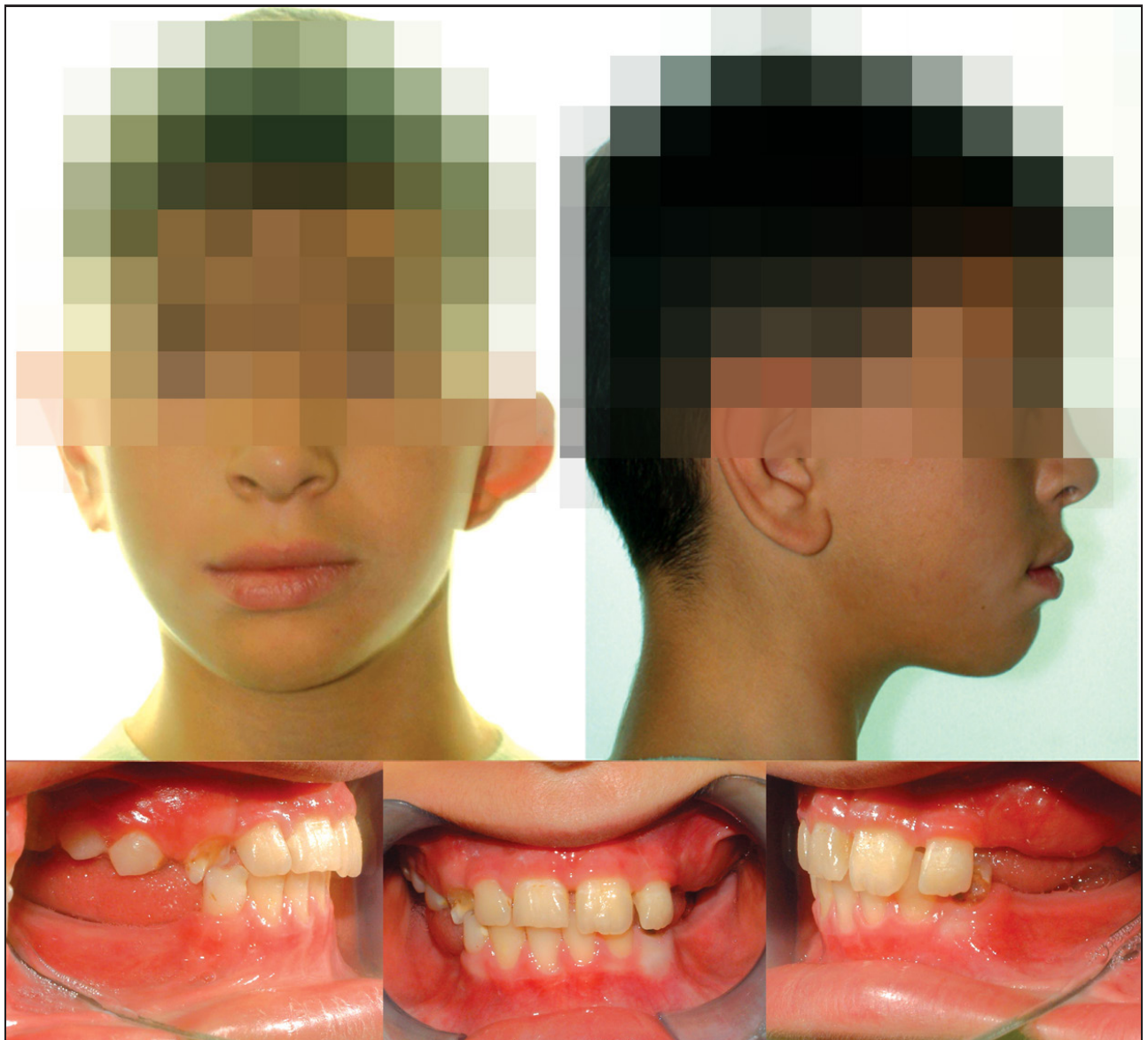


Figure 5. Post-treatment extraoral and intraoral photographs.

cles vary with craniofacial form. In patients with hemifacial microsomia, jaw muscles have been found to be significantly smaller on the affected side when compared to the non-affected side,^{16,17} and the jaw muscles on the non-affected side have also been shown to be less developed than those of controls.¹⁵ Moreover, the degree of masticatory muscle hypoplasia in hemifacial microsomia patients has been found to increase with the degree of mandibular dysmorphology.¹⁷ In the case presented here, in order to achieve growth and improvement in facial and masticator muscles, the patient was instructed to practice myofunctional exercises (smile exercises, cheek inflating, cheek and lip stretching) on a regular basis.

Asymmetrical patients have also been found to have a higher incidence of morphological changes and internal derangement in the TMJ on the shifted side when compared to the non-shifted side,¹⁸ and it has been suggested that the incidence of disk displacement and TMJ disorder symptom on the deviated side is higher than on the non-deviated side.¹⁹ In the case presented here, no symptoms of TMJ disorder were observed either before or after functional appliance therapy.

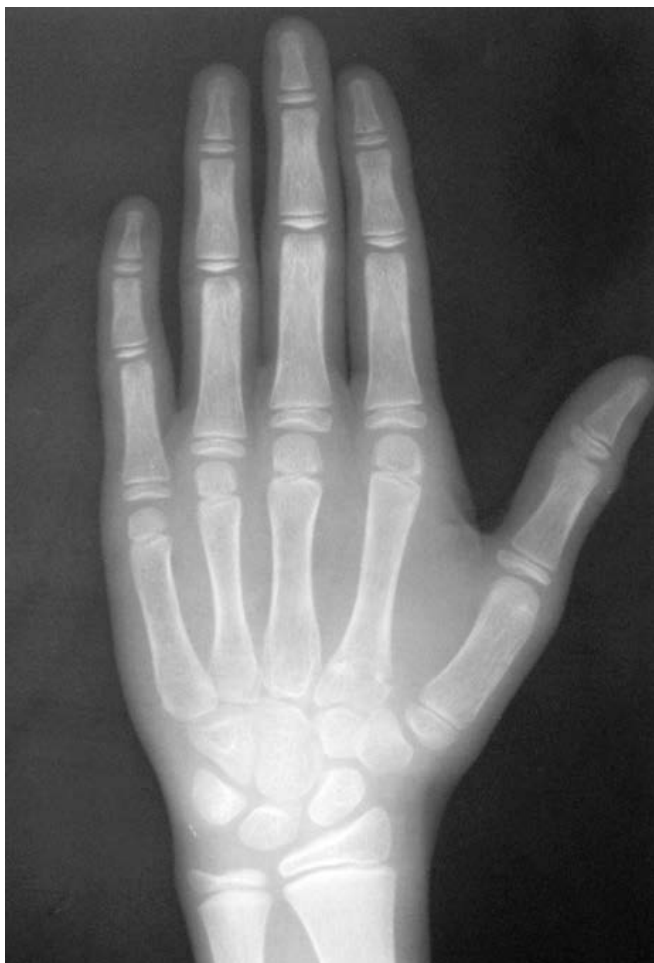

Figure 6. Post-treatment hand-wrist radiograph.

In a study of adult rhesus monkeys, asymmetric lateral force was shown to result in growth modification on the distal surface of the condyle after 6 months,²⁰ while a study on rats found that lateral forced bite influenced the structure and shape of the mandibular bone and the composition of the masseter muscle.²¹ In the case presented here, growth modification and stretching of soft tissues led to improvements in mandibular bone shape and facial form. These results support the findings of Melsen et al¹⁴ that functional appliance therapy can establish symmetry in facial asymmetry cases. Authors of that study emphasized that because results depend on timing as well as on patient compliance, treatment should be initiated as early as possible.¹⁴

In the case reported here, functional appliance therapy achieved satisfactory improvements in facial esthetics and symmetry in a short period of time that was maintained after 2 years of follow-up (Figure 8). With this improved function and growth, the patient also experienced markedly positive psychosocial changes. In view of the patient's growth potential, long-term follow-up is planned.

CONCLUSIONS

In spite of the fact that orthognathic surgery was indicated at the beginning of treatment, considerable improvements in facial and dental esthetics and oral functions were achieved with a functional and myofunctional orthodontic approach. At the end of treatment, acceptable esthetic and psychosocial outcomes were obtained.

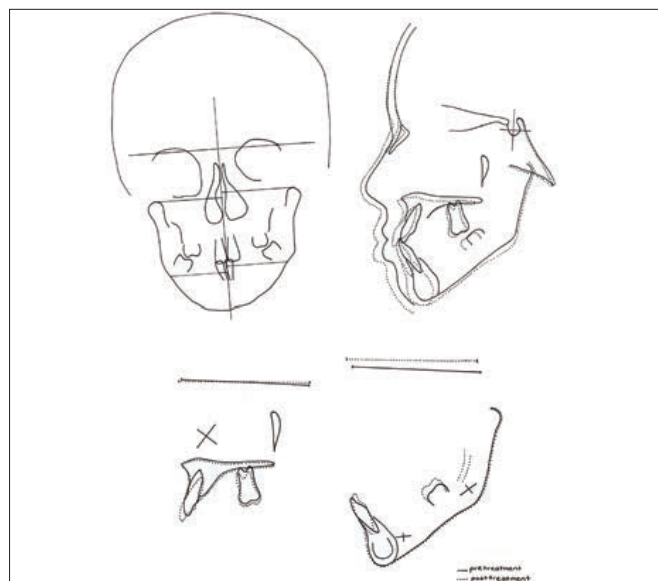


Figure 7. Postero-anterior cephalometric measurements and superimpositions using Björk's structural technique.

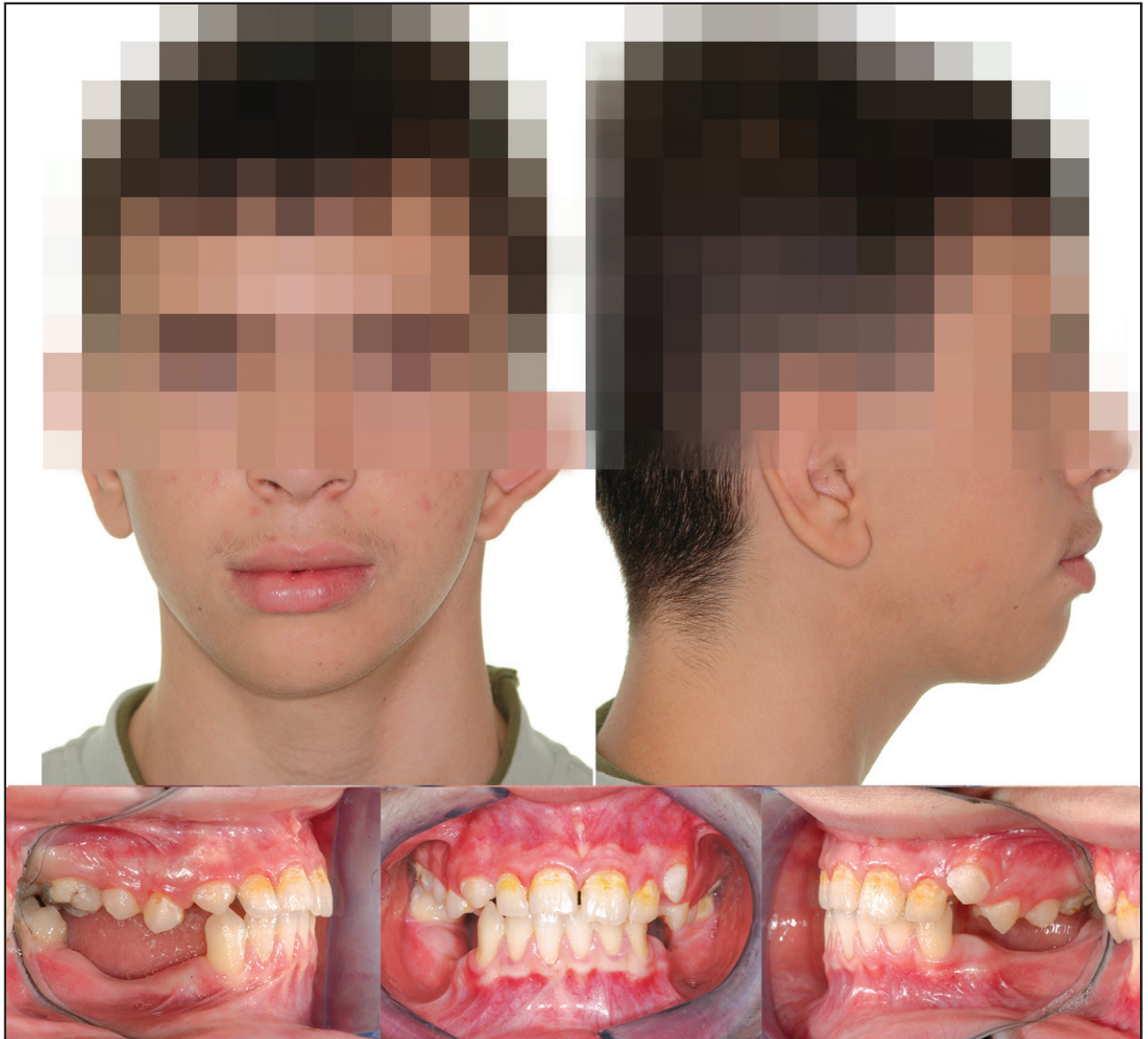

Figure 8. Two years follow-up extraoral and intraoral photographs.

Table 1. Pre-treatment and post-treatment cephalometric analysis.

Lateral cephalometric analysis	Pretreatment	Post-treatment
SNA	82°	83°
SNB	82°	83°
ANB	0°	0°
Upper incisor-NA	4.5 mm / 29°	6.5 mm / 32°
Lower incisor-NB	7 mm / 30°	4 mm / 20°
Pg-NB	-0.5 mm	0 mm
Interincisal angle	121°	130°
Occl-SN	12°	11°
GoGn/SN	36°	35°
Steiner's Line Upper lip/ Lower lip	2 mm / 5 mm	2.5 mm / 5 mm
Posteroanterior cephalometric analysis	Right-Left discrepancy	Right-Left discrepancy
Condylion-vertical reference line	-3 mm	-0.5 mm
Maxillare-vertical reference line	0.5 mm	0.5 mm
Upper molar-vertical reference line	1 mm	1 mm
Lower molar-vertical reference line	-3 mm	0 mm
Mandibulare-vertical reference line	-2 mm	1 mm

REFERENCES

1. Bishara SE, Burkey PS, Kharouf JG. Dental and facial asymmetry: a review. *Angle Orthod* 1994;64:89–98.
2. Menlik AK. A cephalometric study of mandibular asymmetry in a longitudinally followed sample of growing children. *Am J Orthod Dentofac Orthop* 1992;101:355–366.
3. Proffit WR, White RP. Surgical orthodontic treatment, 2nd edition, Mosby, St. Louis 1991, p.142–168.
4. Hwang HS, Youn IS, Lee KH, Lim HJ. Classification of facial asymmetry by cluster analysis. *Am J Orthod Dentofac Orthop* 2007;132:279.
5. Pirttiniemi PM. Associations of mandibular and facial asymmetries—a review. *Am J Orthod Dentofacial Orthop* 1994;106:191–200.
6. Singh G. Orthognathic Surgery, in Textbook of Orthodontics, 1st edition, Jaypee Brothers Medical Publishers, India, 2004, p.262.
7. Sezgin OS, Celenk P, Arıcı S. Mandibular asymmetry in different occlusion patterns. *Angle Orthod* 2007;77:803–807.
8. Yamashiro T, Okada T, Takada K. Case report: facial asymmetry and early condylar fracture. *Angle Orthod* 1998;68:85–90.
9. Graber M, Vanarsdall Jr.RL. Orthodontics and orthognathic surgery: Principles of combined treatment, in *Orthodontics Current Principles and Techniques*, 2nd edition, Mosby, St. Louis, 1994, p.876.
10. Graber TM, Rakosi T, Petrovic AG. Treatment of Class III malocclusion, in *Dentofacial Orthopedics with functional appliances*, 2nd edition, Mosby, St. Louis, 1997, p.133.
11. Weisner SM. Treatment of a skeletal Class III malocclusion with mandibular asymmetry using a single miniscrew. *J Clin Orthod* 2009;43:335–341.
12. Takano-Yamamoto T, Kuroda S. Titanium screw anchorage for correction of canted occlusal plane in patients with facial asymmetry. *Am J Orthod Dentofacial Orthop* 2007;132:237–242.
13. Egermark I, Thilander B. Craniomandibular disorders with special reference to orthodontic treatment: an evaluation from childhood to adulthood. *Am J Orthod Dentofac Orthop* 1992;101:28–34.
14. Melsen B, Bjerregaard J, Bundgaard M. The effect of treatment with functional appliance on a pathologic growth pattern of the condyle. *Am J Orthod* 1986;90:503–512.
15. Huisinga-Fischer CE, Zonneveld FW, Vaandrager JM, Prah-Andersen B. Relationship in hypoplasia between the masticatory muscles and the craniofacial skeleton in hemifacial microsomia, as determined by 3-D CT imaging. *J Craniofac Surg* 2001;12:31–40.
16. Huisinga-Fischer CE, Vaandrager JM, Prah-Andersen B, Van Ginkel FC. Masticatory muscle right-left differences in controls and hemifacial microsomia patients. *J Craniofac Surg* 2004;15:42–46.
17. Takashima M, Kitai N, Murakami S, Furukawa S, Kreiborg S, Takada K. Volume and shape of masticatory muscles in patients with hemifacial microsomia. *Cleft Palate Craniofacial J* 2003;40:6–12.
18. Ueki K, Nakagawa K, Takatsuka S, Shimada M, Marukawa K, Takazakura D, Yamamoto E. Temporomandibular joint morphology and disc position in skeletal Class III patients. *J Craniofac Surg* 2000;28:362–368.
19. Goto TK, Nishida S, Nakayama E, Nakamura Y, Sakai S, Yabuuchi H, Yoshiura K. Correlation of mandibular deviation with temporomandibular joint MR dimensions, MR disk position, and clinical symptoms. *Oral Surg Oral Med Oral Pathol Oral Radiol Endod* 2005;100:743–749.
20. Curtis DA, Nielsen I, Kapila S, Miller AJ. Adaptability of the adult primate craniofacial complex to asymmetrical lateral forces. *Am J Orthod Dentofacial Orthop* 1991;100:266–273.
21. Nakano H, Maki K, Shibasaki Y, Miller AJ. Three-dimensional changes in the condyle during development of an asymmetrical mandible in a rat: a microcomputed tomography study. *Am J Orthod Dentofacial Orthop* 2004;126:410–420.