

Enchondromas of the Hand: A 20-year Experience*

Encondromas da mão: Uma experiência de 20 anos

Claudio Sollaci¹ Gabriel Costa Serrão de Araújo^{1,2} 

¹ Rede Sarah de Hospitais de Reabilitação, Brasília, Distrito Federal, Brazil

² Universidade Federal Fluminense, Niterói, Rio de Janeiro, Brazil

Address for correspondence: Gabriel Costa Serrão de Araújo, Faculdade de Medicina, Universidade Federal Fluminense, Rua Marques de Paraná 303, 2° andar – Niterói – RJ, CEP 24033-900, Brazil (e-mail: gabrieldearaujo@gmail.com).

Rev Bras Ortop 2019;54:714–720.

Abstract

Objective Enchondromas are the commonest tumors of the bones of the hand. Treatment approaches vary. The present article presents the characteristics of the tumors, diagnostic methods, and treatments.

Methods We discuss the approach used in our institution, where we have treated 48 patients with enchondromas of the hand between 1996 and 2016. Our technique of treatment, which has remained the same over 2 decades, comprises the use of curettage, high-speed burr, and autologous bone graft (harvested with a minimally invasive technique, using a Craig biopsy needle).

Results Pain and fractures were the most common symptoms leading the patients to consultation, at frequencies of 33.3% and 31.3%, respectively. A total of 27.1% of the cases were asymptomatic, and their lesions were discovered incidentally. The mean age was 34.4 years (SD = 12.9 years). Tumors were more frequently presented in the ulnar side of the hand, in the fifth ray (41.5%) and in the proximal bones (in the proximal phalanges [43.8%], and in the metacarpal [33.3%]). The size of the tumors ranged from 0.2 cm² to 5.7 cm², with a mean of 1.7 cm² (standard deviation [SD] = 1.0 cm²) and were not associated with fracture ($p = 0.291$). Fracture was also not associated with any of the symptoms, neither with the age of the patients ($p = 0.964$). After the treatment, most patients achieved full range of motion (91.7%), with good integration of the bone graft. Three patients presented deficit in range of motion (6.3%) and the incidence of complications was also 6.3% (3 patients). At the end, after the needed surgical revisions, these three patients also recovered full function. They achieved full bone graft integration, regained full range of motion and returned to work. There was no tumor recurrence case during the follow-up period evaluated. For all cases, no donor site complications occurred.

Conclusion Our method of treatment has consistently provided good outcomes, with only a few minor complications. Therapeutic level of evidence: IV.

Keywords

- enchondroma
- hand
- benign neoplasms
- bone transplantation

Resumo

Objetivo Os encondromas são os tumores mais comuns dos ossos da mão. As abordagens de tratamento variam. O presente artigo apresenta as características dos tumores, métodos diagnósticos e tratamentos.

* Study conducted at Rede Sarah de Hospitais de Reabilitação, Brasília, Distrito Federal, Brazil.

Métodos Discutimos a abordagem da nossa instituição, onde tratamos 48 pacientes com enchondromas da mão, entre 1996 e 2016. Nossa técnica de tratamento, que permanece a mesma ao longo de duas décadas, compreende o uso de curetagem, esmeril de velocidade e enxerto ósseo autólogo (retirado com uma técnica minimamente invasiva, usando uma agulha de Craig).

Resultados A dor e as fraturas foram os sintomas mais comuns, levando os pacientes à consulta, nas frequências de 33,3% e 31,3%, respectivamente. Um total de 27,1% dos casos era assintomático, e suas lesões foram descobertas incidentalmente. A média de idade foi de 34,4 anos (desvio padrão [DP] = 12,9 anos). Os tumores foram mais frequentemente encontrados no lado ulnar da mão, no quinto raio (41,5%), e nos ossos proximais (nas falanges proximais [43,8%] e no metacarpo [33,3%]). O tamanho do tumor variou de 0,2 cm² a 5,7 cm², com média de 1,7 cm² (DP = 1,0 cm²) e não foi associado à fratura ($p = 0,291$). A fratura também não foi associada a nenhum dos sintomas, e nem à idade dos pacientes ($p = 0,964$). Após o tratamento, a maioria dos pacientes alcançou amplitude completa de movimento (91,7%), com boa integração do enxerto ósseo. Três pacientes apresentaram déficit no arco de movimento (6,3%) e a incidência de complicações também foi de 6,3% (3 pacientes). No final, após as revisões cirúrgicas necessárias, esses três pacientes também recuperaram a função completa. Eles tiveram a integração total do enxerto ósseo, recuperaram toda a amplitude de movimento e retornaram ao trabalho. Não houve nenhum caso de recorrência do tumor durante o período de acompanhamento avaliado. Em nenhum dos casos ocorreram complicações no local doador.

Conclusão O nosso método de tratamento forneceu consistentemente bons resultados, com apenas algumas complicações menores. Nível terapêutico de evidência: IV.

Palavras-chave

- enchondroma
- mão
- neoplasias benignas
- transplante ósseo

Introduction

Enchondromas are the most common tumors of the bones of the hand. They are slow-growing cartilaginous lesions that are sometimes associated with swelling, deformity, pain, and fractures. Lesions may also be asymptomatic and are often discovered incidentally on radiography for other reasons (► **Supplementary Fig. S1**).¹

In a review of 110 patients, with 288 bones affected by enchondromas, Takigawa defined the strategies to deal with these lesions.² The tumors can be classified according to bone involvement as monostotic or polyostotic, and according to shape as central, eccentric, associated, polycentric, or giant form.

A variety of treatment approaches have been described. However, two issues are still unsettled: whether surgery can help prevent fractures³, and whether augmentation techniques or filling of the cavity is beneficial after tumor curettage.⁴

During the past 20 years, we have been using a minimally invasive technique to harvest iliac crest bone graft for use at various sites (► **Supplementary Fig. S2**). First described 4 decades ago⁵⁻⁷ this simple technique involves the use of a Craig needle biopsy set⁸ to harvest bone from the iliac crest. The main advantage of this technique is that it provides osteoconductive, osteoinductive, and osteogenic properties,

with low donor site morbidity.^{6,9} We have also routinely applied bone graft harvested by this technique in enchondroma surgery.

In the present study, we perform a retrospective review of the patients treated for enchondromas of the hand at our institute over the past 20 years.

Materials and Methods

The present retrospective review was approved by the ethics committee of the institute and was performed in accordance with the institutional guidelines and the Declaration of Helsinki (1964) and the subsequent revision of the General Assembly, Fortaleza, Brazil (2013). At the time of treatment, all of the patients signed a consent form allowing the institution to use their health records for scientific purposes, and therefore the ethics committee waived the need for obtaining formal consent for the use of data in the present paper.

All of the patients who had undergone surgery for enchondroma of the hand between 1996 and 2016 at our institute were identified by a search of the electronic records of operation notes and pathological diagnosis. Data were collected on demographic characteristics, follow-up period, clinical presentation, postoperative complications, radiographic findings, and histopathological results. Tumor length

and width were measured on anteroposterior radiographs, and tumor size was expressed in square centimeters (length \times width). Descriptive statistics (minimum, maximum, mean, median, standard deviation [SD], and coefficient of variation [CV]) were computed for quantitative variables. Due to the small size of the subgroups, the Mann-Whitney test was used to compare the distributions of the quantitative variables. Qualitative variables were described in terms of distribution of frequencies. Complementary proportions were compared by a binomial test. When possible, associations between factors were evaluated by the chi-Squared test or by the Fisher exact test.

During the last 2 decades, orthopedic surgeons at our institution have followed a standard method for surgery of hand enchondroma. Briefly, the patient is placed in the dorsal decubitus position, with a tourniquet wrapped around the arm. Surgery is performed under brachial plexus block, supplemented with general anesthesia. A lateral approach is used for phalangeal lesions and a dorsal approach for lesions of the metacarpal bones. Protecting the tendons and neurovascular bundles, a bone window is made with a drill. Then, using an angled curette, all cartilaginous tissue is removed from inside the bone. While the pathologist analyzes the curetted tissue by cryosectioning, the cavity is cleaned with 0.9% NaCl saline solution and a high-speed burr (**► Supplementary Figs. S3 and S4**). After the diagnosis of enchondroma is confirmed, the ipsilateral iliac crest, which has been previously prepared for surgery, is accessed via a 1-cm incision placed 5 cm posterior to the anterosuperior iliac spine. A Craig trephine is used to remove some cylinders of cancellous bone from the iliac crest (**► Fig. 1**). To prevent contamination of the donor site with tumor cells, all instruments used for bone graft removal are prepared on an auxiliary table, and the gloves of all staff are changed before the procedure. Local anesthesia is used for the graft removal procedure. The small wound is closed with a single skin suture. The cancellous bone graft cylinders are used to fill the cavity at the site of the lesion (**► Fig. 2**). The tourniquet is

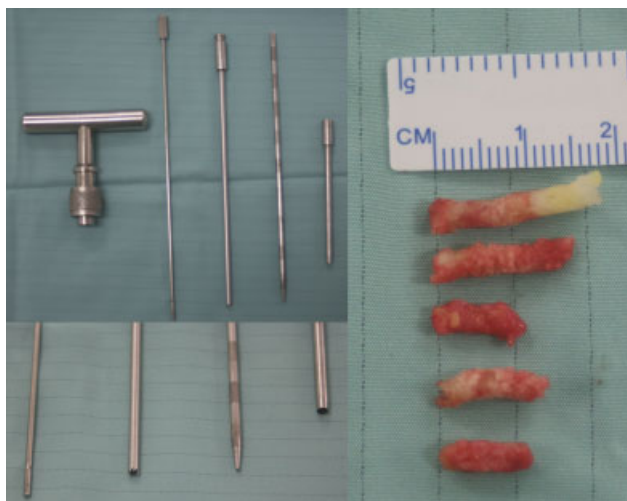

Fig. 1 The Craig needle set used to harvest bone graft, and the harvested bone cylinders.

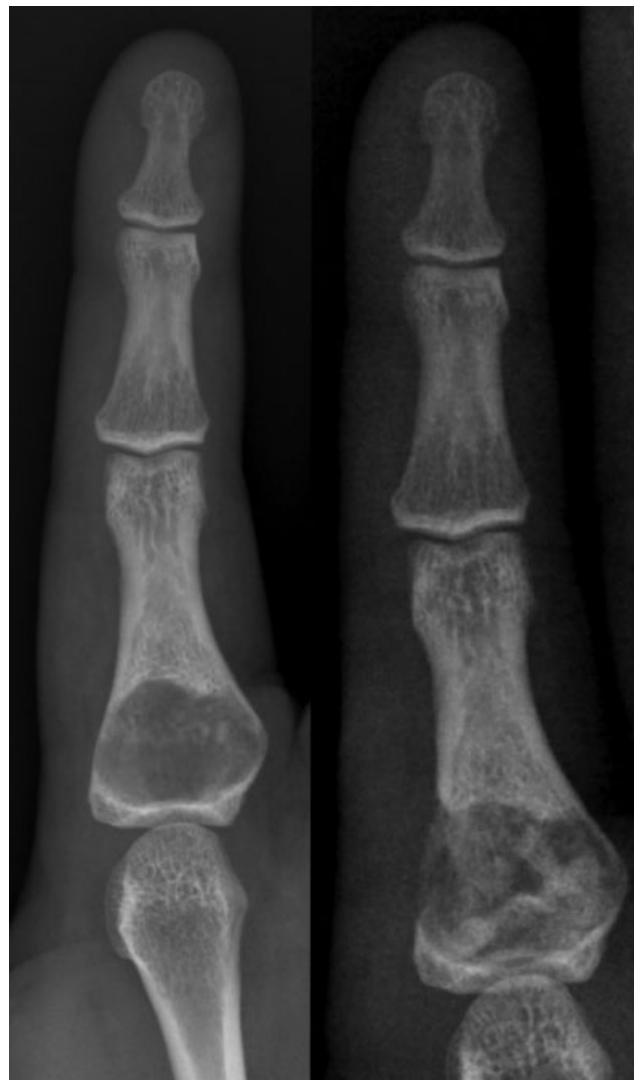


Fig. 2 Pre- and postoperative roentgenograms of the index finger. The picture on the left shows a tumor (enchondroma) in the proximal phalanx of the index finger, and the picture on the right shows the appearance after tumor resection and cavity filling with cylinders of cancellous bone graft.

removed for hemostatic revision, and the wound is closed (**► Supplementary Fig. S5**).

This study provides Level IV evidence both for therapeutics and prognostics issues.

Results

A total of 51 patients were identified from the database. Two patients were excluded because of incomplete follow-up data. One other patient refused harvest of iliac crest bone, so the cancellous bone graft was obtained from the distal radius of the same limb. These three patients were excluded from the study. Thus, the present review is based on a sample of 48 patients (38 women and 10 men).

By this sample, we can estimate that, in the population from the present study, the enchondromas are significantly more frequent in women (79.2% of cases occurred in women and 21.8% in men; p -value of the binomial test < 0.001).

► **Tables 1 and 2** show the main characteristics of the cases of enchondromas of this sample. The ages of the patients ranged from 10 years to 70 years old, with the mean age being 34.4 years (SD = 12.9 years, CV = 0.38, moderate variability) and the women were significantly older than the men, in average 12.6 years older (p-value of the Mann-Whitney test = 0.012).

Table 1 Main Statistics of Quantitative Variables Distributions

Statistic	Age (years old)	Follow-up period (months)	Size of the tumor (cm ²)
Minimum	10.0	0.3	0.2
Maximum	70.0	132.0	5.7
Mean	34.4	20.4	1.7
Median	34.5	12.5	1.6
Standard Deviation	12.9	24.7	1.0
Coefficient of Variation	0.38	1.21	0.59

Table 2 Distribution of Frequencies to Qualitative Variables

Qualitative Variable	Frequency	
Symptoms		
Pain	16	33.3%
Fracture	15	31.3%
Swelling	6	12.5%
Deformity	1	2.1%
Multiple enchondromatosis	1	2.1%
None, discovered incidentally	13	27.1%
Ray of Localization		
First ray	1	2.1%
Second ray	6	12.5%
Third ray	8	16.7%
Fourth ray	13	27.1%
Fifth ray	20	41.7%
Bone		
Distal Phalanx	3	6.3%
Middle Phalanx	8	16.7%
Proximal Phalanx	21	43.8%
Metacarpal	16	33.3%
Arc of motion post surgery		
Whole (full)	44	91.7%
Deficit 30° PIP	1	2.1%
Deficit 30° MCP	1	2.1%
Deficit 90° MCP	1	2.1%
Post-surgery complications		
Fracture	1	2.1%
Surgery's revision	2	4.2%

Abbreviations: PIP, proximal interphalangeal joint; MCP, metacarpophalangeal joint.

Reasons for the initial consultation included pain (16 patients, 33.3%), fracture (15 patients, 31.3%), swelling (6 patients, 12.5%), and deformity (1 patient, 2.1%). Four patients (8.33%) presented both pain and swelling symptoms. One patient (2.1%) had multiple enchondromatosis. In 13 patients (27.1%), the enchondromas were asymptomatic and were incidentally discovered on radiographies made for other reasons. Fracture was not associated with any of the symptoms because it did not occur in any of the symptomatic cases, neither was it associated with the age of the patient. The mean age of the group without fracture was 34.2 years old (SD = 14.0 years, median = 34 years), and the mean age of the group with fracture was 34.2 years old (SD = 10.4 years, median = 36 years); the p-value of the Mann-Whitney test comparing the distributions of the 2 subgroups was 0.964.

Tumors were more frequently present in the ulnar side of the hand, in the fifth ray (41.5%) and in the proximal bones (in the proximal phalanges [43.8%] and in metacarpal [33.3%]). The distribution of occurrences in each bone of the hand is shown in ► **Fig. 3**.

The size of the tumors ranged from 0.2 cm² to 5.7 cm², with a mean size of 1.7 cm² (SD = 1.0 cm²), and there was no significant difference between the distributions of the sizes of the tumors from the female and male (p-value of the Mann-Whitney test = 0.069). Fracture was not associated with the size of the tumor. The mean size of the tumor

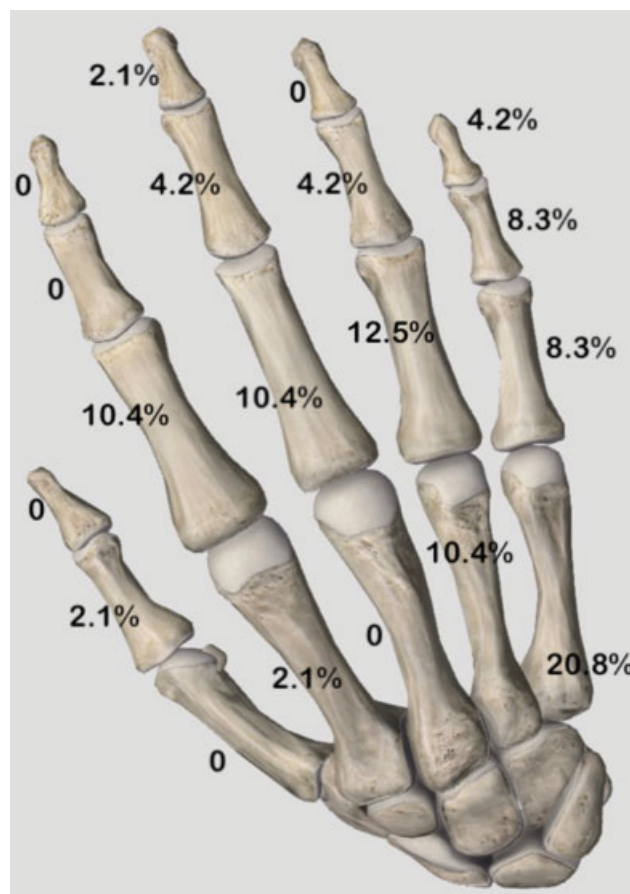


Fig. 3 Distribution of frequencies of enchondromas in each bone of the hand.

of the group without fracture was 1.8 cm^2 ($\text{SD}=1.2\text{ cm}^2$, median = 1.7 cm^2) and the mean size of the tumor of the group with fracture was 1.5 cm^2 ($\text{SD}=0.8\text{ cm}^2$, median = 1.3 cm^2); the p-value of the Mann-Whitney test comparing the distributions of the 2 subgroups was 0.291.

The mean follow-up ranged from 0.3 to 132 months, with a mean of 20.4 months ($\text{SD}=24.7$ months, $\text{CV}=1.21$, high variability).

After the treatment, most patients achieved full range of motion (91.7%), with good integration of the bone graft. Three patients presented deficit in range of motion (6.3%). One of these patients, a 56-year-old woman with a $0.9\text{ cm} \times 1.2\text{ cm}$ tumor in the 5th metacarpal, had a 30° deficit of flexion in the metacarpophalangeal joint arc of motion. She had been operated after her fracture had healed. The other patient, a 47-year-old woman who was treated for a 0.37 cm^2 tumor in the middle phalanx of the ring finger, had a residual 30° deficit of extension in the proximal interphalangeal joint. Her initial complaint was pain, without history of trauma or fracture. The 3rd patient, a 42-year-old man, presented a 90° deficit in the metacarpophalangeal joint arc of motion.

The incidence of complications was 6.3% (3 patients), and only minor complications were found: 2 revision surgeries and 1 pathological fracture case. The incidence of revision surgery is significantly higher in the male subgroup, 20.0% versus 0.0% in the female subgroup; p-value of the Fisher exact test = 0.040. Case 1 of complication was a 10-year-old boy who had a tumor ($0.77\text{ cm} \times 2.77\text{ cm}$) in the proximal phalanx of the middle finger. He needed review surgery because of tumor recurrence. The technique used was the same of the previous surgery. Case 2 of complication was a 42-year-old man who had a tumor ($1.3\text{ cm} \times 1.5\text{ cm}$) in the distal second metacarpal bone. He presented with a fracture and was operated on after the fracture had healed. This man needed a capsulotomy to recover the 90° deficit in the metacarpophalangeal joint arc of motion. Case 3 of complication was a 36-year-old woman who had a $0.92\text{ cm} \times 1.46\text{ cm}$ tumor in the proximal phalanx of the ring finger, and presented with a fracture after a fall. Surgery for removal of the tumor was performed after complete healing of the fracture. However, she had another fall within one month of surgery and sustained another pathological fracture. The fracture healed with conservative management. She regained full range of motion, and there was no tumor recurrence.

All of the other patients recovered full function and returned to work. They achieved full bone graft integration and regained full range of motion. There were no cases of tumor recurrence during the follow-up period evaluated.

Discussion

Our experience with hand enchondromas is not very extensive, but in the present review we describe a treatment method that we have used for two decades that has provided good outcomes, with results comparable to that of others.

In the present case series enchondromas were more common in the proximal bones and on the ulnar side of the hand. This finding is consistent with a previous report.¹⁰

A variety of treatment approaches have been described for enchondroma. Unfortunately most papers have been case series, with low-level evidence. Wulle used simple curettage, without cavity fill, to treat 10 cases of enchondromas, and reported that the stability achieved was almost the same as that with cavity fill with plaster of Paris (calcium phosphate), the standard treatment at that time.¹¹ Shortly after, another series of 28 patients¹² was reported; the authors used simple curettage, and reported that new bone formation in the cavity was satisfactory enough to achieve the main treatment objectives, i.e., prevention of fractures and recurrences. Another group¹³ used intralesional augmentation with K-wires and polymethylmethacrylate in 13 patients and proposed that such an approach increased stability, guaranteeing the conditions necessary for early mobilization of the operated segment.

In a case series of 35 hand enchondromas,¹⁴ 29 were operated, with 26 patients having the cavities filled with autologous iliac bone graft harvested with a minimally invasive technique. The authors do not describe the harvest technique, but the paper shows a picture with a unique bone block of $\sim 1\text{ cm}^2$.

In one study, 16 patients were followed up for > 2 years after surgery for hand enchondromas;¹⁵ 8 patients did not receive any cavity filling, while 8 received iliac crest bone graft, harvested using the conventional technique with a 5-cm skin incision. The study concluded that bone grafting was necessary only if the cortical bone was thin, with high risk for fracture, or if the lesion was located close to an articular surface.

In a case series of 102 enchondromas operated using different techniques,¹⁰ the authors found that autologous graft did not influence the healing process; it did not reduce healing time, recurrence, or complications, or increase range of motion. They suggested that surgeries be performed with allograft or without any cavity fill to avoid the problem of donor site morbidity. Another study compared 11 patients treated with bone substitute (tricalcium phosphate granules) with 13 patients treated with iliac crest bone graft.¹⁶ The authors did not find any differences between the groups on functional evaluations. They observed that bone substitutes took twice as long to achieve bone integration; however, they related that in the last 5 years, they had tended to favor the use of bone substitutes, since it avoided the problem of donor site morbidity, reduced local anesthetic use and surgical time, and permitted outpatient treatment.

A biomechanical study performed on metacarpal bones of fresh cadavers to evaluate different treatments for enchondromas¹⁷ showed that simple curettage makes the bone 70% weaker than intact bone, increasing its susceptibility to fractures. However, tricalcium phosphate bone cementation could raise the system rigidity to a level similar to that of intact bone.

In a recent case series, 82 patients were treated with curettage, chemical cauterization with phenol, and tumor

cavity filling with chips of coralline hydroxyapatite.¹⁸ After 5 years of follow-up, the authors reported satisfactory bone healing and function, with no infections, pathological fractures, or recurrences.

In a systematic review of 505 cases of hand enchondromas¹⁹, after stratification for treatment types, complications were more frequent (3.5%) in the cases in which autologous bone graft was used, with infection being the most common complication. In the cases without cavity filling, the only complication registered was persistent pain (0.07%). There were no complications in patients treated with bioactive or osteoconductive synthetic materials. Patients treated with bone cement cavity filling only presented nonunion as a complication (2%).

Bone graft substitute is an alternative to autologous bone graft. However the results in the literature are conflicting. The most recent study²⁰ found that after cavity filling with injectable bone graft (calcium sulfate and hydroxyapatite), seven of 12 patients treated for hand enchondromas presented with postoperative redness and swelling. The authors attributed this to the thin soft tissue envelop of the fingers.

According to current recommendations for management of hand enchondromas^{1,4} symptomatic and large tumors should be considered for elective surgery. However, in our series, large tumors were not necessarily symptomatic. There was no significant difference in size between asymptomatic and symptomatic lesions: 1.69 cm^2 ($\text{SD} = 0.9 \text{ cm}^2$) versus 1.71 cm^2 ($\text{SD} = 1.07 \text{ cm}^2$); $p = 0.952$.

It has been suggested that a larger tumor size is related to a higher risk of fracture³, but this was not confirmed in our series. The mean tumor size was 1.79 cm^2 ($\text{SD} = 1.09 \text{ cm}^2$) in lesions without fracture versus 1.49 cm^2 ($\text{SD} = 0.81 \text{ cm}^2$) in lesions with fracture ($p = 0.787$), indicating that tumor size was not a significant risk factor for fracture.

An algorithm proposed for hand enchondroma treatment recommends only regular follow-up with radiography for small asymptomatic lesions, because the risk of fracture is low in these lesions.⁴ Curettage without augmentation techniques is recommended for expanding or symptomatic lesions. The authors consider that there is enough evidence to show that augmentation techniques are unnecessary to prevent fractures. The algorithm also does not recommend adjuvant techniques such as high-speed burring. However, in our case series, the use of augmentation and adjuvant techniques was not associated with donor or surgical site morbidity.

Other authors have also advocated only regular monitoring for incidentally found lesions¹, with surgical interventions reserved for symptomatic patients. However, they did not systematically study the benefits of augmentation or adjuvant techniques. Their opinion is based on the fact that they obtained good results without the use of these measures. Importantly, their article highlighted the difficulty in differentiating between low-grade chondrosarcomas and enchondromas. Although chondrosarcomas in the digits do not metastasize, they should be treated respecting the principles of tumor surgery. In this scenario, we consider that aggressive curettage and high-speed burring are

important to prevent recurrence. These methods do not markedly increase surgical time or treatment cost. Unless evidence from randomized controlled trials refute these benefits, there is no justification for abandoning these techniques.

When treating hand enchondromas, it is necessary to consider the benefits and risks of harvesting bone graft. About 20% of the patients experience complications such as persistent donor site pain, nerve injury, hematoma formation, infection, incisional hernia, fracture, and gait derangement.²¹ However, the minimally invasive technique we use was not associated with any donor site complication, and we therefore are in favor of using bone graft for cavity filling after the removal of the tumor.

We have also mentioned the use of angled small curettes. If this instrument is not available, we recommend the use of a modified 18-G needle as described by Chen et al.²²

Conclusion

To summarize, we have described a method that we have successfully used for 20 years for the treatment of enchondromas in the hand. It can be performed with commonly available materials, and provides consistently good outcomes with an extremely low rate of complications (► **Supplementary Figs. S6 and S7**).

Conflicts of Interests

The authors have no conflicts of interests to declare.

References

- 1 Lubahn JD, Bachoura A. Enchondroma of the hand: evaluation and management. *J Am Acad Orthop Surg* 2016;24(09):625–633
- 2 Takigawa K. Chondroma of the bones of the hand. A review of 110 cases. *J Bone Joint Surg Am* 1971;53(08):1591–1600
- 3 Riester S, Ramaesch R, Wenger D, van Wijnen A, Kakar S. Predicting fracture risk for enchondroma of the hand. *Hand (N Y)* 2016; 11(02):206–210
- 4 Tang C, Chan M, Fok M, Fung B. Current management of hand enchondroma: a review. *Hand Surg* 2015;20(01):191–195
- 5 Braun RM. Trephine techniques for small bone grafts. *Hand* 1974; 6(01):103–105
- 6 Caddy CM, Reid CD. An atraumatic technique for harvesting cancellous bone for secondary alveolar bone grafting in cleft palate. *Br J Plast Surg* 1985;38(04):540–543
- 7 Gartsman GM, Lane JM. A simple method of obtaining bone graft by bone biopsy trocar. *J Hand Surg Am* 1981;6(06):627–628
- 8 Craig FS. Vertebral-body biopsy. *J Bone Joint Surg Am* 1956;38-A (01):93–102
- 9 Kinsel RP, Turbow MM. The use of a trephine biopsy needle to obtain autogenous corticocancellous bone from the iliac crest: technical note. *Int J Oral Maxillofac Implants* 2004;19(03): 438–442
- 10 Sassoon AA, Fitz-Gibbon PD, Harmsen WS, Moran SL. Enchondromas of the hand: factors affecting recurrence, healing, motion, and malignant transformation. *J Hand Surg Am* 2012;37(06): 1229–1234
- 11 Wulle C. On the treatment of enchondroma. *J Hand Surg [Br]* 1990;15(03):320–330
- 12 Hasselgren G, Forssblad P, Törnqvist A. Bone grafting unnecessary in the treatment of enchondromas in the hand. *J Hand Surg Am* 1991;16(01):139–142

- 13 Bickels J, Wittig JC, Kollender Y, et al. Enchondromas of the hand: treatment with curettage and cemented internal fixation. *J Hand Surg Am* 2002;27(05):870–875
- 14 Figl M, Leixnering M. Retrospective review of outcome after surgical treatment of enchondromas in the hand. *Arch Orthop Trauma Surg* 2009;129(06):729–734
- 15 Schaller P, Baer W. Operative treatment of enchondromas of the hand: is cancellous bone grafting necessary? *Scand J Plast Reconstr Surg Hand Surg* 2009;43(05):279–285
- 16 Hung YW, Ko WS, Liu WH, et al. Local review of treatment of hand enchondroma (artificial bone substitute versus autologous bone graft) in a tertiary referral centre: 13 years' experience. *Hong Kong Med J* 2015;21(03):217–223
- 17 Pianta TJ, Baldwin PS, Obopilwe E, Mazzocca AD, Rodner CM, Silverstein EA. A biomechanical analysis of treatment options for enchondromas of the hand. *Hand (N Y)* 2013;8(01):86–91
- 18 Georgiannos D, Lampridis V, Bisbinas I. Phenolization and coralline hydroxyapatite grafting following meticulous curettage for the treatment of enchondroma of the hand. A case series of 82 patients with 5-year follow-up. *Hand (N Y)* 2015;10(01):111–115
- 19 Bachoura A, Rice IS, Lubahn AR, Lubahn JD. The surgical management of hand enchondroma without postcurettage void augmentation: authors' experience and a systematic review. *Hand (N Y)* 2015;10(03):461–471
- 20 Liadaki E, Kraemer R, Mailaender P, Stang F. The Use of Bone Graft Substitute in Hand Surgery: A Prospective Observational Study. *Medicine (Baltimore)* 2016;95(24):e3631
- 21 Myeroff C, Archdeacon M. Autogenous bone graft: donor sites and techniques. *J Bone Joint Surg Am* 2011;93(23):2227–2236
- 22 Chen WA, Gluck GS, Li Z. Needle Curette Technique for Hand Surgery. *Tech Hand Up Extrem Surg* 2015;19(03):108–109