



# TAVI Using a Self-Expandable Device for Aortic Regurgitation Following LVAD Implantation

Harun Sarwari<sup>1</sup> Andreas Schaefer<sup>1</sup> Markus J. Barten<sup>1</sup> Lenard Conradi<sup>1</sup>

<sup>1</sup>Department of Cardiovascular Surgery, University Heart Center Hamburg, Hamburg, Germany

Address for correspondence Andreas Schaefer, MD, MHBA, Department of Cardiovascular Surgery, University Heart Center Hamburg, Martinistraße 52, Hamburg 20253, Germany (e-mail: and.schaefer@uke.de).

Thorac Cardiovasc Surg Rep 2019;8:e33–e36.

## Abstract

### Keywords

- ▶ left ventricular assist device
- ▶ aortic regurgitation
- ▶ transcatheter aortic valve implantation
- ▶ heart failure

**Background** In patients treated by left ventricular assist device (LVAD), aortic regurgitation (AR) may occur. Secondary surgery to correct AR is considered high risk.

**Case Description** We report a case of severe AR following LVAD implantation in a patient who was subsequently treated by transcatheter aortic valve implantation (TAVI) using the latest generation self-expandable transcatheter heart valve (THV) (Boston Scientific Acurate neo, size M [Boston Scientific, Marlborough, Massachusetts, United States]). TAVI followed modified procedural protocol and sizing algorithm. THV implantation without prior balloon aortic valvuloplasty resulted in an adequate valve function without leakage.

**Conclusion** This THV may be particularly well suited for TAVI subsequent to LVAD implantation if modified sizing and deployment considerations are appreciated.

## Introduction

Severe aortic regurgitation (AR) is a well-known complication following left ventricular assist device (LVAD) implantation.<sup>1,2</sup> In these patients, severe AR leads to recirculation of regurgitant blood generating low antegrade left ventricular output which may result in impaired hemodynamics. Treatment of these patients by secondary open heart surgery is considered a high-risk procedure.

We herein describe a case of severe AR in a native aortic valve following LVAD implantation treated by transfemoral transcatheter aortic valve implantation (TAVI) using the latest generation self-expandable Boston Scientific Acurate neo transcatheter heart valve (THV).

## Case Report

A 61-year-old female patient (168 cm, 54 kg, BMI 19.1 kg/m<sup>2</sup>) was admitted 8 months following LVAD implantation (Medtronic, Ventricular Assist System HVAD, Miami Lakes, Florida, United States) in new-onset acute heart failure (New York Heart Association [NYHA] III-IV). Comorbidities included chronic renal failure (creatinine 2.5 mg/dL), recurrent hem-

orrhagic gastritis, multiple sclerosis, and condition after malignant melanoma resulting in an Society of Thoracic Surgery- Predicted Risk of Mortality (STS PROM) score of 8.74% and logistic EuroSCORE I of 16.5%. Transthoracic echocardiography (TTE) and transesophageal echocardiography (TEE) revealed new-onset severe AR with volume overload left ventricular dilatation. Morphologically, the aortic valve was tricuspid and free of any calcification (▶Fig. 1A,B). AR was eccentric caused by retraction of the noncoronary cusp. Due to her poor general status (cardiac cachexia, use of wheeled walker) and thus increased perioperative risk for open redo surgery, the local interdisciplinary heart team indicated off-label TAVI.

TAVI procedure was performed according to local standard protocol. Preprocedural echocardiogram-gated multislice computed-tomography (MSCT) demonstrated an effective perimeter-derived annulus diameter of 22.4 mm, annulus perimeter of 70.5 mm, and area of 390.3 mm<sup>2</sup> (▶Fig. 1). Coronary distances from the aortic plane were 14.9 mm (right) and 11.4 mm (left), sinus diameters were 26.2 mm/27.9 mm/27.8 mm for non-/left-/right-coronary sinuses (▶Fig. 1). Subsequently, an Acurate neo, size M THV (Boston Scientific) was chosen to provide sufficient oversizing. The intervention was

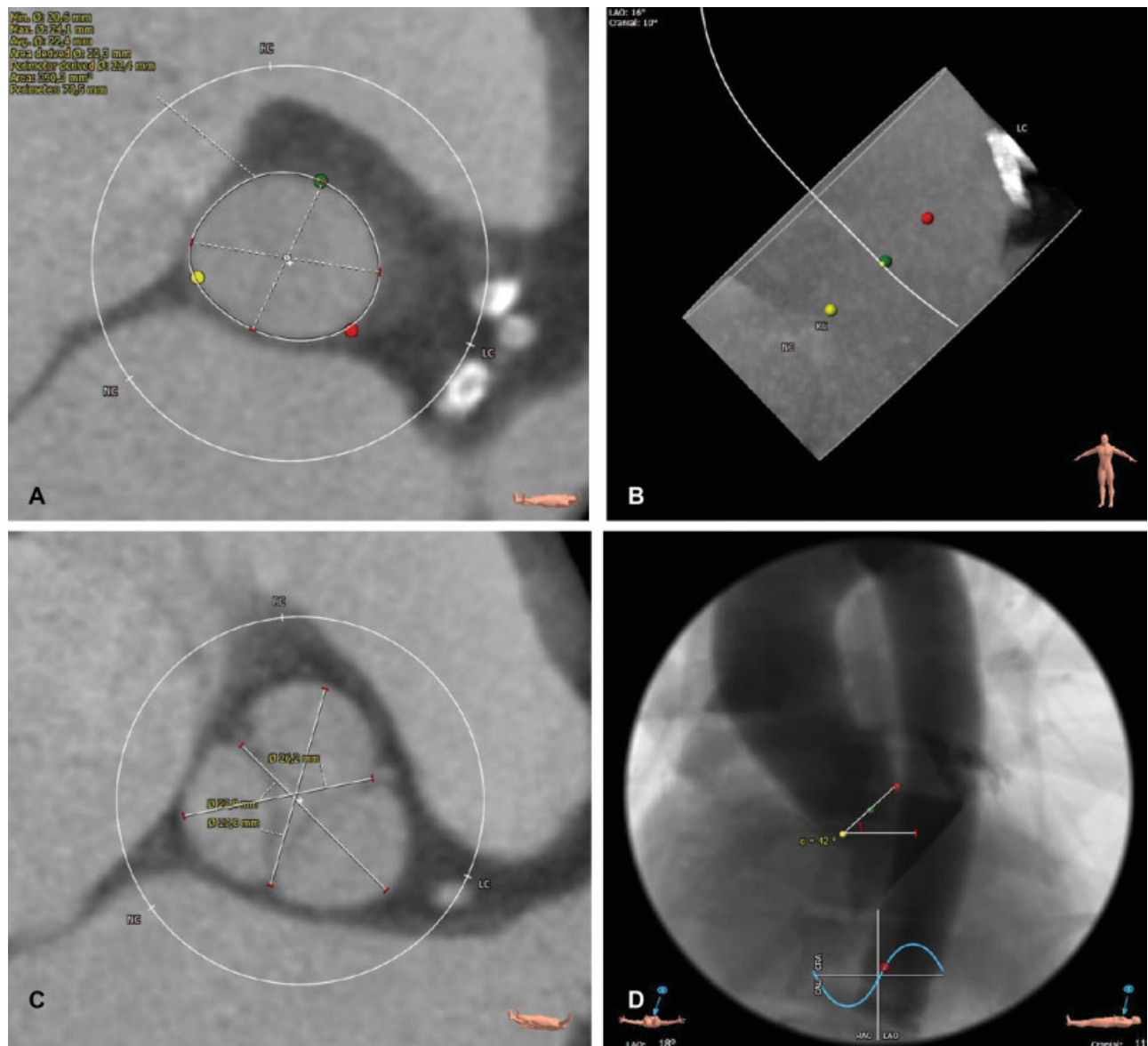
received  
June 28, 2019  
accepted  
August 12, 2019

DOI <https://doi.org/10.1055/s-0039-1698412>.  
ISSN 2194-7635.

© 2019 Georg Thieme Verlag KG  
Stuttgart · New York

License terms

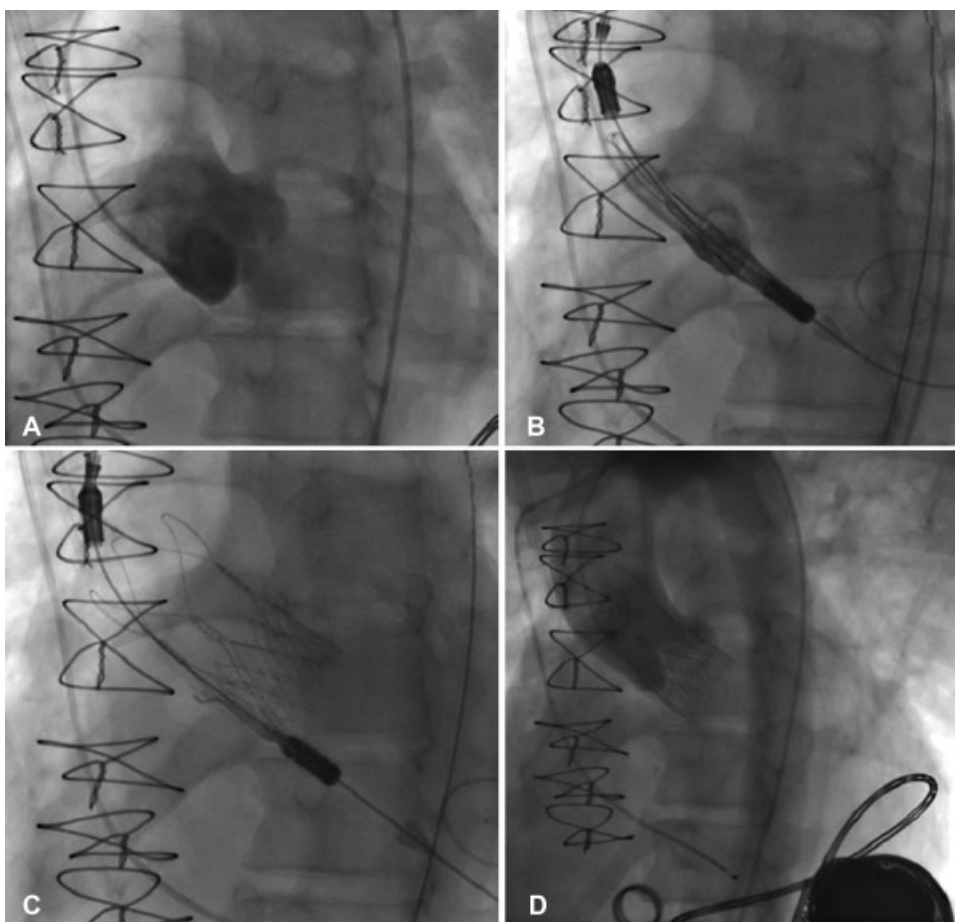




**Fig. 1** Preinterventional multislice computed tomography. Preprocedural planning of transcatheter aortic valve implantation with echocardiogram-gated multislice computed tomography in severe aortic regurgitation of a native aortic valve in a patient with left ventricular assist device: diameter, perimeter, and area of the annulus (A), depiction of nonexistent calcifications in hockey-puck view (B), sinus diameters (C), and aortic arch with angle of aortic root for subsequent deployment of transcatheter heart valve (D).

then conducted via right-sided percutaneous transfemoral access using standard preclosure (ProGlide, Abbott Vascular, Santa Clara, California, United States). In view of the risk of entrapment of a straight guidewire in the LVAD inflow, a wire enforced pigtail catheter was used for retrograde valve passage. After crossing, invasive assessment of baseline hemodynamics was performed (heart rate [HR] 80 bpm, aorta [AO] 74/58/66 mm Hg, left ventricle [LV] 74/20 mm Hg, pulmonary artery [PA] 48/20/32 mm Hg, right atrium [RA] 21/25/21 mm Hg, cardiac output [CO] 4.9/4.8/5.1 L/min). Then, a stiff pre-shaped guidewire (Safari 275 cm, Boston Scientific Corp., Marlborough, Massachusetts, United States) was inserted and placed carefully in a para-apical position immediately adjacent to the LVAD inflow cannula. By the guidance of TEE and fluoroscopy and using a single diagnostic noncoronary cusp pigtail catheter, the THV was inserted via an 18Fr Boston

iSleeve sheath and advanced to an intra-annular position with the annular marker band slightly above the native aortic valve annulus (►Fig. 2). Immediately prior to the initiation of deployment, LVAD output was reduced from 4.6 L/min, 2,600 RPM, 4.0 Watt to 2.3 L/min, 1,800 RPM, 1.6 to 1.8 Watt to achieve a stable intra-annular THV position. After the development of the aortic stabilization arches and the upper stent crown, correct implant height was angiographically confirmed. The second step of deployment was performed in a brief phase of rapid ventricular pacing. Particular care was taken during delivery system retrieval with centering of the nose cone by retraction of the Safari guidewire. After delivery system retrieval previously reduced LVAD output parameters were changed back to the original LVAD adjustment. A ventricular pigtail catheter was inserted for invasive assessment of hemodynamics. An improvement of CO was observed (HR 85



**Fig. 2** Intraprocedural fluoroscopy images. Fluoroscopy of transcatheter aortic valve implantation in severe aortic regurgitation of a native aortic valve in a patient with left ventricular assist device: root shot with depiction of severe aortic regurgitation (A), placement of a self-expandable transcatheter heart valve with alignment of radiopaque markers slightly above the height of the aortic annulus (B), transcatheter heart valve after final deployment (C) and final root shot with no residual aortic regurgitation, and left ventricular assist device at the left ventricular apex (D).

bpm, AO 74/61/66 mm Hg, LV 74/23 mm Hg, PA 44/28/35 mm Hg, RA 25/29/23 mm Hg, CO 5.1/5.0/5.1 L/min). Final angiography demonstrated adequate THV stent expansion (► **Fig. 2**), complete absence of paravalvular leakage (PVL), and a transprosthetic gradient of peak/mean 4/1 mm Hg. Throughout the procedure, completely stable hemodynamics were noted with low doses of catecholamines.

Following the procedure, the patient was transferred to the intensive care unit for 24 hours. During the further postprocedural course, the patient recovered rapidly with early mobilization. TTE prior to discharge documented an excellent THV position without any PVL.

Regarding Valve Academic Research Consortium (VARC-2) adjudicated clinical end points one complication was observed: the patient was readmitted 2 weeks after THV implantation for the known recurrent hemorrhagic gastritis. At latest follow-up, 100 days after the procedure, TTE showed an adequate THV function without any leakage.

## Discussion

Secondary occurrence of relevant AR after LVAD implantation is a well-known complication.<sup>1,2</sup> A progress in AR severity

often increases symptoms of heart failure and is related to poor prognosis.<sup>3</sup> These conditions represent a serious medical challenge and require an exceptional therapeutic concept. A primary surgical regime in these patients characterized with end stage heart failure, previous cardiac surgery, and frequently high comorbidity burden should be considered critically. In these cases, TAVI is an alternative less invasive option. However, in this alternative setting some challenges have to be considered. THV has been developed for the treatment of aortic stenosis. As a consequence, anchoring of THV in patients with pure AR in a native aortic valve without annular or leaflet calcifications represents an off-label indication and requires a modified sizing and implant algorithm.

To date, anecdotal reports of treatment with THV in patients with pure AR following LVAD implantation exist.<sup>4</sup> In most of these cases, CoreValve THVs were used (Medtronic, Inc, Minneapolis, Minnesota, United States) and TAVI was demonstrated to be a reasonable option. However, from larger series on use of this particular self-expandable THV in pure, noncalcified AR it is known that the implant procedure is not trivial with relevant rates of sequential valve implantation for malpositioning of the first THV as well as an incidence of residual AR  $\geq$  grade II in 21% of the patients.<sup>5,6</sup>

This is the first report of the latest generation self-expandable Acurate neoTHV for the pure noncalcified AR in the presence of an LVAD. This case demonstrates technical feasibility and safety and adds to the existing literature on this type of THV for the treatment of AR (15). In contrast to the CoreValve THV, the x-shaped design of this THV stent allows for sufficient anchoring even in the absence of calcification by aligning the stent waist with the aortic annulus. However, in contrast to use in aortic stenosis, a modified sizing algorithm has to be appreciated with a more pronounced oversizing to prevent THV migration. From experience with this type of THV in AR patients in general, the maximum effective annulus diameter should not exceed 24.5 mm and eccentricity of the annulus should also be carefully assessed before indicating such a procedure (own unpublished data). An aortic annulus above 24.5 mm most likely does not offer the possibility of adequate oversizing in AR with this particular THV with consecutive risk of device migration. Due to the low number of cases performed at our or other centers, these sizing recommendation have to rely on clinical experience rather than complete datasets. Also, since the use of this type of THV for AR remains off-label use at present, no general conclusions should be drawn from the few anecdotal reports or small series published to date. In other reports of valve size selection a tendency to over-size  $9 \pm 4\%$  was chosen compared with nominal diameters of 23, 25, and 27 mm for the sizes S, M, and L of this particular THV.<sup>7</sup> Furthermore, a slightly higher initial THV position seems advisable due to the lower extent of counterforce in a non-calcified landing zone. To perform the second deployment step in a brief phase of rapid ventricular pacing also seems prudent to stabilize the aortic root and to promote a controlled THV release from the delivery catheter. Finally, reduction of LVAD flow to a minimum immediately prior to THV deployment can be advised to reduce suction toward the left ventricular outflow tract.

## Conclusion

In selected cases, TAVI using this latest generation self-expandable THV system for correction of severe AR following LVAD implantation is technically feasible and represents an alternative less invasive treatment option. Careful MSCT assessment of annular dimensions as well as modified sizing and implantation strategies is the key to success.

### Conflict of Interest

L.C. reports other from Boston Scientific, outside the submitted work. All the other authors report no conflict of interest.

## References

- 1 Cowger J, Pagani FD, Haft JW, Romano MA, Aaronson KD, Kolia TJ. The development of aortic insufficiency in left ventricular assist device-supported patients. *Circ Heart Fail* 2010;3(06):668–674
- 2 Pak SW, Uriel N, Takayama H, et al. Prevalence of de novo aortic insufficiency during long-term support with left ventricular assist devices. *J Heart Lung Transplant* 2010;29(10):1172–1176
- 3 Toda K, Fujita T, Domae K, Shimahara Y, Kobayashi J, Nakatani T. Late aortic insufficiency related to poor prognosis during left ventricular assist device support. *Ann Thorac Surg* 2011;92(03):929–934
- 4 van der Werf HW, Schurer RA, Vonck TE, et al. Emergency transcatheter aortic valve implantation in patients with severe aortic regurgitation and a left ventricle assist device: a case report and systematic review. *Eur Heart J Acute Cardiovasc Care* 2017;6(08):719–727
- 5 Spina R, Anthony C, Muller DW, Roy D. Transcatheter aortic valve replacement for native aortic valve regurgitation. *Interv Cardiol (Lond)* 2015;10(01):49–54
- 6 Jiang J, Liu X, He Y, et al. Transcatheter aortic valve replacement for pure native aortic valve regurgitation: a systematic review. *Cardiology* 2018;141(03):132–140
- 7 Toggweiler S, Cerillo AG, Kim WK, et al. Transfemoral implantation of the Acurate neo for the treatment of aortic regurgitation. *J Invasive Cardiol* 2018;30(09):329–333