



Clinical Outcome of Single-Stage Decompression and Posterior Stabilization in Thoracolumbar Spinal Tuberculosis

Susanta Kumar Patro¹ Biswaranjan Nayak² Balappa Holeppagol Krishnamurthy³ Arun Kumar⁴
Debabrata Biswal⁵ Prafulla Kumar Sahoo⁵

¹Department of Neurosurgery, Ispat General Hospital, Rourkela, Odisha, India

²Department of Neurosurgery, AMRI Hospital, Bhubaneswar, Odisha, India

³Department of Neurosurgery, Sri Balaji Institute of Neuroscience and Trauma, Vidyanagar, Hubli, Karnataka, India

⁴Department of Neurosurgery, Fortis Hospital, Shalimar Bagh, Delhi, India

⁵Department of Neurosurgery, Apollo Hospital, Bhubaneswar, Odisha

Address for correspondence Biswaranjan Nayak, D. Orth, MS, DNB, Department of Neurosurgery, AMRI Hospital, Bhubaneswar 751030, Odisha, India (e-mail: dr.bnayak@gmail.com).

Indian J Neurosurg 2021;10:183–189.

Abstract

Background Thoracolumbar spine constitutes the most common site for spinal tuberculosis. Though the treatment of spinal tuberculosis is antitubercular drugs initially, the patient with neurologic weakness warrants definitive surgical procedure of decompression and stabilization. Even though many investigators have reported favorable results with anterior decompression and stabilization surgery, due to the increased morbidity and complications, the posterior-only approach with decompression and stabilization has evolved as the operation of choice in recent time.

Methods All patients aged between 18 and 70 years with clinically and radiologically proven symptomatic thoracolumbar spinal tuberculosis who failed with conservative treatment for 4 weeks or developed neurologic weakness between the treatments are included in this study. All patients were offered decompression and posterior stabilization with transpedicular screws and rods after explaining the above procedure. Clinical outcome was measured by modified Frankel grading; AIS (American Spinal Injury Association impairment score) grade impairment score; and pain assessment done with visual analog scale (VAS) pre- and postoperatively and at 3, 6, and 9 months of interval.

Results The postoperative pain relief, neurologic improvement as per modified Frankel grade, AIS grade, and improvement in erythrocyte sedimentation rate and C-reactive protein were significant as compared with the preoperative status. The surgical interventions thus prove to have adequate relief to the patient and arresting the disease progression. The surgical outcome has very minimal intra- and postoperative complications.

Conclusion Single-stage decompression and posterior stabilization in thoracolumbar spinal tuberculosis is safe, effective, and results in good clinical outcome. The advantages of surgery include thorough debridement, decompression, and achievement of spinal stabilization.

Keywords

- ▶ tuberculosis
- ▶ spine
- ▶ decompression
- ▶ posterior fixation

Introduction

Tuberculosis (TB) has lived in symbiosis with human beings since time immemorial and is as old as humankind. It has

been demonstrated in the remains of Iron Age and Egyptian Mummies. As we have evolved in medical science, the goals of treatment have changed. In the pre-antibiotic era, patients with spinal TB were treated by high-protein diet, rest, fresh

published online
April 19, 2021

DOI <https://doi.org/10.1055/s-0039-1698588>
ISSN 2277-954X.

© 2021. Neurological Surgeons' Society of India.

This is an open access article published by Thieme under the terms of the Creative Commons Attribution-NonDerivative-NonCommercial-License, permitting copying and reproduction so long as the original work is given appropriate credit. Contents may not be used for commercial purposes, or adapted, remixed, transformed or built upon. (<https://creativecommons.org/licenses/by-nc-nd/4.0/>).

Thieme Medical and Scientific Publishers Pvt. Ltd. A-12, 2nd Floor, Sector 2, Noida-201301 UP, India

air, and sunshine in sanatorium hoping for natural quiescence of the disease.¹

Globally, nearly 30 million people suffer from TB. Three million deaths occur due to TB per year. India has a burden of 6 million cases. Recent increase in the incidence is due to concomitant TB with human immunodeficiency virus (HIV) infection and drug resistance. Of these, 1 to 3% constitutes skeletal system involvement. Spinal TB (50%) is the most common form of skeletal TB.² The evolution of treatment of spinal TB has passed through different phases of development from pre-antitubercular era, through post-antitubercular era, and from radical surgery through middle path regimen.² Traditionally, the anterior approach was the gold standard because vertebral bodies and disc spaces are most commonly affected, and the anterior approach allows direct access to the diseased vertebral bodies for debridement and abscess drainage and wide decompression and reconstruction of the defect.^{2,3} In the thoracic and lumbar region, morbidity and complications associated with anterior surgery (thoracotomy and retroperitoneal approach) are very significant. Anterior instrumentation to provide bone stability may be tenuous because the concomitant osteoporosis associated with infection renders the vertebrae structurally weak, prevent adequate fixation, and the construct is biomechanically less stable.^{4,5} The approach to the upper thoracic spine is difficult, and there is a need for thoracic surgeon. The lung may be scarred or adherent to the underlying pleura that precludes the anterior approach.

A combined anterior debridement and posterior instrumentation helps overcome stability-related drawbacks of anterior approach alone.^{6,7} However, it entails two surgeries (single event or staged) with additional morbidity and is indicated for patients with significant deformity.

In posterior or posterolateral approaches, anterior and lateral column can be reached through extrapleural approach. Posterior approach provides excellent exposure for circumferential spinal cord decompression; allows multiple-level posterior instrumentation above and below the level of pathology, more stable construct, less morbid surgery, and earlier rehabilitation; and is a familiar approach.^{2,8,9} In this study, we tried to analyze the neurologic outcome of decompression posterior stabilization in thoracolumbar spinal TB.

Aim and Objectives

The aim of this prospective study is to analyze the neurologic outcome in decompression, posterior stabilization in thoracolumbar spinal TB in adult patients in our institution.

Materials and Methods

This study was conducted at a tertiary care hospital in Bhubaneswar, Odisha, India, and a total of 43 patients were enrolled in this study. The inclusion criteria included patients aged between 18 and 70 years, who are suffering from thoracolumbar spinal TB refractory to medical treatment with antitubercular drugs for 4 weeks, patients having neurologic

weakness, development of the neurologic weakness during the period of medical treatment, and monosegmental spinal TB. The exclusion criteria included severe systemic illness (severe anemia, hypoalbuminemia, high fever, HIV infection, chronic obstructive pulmonary disease [COPD] with cardiac insufficiency), severe osteoporosis, and spinal degenerative disease and patients improved with antitubercular treatment.

Detailed history was recorded in each case. Thorough clinical examination such as general, systemic, and neurologic examination and comorbid condition were done and recorded. Pain was evaluated by visual analog pain score (VAS). Neurologic status was documented by modified Frankel grade and AIS American Spinal Injury Association impairment score) grade. Hematologic investigation includes complete blood count (CBC), renal function test (RFT), liver function test (LFT), erythrocyte sedimentation rate (ESR), C-reactive protein (CRP), and tuberculosis polymerase chain reaction (TB PCR). Radiographic examination includes X-ray of the dorsal and lumbar spine (anteroposterior [AP] and lateral views). Magnetic resonance imaging (MRI) scan of the thoracolumbar spine and screening of whole spine were done in all cases. Postoperatively histopathologic confirmation of the tissue was done. Check X-ray was done to access implant position. Clinical outcome was measured by modified Frankel grading. AIS grade and pain assessment was done with VAS pre- and postoperatively and at 3, 6, and 9 months of interval. Other parameters such as postoperative complications and postoperative improvement in ESR and CRP were noted. We give four drugs (H = isoniazid, R = rifampicin, Z = pyrazinamide, E = ethambutol) in intensive phase for 3 months and three drugs (H = isoniazid, R = rifampicin, E = ethambutol) for continuation phase for 15 months, a total of 18 months.

All patients were explained about the objective of this study and fully explained about its conditions such as confidentiality and option to withdraw from this study at any point of time and taken proper consent. Clearance was taken from the institutional ethical and scientific committee.

Statistical Analysis

Scale variables have to be compared by dependent sample *t*-test. Nonparametric procedure can also be considered for comparison. Minimum sample size (which is 41) has been determined using software G*power version 3.1.9.2. The statistical analysis was done using IBM Corp. statistics SPSS 24.0. Association of age and sex distribution was studied using cross-tabulation procedure along with chi-square test of independence. Descriptive statistics of age such as mean, standard deviation, median, Q1, and Q3 were computed using descriptive statistic procedure. Distribution of comorbidities, constitutional symptoms, and vertebrae level was done following frequency procedure. Association of pathologic lesion by age was studied using cross-tabulation procedure and chi-square test of association.

Observations

The analysis was based on 43 cases of thoracolumbar spinal TB following decompression and posterior stabilization.

Demographic and Clinical Profile

Age and Sex Distribution of the Study Patients

The mean age of diagnosis of spinal TB was 54.1 ± 14.5 years. There were 12 (27.9%) cases younger than 50 years, 11 (25.6%) in the age group of 50–59 years, and 20 (46.5%) were 60 years or older. Thus, nearly 50% of the cases were older than 60 years, whereas more than 70% were older than 50 years. Out of the 43 cases, 32 (75%) cases were males and 11 (25%) were the females. However, the age distribution of patients in both the sexes was not significantly different ($p = 0.555$).

Comorbidities and Constitutional Symptoms of Subjects

Diabetes mellitus (DM) was present among 37.2% of cases whereas hypertension was seen in 23.3% cases. Pain was the universal symptom of all the cases. Besides, 14 (32.6%) cases presented with fever, 31 (72.1%) with weight loss, 36 (83.7%) with fatigue, and 13 (30.2%) with night sweat. Five cases did not have any of the constitutional symptoms whereas 19 had only one constitutional symptom, 8 had two symptoms, and only 1 case presented with three symptoms.

Involvement of Vertebra Level

Out of the 43 cases, 30 (69.8%) cases were of dorsal and 13 (30.3%) were lumbar spinal TB. This has implied that spinal TB cases are more presented over the dorsal region than the lumbar region. Among the dorsal cases, maximum levels of involvement were at D8–9 (16.3%), followed by D7–8 and D6–7 (11.6%) each. Among the lumbar cases, the affections of disease were maximum at L4–5 (14%) level.

Analysis of Surgical Parameters

Surgical Time

Among the 30 dorsal cases, the mean surgical time was 199.3 ± 17.4 minutes and that of the lumbar cases was 182.3 ± 21.2 minutes. There is a mean difference of 17 minutes in the surgical time ($p = 0.009$). The overall mean in the surgical time is 194.19 ± 19.96 minutes, with a range of 165 to 235 minutes.

Duration of the Hospital Stay

The mean hospital stay in dorsal cases was 12.3 ± 1.2 days, whereas that of the lumbar cases was 10.8 ± 0.9 days. It was

observed that the overall mean duration of hospital stay was 11.9 ± 1.4 days, with a range of 10 to 15 days.

Postoperative Pain Relief

At the preoperative stage, out of 43 cases, 34 (79.1%) cases presented with mild pain and 9 (20.9%) with moderate pain (► **Table 1**). At postoperative 3 months, out of the 43 cases, 40 (93%) cases improved significantly and presented with no pain and 3 (7%) had only mild level of pain. The improvement was significant at 3 months ($p = 0.000$). At 6 and 9 months, all the cases were presented without any pain during our evaluation. The mean preoperative VAS is 3.05 ± 0.61 and that at 3-month follow-up was 1.07 ± 0.25 . The difference is statistically significant ($p = 0.000$). This has implied that decompression posterior stabilization in thoracolumbar spinal TB was a very effective procedure in relieving the pain.

Neurologic Outcome

Neurologic Weakness (Modified Frankel Grade) and AIS Grade

At the preoperative stage, out of the 43 cases, 3 (7%) cases had Frankel score B; 21 (48.8%) had a Frankel score C1, C2; 17 (39.5%) had D1, D2, D3; and 2 (4.7%) had Frankel E.

At postoperative 3 months, no cases were in Frankel B; presentation of C1 and C2 reduced to 8 (18.6%) cases; and presentation of D1, D2, D3 increased to 34 (79.1%) cases. However, the improvement was not statistically significant at 3 months ($p = 0.157$).

At 6 months postoperative, presentation of the cases in C1, C2 further reduced to 3 (7%) cases; presentation of D1, D2, D3 increased to 36 (83.7%) cases; and presentation of E became 4 (9.3%) cases. Therefore, significant improvement was noticed in paraplegia at 6 months over the preoperative stage ($p = 0.025$).

At 9 months, only 2 (4.7%) cases were in C1, C2; 14 (32.6%) were in D1, D2, D3; and 27 (62.8%) were in E. Thus there was significant improvement in neurologic weakness at 9 months of postoperative follow-up ($p = 0.000$) (► **Table 2**). Similar type of improvement was observed in AIS grade also.

Intra- and Postoperative Complications

We have analyzed the intraoperative complications such as neural and vascular injuries that were not observed in any

Table 1 Comparative picture of VAS pain over the different follow-ups at 3, 6, and 9 months

VAS	Preoperative		Postoperative 3 mo		Postoperative 6 mo		Postoperative 9 mo	
	No.	%	No.	%	No.	%	No.	%
No pain	0	0.0	40	93	43	100	43	100
Mild pain	34	79.1	3	7	0	0	0	0
Moderate pain	9	20.9	0	0	0	0	0	0
Severe	0	0.0	0	0	0	0	0	0
Total	43	100.0	43	100	43	100	43	100
Marginal homogeneity test ^a	$p = 0.000$							

Abbreviation: VAS, visual analog scale.

^aMarginal homogeneity test has been done to compare the proportions at the follow-ups with the preoperative proportions.

patient, whereas two (4.7%) cases had postoperative wound infection and one (2.3%) case had sinus formation at the wound site. There was no incidence of implant failure such as screw breakage and pullout seen in this series.

Comparison of Erythrocyte Sedimentation Rate between the Pre- and Postoperative Period

At the preoperative stage, the mean ESR was 83.6 ± 14.9 mm, with a range of 46 to 110 mm that was reduced to 32.63 ± 7.9 mm, with a range of 11 to 47 mm at 3-month follow-up (►Fig. 1). The reduction is highly significant ($p = 0.000$). Similarly, the median at the preoperative was 85 mm, with an interquartile range (IQR) of 76 to 93 mm. In the postoperative period, the median value was 34 mm, with an IQR of

29 to 37 mm. This shows at the postoperative period, there has been a significant reduction in the patients' ESR level.

Comparison of C-reactive Protein between Pre- and Postoperative Period

The mean CRP at preoperative period was 38.98 ± 12.84 mg/L, with a range of 20 to 72 mg/L that has reduced to 16.42 ± 4.36 mg/L, with a range of 8 to 30 mg/L that is significant ($p = 0.000$) at the postoperative 3-month follow-up (►Fig. 2). The minimum and maximum values have also significantly reduced. The median, first, and second quartile have also significantly reduced in the postoperative follow-up. This implied that the CRP values are significantly improved in the postoperative period.

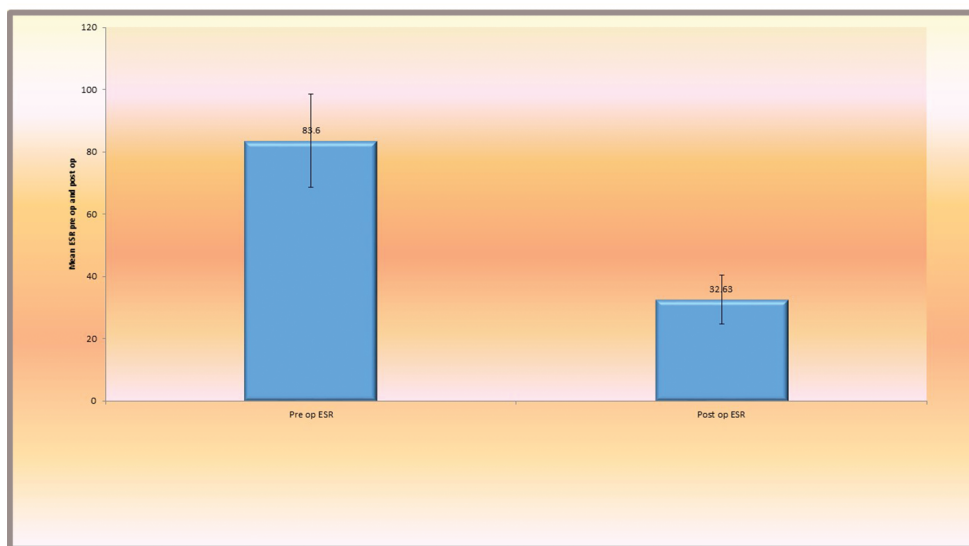


Fig. 1 Mean improvement of erythrocyte sedimentation rate (ESR) at 3 months.

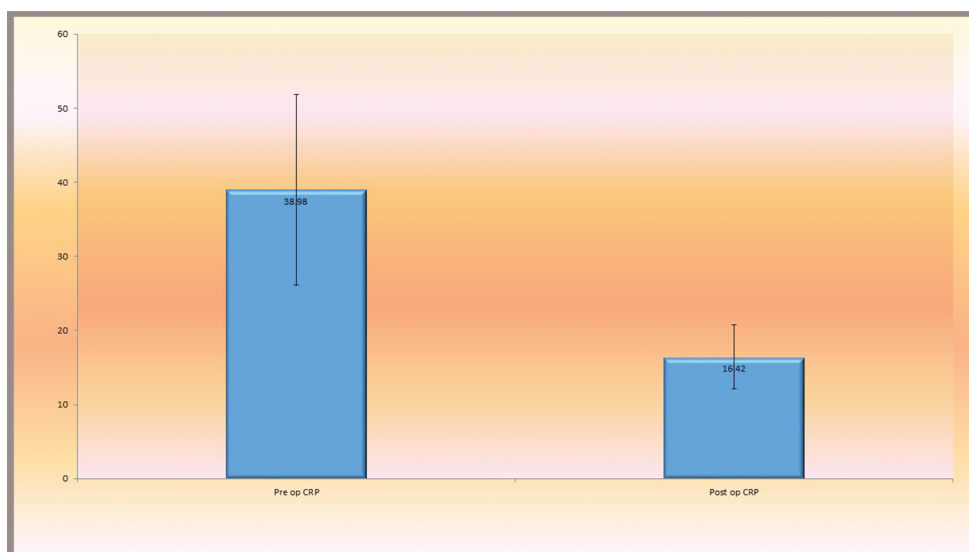


Fig. 2 Improvement of C-reactive protein (CRP) at 3 months.

Table 2 Change of Frankel score in pre- and postoperative periods

Frankel score	Preoperative		Postoperative 3 mo		Postoperative 6 mo		Postoperative 9 mo	
	No.	%	No.	%	No.	%	No.	%
B	3	7	0	0	0	0	0	0
C1, C2	21	48.8	8	18.6	3	7	2	4.7
D1, D2, D3	17	39.5	33	76.7	36	83.7	14	32.6
E	2	4.7	2	4.7	4	9.3	27	62.8
Total	43	100	43	100	43	100	43	100
Marginal homogeneity test (<i>p</i> -value)			0.157		0.005		0.000	

Radiologic Improvement

There is a significant radiologic improvement seen in these cases. We have the X-ray immediate postoperative day and X-ray along with MRI scan at 6-month interval to look for the radiologic improvement. The MRI (►Fig. 3) shows preoperative status and postoperative improvement.

Discussion

This study is an evaluation of clinical development as well as neurologic outcomes in decompression posterior stabilization in thoracolumbar spinal TB in adults. This study results have highlighted findings based on 43 sample cases. In the literature, the sample sizes vary from 20 to 440 in most studies, but there are fewer studies with sample size more than 40 according to our knowledge.

The mean age of presentation of the disease was 54.1 ± 14.5 years, with a range of 18 to 70 years in our study. The higher age group of 50 to 59 years had one-quarter of this study patients and group of 60 years or older had 46.5% of this study patients. In the studies by Jia et al,¹⁰ the mean age of presentation was 45.9 ± 12.7 years, with a range of 27 to 69 years. The mean age of representation in the studies by Zhong et al¹¹ was 45.5 years, with a range of 19 to 76 years. Dai et al¹² in their studies found that the mean age of presentation of the disease was 43.8 ± 12 years, with an age range of 25 to 68 years. This revealed that patients in our study had a higher mean age than those in other studies. This may be the peculiarity of this study population where nearly three-fourths of patients in the elderly age group of 60 years or older are found. Old age was found to be more associated with the disease. The male-to-female ratio in our study was 3:1 showing a high level of male preponderance of the disease. However, the literature^{10,13} has found approximately equal male to female ratio. The high preponderance of male in our study is something intriguing and needs further exploration.

In this study, we found DM in 37.2% of cases and hypertension in 23.3% of cases. In the studies by Alavi et al,¹⁴ the incidence of DM was 30%. The above association is corroborated to our study in which the incidence was little higher. We could not locate studies showing the clinical presentation of hypertension among study patients.

Though pain in the back and neurologic weakness was the universal symptom of patients in this series, the various other constitutional symptoms are discussed. Fourteen (32.6%) cases presented with fever, 31 (72.1%) with weight

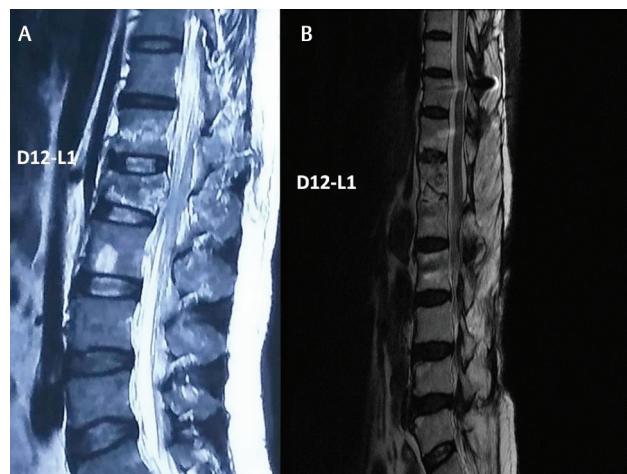


Fig. 3 The preoperative (A) and 6 months postoperative (B) MRI picture given along with the radiologic signs of resolution of disease.

loss, 36 (83.7%) with fatigue, and 13 (30.2%) cases with night sweat. In the study by Saha et al,¹⁵ the most common clinical presentation was pain (83.33%), followed by gibbus (58.33%), paraplegia (50%), weight loss (33.33%), and difficulty to work (16.67%). Though we did not find any incidence of gibbus in our study, because most patients had reported to us in the early disease process, the incidence of pain corroborates with our study in which it was also the most common symptom, followed by neurologic weakness at various grades. Berkowitz et al,¹⁶ in their studies, found the incidence of symptoms such as fatigue in 31.6%, weight loss in 16.6%, and night sweats in 16.4% of cases. Though the incidence of fatigue is less as compared with that shown in our study, but it is the most common presenting complaint.

In this study, out of the 43 cases, 30 (69.8%) cases were dorsal and 13 (30.2%) were lumbar spinal TB. Among the dorsal cases, the maximum levels of involvement were seen at the D8–9 level (16.3%), followed by D7–8 and D6–7 (11.6%) each. Among the lumbar cases, the affection of the disease was maximum at L4–5 (14.0%) level. This corresponds to other studies such as by Saha et al¹⁷ in which they found the distribution of disease to be 58.33% in the dorsal region, which is the highest followed by 25% in the lumbar region and 16.67% in the thoracolumbar region. Regarding the maximum level of affection of the disease, our study also corresponds to the studies by Prabhat et al¹⁸ in which the distribution of disease is maximum, that is, at the T5–T9 level. This has implied that

the thoracolumbar spinal TB cases are more present at the dorsal region than the lumbar and junctional regions. From this study, it may be concluded that back pain, whenever associated with any of the constitutional symptoms in elderly population, should be investigated in the line of thoracolumbar spinal TB.

The mean surgical time in this study was 194.19 ± 19.96 minutes. It ranges from 165 to 235 minutes. Liu et al,¹⁹ in their studies in which 37 cases of thoracolumbar spinal TB were studied, found the average surgical time to be 192 ± 28 minutes and the range varies from 150 to 255 minutes. This study corroborates to the findings of our study. Luo et al,²⁰ in their studies, found the average operating time as 162 ± 19.88 minutes (120–210 minutes). Similarly, Patidar et al¹³ observed the average time of operation to be 155 ± 23.95 minutes in their study. The two above studies have lower mean surgery time in comparison to our study.

The average hospitalization duration in this study was 11.9 ± 1.4 days, which is comparable to other studies such as by Zeng et al²¹ in which the average hospitalization duration was 12.4 ± 4.1 days. Luo et al,²⁰ in their study, reported an average stay of 13.54 ± 1.3 days. The findings of the literature are comparable with those of this study. Economically postoperative hospital stay plays a vital role in this part of the world where more people live in a below-poverty-line condition. Therefore, it is required to expound innovations to decrease the postoperative hospital stay.

In this study, we compared the preoperative VAS to the final follow-up. The preoperative average VAS score in our study is 3.05 ± 0.615 , which was 1.07 ± 0.258 in the final follow-up. This is equivalent to the studies by Prabhat et al.¹⁸ Most patients improved in the first follow-up as like in the above study. Liu et al,¹⁹ in their studies in which the follow-up visits are at 1, 3, and 6 months, reported that the preoperative VAS of 5.5 ± 2.23 improved to 1.5 ± 1.22 in the final follow-up period, which was also consistent with our study. This signifies that the procedure of decompression posterior stabilization is very much effective in relieving pain in thoracolumbar spinal TB cases.

This study shows three (7%) cases at Frankel B preoperatively, whereas no case was found in Frankel B at postoperative 9 months. There were 21 (48.8%) cases in Frankel C1 and C2, whereas only 2 such cases were found at postoperative 9 months. Similarly, 17 (39.5%) cases were in Frankel D1, D2, D3 at preoperative period, which has become 14 cases (32.6%) cases at the 9-month follow-up period. There were only 2 (4.7%) cases in Frankel E grade at preoperative period, which was increased to 27 (62.8%) cases at 9-month follow-up period.

In more than 37 cases by Liu et al¹⁹ where they compared with Frankel grade in comparison to ours in which modified Frankel grading is applied, the results are discussed as preoperative Frankel grade A3, B5, C11, D9, and E9 cases that are improved to A1, B2, C4, D9, and E21 cases in the final follow-up, which is statistically significant ($p = 0.000$). In the studies by Nabarun et al¹⁷ in which the Frankel grades of Gp 2 are discussed as preoperative Frankel C4, D8, and E10 cases were improved to Frankel C1, D3, and E18 cases in their

final follow-up. Thus decompression posterior stabilization is proven to be very effective in terms of neurologic improvement, and this study corroborates with other studies as above.

In our study, we observed at the preoperative stage, 3 (7%) cases in AIS grade B, 21 (48.8%) in AIS C, 17 (39.5%) in AIS D, and 2 (4.7%) in AIS E, and the same at the final follow-up stood at 27 (62.8%) out of 43 cases that improved to AIS E, 14 (32.6%) were in AIS D, 2 (14.7%) in AIS C, and none in AIS B. The statistical comparison is also significant ($p = 0.000$). In the studies by Zeng et al,²¹ the preoperative AIS grade finding that was AIS grade A3, B5, C15, D11, and E0 has improved to AIS grade A0, B2, C4, D14, and E14 at their final follow-up. Luo et al,²⁰ in their studies, said that all of their patients improved neurologically. This also signifies that the procedure of decompression posterior stabilization is very much effective in arresting the disease and enhances neurologic improvement.

In this study, we have not encountered any intraoperative complications such as spinal cord, dura, or root injury, or any major vascular injuries that are also recorded by various other studies such as those by Patidar et al¹³ and Dai et al.¹²

However, we encountered two (4.7%) cases of superficial wound infection and one (2.3%) case of sinus formation. The infected wound is debrided and sutured with broad-spectrum antibiotic coverage, and patients recovered well. The patient with wound sinus has healed within 2 months of antitubercular treatment. This signifies that the procedure of decompression posterior stabilization is not totally devoid of surgical complications.

In our study, we found an increased ESR in all the cases. The mean preoperative ESR was 83.6 ± 14.9 mm, with a range of 46 to 110 mm. In the first 3-month follow-up, the mean ESR decreased to 32.6 ± 7.8 mm, with a range of 11 to 47 mm. The difference is statistically significant ($p = 0.000$). In the studies by Luo et al,²⁰ the mean preoperative ESR that was 73.46 ± 11.39 mm has returned to 10.14 ± 2.85 mm in the first follow-up. In the studies by Zeng et al,²¹ the preoperative mean ESR that was 40.2 ± 6.3 mm has returned to 21.3 ± 5.1 mm in the follow-up period. Our study corresponds to the above studies about improvement in ESR. Thus, ESR estimation in the preoperative stage compared with the postoperative stage depicts the efficacy and adequateness of debridement and control of the disease.

In our study, we found an increased CRP that is a definitive inflammatory marker in all the cases. The mean preoperative CRP was 38.98 ± 12.83 mg/L, with a range of 20 to 72 mg/L. In the first 3-month follow-up, the mean CRP decreased to 16.42 ± 7.8 mg/L, with a range of 8 to 30 mg/L. The difference is statistically significant ($p = 0.000$). In the studies by Zeng et al,²¹ the preoperative mean ESR that was 22.4 ± 5.7 mg/L has returned to 10.2 ± 4.5 mg/L in the follow-up period. Hence our study corresponds to the above study about the improvement in CRP in the follow-up period. Thus, CRP estimation in the preoperative stage compared with the postoperative stage depicts the efficacy and adequateness of the surgical procedure undertaken for control of the disease.

This study has evaluated patients with a limited number in a single center up to 9 months of postoperative follow-up.

Large-scale studies and clinical trials are also required to develop and validate more accurate modules, matrixes, or algorithms for early diagnosis of spinal TB based on advances in medical technologies.

Conclusion

Spinal TB is a very common disease, particularly in the developing countries. Early diagnosis and proper management strategy improve the outcome. On the basis of this study results, decompression posterior stabilization in thoracolumbar spinal TB is found to be safe and effective, with good clinical outcomes such as postoperative pain relief, neurologic outcomes, and improvement in ESR and CRP. The advantages of surgery include thoroughness of debridement, decompression of the spinal cord, and achievement of adequate spinal stabilization.

Authors' Contributions

B.N. contributed in concept design, definition of intellectual content, literature search, clinical study, manuscript preparation, manuscript editing, manuscript review, guarantor, and is the corresponding author of the article. S.K.P., A.K., B.H.K., and D.B. contributed in literature search, clinical study, manuscript editing, and manuscript review.

Conflict of Interest

None declared.

References

- Jain AK. Tuberculosis of spine: Research evidence to treatment guidelines. *IJO* 2016;50(1):3–9
- Tuli SM. Tuberculosis of the Skeletal System (Bones, Joints, Spine and Bursal Sheaths), 4th edition. Chapter 19. New Delhi: Jaypee Brothers Medical Publishers; 2010
- Jain AK, Dhammi IK, Prashad, Simultaneous anterior decompression and posterior instrumentation of the tuberculosis spine using an anterolateral extrapleural approach. *J Bone Joint Br* 2008;90;1477–1481
- Hodgson AR, Stock FE, Fang HS, Ong GB. Anterior spinal fusion: The operative approach and the pathological findings in 412 patients with Pott's disease of the spine. *Br J Surg* 1960;48:172–178
- Hee HT, Majd ME, Holt RT. Better treatment of vertebral osteomyelitis using posterior stabilization and titanium mesh cages. *J Sinal Disord Tech* 2002;15:149–156
- Krodel A, Kruger A, Pfahler M. Anterior debridement, fusion and extra focal stabilization in the treatment of osteomyelitis of spine. *J spinal Disord* 1999;8:304–309
- Fukuta S, et al. Two stage surgical treatment using posterior spinal instrumentation for pyogenic and tuberculous spondylitis. *Spine* 2003;28:E302–E308
- Moon MS, Woo YK, Lee KS, et al. Posterior instrumentation and anterior interbody fusion for tuberculous kyphosis of dorsal and lumbar spine. *Spine* 1995;20:1910–1916
- Lee TC, Lu K, Yang LC, Huang HY, Liang CL. Transpedicular instrumentation as an adjunct in the treatment of

- thoracolumbar and lumbar spine tuberculosis with early state bone destruction. *J Neurosurg* 1999;91(2 Suppl):163–169
- Jia Xufeng, Long Miao, Zhou Qingzhong, Ji Yong, Huang Guangping, Zhou Yu1, Feng Daxiong, Efficacy of posterior-only decompression, focal clearance, and internal fixation in treatment of thoracic and lumbar tuberculosis. *Biomedical Research* 2018;29(2):262–267
- Zhong Nanzhe, Kong Jinhai, Sun Zhengwang, Quian Ming, Liu Tielong, Xiao Jianru. One-stage posterior approach in the treatment of consecutive multi-segment thoracic tuberculosis with Kyphosis. *Turkish Neurosurgery* 2018;28(3):1–8
- Yuliang Dai, Li Yawei, Wang Bing, Lv Guohua. Anterior versus posterior surgery for mono-segmental thoracic spinal tuberculosis: selection of the optimal approach and comparison of outcomes. *Int J Clin Exp Med* 2017;10(7):10463–10471
- Patidar AB, Mehta RP, Sharma SK, Vyas GB, Singh V, Ramchandra O. Single-stage posterior-only debridement and transpedicular screw fixation for thoracolumbar tuberculosis: a prospective study of twenty cases. *J Orthop Allied Sci* 2017;5:74–79
- Alavi SM, Khoshkhoy MM. Pulmonary tuberculosis and diabetes mellitus: Co-existence of both diseases in patients admitted in a teaching hospital in the southwest of Iran. *Caspian J Intern Med* 2012;3(2):421–424
- Saha Apel Chandra, Kabiraj Snriti Kona, Rahman Md Rezwannur, Md Shahana Shermin, Masud Hasan, Hossain Muhammad Awlad. Surgical treatment of thoracolumbar spine tuberculosis by posterior decompression, stabilization with transpedicular screws and rods and fusion. *Delta Med Col J* 2016;4(2):71–76
- Berkowitz Natacha, Okorie Adaeze, Goliath Renea, Levitt Naomic, Wilkinson Robert J, Oni Tolu, The prevalence and determinants of active tuberculosis among diabetes patients in Cape Town, South Africa, a high HIV/TB burden setting. *Diabetes research and clinical practice* 138 (2018): 16–25
- Saha Nabarun, Mukhopadhyay Kiran Kumar, Garg Anant Kumar, Sanjay Kumar, Sarkar Partha Sarathi. Comparative study of debridement, fusion and instrumentation via single stage anterior or single stage posterior approach in thoraco-lumbar spinal tuberculosis. *International Journal of Orthopaedics Sciences* 2017;3(2):901–990
- Prabhat Vinay, Kumar Ramesh, Sahu Harekrushna, Boruah Tankeshwar, Palak Jay, Dagar Ashish. Single stage transpedicular decompression, fixation and deformity correction in tuberculosis of dorsal and lumbar spine. *IOSR Journal of Dental and Medical Sciences* Aug. 2017;16(8):92–97
- Liu Zhili, Liu Ziaming, Peng Aifeng, Long Xinhua, Yang Dong, Huang Shanhu. One-stage posterior debridement and transpedicular screw fixation for treating monosegmental thoracic and lumbar spinal tuberculosis in adults. *ScientificWorldJournal* 2014;2014:137106
- Luo Chengke, Wang Xiyang, Wu Ping, Ge Lie, Zhang Hongqi, Hu Jianzhong. Single-stage transpedicular decompression, debridement, posterior instrumentation, and fusion for thoracic tuberculosis with kyphosis and spinal cord compression in aged individuals. *The Spine Journal* 2016;16(2):154–162
- Hao Zeng et al. One-stage posterior-only approach in surgical treatment of single-segment thoracic spinal tuberculosis with neurological deficits in adults: a retrospective study of 34 cases. *BMC Musculoskeletal Disorders* 2015;16:186