

Malignant Transformation of an Enchondroma of the Hand: A Case Report

Transformación maligna de encondroma en la mano: Caso Clínico

María Jesús Rivera Vegas¹

¹Plastic Surgery Department, Hospital Universitario de Burgos, Burgos, Spain

Address for correspondence: María Jesús Rivera Vegas, PhD, Departamento de Cirugía Plástica, Hospital Universitario de Burgos, Burgos, Burgos 09002, España (e-mail: riveravegas@gmail.com).

Rev Iberam Cir Mano 2020;48:128–132.

Abstract

We present the case of the transformation of an enchondroma in the middle phalanx of the fourth finger of the left hand into a chondrosarcoma. The patient presented a lesion with clinical history, examination, and radiology findings consistent with an enchondroma, which was conservatively treated. Two years later, the patient came for a medical visit with a clinical and radiological variation of the lesion. Computed tomography scans and biopsy revealed a lesion with sarcomatous degeneration which was confirmed after the controlled amputation of the fourth finger. The malignant transformation potential of an enchondroma must be considered.

Keywords

- ▶ enchondroma
- ▶ chondrosarcoma
- ▶ malignant transformation

Resumen

Presentamos el caso de una transformación maligna de un encondroma en falange media de 4° dedo mano izquierda en un condrosarcoma. El paciente presentó una lesión con una historia clínica, exploración y radiología compatible con encondroma y se decidió tratamiento conservador. Dos años mas tarde, el paciente vuelve a consulta por una variación clínica y radiológica de la lesión. El TAC y la biopsia, indican la posibilidad de una degeneración sarcomatosa de la lesión confirmada tras la amputación reglada del 4° dedo. La posibilidad de dicha transformación maligna en el encondroma debe ser considerada

Palabras Clave

- ▶ encondroma
- ▶ condrosarcoma
- ▶ transformación maligna

Introduction

An enchondroma is the most common benign bone tumor in hands, involving predominantly phalanges. Its malignant counterpart, the chondrosarcoma, usually affects the pelvis, proximal femur, and humerus, but it was not reported in the small bones of the hand. Enchondromas rarely turn into chondrosarcomas. Although this transformation is more frequent in multiple conditions than in solitary injuries, it is infrequent in hands.¹

We present a case of malignant degeneration of an enchondroma at the middle phalanx of the fourth finger of

the left hand initially diagnosed with a simple radiograph. Such malignant transformation was observed clinically and radiologically 2 years later, and the anatomopathological diagnosis of chondrosarcoma was established.

Clinical Case

This is an 85-year-old male patient seen at the Plastic Surgery Clinic from Hospital Universitario de Burgos, in Spain. An enchondroma at the middle phalanx of the fourth finger of the left hand was diagnosed based on clinical findings and simple radiographs. The radiological report described a well-

received
July 4, 2019
accepted
September 18, 2019

DOI <https://doi.org/10.1055/s-0039-1698814>.
ISSN 1698-8396.

Copyright © 2020 Thieme Revinter
Publicações Ltda, Rio de Janeiro, Brazil

License terms



defined expansive lytic lesion associated with cortical erosion, soft tissue swelling with probable calcification, and reduced bone density in the middle phalanx of the fourth finger of the left hand, all link with focal osteopenia. This lesion was consistent with an enchondroma as first diagnostic option. In addition, the radiological report described severe degenerative changes at the medial and distal phalanx and the first carpometacarpal joint (►Fig. 1) In view of radiological and clinical findings, a conservative treatment was instituted due to the medical history of the patient (who had multiple conditions and a generalized vascular compromise) and his advanced age.

Two years later, the patient came for a visit due to a clinical change, with increased pain and joint stiffness, but no cutaneous ulceration.

At the physical examination, the patient had a painful lesion with an external size of $2.5 \times 3 \times 2$ cm at the level of the medial phalanx and distal interphalangeal joint of the fourth finger from the left hand. In addition, the lesion hindered the movement of the affected finger. Since its radiological presentation► (Figures 2 and 3) was consistent with a sarcomatous degeneration, a computed tomography (CT) and biopsy were requested.

A multislice helical CT was performed in the left hand to complete the study of this expansive, lytic lesion affecting the middle phalanx of the fourth finger of the hand. The scan revealed cortical bone thinning, areas of cortical destruction, and small, punctate calcifications within the lesion which were related to the chondroid matrix. The approximate diameter of the lesion was $21 \times 28 \times 25$ mm (anteroposterior, transversal, and craniocaudal measurements, respectively). These findings suggested a protruding enchondroma. Although protruding enchondromas appear aggressive, a sarcomatous degeneration could not be ruled out because of the increased size of the lesion and the greater cortical destruction when comparing radiographs taken in January 2011 and October 2013 (►Figure 4)

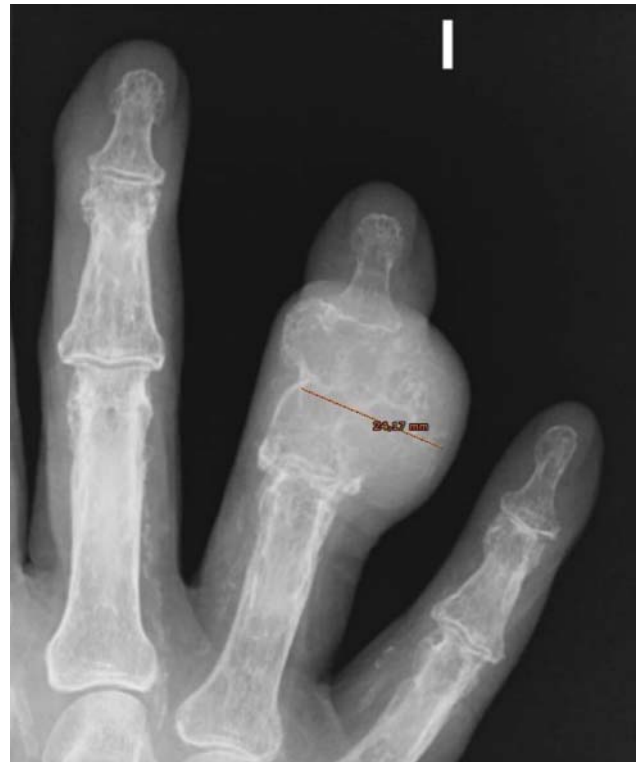

Figure 2 Posteroanterior simple radiography revealing an expansive lesion at the middle phalanx of the fourth finger, with different size and shape but at the same location seen 2 years ago.

These radiological findings led to lesion biopsy, which could not establish a histological differentiation between a protruding condition and a low-grade chondrosarcoma.

After discussing the condition with the patient and his family, the surgical removal of the lesion was decided, with amputation of the fourth finger of the left hand. Pathological anatomy grossly described a lesion at a surgical resection piece measuring 6.8 cm at its longitudinal axis, 3.5 cm at its

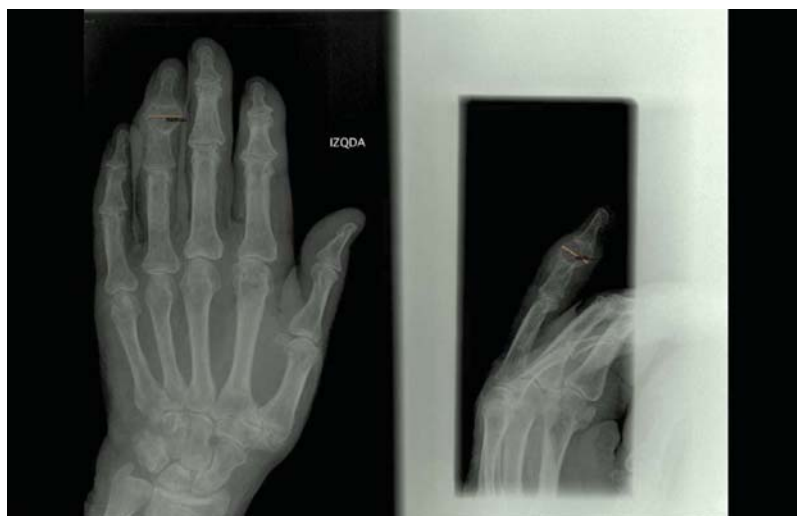

Figure 1 Posteroanterior simple radiography showing the lesion diagnosed 2 years ago as an enchondroma. The tumor was located at middle phalanx of the fourth finger and measured in millimeters.

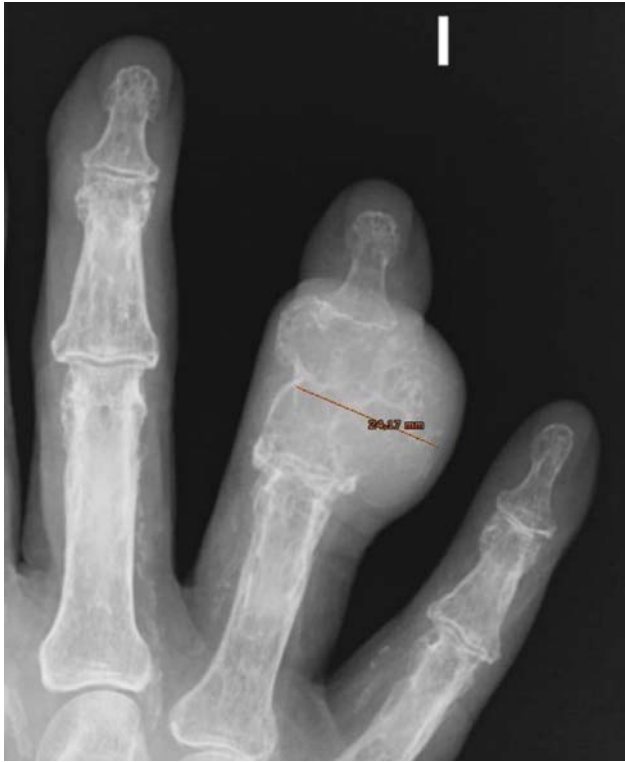

Figure 3 Oblique simple radiography showing an expansive lesion at the middle phalanx of the fourth finger.

transversal axis and 3.4 cm at its dorsoventral axis. The medial region of the piece presented a tumor measuring 4 cm at its longitudinal axis per 3.5 cm at its transverse axis that ulcerates focally on the external lateral surface. When sectioned, the tumor was white, elastic, smooth and homogeneous, with white areas alternating with reddish brown areas, measuring 2.7 cm at its dorsoventral axis per 2.8 cm in its transversal axis. Microscopically, it was a chondroid

tumor, with nodular appearance and dense cellularity, atypical cells with pleomorphic, hyperchromatic nuclei and frequent binucleation. In addition, the tumor presented myxoid areas. Cortical bone disruption was observed in multiple points, with infiltration of the adjoining soft parts in some areas. These histological findings are consistent with a low-grade chondrosarcoma that does not contact the resection margin. The study was carried out using formaldehyde fixation and decalcification techniques.

The patient died 4 years after treatment with no signs of local recurrence or secondary chondrosarcoma metastasis. Clinical history reported cause of death as an acute myocardial infarction.

Discussion

We present the malignant transformation from a solitary enchondroma to chondrosarcoma. This malignancy is extremely rare, with few cases recorded in the literature.

Enchondromas are the most common bone tumors in hands (90%), consisting in intramedullary lesions characterized by a well-differentiated hyaline cartilage. Although infrequent, its transformation into malignant entities must be considered. Malignancy transformation rates are much higher in patients with multiple enchondromatosis, such as those with Ollier disease or Maffucci syndrome. Some authors reported an up to 50% relationship rate between chondrosarcomas and Ollier disease.¹

Enchondromas arise from growth plates with failed cell hypertrophy and programmed change processes, originating non-calcified columnar cartilage cells.

An enchondroma is usually diagnosed incidentally due to a fracture associated with a regular trauma or in a radiological examination requested for another cause. This tumor is indolent, slow growing and avascular, with no relevant perilesional inflammatory response.¹ An enchondroma with enlarged

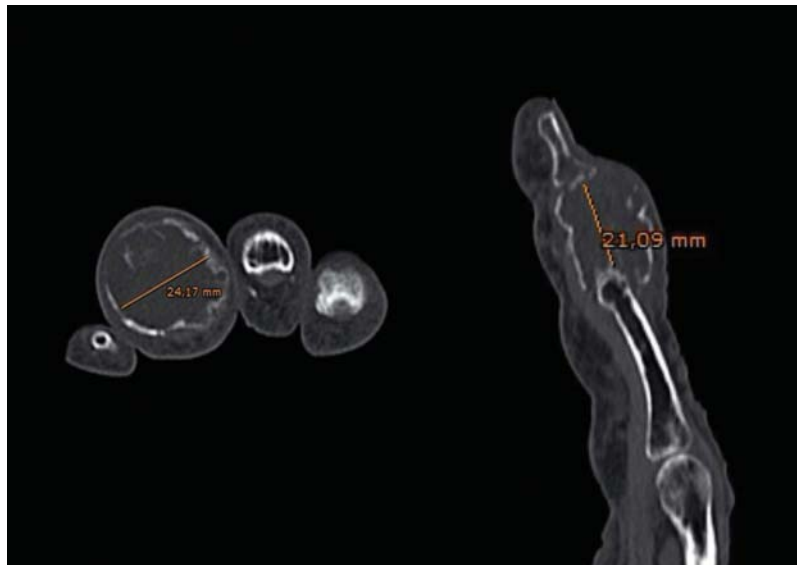


Figure 4 Helical computed tomography images revealing an expansive lesion at the middle phalanx of the fourth finger of the hand (explanation in text).

width is called protruding enchondroma and a differential diagnosis with chondrosarcoma is required.

The usual treatment for an enchondroma is curettage and defect filling with autologous tissue or a bone replacement.

The skeletal chondrosarcoma family is a heterogeneous group of malignant mesenchymal bone tumors characterized by chondroid matrix production. Primary chondrosarcomas are often located in the pelvis, femur and proximal humerus, but are very rare in hand bones, with a frequency of 0.5 to 3.2% of all chondrosarcomas. In addition, these hand tumors present a low risk of either primary or secondary metastasis (1.8%) in contrast to other locations (18%), and they are not life-threatening. Its small malignancy potential relates to tumor biology. Its K_i-67 index (associated with the cell proliferation phase) is lower compared to other locations; the same is true for p53.² Their location facilitates detection with a smaller size, allowing for radical treatment.

For hand chondrosarcomas, mean age at presentation (67 years old) is higher compared to other locations, and there is a slight predilection for females. These tumors are located in phalanx and metacarpal bones in 60% and 40% of the cases, respectively, and present with cortical destruction and tissue extension.² The most affected finger is the 5th finger, whereas the least involved finger is the fourth finger, as in our clinical case. In cases with distal phalanx compromise, the first finger is the most affected one.

Secondary sarcomas may derive from isolated osteochondromas and multiple hereditary osteochondromas, synovial chondromatosis, fibrous dysplasia, Paget disease, enchondromas, and multiple enchondromatosis, such as Ollier disease and Maffucci syndrome; in addition, they may arise after radiotherapy. Secondary chondrosarcomas account for approximately 1% of all malignant bone tumors.³ Of all these pathological conditions, the most common precursor for chondrosarcomas is osteochondroma, with a variable transformation incidence in revised series.

The malignant transformation of a solitary enchondroma is infrequently reported in the literature. In 1990, Nelson⁴ presented 18 cases described in the literature, but only those reported by Wu⁵ and the author himself are considered good documentations of the radiographic and/or histological transformation of an enchondroma into a chondrosarcoma. Subsequently, other authors reported the transformation from an enchondroma in a chondrosarcoma with years of radiological follow-up of a enchondroma, including with the development of pulmonary metastasis.⁶⁻⁹ Our case demonstrated radiologically the malignant transformation of an enchondroma diagnosed in 2011 into a low-grade chondrosarcoma 2 years later at the same location. Clinical and the radiological findings support the diagnosis of an enchondroma, although an anatomopathological confirmation would be interesting now in view of the subsequent evolution, because the radiological image of an initial chondrosarcoma can be confused with an enchondroma.

Pain is an important symptom, reported in 90% of chondrosarcomas and 43.8% of enchondromas. The medical history and radiological changes of pre-existing injury must also be considered. Any change in an old lesion, including up to 40 years in evolution as described by Wu, must be assessed

remembering the potential malignant transformation of an enchondroma.

The size of an enchondroma may be an important factor in its malignancy. In lesions ranging from 3 to 7 cm in size, there is a 2% to 3% of potential malignant transformation; these figures rise to 5% in lesions with 8 to 15 cm in size. Logically, we can deduce that a large enchondroma in the hand is uncommon because this is a very exposed location, in which the growth of an injury would be noted, resulting in a medical attention.

The differentiation between a phalangeal low-grade chondrosarcoma and an enchondroma is difficult for both pathologists and clinicians, with no well-defined criteria. Despite the low metastatic potential of chondrosarcomas, this distinction is critical because they require a more radical treatment than enchondromas. According to Welkerling,¹⁰ the distinction between enchondromas and chondrosarcomas is not clearly defined, but hand enchondromas present greater cellularity compared to other locations, with enlarged, double nuclei. Some authors have suggested the differentiation of enchondromas and low-grade chondrosarcomas using a DNA cytometric analysis of nuclear changes, including nucleus size and polymorphism, always supported by clinical and radiological findings.

Regarding treatment, radical excision is recommended since limited surgical procedures result in a high recurrence rate for chondrosarcomas (up to 12.5%).¹¹ Conservative treatment in this location is difficult due to the proximity of hand plans, which facilitate tumor extension to other compartments.

The amputation of the affected finger is the correct surgical treatment to avoid local recurrence or distant metastasis. If this intervention is not carried out, a careful follow-up of the patient is warranted.

As a conclusion, we must remember that enchondromas may evolve to malignant degeneration in chondrosarcoma. Although unusual, there are some cases recorded in the literature, and such transformation may be considered in our therapeutic action.

Conflicts of Interests

The authors declare that have no conflict of interests.

References

- 1 Campanacci M. Bone and soft tissue tumors. Springer-Verlag, WienNew York1999
- 2 Bovée JV, van der Heul RO, Taminiou AH, Hogendoorn PC. Chondrosarcoma of the phalanx: a locally aggressive lesion with minimal metastatic potential: a report of 35 cases and a review of the literature. *Cancer* 1999;86(09):1724-1732
- 3 Hogendoorn PCW, Bovee JM, Nielsen GP. Chapter 15:Chondrosarcoma (grades I-III), including primary and secondary variants and periosteal chondrosarcoma. In: Fletcher CDM, Bridge JA, Hogendoorn PCW, Mertens F(eds). World Health Organization (WHO) classification of tumours of soft tissue and bone. 4th edition, vol. 5 International Agency for Research on Cancer (IARC) Press, Lyon: France; 2013:264-268
- 4 Nelson DL, Abdul-Karim FW, Carter JR, Makley JT. Chondrosarcoma of small bones of the hand arising from enchondroma. *J Hand Surg Am* 1990;15(04):655-659

- 5 Wu KK, Frost HM, Guise EE. A chondrosarcoma of the hand arising from an asymptomatic benign solitary enchondroma of 40 years' duration. *J Hand Surg Am* 1983;8(03):317-319
- 6 Peiper M, Zornig C. Chondrosarcoma of the thumb arising from a solitary enchondroma. *Arch Orthop Trauma Surg* 1997;116(04):246-248
- 7 Schauer H, Fiedler B, Walker B, Müller C. [Secondary malignant transformation of an enchondroma of the hand]. *Handchir Mikrochir Plast Chir* 2006;38(03):188-193
- 8 Ozcanli H, Alimoglu E, Aydin AT. Malignant transformation of an enchondroma of the hand: a case report. *Hand Surg* 2011;16(02):201-203
- 9 Müller PE, Dürr HR, Nerlich A, Pellengahr C, Maier M, Jansson V. Malignant transformation of a benign enchondroma of the hand to secondary chondrosarcoma with isolated pulmonary metastasis. *Acta Chir Belg* 2004;104(03):341-344
- 10 Welkerling H, Werner M, Delling G. Zur histologischen Gradeinteilung der Chondrosarkome. Eine qualitative und quantitative Analyse an 74 Fällen des Hamburger Knochtumorregisters. *Pathologe* 1996;17(01):18-25
- 11 Essadki B, Belabidia B, Fikry T, et al. [Chondrosarcoma of the hand. Diagnostic and therapeutic discussion (three case reports)]. *Chir Main* 2001;20(02):164-171