

Ultrasonic cavity preparation using CVD coated diamond bur: A case report

Beatriz Tholt de Vasconcellos¹
Jeffrey Y. Thompson²
Manoel Roberto de Paula Macedo³
Janaína Monalisa de Oliveira Maia¹
Margareth Oda⁴
Narciso Garone-Netto⁴

ABSTRACT

Before any restorative procedure can be undertaken a proper cavity preparation is required. This clinical step is the mechanical alteration of the tooth to receive a restorative material with which a satisfactory form, function and the esthetics of the tooth will be established. In recent years improvements in materials and techniques have been devised and new technologies are now available for this purpose. The aim of the present study is to report two clinical cases in which a CVD coated diamond bur coupled to an ultrasonic handpiece is used in dental preparation. This technique provides an accurate and conservative tooth preparation with ideal access and visibility and because of enhanced efficiency can also play a role in eliminating some of the patient discomfort of the dental treatment. (Eur J Dent 2013;7:127-132)

Key words: Dental cavity preparation; ultrasonics; smear layer; CVD bur

INTRODUCTION

As an aftereffect of the evolution of man and his eternal quest for time-efficient, effective and practical instruments and technology, dental practice has had its share of profit as well. Advancements in dental materials lead to new restorative

principles. The classic systematic procedures of cavity preparation have resulted in a more tissue-saving way of treatment determined by one underlying theme "adhesive dentistry".

The possibility of bonding dental materials to enamel and dentin has brought forward significant developments of dental equipment together with improved sources of energy and means for holding and controlling the cutting instruments. In the 1870's the introduction of the electric motor as a power source was one of the most significant advances. After that, cutting techniques were revolutionized when diamond burs capable of cutting enamel were produced.¹

Conventional diamond burs are the most common rotary instruments used in the dental office and dental laboratory. Conventional diamond burs are made by plating small industrial or mineral

- ¹ Department of Dentistry, Universidade Veiga de Almeida, Rio de Janeiro, RJ, BRAZIL
- ² Department of Prosthodontics, College of Dental Medicine, Nova Southeastern University, Ft. Lauderdale, USA
- ³ Oregon Health and Sciences University, USA.
- ⁴ Department of Operative Dentistry, School of Dentistry, University of São Paulo, SP, BRAZIL

- Corresponding author: Dr. Beatriz Tholt de Vasconcellos
Rua Paissandú, n.385 apto 301 -Flamengo - Rio de Janeiro
CEP: 22210-080, BRASIL
Tel: +55 21 25748871
Fax: +55 21 35026057
Email: biatholt@hotmail.com

diamond particles on stainless steel shanks using a galvanic process. These conventional diamond burs show several limitations such as the heterogeneity of grain shapes, the difficulty of automation during fabrication, the decrease of cutting effectiveness due to repeated sterilization, and short functional lifetime. An additional shortcoming may be represented by the potential release of Nickel (Ni) ions from the metallic binder into the body fluids.²

According to the literature, clinical performance of abrasive instruments depends on the size, spacing, uniformity, exposure and bonding of the diamond particles, so, the significant loss of diamond particles during cutting procedure is an undesirable factor.²

At present, there are some alternative methods of cutting enamel and dentin. Air abrasive instruments for example, developed in the mid 1950's, and approved by the FDA in 1992, have not reached widespread clinical acceptance because of the difficulty of eliminating residual aluminum oxide dust. Another alternative method is the use of laser cutting. The search for a laser to cut hard tissue began with Dr. Leo Goldman's research in 1964 and subsequent research has identified many laser wavelengths for possible use in dentistry. Presently, the Er:YAG laser's ability to ablate dental tissue efficiently, owing to transmission of specific wavelengths absorbed by water and hydroxyapatite, is regarded as the most efficient laser.³ The general lack of knowledge of many dental professionals regarding this technique and the cost of the equipment has restricted its use. This technology is available to the clinicians, but can only be used effectively provided that dentists have the scientific information necessary to use them

appropriately, and are aware of their advantages as well as their limitations.

Although the use of the ultrasonic devices for dental preparation is a fairly recent and updated technology, ultrasonics have been part of the clinician's everyday routine for some time and are easily utilized and accepted.^{4,5} Recently, a special diamond coated bur coupled to an ultrasonic handpiece for dental applications was developed at the "Instituto Nacional de Pesquisas Espaciais" - INPE - Brazil, by coating a molybdenum substrate through a Chemical Vapor Deposition (CVD) process. Hereafter we will refer to that device as a CVD bur, as labelled by the manufacturer (CVDentus - Brazil).

Developed from a continuous diamond film, this bur is characterized by a pure diamond cutting surface without a metallic binder between crystals (Figure 1). These burs can be adapted by an appropriate mandrel to almost any ultrasonic handpiece system commercially available, producing a cutting speed about half that of a conventional rotary instrument.^{5,6} The aim of this study is to report two clinical cases in which CVD burs are used for cavity preparation.

CASE REPORT NUMBER 1

In the clinical case number 1 (Figure 3), esthetic deficiencies and secondary caries, detected by a previous bite-wing radiographic exam were the reasons for replacement of the amalgam restorations with resin composite. The removal of the amalgam restorations in a maxillary pre-molar and first molar was carried out using a CVD bur (cylindrical shaped point - Figure 4). The adjacent tooth and soft tissue were protected by a plastic matrix, and not harmed by the CVD bur (Figure 5).



Figure 1a. Diamond coated CVD bur.




Figure 1b. Pure diamond cutting surface of a CVD bur - SEM Image.



Figure 2. Diamond CVD burs of different shapes and sizes.

The patient did not request or require anesthetic during the procedure, which is a major advantage of this approach. An inverted cone shaped CVD bur was used to remove the amalgam from the retention areas. Ultrasonic CVD burs were used under constant water cooling, but the amount of water released by this equipment is much less than by conventional rotary instruments, as it produces less heat. This offers minimal risks of pulp damage, and makes the visibility of the operation field better requiring less frequent interruption during the procedure (Figure 6).

Based on the amplitude of the handpiece movement, a different type of result is obtained, and for each bur, the manufacturer indicates the best amplitude to work with, which must be adjusted in the ultrasonic equipment by the professional. The authors present SEM images obtained in an in vitro previous study that demonstrated a typical cutting pattern that is expected to be seen in the prepared surfaces when working with CVD burs⁴ (Figure 7).

To confirm this pattern, the authors also investigated, in an in vitro research, dentin surfaces prepared with the CVD burs, by using an Atomic Force Microscope (AFM) – (Nanoscope IIIa - Veeco Instruments - Santa Barbara - California), operat-

ed in contact mode.^{7,13} The AFM obtained a three-dimensional image that illustrates the typical dentin surface that should be expected when working with this particular instrument (Figure 8). The qualitative results of the prepared dentin surface investigated in SEM and AFM, corroborates with other authors¹³ who have stated that CVD burs produce a characteristic dentin surface, where a thin smear layer is detected (Figure 9). For this reason, the authors selected a self-etch dentin adhesive (Adhese - Ivoclar Vivadent) that was applied according to the manufacturers' instructions.

As a clinical aspect of a bright wet layer was observed, light curing was conducted.⁸ The curing light used was a LED (Light Emitting Diode - Radian - SDI) with 1400 mW/cm² for 40 seconds (Figure 10), and the composite resin (4 Seasons - Ivoclar Vivadent - shade A2) was inserted in oblique increments.⁹ The superficial resin film was covered by a glycerine gel to prevent the formation of an oxygen-inhibition layer during the polymerization of the composite material.^{10,11} An AFM image of the surface of a polymerized 4 Seasons dental composite, when a glycerin gel is used, is presented in Figure 11. After light curing, the rubber dam was removed and occlusion checked. Neces-

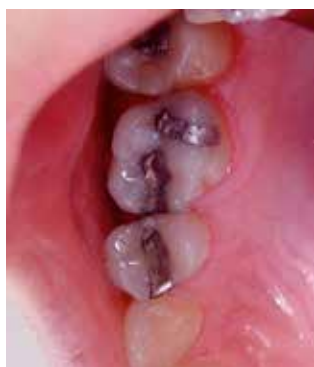

Figure 3. Clinical Case - Initial picture.

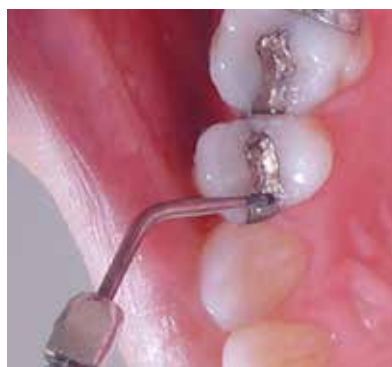

Figure 4. Cylindrical shaped CVD bur used for the removal of the amalgam restoration.

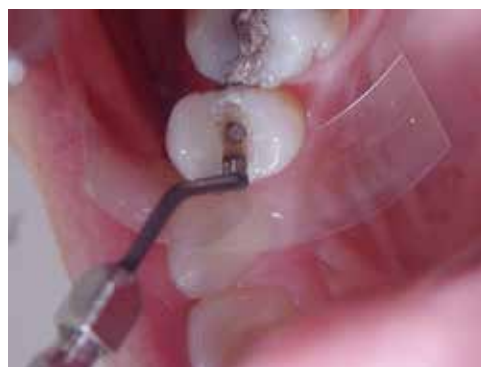

Figure 5. Plastic matrix positioned to protect soft tissue and the adjacent tooth.

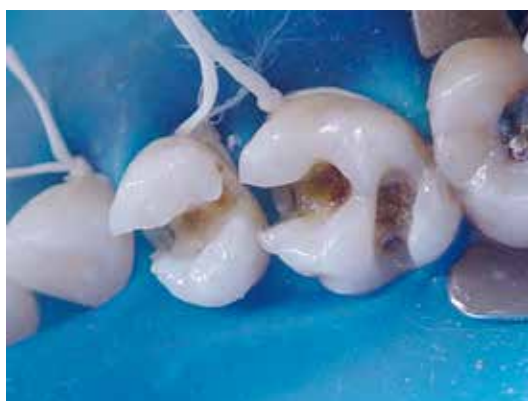

Figure 6. Clinical aspect after cavity preparation.

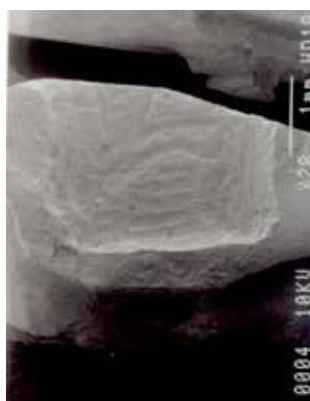


Figure 7. SEM Image of the prepared dentin surface.




Figure 8. AFM Image of the prepared dentin surface.

sary adjustments were done using CVD finishing burs. The restoration was polished with enhance silicone abrasive points followed by a felt disk, to achieve an excellent final result (Figure 12).

don't cut if they touch soft issues, allowing cavity preparations at gingival level without damaging this tissue.^{17,18}

CASE REPORT – NUMBER 2

The authors present case number 2 to demonstrate the important capability of the CVD burs of working at high inclination angles. Moreover, because of the pendular vibratory movements with nanometric variations of amplitude, these burs

DISCUSSION

Ultrasonic CVD burs are produced in a reactor in which a mixture of methane and hydrogen gases results in the formation of a single artificial diamond layer without space between the grains on the substrate (a molybdenum rod). Conventional facturing methods weld the diamond layer using a galvanic process to the substrate which results in a relatively large area between the diamond grains. This new technique allows the diamond to have sufficient adherence to the metal rod to bear the vibration effect of ultrasound.

According to the manufacturer, these tips have to be used under constant water cooling, but the amount of water released by this equipment is much less than by conventional rotary instruments which produces better visibility of the op-

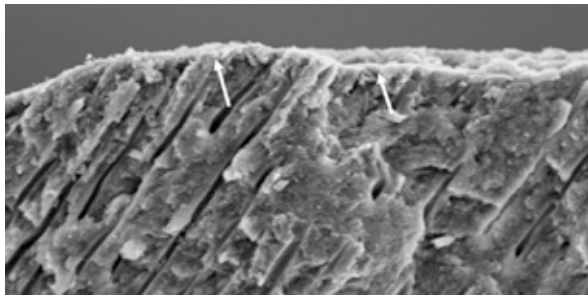


Figure 9. SEM Image of the obtained smear layer.

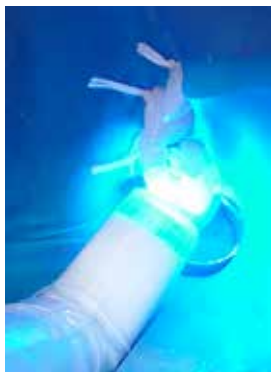

Figure 10. Light-Curing




Figure 11. AFM Image of the polymerized resin surface layer.

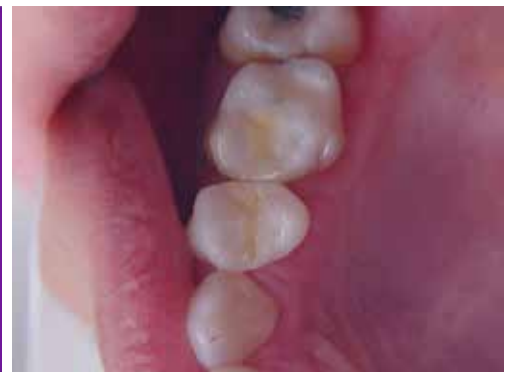

Figure 12. Clinical Case - Final pictures.

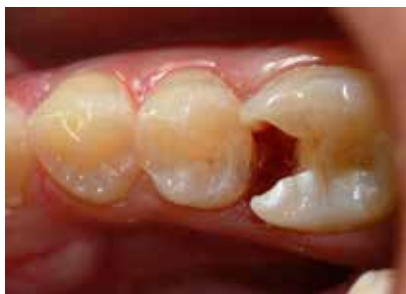

Figure 13. Clinical Case - Initial Clinical image of the first inferior molar.

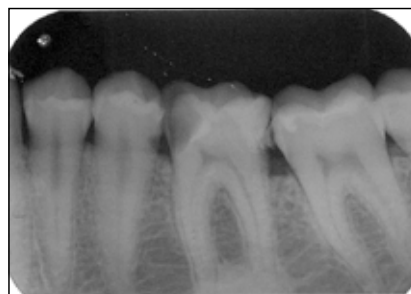

Figure 14. Initial X-Ray image



Figure 15. Cylindrical shaped CVD bur.

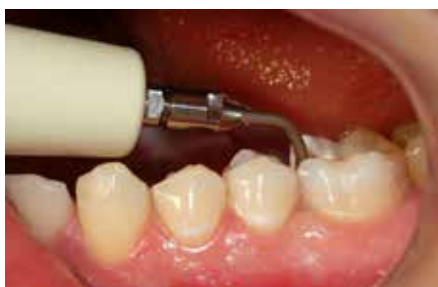

Figure 16. Cylindrical shaped CVD bur being clinically used.

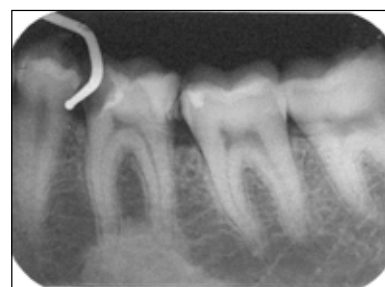


Figure 17. X-Ray demonstrating the access capability of the ultrasonic handpiece with the CVD bur.

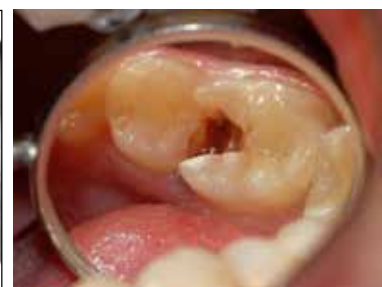

Figure 18. Clinical image after dental preparation.

eration field requiring less frequent interruption during the procedure and less heat.¹⁶

Researches that assessed intrapulpal temperature variation with different equipments presented controversial results. Higher intrapulpal temperature with ultrasound has been reported than with Er:YAG laser and high-speed rotation, while on the other hand other studies demonstrated no statistically significant difference in the temperature increase between high-speed rotation and ultrasound. However, other authors agree that the use of ultrasound can be considered safe, since this increase is lower than the critical value of 5.5°C, thus offering no risk of pulpal damage.^{12,14,15}

The main disadvantage related to this technique seems to be the time required for a complete ultrasonic cavity preparation that is significantly higher than that required for preparation using a high-speed hand-piece, approximately 4 times.^{2,16}

CONCLUSION

The ultrasound-coupled CVD bur was found to be an efficient method for tooth preparation in this instance. It was effective and safe for working close to the gingival margin, and improved the operating field visibility, because of access inclination angles that are not available when using a conventional handpiece.

The ultrasonic preparation procedure also potentially eliminates undesirable psychological effects associated with conventional rotary instrument noise. Consequently, the ultrasonic cavity preparation using CVD coated diamond bur offers promising clinical utility for certain dental procedures.

DISCLOSURE AND ACKNOWLEDGEMENTS

The authors are very grateful to Professor Rodrigo Prioli, DDS, MS, PhD, Department of Physics, PUC University, Rio de Janeiro, Brasil, for sharing his expertise. The authors have no financial interest in any of the companies whose products are included in this article.

I hereby grant all rights to publish photographs or other images of me in the above manuscript where I appear as a patient or subject without payment of any kind. I have been informed that any images of me that do appear may be modified.” – Beatriz Tholt de Vasconcellos.

REFERENCES

1. Sturdevant C, Roberson T, Heymann H, Swift Jr E. The art and science of Operative Dentistry. 3rd ed. St. Louis: CV Mosby; 1995.
2. Borges C, Magne P, Pfender E, Heberlein J. Dental diamond burs made with a new technology. *J Prost Dent* 1999;82:73-79.
3. Celiberti P, Francescut P, Lussi A. Performance of four dentine excavation methods in deciduous teeth. *Caries Res* 2006;40:117-123.
4. Macedo MRP. Características da superfície dentinária e do esfregação formado por instrumentos abrasivos diamantados: rotatório convencional, CVD rotatório e CVD por ultrassom. Estudo in vitro. São Paulo: Universidade de São Paulo; 2005.
5. Trava-Airoldi V, Corat E, Pena A, Leite N, Baranauskas V, Salvadori M. Columnar CVD diamond growth structure on irregular surface substrates. *Diamond Relat Mater* 1995;4:1255-1259.
6. Conde A. Estudo comparativo entre preparo cavitário ultrassônico e alta rotação. *RGO* 2004;52:169-172.
7. Conrado L, Trava-Airoldi V, Corat E. The use of a CVD - Coated Diamond Bur Coupled to an Ultrasound Handpiece in Dental Preparation. [acesso em: 2012-02-07]. Disponível em: URL: <http://www.cvd-diamante.com.br/ref-bibliograficas.htm>.2003.
8. Ritter A. Posterior resin-based composite restorations: clinical recommendations for optimal success. *J Esthet Restor Dent* 2001;13:88-99.
9. Lopes G, Vieira L, Araújo E. Direct Composite Resin Restorations: A review of some clinical procedures to achieve predictable results in posterior teeth. *J Esthet Restor Dent* 2004;16:19-32.
10. Peutzfeldt A, Asmussen E. Oxygen-inhibited surface layers on microfill pontic. *Acta Odontol Scand* 1989;47:31-33.
11. Rueggeberg F, Margeson D. The Effect of Oxygen Inhibition On An Unfilled/Filled Composite System. *J Dental Res* 1990;69:1652-1658.
12. Oliveira MAVC, Biffi JCG, Dechichi P. CVD [Chemical Vapor Deposition] - solution for control of temperature during cavity preparation? *Rev Odontol UNESP* 2009;38:363-369.
13. Lima L, Motisuki C, Santos-Pinto, Corat E. Cutting characteristics of dental diamond burs made with CVD technology. *Braz Oral Res* 2006;20:155-161.
14. Vanderlei A, Borges A, Cavalcanti B, Rode S. Ultrasonic versus high-speed cavity preparation: Analyses of increases in pulpal temperature and time to complete preparation. *J Prosthet Dent* 2008;100:107-109.

15. Mollica FB, Camargo FP, Zamboni SC, Pereira S, Teixeira S, Nogueira-Junior L. Pulpal temperature increase with high-speed handpiece, Er: YAG laser and ultrasound tips. *J Appl Oral Sci* 2008;16:209-213.
16. Predebon JC, Flório FM, Basting RT. Use of CVDentUS diamond tips for ultrasound in cavity preparation. *J Contemp Dent Pract* 2006;7:50-58.
17. Macedo MRP, Vasconcellos BT, Pereira Neto JP, Pereira M, Garone-Netto N. Pontas CVD e Ultra-Som como nova técnica cirúrgica. Aplicação no levantamento de seio maxilar. *Clínica-International J Braz Dent* 2006;2:44-47.
18. *Clorovale Diamantes: CVDentus®* [online]. [acesso em: 2012-02-07]. Disponível em: URL: <http://www.cvdentus.com.br>.