

Original Article

Three-year experience of hypospadias surgery: Bracka's method

C. Ramanathan

Department of Plastic and Reconstructive Surgery, The James Cook University Hospital, Marton Road, Middlesbrough, United Kingdom TS4 3BW

Address for correspondence: C. Ramanathan, Department of Plastic and Reconstructive Surgery, The James Cook University Hospital, Marton Road, Middlesbrough, United Kingdom TS4 3BW. E-mail: c.ramanathan@ntlworld.com

ABSTRACT

This is the author's experience of hypospadias reconstruction using Bracka's technique (mainly) over a period of three years. A total of 98 procedures related to hypospadias were done in three years. The surgical technique is described. In the author's hand, Bracka's technique gives good result both functionally and in appearance. Its versatility enables its use in all types of hypospadias with consistently reproducible results with minimal complications. At the end of the second stage a circumcised penis with natural looking vertical slit neo-meatus at the apex of the glans is produced.

KEY WORDS

Bracka's method, hypospadias, two-stage

INTRODUCTION

The goals of treatment in hypospadias surgery are to correct the chordee and to create an even-caliber neo-urethra terminating in a slit-like neo-meatus at the apex of the reconfigured glans restoring the normal anatomy and physiology with minimal complications. The use of preputial skin graft in hypospadias was described by Humby in 1941.^[1] The two-stage repair of hypospadias is widely attributed to Nicolle^[2] by many authors and his technique was based on descriptions by Byars^[3] and Cloutier.^[4] More recently the two-stage repair has been popularised by Bracka.^[5] In this series, two-stage hypospadias repair popularised by Bracka^[5] was used to treat most of the patients. In selected cases single-stage repair of Snodgrass^[6] was used.

The first stage of Bracka's method is a preparatory stage

for neo-urethral reconstruction and involves correction of chordee, glans split to create a gutter which is lined by skin graft harvested from the inner layer of the hooded prepuce. In the second stage, neo-urethral reconstruction is done by incising and tubing the grafted area terminating in a vertical slit of neo-meatus at the apex of the glans and trimming off the excess prepuce to make it look like a circumcised normal penis.

Timing of surgery

There are two windows of opportunity to perform surgery based on the following factors, namely the environment in which the patient will be managed, the anaesthetic risks, penile dimensions and the psychological effects of genital surgery.^[7] There is an increasing trend to perform surgical correction between six months to 18 months of age. The second option is between three to four years of age i.e., before the boy starts school.^[7] We use the second window period for

surgical correction. In our unit, the patient is seen as soon as the referral is made by the Family Doctor or Paediatrician and clinical assessment is done. The parents are given information about the diagnosis, treatment plan, risks, complications and long-term follow-up plan. Further reviews are done yearly till three years of age and when potty trained the first stage of the operation is carried out. During the waiting period, if required, the child is investigated for associated congenital anomalies with the help of the Paediatrician. The second stage of the operation is done four to six months after the first stage.

Surgical technique

First stage

All the patients are operated under general anaesthesia with caudal block. The caudal epidural anaesthesia makes the child recover smoothly with minimal risk of postoperative bleeding and haematoma in addition to an effective immediate postoperative analgesia. Then the detailed examination on the table is carried out regarding the position and size of abnormal meatus, the presence of chordee, the quality and width of urethral plate and the configuration of glans penis [Figure 1A]. 4/0 Nylon stay stitch is applied to the glans. Then the presence and degree of chordee is assessed [Figure 1B]. The author performs erection test only in selected cases [Figure 1C]. Meatal assessment is done using urethral dilators. Tourniquet is applied after dilatation. If required meatotomy is done to split the thin layer of urethra to the spongiosum-covered urethra. The suturing of urethral mucosa to skin is done after meatotomy using 6/0 vicryl Rapide. Two more stay sutures are applied on either side of the midline over the distal aspect of the glans which will be used as traction during glans split and later as first tie-over suture.

Release of chordee is done from the proposed neo-meatus to the ventral aspect of the abnormal meatus [Figure 1D]. From the sub coronal part of the vertical incision, lateral incisions on either side are done to correct the chordee. This is done by a combination of incision and excision of tissues using scalpel and fine scissors. The chordee correction is achieved in this manner in the majority of cases. In cases of residual chordee further correction is done by extending the sub coronal incisions to circumcoronal incision and stripping the penis. The author did not have to use dorsal plication for chordee correction. There is still some uncertainty about the long-term effects of dorsal plication in children.^[8]

After the chordee correction, the size of the defect is measured, appropriate marking made on the inner aspect of the prepuce [Figure 2A], incised and a thin skin graft elevated using sharp scissors. It is important that the graft is even and quite thin [Figure 2B]. The tourniquet is released and haemostasis is achieved. The donor site is closed using 6/0 Vicryl Rapide. The graft is sutured to the defect from the distal margin to proximally, snugly without any excess using 6/0 Vicryl Rapide interrupted and one or two quilting sutures [Figure 2C]. Then rolled paraffin gauze is placed on the graft and tied with Loop 4/0 Nylon suture [Figure 2D]. An indwelling 8 or 10F silastic urinary catheter is inserted for continuous bladder drainage which is fixed to the lower abdomen. A circumferential paraffin tulle-gauze and dressing gauze are applied around the penis.

The urinary catheter and dressings are removed after 48 hours and the patient is discharged home with advice to apply paraffin ointment over the tie-over dressing daily. After six to seven days the patient is reviewed in the Plastic Surgery Dressings Clinic and the tie-over dressing is removed by snipping the loop Nylon sutures in the middle and the graft is inspected (patient is given oral analgesics). In author's series all the grafts survived. The parents are advised to apply thin layer of paraffin ointment.

Second stage

The patient is usually reviewed in three months in the outpatient clinic to assess the patient and to plan the second stage which is usually done four to six months following first stage.

Under general anaesthesia with caudal block, the adequacy and quality of graft and chordee correction are assessed. Adequacy of the meatus is assessed by using dilators. A stay stitch is applied to the glans using 4/0 Nylon. Marking is done for tubing of urethra [Figure 3A]. The graft is incised [Figure 3B] and tubed over the silastic indwelling (8F or 10F) urinary catheter with a few interrupted marking 6/0 Vicryl suture [Figure 3C] followed by inverting continuous 7/0 Vicryl suture [Figure 3D]. The repair is protected and reinforced using an intermediate vascularised fascial layer dissected from the dorsal aspect following circumcoronal incision and stripping of penis [Figures 4A and 4B]. This vascular layer helps the healing process and avoids suture lines in contact with each other and thus reduces the risk of fistula formation.

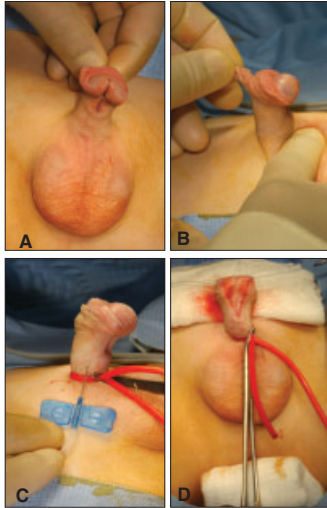


Figure 1: First stage: A: Marking for glans split. B: Chordee seen clinically. C: Artificial erection test. D: Glans split and Chordee released

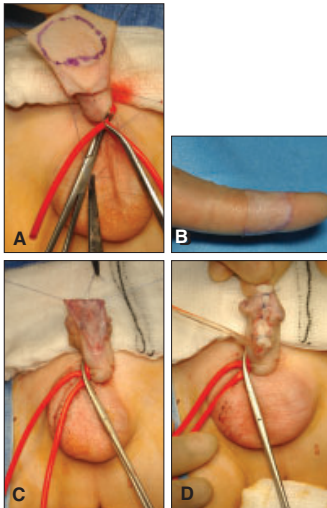


Figure 2: First stage: A: Prepuce skin harvest. B: Thin skin graft. C: Skin graft sutured to defect. D: Tie-over dressing

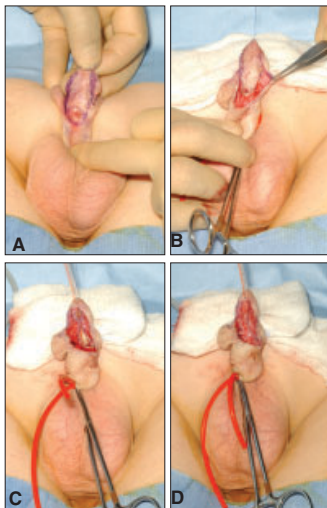


Figure 3: Second stage: A: Graft marked for tubing. B: Graft incised. C: Neo-urethra with interrupted sutures. D: Neo-urethra complete with inverting suture

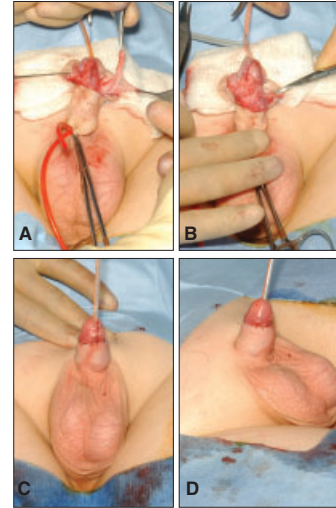


Figure 4: Second stage: A: Intermediate protective layer. B: Intermediate layer covering neo-urethra. C: Final result. D: Final result lateral view

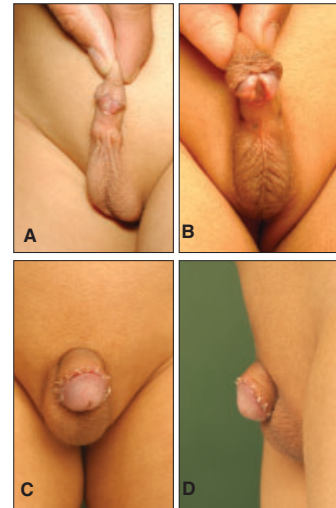


Figure 5: Another example: A: Distal Hypospadias with chordee. B: First stage - Post op. C: Second Stage - Post op. Front view. D: Lateral view

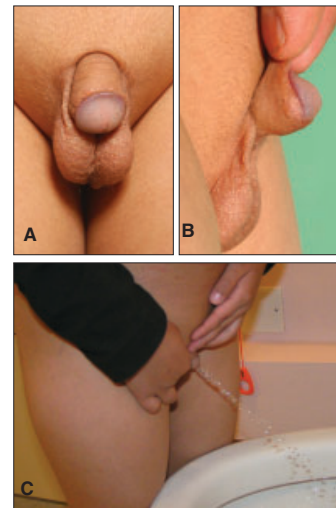


Figure 6: 3 year follow-up of the patient in Fig.5 A: Front view B: Lateral view C: Patient passing urine normally

Then the glans wings are rotated to reconfigure it using 6/0 Vicryl and 6/0 Vicryl Rapide. Tourniquet is released and haemostasis done at this stage, and further assessment is done of the remaining skin envelop by draping the shaft. The excess tissue is excised and sutured using 6/0 Vicryl and 6/0 Vicryl Rapide [Figure 4C] with or without vertical suture line on the shaft of the penis. At the end it looks almost like a normal circumcised penis [Figure 4D]. Paraffin tulle-gauze and dressing gauze are applied around the penis. Recently, the author has started using just a layer of paraffin ointment and leaving it open. The urinary catheter is fixed on the lower abdomen with a "mesenteric type" of tape fixation so that the catheter is directed upwards away from the ventral suture line. The patient is given a one-week course of oral antibiotics Coamoxiclav (a mixture of Amoxicillin and Clavulanic acid). The urinary catheter is removed in a week and the patient discharged home after voiding urine satisfactorily which is observed (the flow and leakage, if any) by the Nursing staff. Usually, the patient is reviewed in the clinic the following week, three months and annually thereafter.

MATERIALS AND METHODS

This paper analyses 98 procedures related to hypospadias over three years (2002-2005) performed by the author in this unit. The author took over an existing practice from the retirement of a Plastic Surgery colleague with an interest in hypospadias surgery. Out of 98 procedures, 35 were first stage (Bracka's) procedures, 44 second stage (Bracka's) procedures, two single-stage (Snodgrass) procedures, one meatal advancement and glanduloplasty, eight posthypospadias trimming of prepuce for patients treated by the predecessor (the author routinely performs this in the second stage), three urethral fistula repair (one of which was from the predecessor), four neo-meatal dilatation and one correction of residual chordee with glanduloplasty and circumcision [Table 1].

Table 1: Details of operative procedures

Procedure	2002-3	2003-4	2004-5	Total
I stage (Bracka)	8 (4Redo)	12 (1Redo)	15 (1Redo)	35
II stage (Bracka)	13	15	16	44
Single-stage	2	0	1	3
Posthypo.Circ	4	2	2	8
Fistula repair	1	1	1	3
Meatal dilatation	0	2	2	4
Residual chordee	0	0	1	1
Total	28	32	38	98

RESULTS

The average age at which first stage was undertaken in this series was three years and four months (Chart 1) excluding two cases (seven years and 37 years). Most of the patients were operated before three years of age. More than half required meatotomy in the first stage as there was a thin ventral band at the meatus without the spongiosum. In all patients inner prepuce skin graft was used except the adult patient who was already circumcised and hence post-auricular skin graft was used. The better alternative for those patients who have had circumcision would be buccal mucosal graft. The average age of the patients when the second stage operation was performed was four years and three months (Chart 2). Two-thirds of the patients were operated before four years of age.

Most of the patients had abnormal meatus located distally

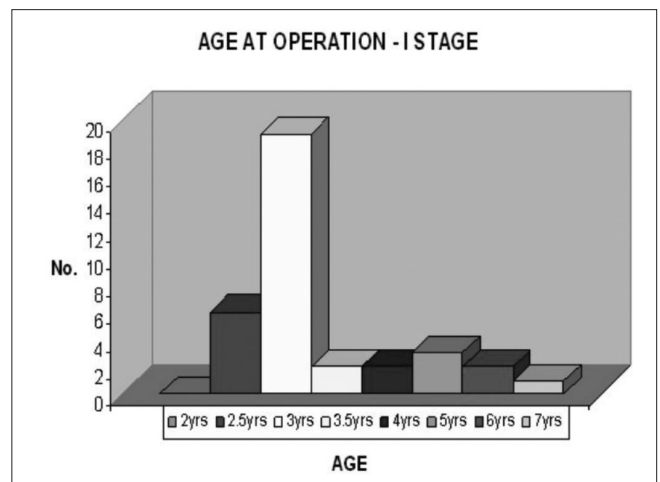


Chart 1: Age at operation - First Stage

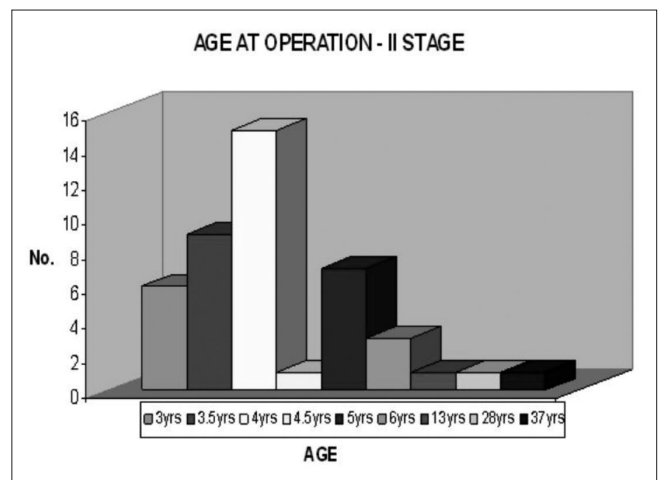


Chart 2: Age at operation - Second stage

(Chart 3) which includes mid-shaft, distal shaft and sub coronal groups. There was significant chordee seen in most of the patients.

Two patients had Snodgrass method of single-stage correction. The author chooses Snodgrass repair for distal hypospadias when there is no significant chordee with wide urethral plate and a deep grooved, well-developed glans. The principle and technique of Snodgrass^[6] is similar to the second stage of Bracka's technique in addition to incising the urethral plate for tension-free reconstruction of neo-urethra. In retrospect, some of the patients who had to undergo redo first stage in this series could have been managed by "Snodgraft" technique^[8] by performing a midline dorsal incision of the old graft, quilting a new free graft into the defect and tubularizing the neo-urethra as described by Manzoni and Bracka.

Eight cases of posthypospadias trimming (circumcision) were done for the patients treated before the author joining the unit. The author routinely performs this as part of the second stage. Out of the three cases of fistulae treated in this series, one case was from the previous series.

The follow-up in this series ranged from three months to three years and an example of one of the patients with distal hypospadias is shown in [Figure 5 A-D] and [Figure 6 A-C], showing three-year follow-up views including patient passing urine normally.

DISCUSSION

Bracka's two-stage correction is a very versatile

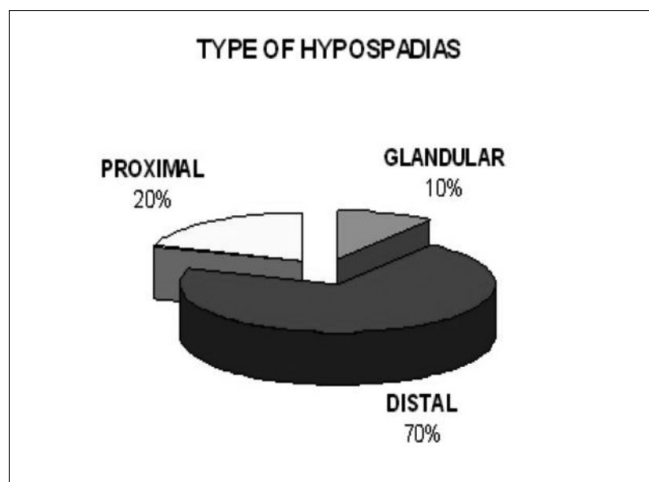


Chart 3: Location of meatus

technique which can be used to correct all types of hypospadias. This gives good results both in terms of restoration of normal appearance and normal function with minimal complications. The author has started to use Snodgrass method in selected suitable cases.

The successful reconstruction depends on proper planning, gentle handling of tissues with fine instrumentation, usage of fine suture materials, inverting sutures of neo-urethra and usage of intermediate vascular layer of tissues.^[8] It is also important that the surgeon should have a sub-specialty interest of hypospadias.^[7] It will be an advantage to have a Nurse practitioner with special interest in the care of hypospadias who would be available to offer help, advice and support to the patients and parents. The author follows up the patients regularly till their mid-teens (sexual development) as suggested by Bracka.^[9] This will offer psychological support, identify any occult fistula becoming obvious and the changes occurring with growth and development of penis, especially during puberty which might require further surgical treatment. Early discharge will lead to "sweeping the problems under the carpet".^[7]

CONCLUSION

The author considers that the hypospadias surgeon will be able to restore the normal anatomy and physiology with minimal complications in all types of hypospadias by using one of the three options. First option of Urethral Plate Tubularisation (as in Snodgrass or second stage of Bracka's method) is done when the urethral plate does not require transection and its axial integrity can be maintained. Second option of Urethral Plate Augmentation is done when the urethral plate is narrow and inelastic requiring augmentation with free graft and tubularisation (as in "Snodgraft"). The third option of Urethral Plate Substitution (Bracka's Two-Stage) is done when there is significant chordee requiring full circumferential substitution urethroplasty in two stages.

REFERENCES

1. Humby G. A one-stage operation for hypospadias. *Br J Surg* 1941;29:84-92.
2. Nicolle FV. Improved repairs in 100 cases of penile hypospadias. *Br J Plast Surg* 1976;29:150-7.
3. Byars LT. A technique for consistently satisfactory repair of hypospadias. *Surg Gynecol Obstet* 1955;100:184-90.
4. Cloutier AM. A method for hypospadias repair. *Plast Reconstr Surg* 1962;30:368-73.

5. Bracka A. A versatile two-stage hypospadias repair. *Br J Plast Surg* 1995;48:345-52.
6. Snodgrass WT. Snodgrass technique for hypospadias repair. *BJU Int* 2005;95:683-93.
7. Manzoni G, Bracka A, Palminteri E, Marrocco G. Hypospadias surgery: When, what and by whom? *BJU Int* 2004;94: 1188-95.
8. Telfer JR, Quaba AA, Kwai Ben I, Peddi NC. An investigation into the role of waterproofing in a two-stage hypospadias repair. *Br J Plast Surg* 1998;51:542-6.
9. Bracka A. A long-term view of hypospadias. *Br J Plast Surg* 1989;42:251-5.

Author Help: Online Submission of the Manuscripts

Articles can be submitted online from <http://www.journalonweb.com>. For online submission articles should be prepared in two files (first page file and article file). Images should be submitted separately.

- 1) **First Page File:**
Prepare the title page, covering letter, acknowledgement, etc., using a word processor program. All information which can reveal your identity should be here. Use text/rtf/doc/pdf files. Do not zip the files.
- 2) **Article file:**
The main text of the article, beginning from Abstract till References (including tables) should be in this file. Do not include any information (such as acknowledgement, your names in page headers, etc.) in this file. Use text/rtf/doc/pdf files. Do not zip the files. Limit the file size to 400 kb. Do not incorporate images in the file. If file size is large, graphs can be submitted as images separately without incorporating them in the article file to reduce the size of the file.
- 3) **Images:**
Submit good quality colour images. Each image should be less than **100 kb** in size. Size of the image can be reduced by decreasing the actual height and width of the images (keep up to about 3 inches) or by reducing the quality of image. All image formats (jpeg, tiff, gif, bmp, png, eps, etc.) are acceptable; jpeg is most suitable. The image quality should be good enough to judge the scientific value of the image.
Always retain a good quality, high resolution image for print purpose. This high resolution image should be sent to the editorial office at the time of sending a revised article.
- 4) **Legends:**
Legends for the figures/images should be included at the end of the article file.