

**CME**

# Evolution of the functional repair concept for cleft lip and palate patients

**Jean Claude Talmant**

Clinique Jules Verne, 2-4 Route de Paris, 44300 Nantes, France

**Address for correspondence:** Jean Claude Talmant, Clinique Jules Verne, 2-4 Route de Paris, 44300 Nantes, France.

E-mail: jeanclaudetalmant@libertysurf.fr

## INTRODUCTION

The paradigm over the past fifty years has been that cleft lip and palate are the consequence of mesoderm deficiency, thus explaining both the poor potential of growth of cleft patients and their tissue defects. On the contrary an ancient French school has stressed the idea that normal function will result in normal growth, even in the cleft patient. Three generations of surgeons have spent their whole professional life thinking about the concept of functional repair in cleft patients. Victor Veau had been the first to say that our poor results are the consequence of our lack of knowledge. Delaire has clearly shown that we have to restore all the functions to allow normal facial growth, but this ambitious program is a long and difficult way. The science of morphology is very young and we are just becoming aware of the imperative necessity of nasal breathing, of the essential role of the teeth, particularly in the premaxilla, of the interaction of the different functions. We are now able to understand in depth the physiopathology of a cleft lip and palate and we have to forget the empiricism of the previous generations, to become rational.

The current situation in the world is well known. Western wealthy countries treat only a few cleft lip and palate patients compared to continents like Asia or Africa where

so many people need a repair. When treated, these patients are frequently operated on at any age, without a real follow up and assistance of a specialized team. Orthopedics, orthodontics, speech therapy are not easily available and to achieve a standard protocol is a rare opportunity.

All over the world, every cleft palate team should be concerned with the necessity to decrease the burden on the family and the patient and to give them the benefit of a good social life very early, before school age. Rather than to spend money and time in sophisticated procedures, we should urge the need to finalize a primary uni- and bilateral cleft lip nose and palate repair feasible in every socioeconomic circumstance and country, without preoperative orthopedics and with only standard orthodontics. Unfortunately, it will be a long wait before we reach this ideal protocol, but we believe that a better understanding of the imperative necessity of good function at the time of the primary surgery is the first step.

## CURRENT STATE OF CLEFT LIP AND PALATE TREATMENT

The last fifty years of papers, presentations, congresses, conferences and statistics have not contributed to an overall consensus. Our knowledge is progressing very slowly for many reasons. Some of them are easy to

This manuscript is the synthesis of two texts presented in the annual meeting of the Indian Society of Cleft Lip Palate and Craniofacial Anomalies (ISCLP and CA) - 23<sup>rd</sup>, 26<sup>th</sup> March, 2006 Guwahati - Assam:

1. Delaire philosophy conversion
2. The primary nasal breathing approach for cleft patients.

understand and quite acceptable. However it is surprising to note that 201 European cleft centers were performing 194 different protocols of treatment in 2000. In these teams the oldest procedures of pushback, leaving denuded bone to close the hard palate, were very popular despite their well known drawbacks. Fifty years of preoperative orthopedics have not established the proof of its real benefit in the long term, but new tricky procedures of preoperative orthopedics are presented as well as numerous smart cutaneous plasties for a nice lip or a nice columella, that change nothing or very little in depth. Empirical is the adjective which could summarize most of the attempts made to improve the results. We are in a labyrinth, yet we have not been lucky enough to open the real door. This is probably the main reason for the poor power of conviction of the work published during the previous decades and the fact that each team keeps on following its own protocol with stubbornness.

## IS THERE A RIGHT WAY?

The paradigm over the past fifty years has been that cleft lip and palate are the consequence of mesoderm deficiency, explaining the poor potential of growth of cleft patients and their tissue defect at the level of the premaxilla and the columella, particularly in bilateral cleft. On the opposite side an ancient French school has stressed the idea that normal function result in normal growth, even in the cleft patient. In 1928, Victor Veau,<sup>[1]</sup> a well known surgeon from Paris, wrote, after studying the gross anatomy of still born babies with clefts and the microanatomy in cleft fetuses: "I do believe that in the cleft patient the normal structures are present on either side of the cleft, only modified by the fact of the cleft. "According to him: "the treatment should be embryological surgery..." on each side of the cleft, the adequate structures, precisely identified, are anatomically repositioned, without any substitution by other tissue, which gives an imperfect result."

The logical conclusion of this concept is to consider that our poor results are not intrinsic to the cleft but more likely depend on our current lack of knowledge and skills.. It is not very comfortable to think that; moreover it is hard, but in the end much more stimulating! Probably our knowledge is at a standstill because we all have left unexplored something that might be essential. Yet there is an indispensable and permanent

function starting early in fetal life and working on until death to which we have given very little attention. Nasal breathing deserves to catch our attention and we have to think about it.

For Victor Veau and Jean Delaire, one of his followers and a maxillofacial surgeon from Nantes, the growth mechanisms are normal in cleft patients but they are operating in an abnormal relationship. This concept is supported by a few studies.

Mooney *et al*,<sup>[2]</sup> have brought an excellent argument in favor of this hypothesis: in cleft fetuses compared to normal fetuses, the hypoplasia of the premaxilla is noticeable only after the 14<sup>th</sup> week of the fetal life, 8 weeks after the cleft occurs. Actually this secondary hypoplasia is well explained by the change in fetal ventilatory dynamics which is the consequence of the cleft. We will discuss this below.

Ortiz Monasterio<sup>[3]</sup> in 1959 has shown that unoperated adult cleft patients have a good facial growth, even if they have mild deformities along the edges of the cleft which were in fact present at birth and then have changed in a logical way, as they are the consequences of dysfunctions. On the cleft side, the linguoversion of the temporary canine can only be made worse by mastication, with increasing lateral cross-bite of the small maxillary segment, lateral deviation of the mandible and progressive vertical shortening of the face on the cleft side. However, there is no doubt that these unoperated patients have a better facial growth than operated ones and that surgeons from Asia or Africa are aware of that because they have seen such patients.

Currently it is well known and taught in dental school that oral breathing leads consistently to non specific growth disorders of the face: like malocclusion of types Class II or Class III, open bite or a long face. Warren<sup>[4]</sup> has written in 1996 that 75% of complete uni- or bilateral cleft children are more oral than nasal breathers. Raphael<sup>[5]</sup> has published in 2002 that 60% of his complete unilateral cleft patients had a small maxilla after the growth spurt of adolescence. This high rate of facial growth impairment is not far from the rate of oral breathers in complete unilateral clefts published by Warren. Among cleft children only a few oral breathers escape the growth disturbances, despite orthopedics and orthodontics.

### **The functional approach: A definition**

Delaire,<sup>[6,7]</sup> who was very committed to the functional approach, has emphasized the importance of the muscle repair in front of the septum and anterior nasal spine. Like Scott, Delaire believes that the septum is the motor of facial growth. To anatomically reposition the interrupted lateral muscles in this area is therefore the main goal of the cleft lip nose repair. Actually we think that the functional approach is much more demanding than the simple layered closure with orbicularis muscle realignment adopted by other teams all over the world and termed functional repair of the lip.<sup>[8]</sup> This vision of the functional approach which keeps our whole mind on the repair of the muscles of the lip and the nostril sill is far too limited. Delaire has given in our opinion an excessive role to the septal traction model of growth and has not sufficiently stressed the function of nasal breathing. Those who will adopt his muscle repair as a recipe will frequently be disappointed and become suspicious about the philosophy that is behind it.

The functional approach is in fact a global concept. The goal is to restore all the functions concerned by the repair of the lip, the nose, the maxilla, the dentition and the palate. That means we have to restore properly, mastication in good occlusion, deglutition, speech, nasal breathing. We must not forget an essential function of the face which is communication. It needs to look good at rest with a good aptitude for normal movement and a symmetrical expression which are necessary for a good social life and self esteem. If all these functions have their importance and interact with each other, then the most important function with regard to facial growth is, in our opinion, nasal breathing.<sup>[9,10]</sup> Another point to stress is that the functions should be restored at the time of primary surgery to avoid dysfunction and postural adaptation which are so difficult to change into normal habit later and will continue their detrimental influence. This fact is well known in the field of speech and our experience is that it is absolutely the same in the field of nasal breathing.

The functional approach is a careful and permanent attempt to create the best esthetic and functional result. When we act locally we must always think globally.<sup>[11]</sup>

At any step of the primary treatment we must take into account these objectives and never forget that we operate on very fragile muscles, cartilaginous structures

and a cleft maxilla threatened by scarring, which also has to grow.

To get good function after primary anatomical repair we must leave the least scar we can. The only way we know to respect this demanding condition is to select in a rational way and very carefully, all the elements of the protocol:

- The best time to achieve this delicate primary surgery.
- The chronology of the different steps to take the benefit of the most active period of growth.
- The procedures allowing a precise and consistent repair, with few and well placed scars.

Then we have to control the healing process where it is necessary.

When doing so we can achieve a good result by 4 to 5 years of age with a child sleeping with its mouth closed and able to chew in good symmetrical occlusion. We don't see any reason to make a compromise and sacrifice speech to growth. The velar function can also be of good quality by 4 years of age and assure a good start in school and social life. Before undertaking the treatment and restore the normal anatomy, a good understanding of the pathological anatomy is necessary

### **The pathological anatomy**

Understanding of the pathological anatomy of cleft patients has made substantial strides forward recently in the fields of:

- The mechanics of the facial envelope<sup>[12]</sup>
- And the fetal ventilatory dynamics,<sup>[13]</sup> both studied by Jacques Talmant, my brother. Now with this vision of the functional anatomy we can explain all the morphofunctional consequences of a cleft occurring by the 37<sup>th</sup> day of fetal life.

### **THE FACIAL ENVELOPE**

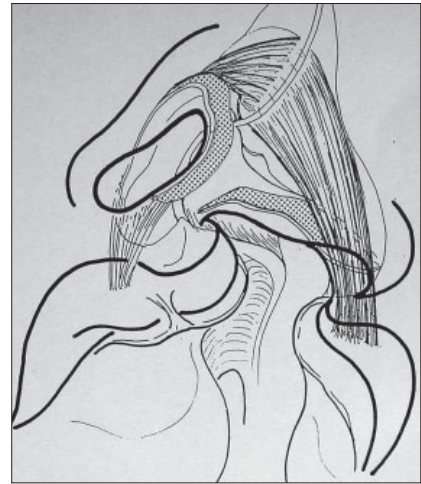
The facial envelope is the ensemble of soft tissue covering the face: skin, muscles and mucosa. This global concept allows a better grasp of their morphofunctional influences than studies limited to individual muscles or even the SMAS. The facial envelope changes according to the rule of the theory of elasticity. Bleschmidt has published the face of a 7 weeks old fetus which looks very sad with two deep paranasal folds extended vertically from the mandibular body to a place just above and

behind the nostril. At this time, there is no muscle activity and the two paranasal folds are well explained by the theory of elasticity. As soon as the oral split opens the facial envelope, the local stresses migrate laterally outside the commissure and concentrate vertically raising the two paranasal folds. The distribution of the forces inside the facial envelope plays an important role for the arrangement of the facial muscles. Shortly after the fusion of the nostril sill and upper lip, the individual precursors muscle cells migrate from the 2<sup>nd</sup> branchial arch toward the anterior face and mature. As soon as they are transformed into muscular cells they become contractile, they orientate themselves toward the axis of the local stresses like iron filings in a magnetic field. This phenomenon occurs as early as the seventh week of fetal life and is able to organize the fascicular arrangement of the facial muscles, which looks like a diagram of the forces acting on them. The first movement detected in the cephalic area is swallowing by the 10<sup>th</sup> week, so the fascicular arrangement of the facial muscle begins probably between the seventh and ninth weeks.

In the case of a cleft patient, the rupture of the facial envelope will change the distribution of the forces and in consequence the arrangement of the muscles. The lateral muscles are not only deprived from their insertion on the midline, but their disposition is different and should be known before undertaking the muscle repair. This mechanical phenomenon is also probably able to influence the control of the facial envelope on this part of the external nose, where the strong and abnormal draft of the fetal ventilatory dynamics separates the lower cartilage from the nasal capsule, leaving as witness of this tear the sesamoid cartilages. This region is called the nasal valve and works like a nozzle with an adaptable neck.

At the time the cleft occurs, the only skeletal framework is the nasal cartilaginous capsule.<sup>[14,15]</sup> The earliest points of ossification will appear two weeks later when the muscle precursors are already present. So all the bone formation will take place at the direction and under the influence of asymmetric muscular forces.

In a unilateral cleft, the balance of the facial envelope is changed on both sides: the midline with the anterior border of the septum is deviated toward the non-cleft side as early as the 8<sup>th</sup> week of fetal life.



**Figure 1:** The nasalis muscle on the cleft side. The superior head is the transverse muscle. The myrtiform muscle is the inferior head. It is the strongest anterior anchorage point of the facial envelop on the cleft side

On the cleft side the facial envelope loses its anterior support in the midline and collapses influencing in the same way the underlying bony structures. The vestibular lining of the nostril is stretched and vertically elongated. The lower lateral cartilage normally overlying the upper lateral cartilage is pulled inferiorly from the upper lateral cartilage with a considerable distension of the nasal fold. Into the space thus created, the nasalis muscle slips down. The nasalis muscle is the only muscle of the face which has two fixed insertions [Figure 1]. Its superior head is the transverse muscle. It lies on top but remains separated from the upper lateral cartilage after which it sweeps down around the lower lateral cartilage, joining with the myrtiform to insert onto the premaxilla and into the floor of the nose. In the complete unilateral cleft, because of its two fixed insertions, only the nasalis muscle resists the posterior displacement of the SMAS and becomes relatively more anterior with regard to the other structures. It covers the inferior part of the lower lateral cartilage and forces the lateral crus to twist inferomedially. In fact the nasalis muscle is now the strongest anterior anchorage point of the facial envelope on the cleft side, a new role which had already been pointed by Victor Veau more than 75 years ago. Between the 10<sup>th</sup> and the 15<sup>th</sup> week of fetal life the deformity of the cleft lip nose is complete and is the same as in a new-born.

The rest of the nose is also deformed. The dorsum and all the structures of the midline are deviated toward the non-cleft side. The septum forms a strong convexity in the cleft. It is impossible to explain the complexity of this deformity just by the rupture of the facial envelope,

but with the morphogenic role of the ventilatory dynamics we can understand that the high pressure of the amniotic fluid in the non cleft nasal fossa compared to the cleft side raises very hypertrophic inferior and middle turbinates and pushes the septum toward the cleft side, which may be very narrow. On the opposite side to the cleft the nasal fossa is distended like a balloon and filled up by the turbinates.

## THE FETAL VENTILATORY DYNAMICS

It is difficult to deny a role to the early septal traction model of midfacial growth<sup>[16]</sup> during embryological life. The septal growth is transmitted by the Latham septopremaxillary ligament which links the septum to the premaxilla. The ligament and its sagittal expansion receive the insertion of the nasolabial muscles, distributing their forces directly to the periosteum of the premaxilla and stimulating the interincisive suture. For Delaire the septum sliding on its vomeromaxillary gutter is the main motor of forward growth during fetal life and remains essential after birth. For this reason Delaire<sup>[17]</sup> believes that the surgical use of vomerine mucosa can hinder the forward sliding of the vomer on its maxillary surface and the forward growth of the maxilla and rejects such procedures. For him, in bilateral cleft, the nasal floor must be restored by suturing the nasal mucosa of both palatal shelves without touching the vomer. In a unilateral cleft there is no ideal solution to escape a direct suture between the vomer and the lateral nasal mucosa, but closure in one layer with a vomer flap is, for Delaire, a poor option.

At present we know that fetal ventilatory dynamics are more likely to be the main motor of facial growth before birth. As suggested by the recent data acquired by means of colour Doppler ultrasound, from the 12<sup>th</sup> week of embryological life, ventilatory dynamics begins, with inspiration and expiration 50 times a minute but is not consistent like aerial ventilation. Nevertheless at birth, the new born has already breathed through the nose for the last 6 months! At the level of the respiratory tract, from the nose to the lungs, the amniotic fluid is much more morphogenic than air as it is incompressible and has a very high density compared to air. When it is ejected toward the amniotic cavity the expiratory flow is reflected against the nasal capsule before contracting and flowing out of the nostril. At each expiration, the nasal capsule is pushed forward and pulls the whole facial

envelope and the septopremaxillary ligament and in consequence the maxilla. In case of a cleft, the pressure decreases in the cleft nasal fossa and this explains why the hypoplasia of the premaxilla and maxilla is noticeable after the 14<sup>th</sup> week of the embryologic life. There are other consequences of the gradient of pressure between the two sides in cleft patients. We have described the deformity of the septum and turbinate in a complete unilateral cleft. These deformities are very consistent in a unilateral cleft, even in incomplete clefts. The flattening of the dome of the lower lateral cartilage, of the upper lateral cartilage and in fact of the whole face on the cleft side relates to the loss of pressure of the amniotic fluid in the cleft nasal fossa.

## THE BILATERAL CLEFT LIP NOSE DEFORMITY

In our opinion,<sup>[18,19]</sup> the bilateral cleft lip nose deformity is the duplication on both sides of the unilateral cleft lip nose deformity, with the great advantage of symmetry. In a complete bilateral cleft the median structures are not deviated.

The short columella doesn't reflect a particular hypoplasia. In a complete unilateral cleft, we have measured and compared the length of the cleft nostril and the circumference of the non-cleft nostril. They are equal and we know how to correct the short columella in unilateral cleft.

In bilateral cleft, the extreme projection of the premaxilla increases the effect of separation on the midline. The lower lateral cartilages are pulled apart from the septum and from each other like in the most severe unilateral clefts. The columella is unzipped as mentioned by McComb<sup>[20,21]</sup> and to restore the columella we have just to zip it up. Currently there is no doubt that the columella is inside the broad and flat tip of the nose, from where we can extract it by proper repositioning of the lower lateral cartilages as we have done for the last 9 years, at about the same time as C. Cutting<sup>[22]</sup> but after Mulliken.<sup>[23]</sup>

### The essential role of teeth<sup>[24]</sup>

When dealing with the alveolar cleft for pre operative orthopedics or for its closure with gingivoperiosteoplasty and bone graft, we must not forget that the width of the piriform aperture is closely related to the width between both canines. There is a constant relation

between the volume of the premaxilla and the number and volume of the incisor teeth.

In fetal life, the width of the piriform aperture is the same as the width of both tooth buds of the temporary central incisor teeth. The agenesis of one temporary central incisor bud is associated with a very narrow piriform aperture and acute breathing problems at birth. After eruption of the temporary central incisor there is a temporary narrowing of the piriform aperture and of the space between both alar bases. The same phenomenon is observed after eruption of the permanent central incisor. At each time, the decrease of tension in the premaxilla is favorable to the eruption of the more palatine lateral incisor tooth. This last tooth contributes to give more width to the piriform aperture and the interalar distance. The width of the piriform aperture is almost stabilized at puberty. This means that it is earlier for girls where, after 12 years of age there is no significant change in the width of the piriform aperture. The treatment should take this sex linked difference into account.

In a cleft patient, the tooth buds of the temporary and permanent lateral incisive teeth are frequently missing. We must preserve the space of the lateral incisive tooth if we want to preserve the width of the piriform aperture. To close the alveolar cleft before the temporary dentition is, for this reason, very harmful.

The central incisor teeth are also frequently in rotation when they are erupting and this particularity is striking in bilateral clefts. In the globular premaxilla, there is no place for a normal transverse alignment of the teeth and the lateral tooth buds are behind the central one, when present. The treatment should take this malposition into account and lead to a gingivoperiosteoplasty with bone graft during the temporary dentition. A previous anterior expansion restores a normal intercanine space to allow good canine function on the cleft side with symmetrical occlusion. After the bone graft, the anterior expansion is continued to stimulate the interincisive suture and increase the width to allow a good alignment of the rotated incisor teeth.

## THE CLOSURE OF THE HARD PALATE

The roof of the mouth is the floor of the nose. The closure in a single layer by vomer flap or periosteal graft

and the push back procedures of Veau, Wardill, Kilner or Von Langenbeck with denuded bone are followed by a healing process with secondary epithelialisation leaving bad scars. It is absolutely necessary to avoid these techniques if we want to preserve the best width of the palatal vault and of the nasal fossa. For the last 26 years, I have closed the soft palate at 6 months of age, at the same time as the lip. This new chronology, inspired from the Schweckendiek<sup>[25,26]</sup> experience, was decided at a time when many surgeons<sup>[27]</sup> in France were concerned by the poor results of the push back procedures at the level of the hard palate. During the following year, the residual cleft of the hard palate narrows to such an extent that, in my experience, it is always possible to close it, in two layers without a vomer flap and without leaving denuded bone, by 18 months of age. The simultaneous closure of the cleft behind and in front seems very favorable to a balanced narrowing of the cleft palate. This procedure takes advantage of a palatal growth spurt up to two and a half years of age. Contrary to Delaire, I never close the alveolar cleft at the same time even if it seems easy. I believe it is wise to wait for the temporary dentition to be sure there is a good canine function prior to the gingivoperiosteoplasty. I never use relaxing incisions and transverse incisions between the soft and the hard palate, nor translation of a bipediced flap from the thin medial palatal mucosa leaving denuded bone as Delaire is doing. Contrary to him, I think that the pharyngoplasty with an inferior pedicle after the Delaire-Rosenthal technique is a poor technique for speech and nasal breathing. I prefer to do a radical dissection of the levator muscle as done by Sommerlad<sup>[28,29]</sup> with his intravelar veloplasty. The transposition of the levator muscles is usually performed at the time of the closure of the soft palate if the cleft is not too wide and at the time of the hard palate repair in the opposite case. The intravelar veloplasty has completely changed the speech results I achieved before. There is no doubt in my mind that the intravelar veloplasty is part of the functional approach. With 7 years of follow up it is clear that secondary surgery for speech will be very infrequent. I follow very carefully the ten first consecutive cases of complete bilateral cleft and the ten first consecutive cases of unilateral complete cleft operated on since late 1997 with this protocol. All of them have a good velar function. Currently, I am doing the final assessment of fifteen consecutive cases of bilateral cleft operated since 1985. They are now 16 to 21 years old. None of them had been operated on with a primary intra-velar veloplasty.

I have performed secondary surgery 7 times, with an Orticochea sphincteroplasty in 3 cases and a secondary intra-velar veloplasty in 4 cases.

Delaire<sup>[17]</sup> explicitly refuses the use of a vomer mucosal flap, accusing it of hindering the maxillary growth. With the chronology I use I don't need a vomer flap and it is probably better to avoid it. To be clear, I consider that undermining the vomer mucosa for a few millimeters along the midline to allow the suture with the lateral mucosa and achieve in the same step a complete closure of the fibromucosa of the palatal vault is not detrimental to facial growth. In bilateral clefts, the nasal mucosa of both palatal shelves are sutured together as far forward as possible. What we have to avoid is the closure in one layer of the palatal cleft with a vomer flap leaving in the cleft very scarred and retracted tissue which will narrow the nasal fossa for life.

### **My rationale for the protocol of primary treatment<sup>[18]</sup>**

My protocol is now the same in complete uni and bilateral clefts.

At 6 months of age, I do a simultaneous closure of the lip with complete correction of the lower lateral cartilage and closure of the soft palate with an intravelar veloplasty. In bilateral clefts the columella is lengthened at the same time.

After this operation, a removable nasal retainer is maintained permanently during the first 4 months postoperatively. We have now followed this protocol for 9 years. This precaution has really changed the quality of the esthetic and functional result. All these patients are nasal breathers at the time of the primary surgery. (I don't understand this. How does a nasal splint after primary surgery affect nasal breathing at the time of surgery? Perhaps he means when the patients return for hard palate surgery). I had never seen that before and am sure it is essential and more likely imperative in cleft children. Before the primary repair, the new born breathes through the cleft and has no cortical representation of his nostril. A normal nasal breathing pattern is not established at birth. When the primary surgery is detrimental to the nasal airway, we create an obligatory oral breather and that is particularly bad in a young baby anatomically designed to breathe only through the nose because he has a short neck and no oropharynx. Our experience with early secondary nasal surgery in

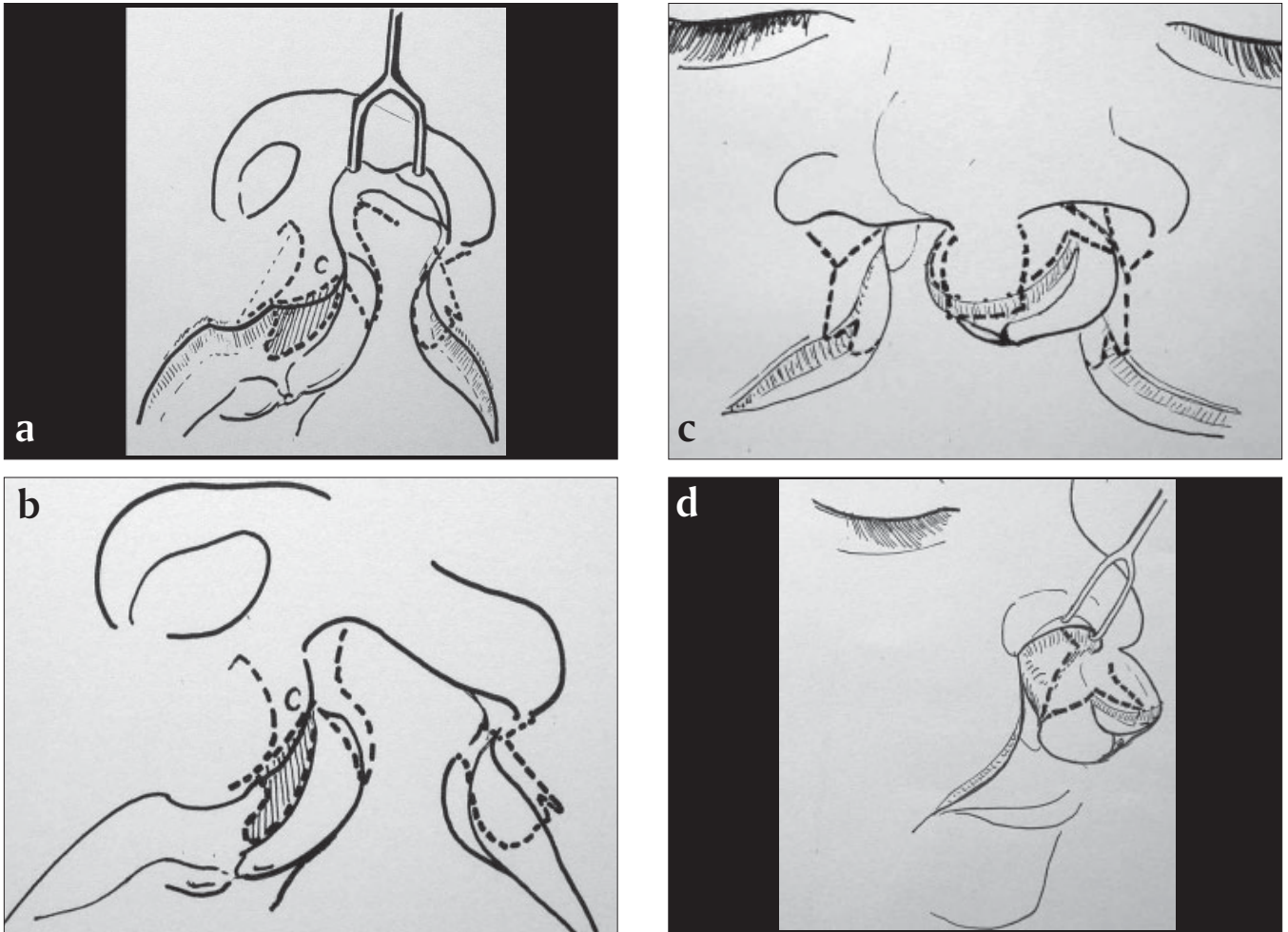
cleft children is that they don't easily develop a normal nasal breathing mode. Primary airway impairment in these patients leaves a cortical imprint difficult to efface.

At 18 month of age, I close the residual cleft of the hard palate in two layers without leaving denuded bone. When the cleft remains too wide, with more than 12 mm of width, it is wise to wait 6 months and take the benefit of the normal growth spurt of the palate up to two and a half years of age. After this age we can expect no more narrowing. In difficult cases, the fibromucosa is incised laterally along the teeth to give a good access to the periosteum of the palatal flap and allow a its quick expansion with parallel hatching and traction. To prolonge the lateral incision behind the molar increases the rotation of the fibromucosa. At the end of the operation, the fibromucosa is completely sutured laterally. I have been doing this timing of surgery for the last 26 years. A long time ago, in one or two cases, I did a third step to close the hard palate. Now when I can't close the palate completely, it is always in its anterior part, in continuity with the alveolar cleft and I know that I have always closed the even the widest alveolar cleft at the time of the gingivoperiosteoplasty without leaving a fistula.

At three and a half years of age, if necessary, an anterior expansion of the maxilla is performed with a quadhelix wired to the temporary teeth. When orthopedics and orthodontics are not available, the surgeon could easily learn this step of the treatment.

Between 4 and 5 years of age, I achieve closure of the gingivoalveolar cleft with gingivoperiosteoplasty and iliac cancellous bone graft.

In the same time, if necessary, are performed secondary revision of the nostril, eventually (?) associated with a septoplasty and turbinectomy The indication for early septal surgery always concerns unilateral or asymmetrical cases. In these cases the septal deformity may be very severe and although the anterior border of the septal cartilage is usually correctly repositioned after the primary repair, the luxation of the cartilage along the vomerine gutter and the strong septal convexity in the cleft nasal fossa persist. The established hypertrophy of the inferior turbinate on the opposite side of the cleft has also to be corrected if we want to stabilise the repositioning of the septum. future the repositioning of the septum will be perhaps performed earlier at the time of the primary surgery.



**Figure 2:** a) Incisions in a unilateral cleft. The design follows the principle of rotation of the philtrum and lateral advancement of the Millard technique. There is no perialar incision and the nasal skin is not incorporated into the lateral lip. The paring incision of the lateral labial mucosa raises a flap that will be rotated into a back cut along the piriform aperture. b) On the medial side, a triangular flap with a superior pedicle based on the columella is raised from the lateral aspect of the premaxilla and will be rotated into a back cut of the septal mucosa just under the upper lateral cartilage. c) Incisions in a bilateral cleft. The mucocutaneous junction of the philtrum is preserved. Rather than a rectangular flap of dry mucosa from the prolabium, we prefer now a triangular flap. d) The triangular flap with a superior pedicle based on the columella, is raised from the lateral mucosa of the premaxilla and will be rotated into a back cut of the septal mucosa

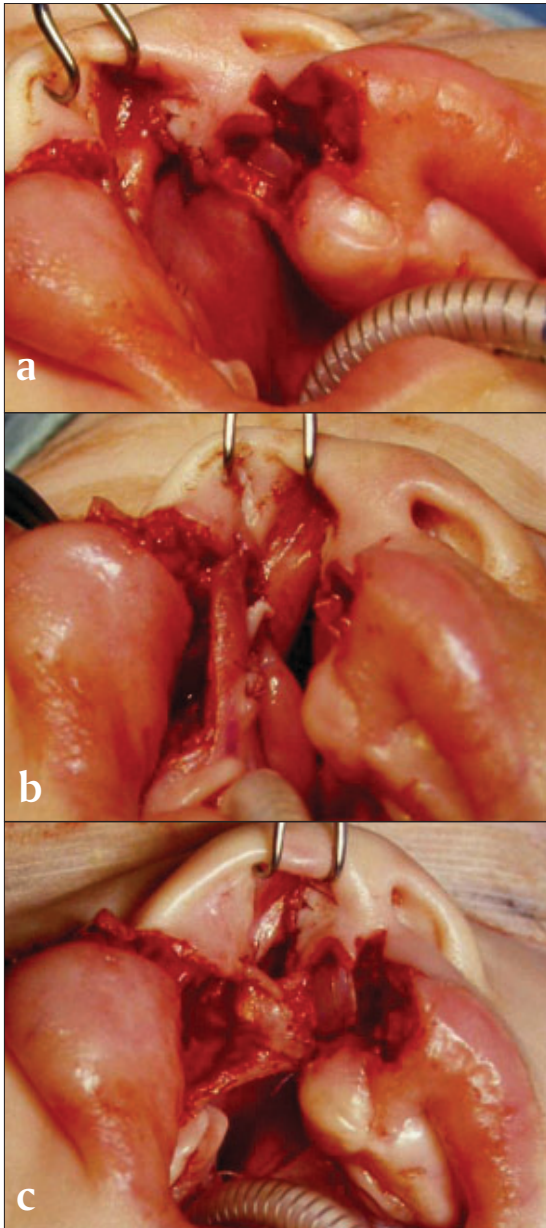
### A few details about the different procedures are necessary<sup>[18]</sup>

#### *Closure of the lip: the incisions*

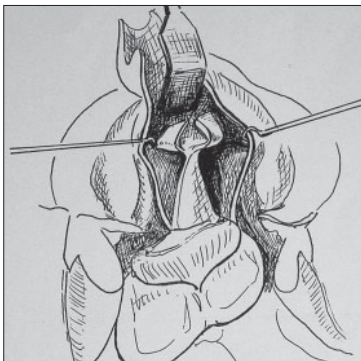
In a unilateral cleft, the design of the incisions is looking like a Millard<sup>[30]</sup> rotation of the philtrum and lateral advancement [Figure 2a and b]. Behind the C flap is designed, on the lateral aspect of the premaxilla, a vertical triangular flap<sup>[18]</sup> with a superior pedicle based on the columella. This flap will be rotated into a back cut of the septal mucosa just under the upper lateral cartilage to lengthen the columella. Like Delaire I think that the height of the lip depends on the muscle repair. I never use a perialar incision. The alar base repositioning depends only on the muscle repair. The back cut is used more to lengthened the columella than the lip.

In a bilateral cleft, the philtrum is 6 mm wide. The mucocutaneous line is preserved as, contrary to Millard and Delaire, I prefer an unscarred Cupid's bow. I keep a large triangular mucosal flap giving a better volume to the vermillion. Later it will be easy to excise the exposed wet mucosa without loss of volume thanks to bilateral dry mucosa island flaps. The 'C' lateral prolabial flaps will be trimmed at the end of the operation in the nostril sill. Just behind the C flap, I raise a large mucosal triangular flap from the lateral aspect of the premaxilla, with a superior pedicle based on the columella. Figure 2c and d. This flap, after the complete dissection of the septum and an interseptocolumellar incision, is lifted with the columella and rotated into a back cut of the septal mucosa just under the upper lateral cartilage. The lifting and the 90° rotation of this flap gives more lining

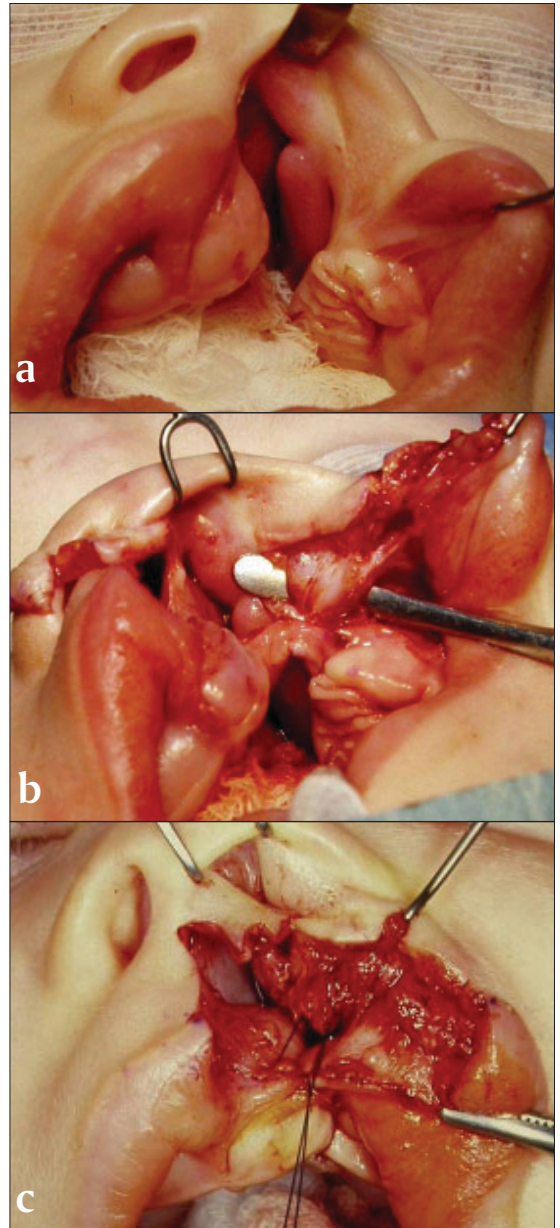




**Figure 3:** a) suture of the lateral premaxillary flap into the back cut of the septal mucosa after lifting of the columella in a unilateral cleft. b) Suture of the lateral labial mucosal flap along the piriform aperture. c) The lateral labial mucosal flap takes part in the suture of the floor of the nostril. In bilateral cleft, these flaps are used on both sides in the same step



**Figure 4:** Dissection of the septum and both upper lateral cartilages in a bilateral cleft

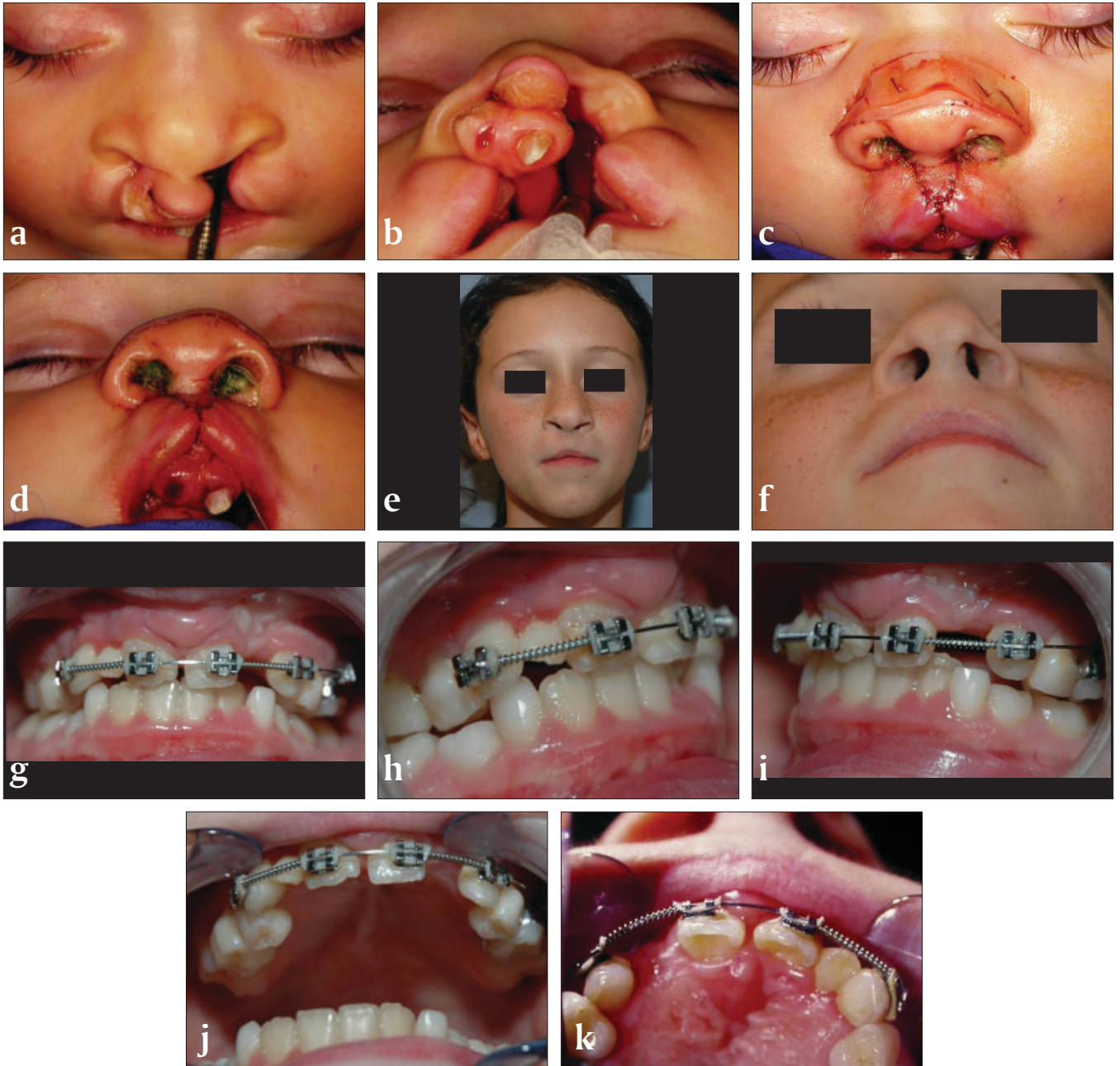

**Figure 5:** a) The myrtiform muscle is just under the mucosa of the nasal web and is the anchorage point of the lateral lip element on the lateral maxilla. b) Dissection of the strong maxillary insertion of the myrtiform. c) The reinsertion of the myrtiform muscle in front of the lateral aspect of the premaxilla is reinforced by passing through the mucosa of the labial sulcus

to the dome, assists in lengthening the columella and hinders the drift of the columella into the lip [Figure 3a, b, c]. Laterally, the incisions are the simplest possible. The flap from the lateral labial mucosa raised as a consequence of the paring incision is kept on a superior pedicle based on the piriform aperture and assists in the closure of the back cut along the piriform aperture and of the nostril floor.

*The dissection*

Time spent on this is essential as only completely freed

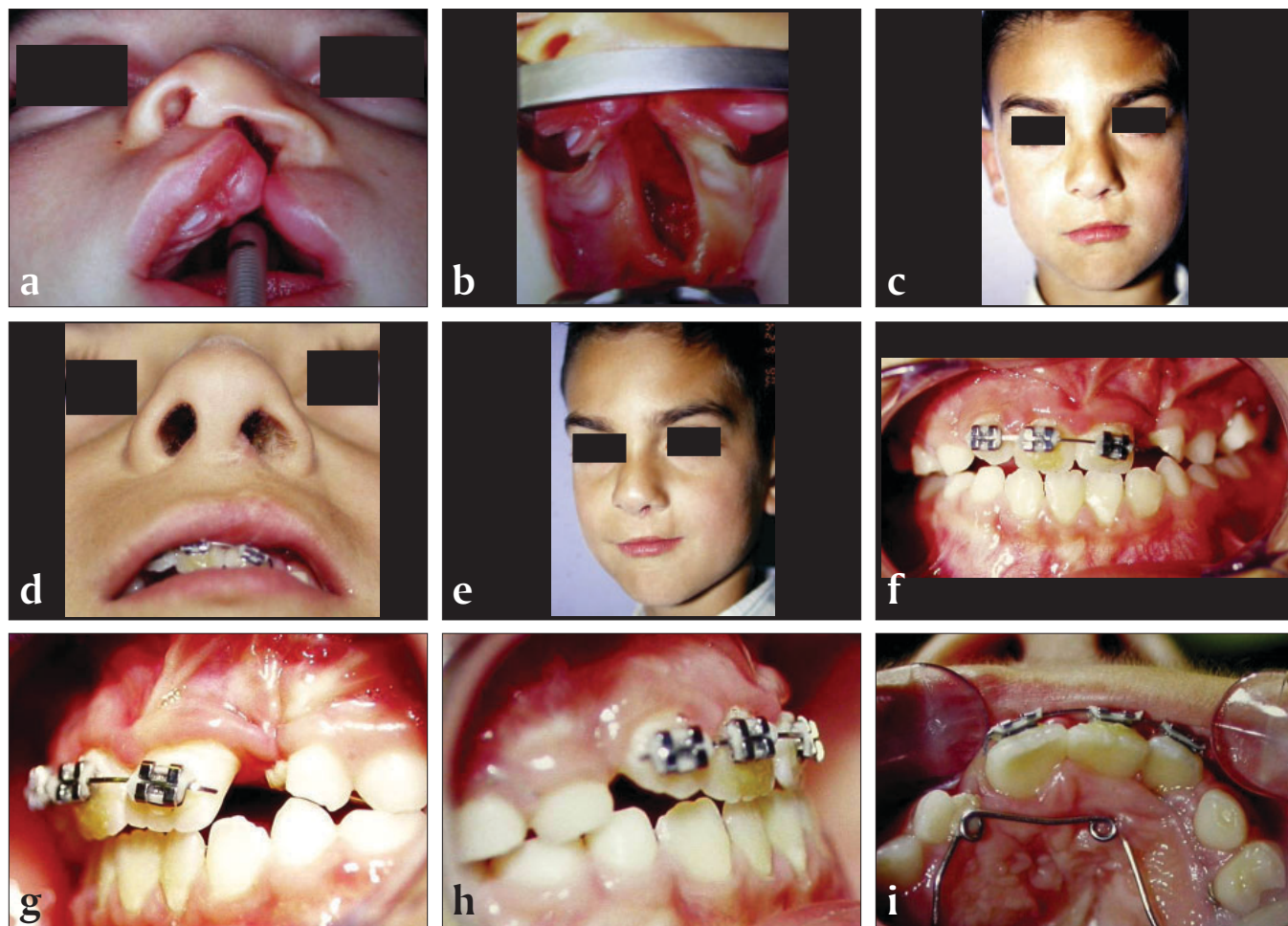


**Figure 6:** a, b) Second oldest patient of the series of the ten first consecutive cases of complete bilateral cleft. c, d) Appearance at the end of the first operation at 6 months of age with nasal splinting. e, f) Result at 9 years of age. g, h, i) Occlusion at 9 years of age. j, k) Maxillary arch and anterior palatal vault at 9 years of age

structures can be anatomically repositioned. The dissection is the same in uni- and bilateral clefts. Laterally, a wide subperiosteal elevation on the whole maxilla, from the malar area behind to the ascending process of the maxilla in front and from the orbital rim to the sulcus of the lip allows the advancement of the lip and the cheek toward the midline. This subperiosteal undermining is controversial.<sup>[31,32]</sup> Our long experience of 35 years is a clear demonstration of its harmlessness. A back cut along the piriform aperture

facilitates the repositioning of the alar base.

On the midline, the periosteum is respected in front of the nasal spine and the interincisive suture. The perichondrium is incised on the anterior border of the septum. At this level the subperichondrial dissection starts on both sides of the septum and both sides of the upper lateral cartilage [Figure 4]. The dissection joins laterally the subperiosteal elevation on the maxilla. The myrtiform head of the nasalis muscle just below the nasal



**Figure 7:** a, b) Complete left labio-maxillo-palatal cleft. This patient is the oldest of the series of the ten first consecutive unilateral cases. c, d, e) Result of the nasolabial repair at 9 years of age. f, g, h) Occlusion at 9 years of age after gingivoperiosteoplasty and bone graft at 9 years of age. i) Palatal vault and maxillary arch at 9 years of age

web and under the mucosa of the lateral vestibule of the nostril is separated from its maxillary insertions. From this place, the lower lateral cartilage is separated from the overlying skin and the dissection of the lower lateral cartilage is resumed in the midline between the dome and the medial crus.

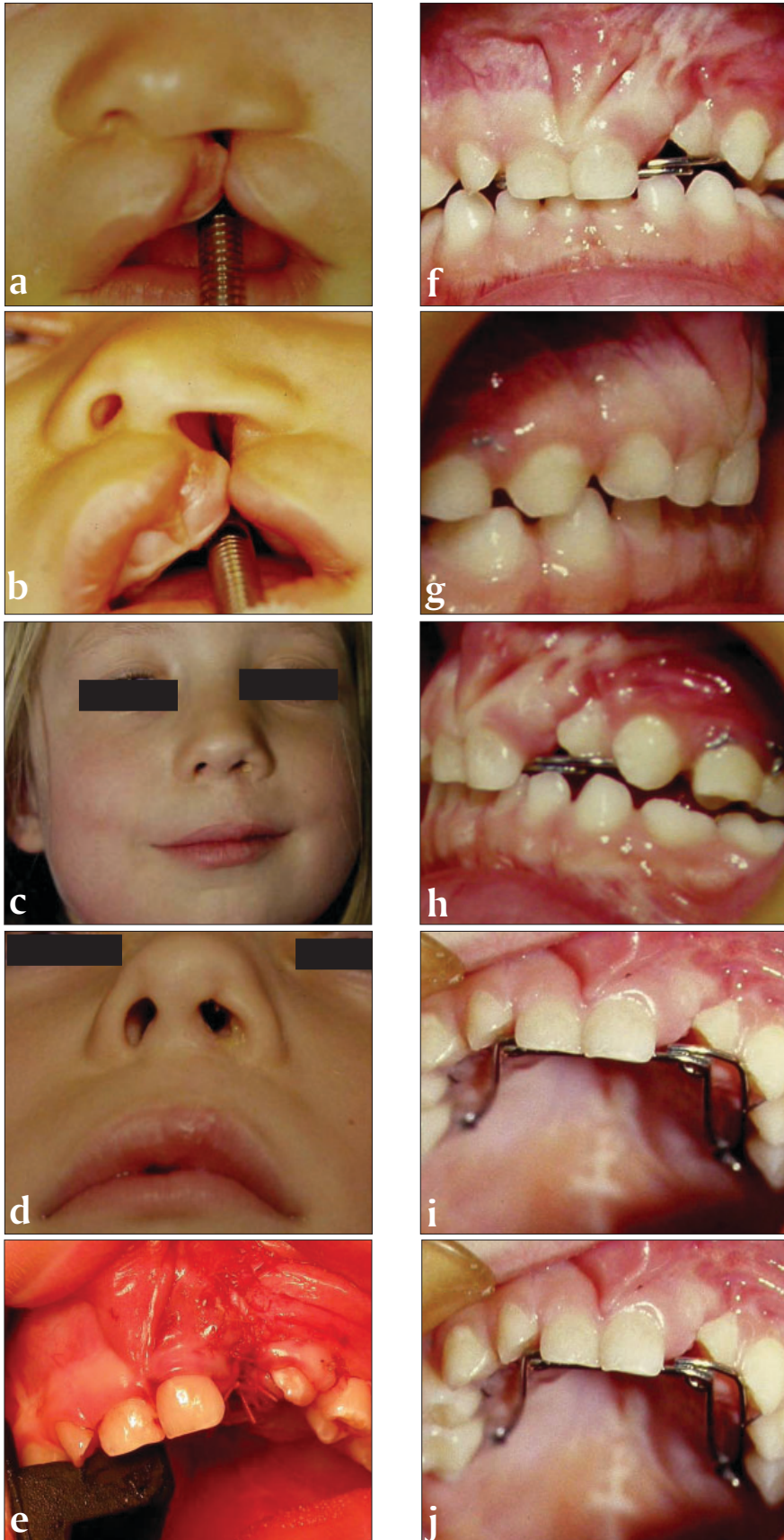
#### *The muscle repair.*

The muscle repair in a unilateral cleft is prepared by a minimal dissection between muscle and skin on both sides. The deepest suture is the reinsertion of the nasalis muscle. Its inferior head, the myrtiform, is attached vertically to the lateral aspect of the premaxilla in the area of the lateral incisor. This reinsertion must be reinforced in primary surgery by passing the suture through the mucosa of the labial sulcus [Figure 5a, b, c]. The suture is kept on a hemostat and tied at the end of the operation. It will lower the nostril sill and at the same time raise the labial vestibule. Delaire has described the repair of the muscles of the lip

and the nostril in another way. For him all the muscles should converge toward the anterior nasal spine and the septum. This kind of repair is detrimental to the patency of the nasal air way. The horizontal suture of the myrtiform onto the nasal septum would result in the muscle raising the nostril sill and pulling the nostril web toward the convexity of the nasal septum, thus obstructing the nasal air way. The narrowing of the nostril and the nasal valve is compounded by the low level of the upper lateral cartilage.

Then the orbicularis muscle is reinserted onto the fibrous tissue of the anterior nasal spine. The criss- crossing direction of these two muscular reinsertions corrects the vertical distension of this region.

The orbicularis oris muscle itself is repaired in two layers. The deep part is sutured to its counterpart beyond the midline. The superficial part is sutured just lateral to the philtrum, mimicking the philtrum column.



**Figure 8:** a, b) Complete left labio-maxillo-palatal cleft. c, d) result at 5 years of age. e) Gingivoperiosteoplasty with iliac cancellous bone graft at 4 years of age. f, g, h) Occlusion at 5 years of age. i, j) Palatal vault and maxillary arch at 5 years of age

*Repositioning the lower lateral cartilage*

To reposition the lower lateral cartilage it must be understood that it is more important to meticulously free the lower lateral cartilage than it is to do complex fixation procedures. For the last ten years I use nasal splinting. A custom made appliance made of a thin sheet of silastic (0, 5 mm) is placed in each nostril. The internal splints are sutured together by mattress sutures passing through the septum. They are then sutured to an external piece of silastic, closing any dead space, a condition which minimizes the scar and is a promise of stability. With this method not only the columella is lengthened but it is possible at the same time to lengthen the nose when the nasal lining is rolled inside the nose. The transparency of the silastic gives good visual control during the whole procedure of remodeling and makes it precise and reproducible as well as safe for the viability of the skin. With experience of more than 10 years, this primary remodeling of the nose and lengthening of the columella has been found to be uncomplicated.

*Nasal retainer*

Nasal breathing and labial competency are prerequisites for good subsequent facial growth. Our experience is that we can expect normal development when the young patient with a repaired cleft lip and palate sleeps with his mouth closed. For 9 years, a nasal retainer has systematically been used during the 4 first postoperative months. We did not dare to imagine that the influence of the nasal retainer would be so positive. Before its use, we had never seen such consistent results in our consecutive patients. Almost all of them are nasal breathers and the maxillae are close to normality. When an anterior expansion is necessary it can be achieved in a few weeks and reestablish a good canine function prior to the gingivoperiosteoplasty and cancellous iliac bone graft at 4 to 5 years of age. We think that our patients have never before reached such favorable conditions at this age with a normal maxillary arch ready for the mixed dentition with a good width and a patent nasal valve for normal ventilation. Figure 6a to i, show the entire sequence in a bilateral cleft while [Figure 7a to i] show it in a unilateral cleft both with 9 yrs follow up. [Figure 8a to i] show another child having a unilateral cleft with a 5 year follow up.

We know from our long experience of 35 years, that the early nasal surgery doesn't hinder nasal or facial growth if the patient is a nasal breather.

**CONCLUSION**

The surgeon must learn to create muscular balance with as little scarring as possible and also to reposition the cartilaginous structures which are the support of what we think is the major function, that is nasal ventilation. It is highly probable that the next years will confirm that to restore nasal breathing at the time of primary surgery is essential for normal facial growth. In the case of a complete cleft, the newborn breathes through the cleft and has no cortical representation of his nostril. A normal nasal breathing pattern is not established at birth. Our experience with early secondary nasal surgery in cleft patients is that they don't easily develop normal nasal breathing. Primary airway impairment in these patients leaves a cortical imprint difficult to efface.

**REFERENCES**

1. Veau V. Etude anatomique du bec-de-lièvre unilatéral total. *Annales d'Anatomie Pathologique et d'Anatomie Normale* 1928;5:601-32.
2. Mooney MP, Siegel MI, Kimes KR, Todhunter J. Premaxillary development in normal and cleft lip and palate human fetuses using three-dimensional computer reconstruction. *Cleft Palate Craniofac J* 1991;28:49-54
3. Ortiz-Monasterio F, Serrano Rebeil A, Valderama M, Cruz R. Cephalometric measurements on adult patients with unoperated cleft palates. *Plast Reconstr Surg* 1959;24:53-61.
4. Warren DW, Drake AF, Davis JU. The nasal airway in breathing and speech. In: Berkowitz S, editor. *Cleft lip and palate, perspectives in management*. Singular Publishing Group Inc: San Diego; 1996. p. 61-73.
5. Raphaël B, Morand B, Bettega G, Lesne C, Lesne V. Evaluation à long terme de l'uranoplastie par greffe de périoste tibial dans la fente labio-maxillo-palatine unilatérale. A propos de 51 cas cliniques. *Annales de Chirurgie Plastique Esthétique* 2003;47:196-203.
6. Delaire J. Primary cheilorhinoplasty for congenital unilateral labiomaxillary fissure. Trial schematization of a technic. *Rev Stomatol Chir Maxillofac* 1975;76:193-215.
7. Delaire J. Secondary functional cheilo-rhino-plastie (author's transl). *Rev Stomatol Chir Maxillofac* 1979;80:218-24.
8. Kernahan DA, Dado DV, Bauer BS. The anatomy of the orbicularis muscle in unilateral cleft lip based on a three-dimensional histologic reconstruction. *Plast Reconstr Surg* 1984;73:875-81.
9. Talmant J, Rouvre M, Thibult JL, Turpin P. Contribution à l'étude des rapports de la ventilation avec la morphogénèse cranio-faciale. Déductions thérapeutiques concernant l' ODF. *In: Rapport du 55è Congrès de la SFODF. Prelat: Paris; 1982.*
10. Talmant JC. La narine du bec-de-lièvre unilatéral. Peut-on concilier esthétique et ventilation normale? *L'orthodontie Française* 1982;53:451-6.
11. Dubos R, Escande JP. Chercher. Des chercheurs, des médecins...et des hommes. Stock: Paris; 1979.
12. Talmant J. Nose breathing and facial covering mechanics: A relationship orthodontists have to control. *In: Bollender CJ, Bounoure McComb H 1990. Anatomy of the unilateral and*

- bilateral cleft lip nose. *In: Bardach J, Morris HL, editor. Multidisciplinary management of cleft lip and palate. WB Saunders: Philadelphia; 1995. p. 144-9.*
13. Talmant J, Deniaud J, Nivet MH. Ventilation foetale, ventilation post natale et morphogénèse. *L'orthodontie Française* 2003;74:147-98.
  14. Talmant JC. Nasal malformations associated with unilateral cleft lip. *Scandinavian J Plast Reconstr Surg Hand Surg* 1993;27:183-91.
  15. Talmant JC. Reflections on the etiopathogenesis of cleft lip and palate and the development of their treatment. *Ann Chir Plast Esthet* 1995;40:639-56.
  16. Siegel MI, Mooney MP, Kimes KR, Gest TR. Traction, prenatal development and the labioseptopremaxillary region. *Plast Reconstr Surg* 1985;76:25-8.
  17. Delaire J, Precious D. Avoidance of the use of vomerine mucosa in primary surgical management of velopalatine clefts. *Oral Surg Oral Med Oral Pathol* 1985;60:589-97.
  18. Talmant JC. Cleft rhinoplasty. *In: Ward BP, Schendel SA, Hausamen JE, editors. Maxillofacial Surgery. 1<sup>st</sup> ed. Churchill Livingstone: London; 1999. p. 1133-71.*
  19. Talmant JC. Current trends in the treatment of bilateral cleft lip and palate. *In: Precious DS, Cleft Lip and Palate: A physiological approach. Oral Maxillofac Surg Clin North Am* 2000;12:421-41.
  20. McComb H. Anatomy of the unilateral and bilateral cleft lip nose. *In: Bardach J, Morris HL, editors. Multidisciplinary management of cleft lip and palate. WB Saunders: Philadelphia; 1990. p. 144-9.*
  21. McComb H. Primary repair of the bilateral cleft lip nose: A 4 year review. *Plast Reconstr Surg* 1994;94:37-47.
  22. Cutting CB, Grayson BH, Brecht LE. Presurgical columellar elongation and primary retrograde nasal reconstruction in one-stage bilateral cleft lip and nose repair. *Plast Reconstr Surg* 1998;101:630-9.
  23. Mulliken JB. Correction of the bilateral cleft lip nasal deformity: Evolution of a surgical concept. *Cleft Palate Craniofac J* 1992;25:40-5.
  24. Talmant J, Deniaud J. The role of the maxillary incisors in the development of the base of the nose. Applications in dento-facial orthopedics. *Orthod Fr* 2006;77:19-62.
  25. Schweckendiek W. Primary veloplasty: Long term result without maxillary deformity. *Cleft Palate J* 1979;15:268-74.
  26. Schweckendiek W, Kruse E. Two stages palatal repair. The Marburg approach. *In: Early treatment of cleft lip and palate. Hotz M, editor. Hans Huber: Berne; 1986. p. 114-8.*
  27. Malek R, Psaume J. New concept of the chronology and surgical technic in the treatment of cleft lip and palate. Results in 220 cases. *Ann Chir Plast Esthet* 1983;28:237-47.
  28. Sommerlad BC. A technique for cleft palate repair. *Plast Reconstr Surg* 2003;112:1542-8.
  29. Sommerlad BC, Mehendale FV, Birch MJ, Sell D, Hattee C, Harland K. Palate re-repair revisited. *Cleft Palate Craniofac J* 2002;39:295-307.
  30. Millard DR. Cleft craft: The evolution of its surgery. Vol I. The unilateral deformity. Little, Brown: Boston; 1976.
  31. Bardach J, Mooney M, Giedrojc-Juraha ZL. A comparative study of facial growth following cleft lip repair with or without soft tissue undermining: An experimental study in rabbits. *Plast Reconstr Surg* 1982;69:745-54.
  32. Mannucci N, D'Orto O, Di Francesco A, Brusati R. A comparison of the effect of sopraperiosteal versus subperiosteal dissection of the growing maxilla in rabbit: An experimental study. *In: Lee ST, Huang M, editors. Transactions 8<sup>th</sup> International Congress on Cleft Palate and Related Craniofacial Anomalies. Stamford Press: Singapore; 1997. p. 125-30.*