

Letters to Editor

Understanding the fibula by the candle model

Sir,

Functional and aesthetic mandibular reconstruction after ablative cancer surgery continues to be a challenge even after the introduction of micro vascular bone Vascularised fibula is the workhorse flap for mandibular reconstruction at most centres because of its unique anatomy, quality of bone stock and size of the bone that can be harvested. Harvesting the fibula and understanding the intricacies of shaping the missing mandible by osteotomising of the fibula are always challenging to beginners. Micro vascular reconstruction of the resected mandible requires accurate preoperative planning. Newer methods like use of anatomical facsimile models, stererolithographic models, three-dimensional computer-aided design/

computer-assisted manufacture technology and selective laser sintering-guided virtual plan are often complex and expensive.^[1-4]

Using the candle model for understanding the anatomy of the fibula and planning the osteotomies gives better aesthetic outcomes in terms of contour, width and projection and reduces the operative time especially for beginners. It is simple, easily available, inexpensive, easy to break and replicates the fibula to a great extent.

A candle of the approximate width and length of fibula, a cucumber peeler, a piece of cloth and a red ribbon are all that is needed. Using the peeler, the candle is triangularized [Figure 1]. On one of its surface (read peroneal), the ribbon is fixed by means of pins which act as a vascular pedicle [Figure 2]. If a cutaneous paddle is desired, the piece of cloth can be fixed by



Figure 1: Triangularization of the candle using a cucumber peeler



Figure 2: Fixation of ribbon to triangularized candle to make a near replica of fibula

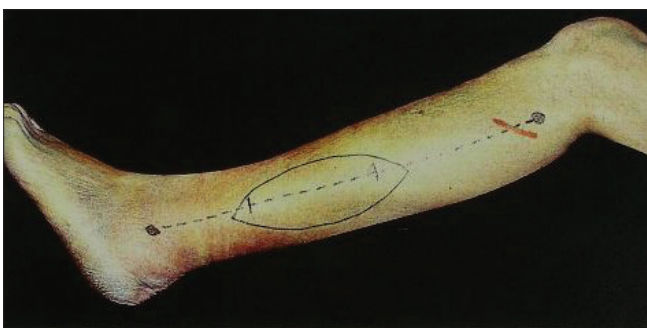


Figure 3: Planning of a skin paddle in relation of the fibula

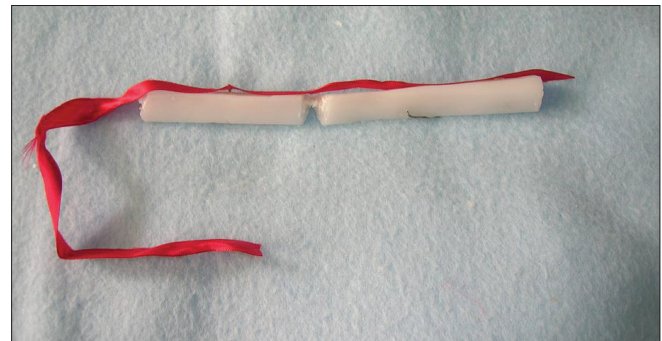


Figure 4: After removing the desired wedge of candle to give appropriate shape during fixation

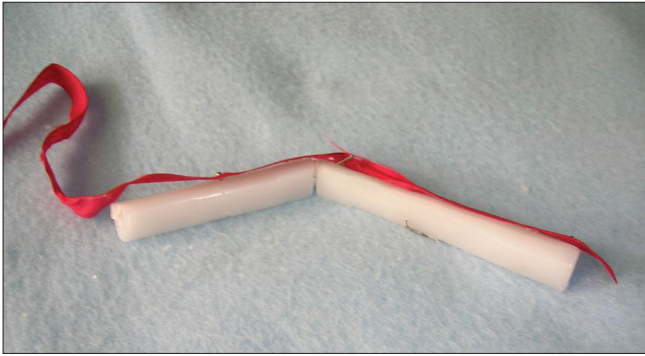


Figure 5: Creation of an appropriate angle by fixation with pins



Figure 7: Showing relative positions of skin paddle, pedicle and plate fixation on the candle model

means of pins. The cutaneous paddle is generally placed at the junction of the middle and distal third of the leg by a preoperative Doppler identification of the perforators in that region. However, an exploratory incision can be given, perforators identified and then final incision can be decided to include the skin paddle [Figure 3]. Anticipating the defect, the candle can be osteotomized using a scalpel or stout scissors by keeping the pedicle intact. And wedge can be excised as desired to give the desired shape and contour to the candle [Figure 4]. Preoperative osteotomy on the candle also gives an idea regarding the placement of skin paddle which can be tricky at times. The osteotomized candle segments can be fixed temporarily by means of long pins [Figures 5 and 6]. Giving a triangular shape to the candle or having a triangular candle helps in better understanding of the surfaces and the vascular anatomy which in turn makes planning of the osteotomies easier. The candle model also helps us understand how much wedge of bone do we remove to achieve the desired angle, how much pedicle length will we possibly need. It also helps us in positioning the skin paddle with near perfection [Figure 7].



Figure 6: Showing the surface for definitive internal fixation by plates

Thus the use of a candle model is a very useful tool for understanding and preoperative planning of osteotomies with equal accuracy, particularly if the modalities of virtual imaging are not available.

Nikhil Panse, Parag Sahasrabudhe

Department of Plastic Surgery, B.J Medical College and Sasoon Hospital, Pune, India

Address for correspondence:

Dr. Nikhil Panse, Department of Plastic Surgery, Vimal Niwas, Sudarshan Society, Near Model Colony Post Office, Shivajinagar, Pune - 16, India. E-mail: nikhil.panse@rediffmail.com

REFERENCES

1. Yeung RW, Samman N, Cheung LK, Zhang C, Chow RL. Stereomodel-Assisted Fibula Flap Harvest and Mandibular Reconstruction. *J Oral Maxillofac Surg* 2007;65:1128-34.
2. Eckardt A, Swennen GR. Virtual planning of composite mandibular reconstruction with free fibula bone graft. *J Craniofac Surg* 2005;16:1137-40.
3. Leiggener C, Messo E, Thor A, Zeilhofer HF, Hirsch JM. A selective laser sintering guide for transferring a virtual plan to real time surgery in composite mandibular reconstruction with free fibula osseous flaps. *Int J Oral Maxillofac Surg* 2009;38:187-92.
4. Dimitroulis G. "Mandibular reconstruction following ablative tumor surgery: An overview of treatment planning". *Aust N Z J Surg* 2000;70:120-6.

Access this article online

Quick Response Code:



Website:

www.ijps.org

DOI:

10.4103/0970-0358.81460