

Review Article

Complex regional pain syndrome

Sandeep J Sebastin

Department of Hand and Reconstructive Microsurgery, National University Health System, Singapore

Address for correspondence: Dr. Sandeep J Sebastin, Department of Hand and Reconstructive Microsurgery, National University Health System, 1E Kent Ridge Road, NUHS Tower Block, Level 11, Singapore 119228. E-mail: sandeepsebastin@gmail.com

ABSTRACT

Complex regional pain syndrome (CRPS) previously known as reflex sympathetic dystrophy is a chronic neurological disorder involving the limbs characterized by disabling pain, swelling, vasomotor instability, sudomotor abnormality, and impairment of motor function. CRPS is not uncommon after hand surgery and may complicate post-operative care. There is no specific diagnostic test for CRPS and the diagnosis is based on history, clinical examination, and supportive laboratory findings. Recent modifications to diagnostic criteria have enabled clinicians to diagnose this disease more consistently. This review gives a synopsis of CRPS and discusses the diagnosis, pathophysiology, and treatment options based on the limited evidence in the literature.

KEY WORDS

Causalgia; complex regional pain syndrome; hand surgery; reflex sympathetic dystrophy; Sudeck atrophy; superficial radial nerve

INTRODUCTION

Complex regional pain syndrome (CRPS) is one of the most challenging chronic pain conditions of the limbs. There is little agreement with regards to the aetiology, symptoms, clinical presentation, diagnosis, or treatment of CRPS. In fact there is confusion regarding the terminology itself. Historically, CRPS has been described by a number of terms that include causalgia, Sudeck atrophy, reflex sympathetic dystrophy (RSD), algodystrophy, post-traumatic dystrophy and shoulder-hand syndrome. In order to bring some uniformity to this problem, the International Association for the Study of Pain (IASP) in 1994 introduced the term CRPS to

describe a wide variety of post traumatic neuropathic pain conditions of the limbs.^[1] The use of the term CRPS has also been questioned and perhaps another more appropriate term will be developed in the future.^[2] In the meantime, CRPS is the term used routinely by pain specialists and neurologists and the use of traditional terminology like RSD and causalgia is dwindling. CRPS is most often associated with surgery of the distal upper extremity to complicate recovery, delay return to work, diminish health related quality of life, and increase the likelihood of poor outcomes and/or litigation.^[3] This article presents a brief historical overview followed by a review of the definition, incidence, pathophysiology, current diagnostic criteria, and the basic approach to patients with CRPS following hand surgery.

HISTORICAL OVERVIEW

The earliest documented description of CRPS is probably Ambroise Pare's report from the 16th century describing the persistent pain and contractures experienced by

Access this article online

Quick Response Code:



Website:

www.ijps.org

DOI:

10.4103/0970-0358.85351

Table 1: IASP diagnostic criteria for CRPS* (1994)

The presence of an initiating noxious event, or a cause of immobilization[†]

Continuing pain, allodynia, or hyperalgesia in which the pain is disproportionate to any known inciting event

Evidence at some time of edema, changes in skin blood flow, or abnormal sudomotor activity in the region of pain (can be sign or symptom)

This diagnosis is excluded by the existence of other conditions that would otherwise account for the degree of pain and dysfunction

*If seen without "major nerve damage" diagnose CRPS I; if seen in the presence of "major nerve damage" diagnose CRPS II, †Not required for diagnosis; 5–10% of patients will not have this. Must meet criteria 2, 3, and 4 for diagnosis.

Table 2: Clinical diagnostic criteria for CRPS* – Budapest Criteria (2003)

Continuing pain, which is disproportionate to any inciting event

Must report at least one symptom in three of the four following categories

- Sensory
- Vasomotor
- Sudomotor/ Oedema
- Motor/ Trophic

Must display at least one sign at time of evaluation in two or more of the following categories

- Sensory
- Vasomotor
- Sudomotor/ Oedema
- Motor/ Trophic

There is no other diagnosis that better explains the signs and symptoms

* If seen without "major nerve damage" diagnose CRPS I; if seen in the presence of "major nerve damage" diagnose CRPS II.




Figure 1: Silas Weir Mitchell (1829-1914)

King Charles IX after a blood-letting procedure.^[4] In 1766, Hunter described the pain syndrome after a joint injury.^[5] Silas Weir Mitchell [Figure 1], the father of American neurology gave the first detailed description of CRPS in 1864.^[6] Mitchell together with Morehouse and Keen noted the frequent occurrence of exaggerated presentation of pain in relation to the injury in veterans of the American civil war.^[7] Mitchell coined the term causalgia from the Greek Kausis (fire) + Algos (pain). His graphic description remains the best depiction of the clinical presentation of CRPS even today.^[2,5] Causalgia is characterized by exquisite burning pain that begins in the distribution of an injured peripheral nerve and then spreads beyond it. It is almost always associated with an injury to a major nerve trunk.^[8]

In 1900, Sudeck described the clinical and radiological features of post-traumatic reflex atrophy of bone latter known as Sudeck atrophy.^[9] He also proposed a post-traumatic pain syndrome associated with oedema and trophic changes. Rene Leriche in 1916 was the first to link the sympathetic nervous system to causalgia and reported pain relief in a patient after extensive periarterial nerve stripping.^[10] In 1946, Evans introduced the term reflex sympathetic dystrophy (RSD) for this condition. Evans theorized that trauma that generated activity in afferents set up a reflex in the spinal cord which stimulated activity in sympathetic efferents, and in turn resulted in dystrophic changes in the periphery of the limb.^[11] This theory gained acceptance because some patients had pain relief after a local anaesthetic or pharmacologic sympathetic ganglion blockade.^[12] However, recent studies have failed to demonstrate a 'reflex arc' and suggest that the sympathetic nervous system may not be involved in every case and that dystrophy rarely occurs.^[13] In 1986, Roberts used the term sympathetically mediated pain (SMP) to describe RSD, whereas Campbell and colleagues used the term sympathetically independent pain (SIP) for those patients with nerve injuries who did not respond to sympathetic blockage.^[14] The use of differing terms with imprecise classifications and unclear pathogenesis led to confusion, misdiagnosis, and mistreatment of patients with this pathology.^[15]

In 1993, IASP designated a Task Force to review the

nomenclature and develop diagnostic criteria. In 1994, at a consensus workshop in Florida, the Task Force developed the nomenclature, CRPS, and proposed the IASP diagnostic criteria [Table 1].^[1] They further subdivided CRPS into types I and II. The clinical features of both types are identical and the only distinguishing feature is the presence of a peripheral nerve injury in type II. In essence, type I refers to RSD and type II refers to causalgia. An IASP consensus workshop held in Budapest in 2003 proposed modified clinical diagnostic criteria (Budapest criteria) to address the lack of specificity in the original IASP diagnostic criteria [Table 2].^[16]

DEFINITION

CRPS describes an array of painful conditions that are characterized by a continuing (spontaneous and/or evoked) limb pain that is seemingly disproportionate in time or degree to the usual course of any known trauma or other lesion. The pain is regional (not in a specific nerve territory or dermatome) and usually has a distal predominance of abnormal sensory, motor, sudomotor, vasomotor, and/or trophic findings [Table 3].^[16] CRPS has been divided into three stages of progression based on the duration of symptoms.^[17] Although it is not necessary for each patient to develop all stages or for these stages to progress in a sequential fashion, recognizing the

stage and the predominant complaint can help with management of patients.^[18]

Stage I (Acute stage: 0-3 months): It is characterized primarily by pain/sensory abnormalities (e.g. hyperalgesia, allodynia), signs of vasomotor dysfunction, and prominent edema and sudomotor disturbance [Figures 2-4].

Stage II (Dystrophic stage: 3-9 months): It is characterized by more marked pain/sensory dysfunction, continued evidence of vasomotor dysfunction, with development of significant motor/trophic changes [Figures 2-4].

Stage III (Atrophic stage: 9-18 months): It is characterized by decreased pain/sensory disturbance, continued vasomotor disturbance, and markedly increased motor/trophic changes.

INCIDENCE

CRPS is an uncommon disease with a prevalence of <2% in most retrospective series.^[19] A study from Netherlands reported an incidence of 26.2 cases per 100,000 person years, whereas a study from the United States estimated the incidence at 5.5 cases per 100,000 person years.^[20,21] A higher incidence of CRPS is reported in patients between the ages of 40-49 and in women

Table 3: Common clinical characteristics of CRPS

<i>Diagnostic category</i>	<i>Symptom</i>	<i>Sign</i>
Sensory	Continuous burning pain in the distal part of the affected extremity Pain is disproportionate in intensity to the inciting event and usually increases when the extremity is in a dependent position. Sensory abnormalities are most pronounced distally, and have no consistent spatial relationship to individual nerve territories or to the site of the inciting lesion.	Stimulus-evoked pains include mechanical and thermal allodynia and/or hyperalgesia, and deep somatic allodynia (pain due to touching the joints and movement of joints).
Vasomotor	Reports of temperature asymmetry Reports of skin color changes/ asymmetry	Evidence of temperature asymmetry Evidence of skin color changes/ asymmetry
Sudomotor/ Edema	Reports of edema Reports of sweating changes and/or sweating asymmetry	Evidence of edema Evidence of sweating changes and/or sweating asymmetry
Motor/ Trophic	Reports of decreased range of motion Reports of motor dysfunction Weakness Tremor Dystonia Coordination deficits Disturbed body perception of the affected extremity Reports of trophic changes Hair Nail Skin	Evidence of decreased range of motion Evidence of motor dysfunction Weakness Tremor Dystonia Coordination deficits Evidence of trophic changes Hair Nail Skin Osteoporosis

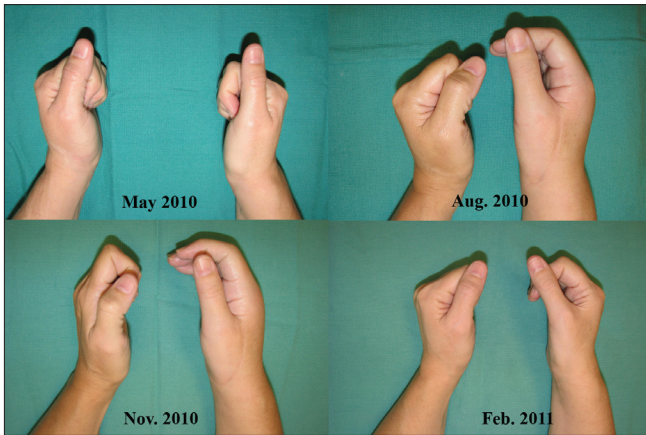


Figure 2: A 45-year-old lady with Madelung deformity of both wrists presented with bilateral pain greater in the right wrist in May 2010. Her pre-operative visual analogue scale (VAS) pain score was 2/10. She underwent excision of the distal ulna (Darrach procedure) for the right wrist in June 2010. Post-operatively (July 2010), she continued to have severe pain (VAS: 9/10) and swelling in the wrist and hand. She described the pain as burning in nature. She also complained of numbness of all fingers, frequent colour changes in her hand (purplish hue), and a subjective feeling of objects feeling colder to touch with her right hand compared to the left

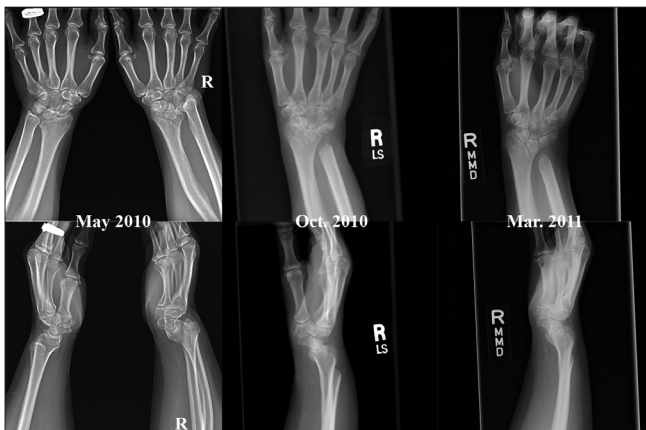

Figure 4: An infraclavicular brachial plexus catheter was placed for continuous patient controlled analgesia. Her pain score improved to 3/10 and she was able to participate in therapy. The catheter was removed in September and she has gradually made progress in her therapy and the medications were tapered. On her last follow-up in March 2011, she complained of intermittently pain (VAS 2-3/10), her range of motion was approximately 70-80% of the opposite limb, and she was able to return to work as a respiratory technician

(76%).^[22] The upper extremity is affected twice as commonly as the lower limb, and a fracture is the most common trigger (46%). In 10-26% of patients with CRPS, no precipitating factors can be found.^[22] No correlation to diabetes, smoking or alcohol has been found.^[23] The incidence of recurrent CRPS type I is 1.8% per year, and 50% are spontaneous recurrences.^[24]

The exact incidence and prevalence of CRPS after hand surgery is unknown. Rates of the occurrence of CRPS range from 4.5% to 40% after fasciectomy for Dupuytren contracture, 2% to 5% after carpal tunnel surgery, and 22%

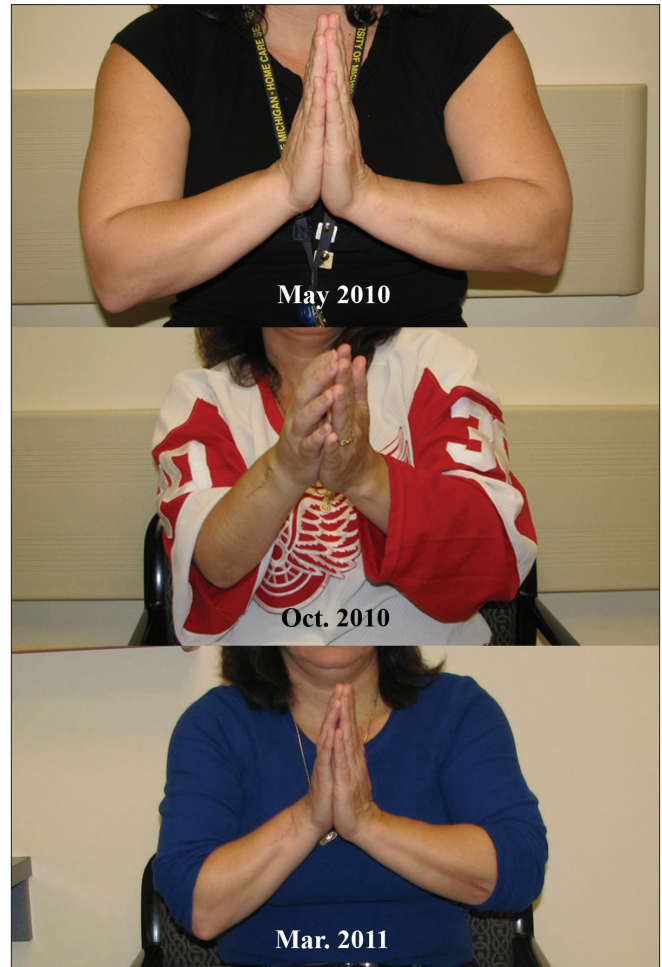

Figure 3: On examination, the right hand appeared pale, swollen, and with limited range of motion at all joints of the hand and wrist. Her motor power at the wrist and fingers (extension/ flexion) was diminished (grade 3) and skin temperature recordings showed the right side to be 34.2 °C and the left hand to be 33.6 °C. Nerve conduction studies were reported as normal. Patient was diagnosed to have CRPS I and started on gabapentin and oxycodone. On follow-up in August 2010, she did not report any improvement in symptoms and a diagnostic stellate ganglion block was done. She did not have any improvement following the sympathetic block

to 39% after distal radius fractures.^[3] A higher incidence of CRPS has been reported in highly comminuted, intra-articular distal radius fractures, fractures with associated ulnar styloid injuries, and in fractures treated with closed reduction and casting (versus percutaneous pinning).^[23] An elevated intra-cast pressure as a result of a tight cast or extreme positions was also a common risk factor for development of CRPS.^[25]

PATHOPHYSIOLOGY

Most patients (90%) with CRPS have an initiating noxious event (trauma/ischemia/nerve compression) in the clinical history. The reason why only some patients develop CRPS is unclear. There is also no single pathophysiological

mechanism that can explain the diversity and the heterogeneity of the symptoms (oedema, central nervous system symptoms, joint involvement, etc).^[26] It is now accepted that multiple mechanisms are involved and the presentation depends on the relative contribution of each mechanism. The pathophysiologic mechanisms that are believed to contribute to CRPS include alterations in cutaneous innervation (lower density of small fibres—C and A α), central and peripheral sensitization (increased excitability of nociceptive neurons in the spinal cord and local tissues as a result of persistent noxious input from tissue damage/nerve injury mediated by neuropeptides like substance P and bradykinin), altered function of the sympathetic nervous system; lower levels of circulating catecholamines; increased levels of local and systemic inflammatory cytokines (TNF- α , interleukin-1, -2, and -6), lower systemic levels of anti-inflammatory cytokines (interleukin-10), genetic factors (HLA-b62 and HLA-DQ8 alleles), and psychologic factors (anxiety, anger, and depression).^[27] The most prominent mechanism appears to be the inflammatory process because all the classic signs of inflammation (oedema, redness, hyperthermia, and impaired function) are conspicuous in the early stages of CRPS.^[26]

DIAGNOSTIC CRITERIA

CRPS is a clinical diagnosis based on patient symptoms and signs elicited on physical examination. The IASP diagnostic criteria [Table 1] have very good sensitivity (0.99), but poor specificity (0.41), potentially leading to over diagnosis. The Budapest clinical diagnostic criteria retain the sensitivity of the IASP criteria, but improve the specificity (0.68) [Table 2].^[28] The IASP Budapest consensus group also retained the division of CRPS into types I and II subtypes depending on the absence or presence of evidence of peripheral nerve injury, respectively. In addition, a third diagnostic subtype called CRPS-NOS was recommended. This is because approximately 15% of the patients previously diagnosed with CRPS (based on 1994 IASP criteria-Table 1) would not fully meet the new clinical diagnostic criteria [Table 2]. Patients who have fewer than three symptom or two sign categories, or who were not showing a sign at the time of the examination, but had exhibited this previously, and whose signs and symptoms were felt to be best explained by CRPS would receive a diagnosis of CRPS-NOS.^[16] The common sensory, vasomotor, sudomotor, motor, and trophic changes associated with CRPS have been tabulated in Table 3.^[29]

The IASP Budapest consensus group also felt that a higher level of specificity was desirable in the research context. The Budapest research diagnostic criteria for CRPS are therefore slightly more stringent and require the patient to have at least two positive sign categories and all four positive symptom categories (versus at least two positive sign categories and three positive symptom categories for clinical diagnosis). This improves the specificity of the Budapest research diagnostic criteria to 0.79.^[28] Harden has also suggested the use of measurement techniques and laboratory testing to further improve the specificity of the research diagnostic criteria.^[30] Some of these techniques include the use of 100 mm visual analogue scale for quantifying pain, measuring temperature allodynia using a Peltier type device, mechanical allodynia using von Frey testing, Laser Doppler for vasomotor tone, and volumetry for oedema.

APPROACH TO A PATIENT WITH CRPS FOLLOWING HAND SURGERY

History

In patients with a suspected diagnosis of CRPS, history of the period prior to surgery should be obtained to determine any pre-existing conditions, past traumatic injuries, or pain issues. Pre-existing subclinical problems can be exacerbated in the perioperative period. One should ascertain the time of onset of symptoms relative to surgery. The symptoms of CRPS (pain, numbness, swelling, stiffness, etc) are often non-specific and frequently seen in most post-operative patients. It is therefore important to evaluate the response of patients to standard treatment of these symptoms. Patients with CRPS do not respond to narcotics, are irritable, do not cooperate with therapy, resist returning to work, and often adopt a protective posture to guard the affected extremity.^[3,12]

Physical examination

The affected extremity should be exposed to allow a full examination from the neck downwards. The examination should be carried out at rest, during activity, and during ambulation. The three goals of physical examination are (1) comparison of the affected extremity against the unaffected limb and the pre-operative examination; (2) to determine evidence of sensory, vasomotor, sudomotor/oedema, and motor/trophic signs diagnostic of CRPS [Table 3]; and (3) identify any possible nerve injuries.^[3] The commonly reported nerve injuries associated with CRPS include the superficial branch of the radial nerve near the radial styloid, the palmar cutaneous branch of

the median nerve near the wrist crease, and the dorsal branch of the ulnar nerve close to the ulnar styloid. The extremity examination should also include assessment of skin integrity, range of motion, joint stability, motor power, neurologic, and vascular functions. Table 4 lists the definitions of the commonly used terms used in describing the signs and symptoms associated with CRPS.^[31]

Investigations

CRPS is a clinical diagnosis, but one of the criteria for diagnosis is the absence of any other diagnosis to explain the findings. The main purpose of investigations in CRPS is therefore to rule out other conditions. The ESR, C-reactive protein, complete blood count, and serum auto-antibodies results are useful in ruling out infections and rheumatologic conditions.^[32] Electrodiagnostic studies may be indicated to rule out specific neuropathic conditions, such as peripheral neuropathy, entrapment neuropathies, or nerve injury. Radiographic studies including magnetic resonance imaging are often necessary to rule out bone or soft tissue pathology as the source of pain.^[12,19]

A few tests have been described that are complementary to the clinical diagnostic criteria and are useful in demonstrating objective abnormalities characteristic of CRPS.^[32] They include:

Plain radiography

If they are normal at baseline, serial examination can reveal significant change over time and aid in confirmation of diagnosis [Figure 4]. Periarticular osteopaenia and patchy osteoporosis can be seen in plain radiographs as early as 2 weeks after onset of CRPS.^[12,19,32]

Bone scans

Three phase (blood pool, blood phase, scan phase) bone scanning of the affected extremity using technetium Tc 99m-labelled bisphosphonates is a highly sensitive (but relatively nonspecific) test that may detect osseous changes earlier than plain radiographs. Classic findings include increased periarticular uptake in the third phase (scan phase) and evidence of vasomotor instability and abnormal patterns of flow distribution in the first and second phase (blood pool and blood phase). Band-shaped increased radionuclide accumulation in the metacarpophalangeal and interphalangeal joints of the affected extremity during the scan phase is characteristic for CRPS. Multiple studies have found that the sensitivity of bone scans decreases and the specificity increases with disease duration.^[12,26,32]

Bone densitometry

They will show a lowered bone mineral density and bone mineral content in affected limb of patients with CRPS. This can be used to monitor treatment efficacy as these indices often improve in patients undergoing treatment.^[12]

Thermography

An infrared thermometer (accuracy of ±0.1 °C) is used to measure several symmetrical points on the affected and contralateral extremity, making comparisons between the two extremities. A difference of 0.5 °C is considered mildly asymmetrical, and a difference of 1.0 °C is considered significant.^[12]

Sweat testing

Subjective sweat testing can be performed by applying an indicator-starch powder to the limbs. The indicator changes colour when the limb sweats. Quantitative

Table 4: Common term used to describe symptoms and signs in CRPS

Term	Meaning
Pain	An unpleasant sensory and emotional experience associated with actual or potential tissue damage
Noxious stimuli	A stimulus that is damaging or threatens damage to normal tissues
Nociception	The neural process of encoding noxious stimuli.
Analgesia	Absence of pain in response to stimulation which would normally be painful.
Hyperalgesia	Increased pain from a stimulus that normally provokes pain.
Hypoalgesia	Diminished pain in response to a normally painful stimulus
Allodynia	Pain due to a stimulus that does not normally provoke pain.
Paresthesia	An abnormal sensation, whether spontaneous or evoked.
Dysesthesia	An unpleasant abnormal sensation, whether spontaneous or evoked.
Hyperesthesia	Increased sensitivity to stimulation (includes both allodynia and hyperalgesia)
Hypoesthesia	Decreased sensitivity to stimulation

sweat production can be measured using the resting sweat output and quantitative sudomotor axon reflex test (provocative test that determines the sweat output in response to an iontophoresis cholinergic challenge, such as acetylcholine or methacholine). Both of these tests have been shown to correlate with clinical signs of CRPS.^[3,12]

Sympathetic blocks

Sympathetically maintained pain (SMP/ RSD) may be differentiated from sympathetically independent pain (SIP) by an intravenous injection of phentolamine (α 1- and α 2-adrenergic receptor blocker). In patients with SMP, the injection results in transient pain relief. Another option is to perform a sympathetic block using a local anaesthetic. A cervicothoracic block (stellate ganglion/ upper thoracic) is used for upper extremity symptoms and a lumbar paravertebral block is used for lower extremity symptoms. In patients who respond during the block, pain is relieved, whereas motor function is retained.^[3]

Treatment

The aim of treatment of CRPS is pain control followed by recovery of limb function.^[26] Although a number of treatment options have been reported in the literature, these are empirical at best and no reliable protocol is available for use in all patients. Early recognition and prompt initiation of treatment improve patient outcomes. Even suspected cases of CRPS should be referred to a pain specialist early. A multidisciplinary approach to treatment with the hand surgeon as the lead with inputs from the hand therapist and anaesthesiologist (pain clinic) is required for optimum outcomes. The inclusion of psychologist or the workmen’s compensation coordinator may be beneficial in certain circumstances. The initial treating surgeon should be involved throughout the process and one must resist the temptation to dump

patients to pain clinics. Comorbidities such as depression, sleep disturbance, anxiety, and loss of body image should be treated concurrently.^[19] The modalities for treatment of CRPS include the following.

Physical therapy

This is the first line treatment for CRPS and has been shown to be effective in multiple controlled studies.^[12] The initial treatment is immobilization and splinting of the extremity. Elevation, massage, gentle range of motion, and isometric strengthening exercises are gradually incorporated into the treatment with provision of adequate analgesia. As the patient improves, therapy becomes more aggressive. However, therapy must not exacerbate the pain. If it leads to escalation of pain, it must be given up.^[29] Contrast baths (alternating heat and cold), transcutaneous electrical nerve stimulation (TENS), H-wave therapy, and a stress loading program of traction and compression exercises have also been shown to be effective in CRPS.^[3]

Pharmacologic therapy

The selection of the drug is determined by the severity of the pain. Traditional NSAID’s (ibuprofen) or COX-2 inhibitors (celecoxib) are useful in the acute stage. Metamizol and controlled release opioids (hydrocodone or oxycodone) can be considered in patients with more severe pain to allow participation in therapy.^[26] Other drugs for which data from controlled clinical trials have established efficacy in CRPS include gabapentin, Ca-modulating drugs (nifedipine, amlodipine, calcitonin, and bisphosphonates), and free radical scavengers^[33] Bisphosphonates (alendronate, pamidronate, and clodronate) are the only class of drugs that have survived placebo controlled trials and shown a statistically significant pain reduction in patients with CRPS.^[32,34] Randomized controlled trials from the Netherlands have

Table 5: Oral medications used in the treatment of CRPS

Drug	Dosage (mg)		Side-Effects
	Initial dose	Maintenance dose	
Oxycodone	10 mg tid	10-80 mg tid	Nausea, dry mouth, hives, hallucination
Gabapentin	100 mg tid	300-600 mg tid	Ataxia, dizziness, somnolence, purpura, fatigue
Nifedipine	10 mg tid	10-30 mg tid	Headache, postural hypotension
Alendronate	40 mg OD	40 mg OD	Nausea, dizziness, heartburn, jaw numbness
Amitriptyline	10 mg ON	25-75 mg ON	Drowsiness
Prednisone	30 mg tid	Tapering dose	Adrenal suppression, avascular necrosis
Phenytoin	50 mg OD	50-100 mg tid	Ataxia, liver damage, convulsion
Pregabalin	50 mg tid	50-200 mg tid	Dizziness, somnolence, peripheral oedema
Fluoxetine	20 mg OD	20-80 mg OD	Headache, postural hypotension

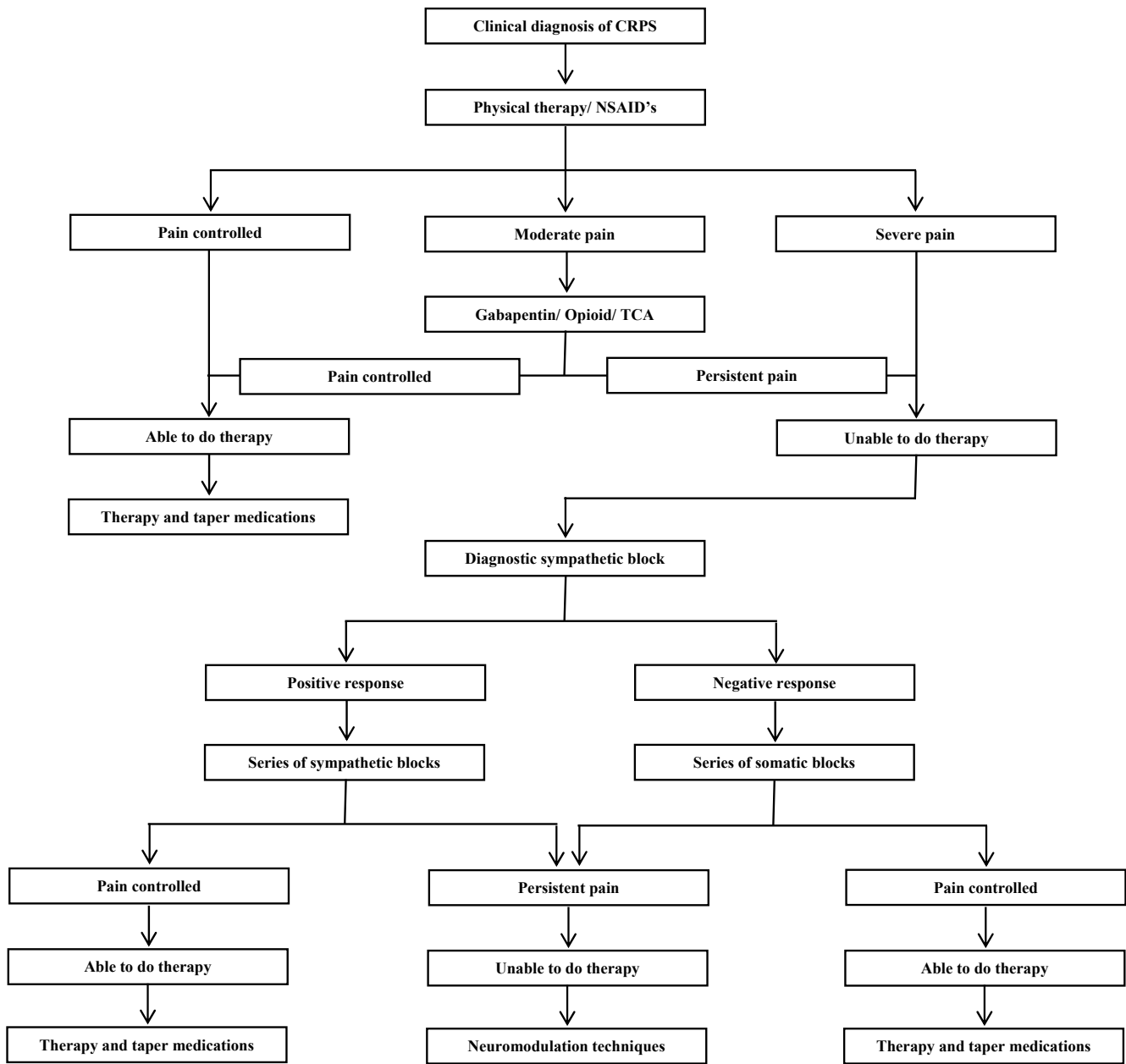


Figure 5: Algorithm for the treatment of CRPS^[38]

shown promising results with the use of free radical scavengers [topical application of 50% dimethylsulfoxide (DMSO) and oral *N*-acetylcysteine(NAC)] in the treatment of CRPS.^[35] High dose vitamin C (500 mg/day) has been shown to have a prophylactic role in diminishing the incidence of CRPS in patients with distal radius fractures.^[36] There is also substantial anecdotal evidence for the efficacy of antidepressants (amitriptyline, nortriptyline, and doxepine), anticonvulsants (dilantin), opioids, topical capsaicin, and lignocaine transdermal in the treatment of CRPS.^[29] The dosage and major complications of use of the common pharmacologic

agents has been summarized in Table 5.

Regional anaesthesia techniques

These are useful in patients with moderate to severe pain that do not respond to physical and pharmacologic therapy. Two types of regional anaesthesia techniques are available, namely a sympathetic nerve block and a combined somatic and sympathetic nerve block. Sympathetic nerve blocks are chosen when the patient has marked improvement after a diagnostic sympathetic block. A somatic plus sympathetic block is used in patients who do not respond to the diagnostic sympathetic block.

Physical therapy should be initiated immediately after the block. A series of daily or every alternate day blocks using local anaesthetic agents is usually required for 1-3 weeks. Blocks are considered successful if the patient can participate in physical therapy and progresses in rehabilitation. If severe pain persists beyond 3 weeks, long-term pain-relieving options may need to be considered.^[12]

Neuromodulation

It involves modulation of central pain pathways by delivery of an electrical current or chemical application to the central neural axis. Neuromodulation techniques include spinal cord and peripheral nerve stimulation, TENS, and intrathecal injection of baclofen, clonidine, or opioids. These techniques are invasive and should be reserved for patients in whom other measures have failed.^[12]

Surgery

The benefit of surgical (and chemical sympathectomy) in CRPS has not been confirmed by controlled studies. In addition these procedures are associated with significant complications and therefore are not currently recommended in the treatment of CRPS.^[37] However, surgery has a role in management of nerve related nociceptive foci. The most common neural diagnoses contributing to CRPS are neuroma, neuroma-in-continuity, and secondary compression neuropathies.^[37]

One needs to address the nerve, the underlying tissue bed, and the overlying skin/ scar. The nerve should be explored by an extensible incision, freed of all adhesions, and evaluated using appropriate magnification. A complete release of the involved nerve should be done in patient with secondary compression neuropathies. Internal neurolysis should be avoided. In patients with a nerve transection or a neuroma-in-continuity, a tension free repair should be done and nerve grafts used, if required. Sural nerve grafts are preferred to medial or lateral antebrachial cutaneous nerves to avoid creating another nociceptive focus in the same extremity. Local fat, muscle or fascial flaps can be used to resurface a scarred bed. The nerve repair site can be wrapped using a vein graft or an artificial conduit. The adhesions between the skin and nerve can be managed by a Z-plasty, local transposition flaps, or a distant flap. It is important to secure meticulous haemostasis and avoid the use of constrictive postoperative dressings. The aim is to initiate physical therapy immediately after surgery and

appropriate continuous sympathetic blocks and/or drugs should be used for pain relief.^[3,37]

An algorithm for the treatment of CRPS is depicted in Figure 5.^[12]

CONCLUSIONS

The diagnosis of CRPS should be made cautiously. In patients who develop CRPS after surgery of the upper limb, one must look for an underlying nerve related nociceptive focus and treat it early before it gets to the chronic phase. Although outcomes for patients with CRPS are very difficult to predict, an early diagnosis and treatment increase the likelihood of a successful outcome. Mild cases respond to physical therapy, whereas moderate cases may require adjuvant analgesics, such as gabapentin and/or an anti-depressant medication. Patients with severe pain and/or sympathetic dysfunction require regional anaesthetic blockade to participate in physical therapy. A small percentage of patients with refractory, chronic pain will require long-term multidisciplinary treatment, including physical therapy, psychological support, and pain-relieving measures.

ACKNOWLEDGEMENT

I would like to thank Prof Kevin C. Chung (Section of Plastic Surgery, Department of Surgery, University of Michigan, Ann Arbor, USA) for his guidance in editing the manuscript and for providing all the clinical pictures.

REFERENCES

1. Merskey H, Bogduk N. Classifications of chronic pain: Description of chronic pain syndromes and definition of pain terms. Report by the International Association for the Study of Pain Task Force on Taxonomy In: Merskey H, Bogduk N, editor. Seattle: IASP Press; 1994.
2. Schott G. Complex? Regional? Pain? Syndrome? *Pract Neurol* 2007;7:145-57.
3. Li Z, Smith BP, Tuohy C, Smith TL, Andrew Koman L. Complex regional pain syndrome after hand surgery. *Hand Clin* 2010;26:281-9.
4. Dommerholt J. Complex regional pain syndrome-1: History, diagnostic criteria and etiology. *J Bodywork Ther* 2004;8:167-77.
5. Feliu MH, Edwards CL. Psychologic factors in the development of complex regional pain syndrome: History, myth, and evidence. *Clin J Pain* 2010;26:258-63.
6. Lau FH, Chung KC. Silas Weir Mitchell, MD: The physician who discovered causalgia. *J Hand Surg* 2004;29A:181-7.
7. Mitchell S, Morehouse G, Keen W. Gunshot wounds and other injuries of nerves. Philadelphia: JB Lippincott, 1864, p. 100-11. *Clin Orthop Relat Res* 1982;163:2-7.

8. Kline D, Hudson A. Pain of Nerve Origin. In: Kline D, Hudson A, editor. *Nerve Injuries: Operative Results for Major Nerve Injuries, Entrapments, and Tumors*. Philadelphia: WB Saunders; 1995. p. 515-7.
9. Sudeck P. U^{ber} die akute entzu^{ndliche} Knochenatrophie. *Arch Klin Chir* 1900;62:147-56.
10. Leriche R. De la causalgie envisage^e comme une ne^{vrite} du sympathique et de son traitement par la de^{nudation} et l'excision des plexus nerveux pe^{riarte} riels. *Presse Me^d* 1916;24: 178-80.
11. Evans J. Reflex sympathetic dystrophy. *Surg Gynecol Obstet* 1946;82:36-43.
12. Rho RH, Brewer RP, Lamer TJ, Wilson PR. Complex regional pain syndrome. *Mayo Clin Proc* 2002;77:174-80.
13. Harden R. A clinical approach to complex regional pain syndrome. *Clin J Pain* 2000;16:S26-32.
14. Stanton-Hicks M. Complex regional pain syndrome (Type I, RSD; Type II, causalgia): Controversies. *Clin J Pain* 2000;16(2 Suppl):S33-40.
15. Griep M. A follow-up study of 14 young adults with complex regional pain syndrome type I. *J Neurol Assoc* 2000;48:49-59.
16. Harden RN, Bruehl S, Stanton-Hicks M, Wilson PR. Proposed new diagnostic criteria for complex regional pain syndrome. *Pain Med* 2007;8:326-31.
17. Bonica J. Causalgia and other reflex sympathetic dystrophies. In: Bonica J, editor. *Management of pain*. Philadelphia: Lea and Feibiger; 1990. p. 220-43.
18. Bruehl S, Harden RN, Galer BS, Saltz S, Backonja M, Stanton-Hicks M. Complex regional pain syndrome: Are there distinct subtypes and sequential stages of the syndrome? *Pain* 2002;95:119-24.
19. Albazaz R, Wong Y, Homer-Vanniasinkam S. Complex regional pain syndrome: a review. *Ann Vasc Surg* 2008;22:297-306.
20. de Mos M, de Bruijn AG, Huygen FJ, Dieleman JP, Stricker BH, Sturkenboom MC. The incidence of complex regional pain syndrome: A population-based study. *Pain* 2007;129:12-20.
21. Sandroni P, Benrud-Larson L, McClelland R, Low PA. Complex regional pain syndrome type I: Incidence and prevalence in Olmsted county, a population-based study. *Pain* 2003;103: 199-207.
22. Veldman PH, Reynen HM, Arntz IE, Goris RJ. Signs and symptoms of reflex sympathetic dystrophy: Prospective study of 829 patients. *Lancet* 1993;342:1012-6.
23. Zyluk A. Complex regional pain syndrome type I. Risk factors, prevention and risk of recurrence. *J Hand Surg Br* 2004;29: 334-7.
24. Veldman P, Goris R. Multiple reflex sympathetic dystrophy. Which patients are at risk for developing a recurrence of reflex sympathetic dystrophy in the same or another limb. *Pain* 1996;64:463-6.
25. Collins E. Complex regional pain syndrome. In: Trumble T, Budoff J, Cornwall R, editors. *Hand, elbow, and shoulder: Core knowledge in orthopedics* Philadelphia: Mosby Elsevier; 2006. p. 255-9.
26. Schwarzer A, Maier C. Complex regional pain syndrome. In: Kopf A, Patel N, editors. *Guide to pain management in low resource settings*. Seattle: IASP Press; 2010. p. 249-54.
27. Bruehl S. An update on the pathophysiology of complex regional pain syndrome. *Anesthesiology* 2010;113:713-25.
28. Harden R, Bruehl S, Perez R, *et al.* Validation of proposed diagnostic criteria (the "Budapest Criteria") for Complex Regional Pain Syndrome. *Pain* 2010;11:1115-25.
29. Charlton J. Complex regional pain syndrome. In: Charlton J, editor. *Core curriculum for professional education in pain*. Seattle: IASP Press; 2005.
30. Harden RN. Objectification of the diagnostic criteria for CRPS. *Pain Med* 2010;11:1212-5.
31. Merskey H, Bogduk N. Part III: Pain Terms, A Current List with Definitions and Notes on Usage. In: Merskey H, Bogduk N, editors. *Classification of Chronic Pain, IASP Task Force on Taxonomy*. Seattle: IASP Press; 1994. p. 209-14.
32. Pontell D. A clinical approach to complex regional pain syndrome. *Clin Podiatr Med Surg* 2008;25:361-80, 6.
33. Sharma A, Williams K, Raja SN. Advances in treatment of complex regional pain syndrome: Recent insights on a perplexing disease. *Curr Opin Anaesthesiol* 2006;19:566-72.
34. Tran de QH, Duong S, Bertini P, Finlayson RJ. Treatment of complex regional pain syndrome: A review of the evidence. *Can J Anaesth* 2010;57:149-66.
35. Perez RS, Zuurmond WW, Bezemer PD, Kuik DJ, van Loenen AC, de Lange JJ, *et al.* The treatment of complex regional pain syndrome type I with free radical scavengers: A randomized controlled study. *Pain* 2003;102:297-307.
36. Zollinger P, Tuinebreijer W, Kreis R, Breederveld R. Effect of vitamin C on frequency of reflex sympathetic dystrophy in wrist fractures: A randomised trial. *Lancet* 1999;354:2025-8.
37. Koman L, Peohling G, Smith B, Smith T, Chloros G. Complex regional pain syndrome. In: Wolfe S, Hotchkiss R, Pederson W, Kozin S, editors. *Greens Operative Hand Surgery*. 6th ed. Philadelphia: Elsevier; 2010.
38. Rho R, Brewer R, Lamer T, Wilson P. Complex regional pain syndrome. *Mayo Clin Proc*. 2002;77:174-180

How to cite this article: Sebastin SJ. Complex regional pain syndrome. *Indian J Plast Surg* 2011;44:298-307.
Source of Support: Nil, **Conflict of Interest:** None declared.