

CASE REPORT

Gastrojejunostomy Stomal Polyp Presenting as Stomal Obstruction and its Endoscopic Management

Mohd Talha Noor, Onkar Prasad Patel, Bhagwan Singh Thakur

Department of Gastroenterology, Sri Aurobindo Institute of Medical Sciences (SAIMS), Indore, India

ABSTRACT

We report the case of a 42-year-old male who presented with postprandial, non bilious, non projectile vomiting for 4 months. Patient underwent gastrojejunostomy 10 years back for post corrosive gastric outlet obstruction. General physical and systemic examinations were within normal limits. Routine laboratory investigations including complete blood count, liver and renal function tests were also within normal limits. Upper gastrointestinal endoscopy revealed solitary pedunculated polyp at the gastrojejunostomy site almost completely obstructing the lumen at the gastrojejunostomy site. Endoscopic snare polypectomy of the gastrojejunostomy site polyp was done. Histopathological examination of the polyp was suggestive of hyperplastic polyp. After snare polypectomy patient became asymptomatic and is doing well at 6 months of follow up. (*J Dig Endosc* 2013;4(2):42-43)

Key Words: Gastric outlet obstruction – Gastrojejunostomy – Polyp – Polypectomy.

Introduction

Corrosive injury is among the commonest causes of benign gastric outlet obstruction.¹ Corrosive injury causes gastric cicatrization in approximately one third of patients and most of the patients with gastric outlet obstruction require gastrojejunostomy bypass surgery.²⁻⁴ Common complications of gastrojejunostomy include stomal stenosis and gastrojejunostomy site ulcer formation.¹ We present the case of a young male who presented with symptoms of gastric outlet obstruction related to gastrojejunostomy site polyp formation.

Case Report

A 42-year-old male presented with vomiting after meals since 4 months. Vomiting was non projectile, and non bilious. There was no history of pain abdomen, fever, weight loss, jaundice, hematemesis or constipation. There was history of gastrojejunostomy 10 years back for post corrosive injury gastric outlet obstruction. General physical and systemic examinations were within normal limits. Routine laboratory investigations including complete blood count,

serum electrolytes, liver and renal function tests were within normal limits. Erect abdominal X-ray and ultrasound abdomen were also normal. Upper gastrointestinal endoscopy revealed solitary pedunculated polyp at gastrojejunostomy site almost completely obstructing the lumen at the gastrojejunostomy site (Figure 1). Endoscopic snare polypectomy of the gastrojejunostomy site polyp was done (Figure 2). Histopathological examination of the polyp was suggestive of hyperplastic polyp. After snare polypectomy patient became asymptomatic and is doing well at 6 months of follow up.

Discussion

Development of polyp at the gastrojejunostomy site leading to gastric outlet obstruction is a rare complication of

Reprints requests and correspondence:

Mohd. Talha Noor, MD, DM

Department of Gastroenterology,

Sri Aurobindo Institute of Medical Sciences (SAIMS), Indore, India

Phone No.: 91-7314231751, 91-8305421496

Email: noorpgi@gmail.com, noorpgi@yahoo.com

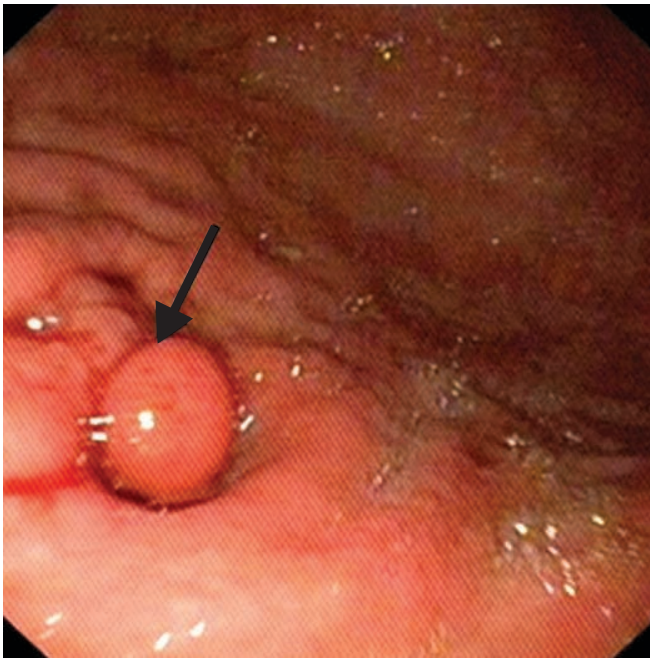

Figure 1: Upper gastrointestinal endoscopy showing a polyp at the gastrojejunostomy site almost completely obstructing the lumen (Arrow)

gastrojejunostomy. Although there are few reports in literature of development of polypoid lesions at the gastrojejunostomy site.^{6,7} But there is no report until now of its endoscopic management. Gastrojejunostomy site polyps are usually asymptomatic but they may manifest with features of gastric outlet obstruction as in our patient. Development of these hyperplastic polyps at the gastrojejunostomy site is postulated to be as a result of reflux of enteric contents into the gastric remnant.⁸

Gastrojejunostomy site polyp should be thought of in any post gastrojejunostomy patient presenting with symptoms of gastric outlet obstruction. These polyps are easily amenable to endoscopic polypectomy.

Conclusion

The development of polyp at the gastrojejunostomy site is rare. This report describes a 42-year male who presented with features of stomal obstruction. The polyp had grown to the extent to cause almost complete occlusion of the stomal opening. The polyp which on histology was hyperplastic, was successfully removed using endoscopic polypectomy.

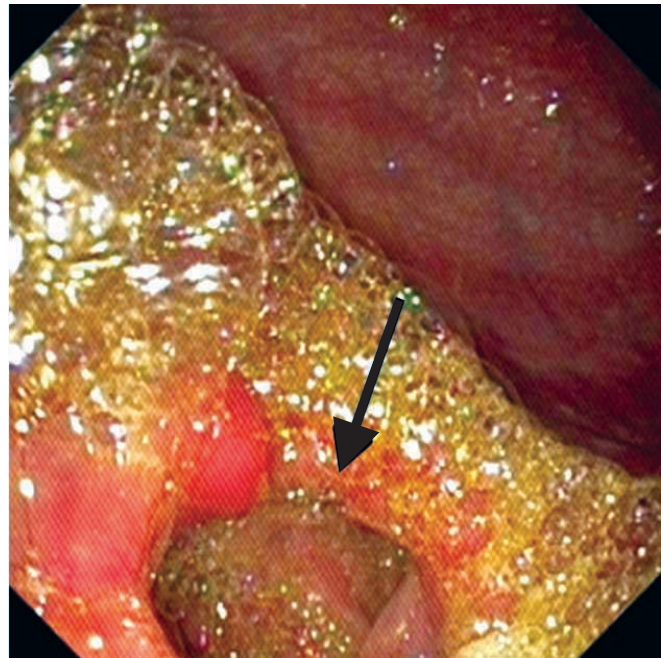


Figure 2: Post endoscopic snare polypectomy the lumen at the gastrojejunostomy site has opened up (Arrow)

References

1. Kochhar R, Kochhar S. Endoscopic balloon dilation for benign gastric outlet obstruction in adults. *World J Gastrointest Endosc* 2010;2:29–35.
2. Zargar SA, Kochhar R, Nagi B, Mehta S, Mehta SK. Ingestion of strong corrosive alkalis: spectrum of injury to upper gastrointestinal tract and natural history. *Am J Gastroenterol* 1992;87:337–41.
3. Zargar SA, Kochhar R, Nagi B, Mehta S, Mehta SK. Ingestion of corrosive acids: spectrum of injury to upper gastrointestinal tract and natural history. *Gastroenterology* 1989;97:702–7.
4. Sarfati E, Gossot D, Assens P, Celerier M. Management of caustic ingestion in adults. *Br J Surg* 1987;74:146–8.
5. Espinel J, Pinedo E. Stenosis in gastric bypass: Endoscopic management. *World J Gastrointest Endosc* 2012;4:290–295.
6. Jablokow VR, Aranha GV, Reyes CV. Gastric stomal polypoid hyperplasia: report of four cases. *J Surg Oncol* 1982;19:106–8.
7. Stemmermann GN, Hayashi T. Hyperplastic polyps of the gastric mucosa adjacent to gastroenterostomy stomas. *Am J Clin Pathol* 1979;71: 341–5.
8. Koga S, Watanabe H, Enjoji M. Stomal polypoid hypertrophic gastritis: a polypoid gastric lesion at gastroenterostomy site. *Cancer* 1979;43: 647–57.

Source of support: Nil; Conflict of interest: none declared