

Traumatic Cervical Spondyloptosis: Review of Literature and Case Report

Hitesh Inder Singh Rai¹ Kanwaljeet Garg¹

¹Department of Neurosurgery and Gamma Knife, All India Institute of Medical Sciences, New Delhi, India

Address for correspondence Kanwaljeet Garg, MBBS, MCh, Department of Neurosurgery and Gamma Knife, All India Institute of Medical Sciences, New Delhi 110029, India (e-mail: kanwaljeet84@gmail.com).

Indian J Neurotrauma 2019;16:45–48

Introduction

Spondyloptosis is defined as complete intercorporeal displacement which was first described in cervical spine by Bhojraj and Shahane.¹ Only a few case reports have been documented in literature as described below in the review of literature.^{1–23} Being a rare entity, several different management options have been described in literature ranging from conservative to 540-degree fusions.^{1–23} In this article, we have done a thorough review of literature on traumatic cervical spondyloptosis and also included our experience of a case we managed at our center.

Review of Literature

Studies describing cervical spondyloptosis are summarized in ►Table 1.

Case Report

A 33-year-old male had a fall from 12 to 15 feet height and sustained neck injury following which he became quadriplegic. He presented to our hospital, a tertiary level trauma center. His Glasgow Coma Scale was 15 and he was quadriplegic below the C5 level with intact sensations (American Spinal Injury Association [ASIA]-B). After initial resuscitation and securing patient's airway, he was screened for other injuries which revealed a left-sided hemothorax, for which an intercostal drain was inserted.

X-ray cervical spine showed no head injury and grade 4 anterolisthesis of C5 over C6 with spinal canal compromise (►Fig. 1A). Computed tomography angiography of neck showed left-sided vertebral artery injury.

He was admitted in the intensive care unit for further management. He was in acute renal failure and was not fit to be taken up for surgery. He was on inotropes which were gradually weaned off the next few days and implantable cardioverter defibrillator was removed after the lung expanded. When his vitals became stable and he was off inotropes, he was planned for surgery. X-ray neck lateral view was done before surgery which showed C5–6 spondyloptosis.

On the day of surgery, intraoperative cervical traction was applied with a 4-kg weight which reduced the listhesis to grade 3. After confirming the C5–6 level with image intensifier, anterior cervical approach was used. C5–6 discectomy was done. After freeing the uncovertebral joints bilaterally and adequate soft tissue release, listhesis was reduced completely by intraoperative manipulation (►Fig. 1B). Cerebrospinal fluid (CSF) leak was seen (noniatrogenic), which was plugged with tissue glue. C5–6 anterior cervical discectomy and fusion (ACDF) using polyetheretherketone cage was done and plating done thereafter (►Fig. 1C). A posterior surgery was planned to be done few days later as the patient's general condition was so good that he can tolerate anterior and posterior surgery in one go.

Postoperatively, he was on ventilator support with no changes in neurological examination. After a week of surgery, the patient developed meningitis for which appropriate antibiotics were started. Subsequently, he developed hydrocephalus for which external ventricular drain was placed. But the patient could not recover and died few weeks after surgery.

Discussion

Spondyloptosis represents the highest grade of instability with three-column involvement and complete segmental disruption. Cervical spondyloptosis is a rare entity that can be caused by trauma, congenital causes, or tumors of the spine.^{2,3} Several management strategies have been described in the literature.

Due to the severe nature of injury and dislocation, most patients present with deficits with very few having intact neurology as first described by Ozdogan et al in 1999.⁴ Our patient presented with complete loss of motor power and the sensation was intact below the C5 level (ASIA-B).

Preoperative reduction of dislocation with traction has been utilized by most of the surgeons but with only a few achieving complete closed reduction^{5–12} while others have to do open reduction. We could only achieve partial reduction till grade 3 on applying traction preoperatively. However, Dahdaleh et al have given an algorithm to use closed

Table 1 Summary of reports of spondyloptosis published in literature

Study	Age/ Sex	Level of injury	Mechanism of injury	Neurology preop	Neurology postop (follow-up)	Type of reduction	Surgery	Complications
Bhojraj and Shahane (1992) ¹	8/F	C6–7	Obstetric palsy	ASIA C	ASIA B	None	C5–7 corpectomy + anterior fusion without instrumentation	None
Amacher (1993) ¹⁷	7/M	C7-T1		Neck pain + hyperreflexia	Stable		Anterior cervical fusion C6-T1 + Posterior fixation C6-T3	
Sharma (2005) ⁹	15/M	C4–5	Fall from two-wheeler	Quadriplegic	Grade 3–4 power	Closed	C4–5 ACDF + plating	None
Lee et al (2007) ¹⁸	65/M	C7-T1	FFH	ASIA D	ASIA D	Open	Anterior C7–T1 discectomy and C7 corpectomy + C7 Laminectomy + facetectomy + C5-T2 instrumented fusion + anterior fusion with Pyra mesh (ACD-PF-AF)	Posterior dural injury with CSF leak managed by lumbar drain
	72/M	C7-T1	FFH	ASIA E	ASIA E	None	Conservative	Only 3 mo follow-up
Menku et al (2004) ¹⁹	35/M	C6–7	RTA	ASIA E	ASIA E	None	C5–6 ACDF + plating + C4–6 posterior instrumented fusion (ACD-PF-AF)	None
Tumialán et al (2009) ⁸	39/M	C7-T1	RTA	ASIA E	ASIA E	Closed with 60 lbs	C7-T1 ACDF + plating f/b C5-T2 posterior instrumented fusion	None
Acikbas and Gurkanlar (2010) ⁷	42/M	C7-T1	RTA	ASIA E	ASIA E	Closed	C7-T1 ACDF + plating f/b C4-T3 posterior instrumented fusion	None
Srivastava et al. (2010) ¹¹	35/M	C3–4	FFH 20 ft	ASIA E	ASIA E	Closed with 4 kg	C3–4 ACDF + plating	None
Chadha et al (2010) ¹²	35/M	C6–7	FFH 10 ft	ASIA A	ASIA A	Closed with 9.07 kg	C6–7 ACDF + plating	Dural leak found Poor general condition
Keskin et al (2013) ¹⁴	51/M	C6–7	RTA	ASIA D	ASIA E	Closed with 20 kg	C6–7 ACDF + plating f/b C6 laminectomy + C4-T2 posterior instrumented fusion	Dural leak found + lumbar drain placed postop
Dahdaleh et al (2013) ¹³	61/M	C7-T1	RTA	ASIA A	NR	Partial closed reduction with 23.6 kg f/b open	C3-T3 posterior instrumented fusion	Reduced to grade 1
	48/F	C6–7	Fall from stairs	ASIA D	ASIA E	Open	C6–7 ACDF + plating	None
	51/M	C7-T1	RTA	ASIA E	ASIA E	Partial closed reduction with 45 lbs f/b open	C4-T2 posterior instrumented fusion + facetectomy	None

(continued)

Table 1 (continued)

Study	Age/ Sex	Level of injury	Mechanism of injury	Neurology preop	Neurology postop (follow-up)	Type of reduction	Surgery	Complications
	48/M	C6-7	RTA	ASIA B	ASIA B	Partial closed reduction with 18 kg f/b open	C4-T1 posterior instrumented fusion + facetectomy	None
	42/M	C7-T1	RTA	ASIA C	ASIA D	Closed	C5-T2 posterior instrumented fusion	None
Ramieri et al (2014) ²⁰	55/M	C6-7	RTA	ASIA E	ASIA E	Partial closed reduction with 20 lbs f/b open	C3-T2 posterior instrumented fusion f/b anterior C6 corpectomy + fusion	None
Ahn et al (2015) ²¹	32/M	C7-T1	FFH 2 m	ASIA E	ASIA E	Failed closed reduction with 27.2 kg f/b open	C7-T2 posterior instrumented fusion + facetectomy f/b C7-T1 ACDF + plating	None
Modi et al (2016) ²²	35/M	C6-7	NR	ASIA A	ASIA A	Failed closed reduction with 30 pounds f/b open	C6-7 ACDF	None
	8/M	C7-T1	NR	ASIA A	NR	Conservative	Patient not willing	Severe spasticity with multiple bed sores and totally dependent
	70/M	C7-T1	NR	ASIA A	NR	Closed	Not operated due to comorbidities and high risk	Patient expired due to the multi-system failure
Wong et al (2017) ¹⁶	49/F	C5-6	RTA	ASIA A	ASIA A	Partial reduction with 13.6 kg f/b open	C5-7 ACDF + plating	Left VA dissection + occlusion
Fattahi and Tabibkhouei (2019) ⁶	18/F	C5-6	RTA	ASIA A	ASIA A	Closed at 25 lbs	C5 corpectomy + fusion + plating	CSF leak from traction pin site f/b meningitis + hydrocephalus and death
Kim et al (2019) ²³	60/M	C7-T1	FFH	ASIA A	ASIA D	Open	C7-T1 discectomy via posterior approach + C6-T1 posterior instrumented fusion	None
	39/M	C7-T1	FFH	ASIA D	ASIA E	Open	C6-T2 posterior instrumented fusion	None
Our case	33/M	C5-6	FFH	ASIA B	ASIA B	Partial reduction with 4 kg f/b open	C5-6 ACDF	Dural leak found

Abbreviations: ACDF, anterior cervical discectomy and fusion; ACD-PF-AF, anterior cervical discectomy and posterior and anterior fusion; ASIA, American Spinal Injury Association; CSF, cerebrospinal fluid; FFH, fall from height; RTA, road traffic accident; VA, vertebral artery.

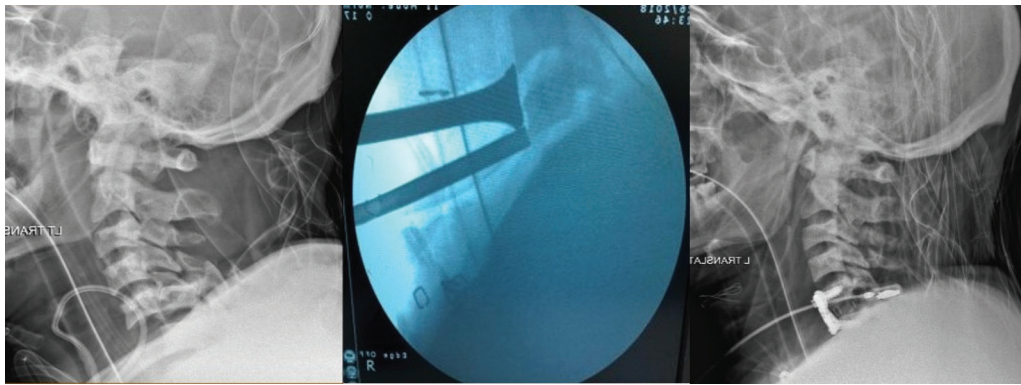


Fig. 1 Preoperative, intraoperative, and postoperative X-ray cervical spine showing spondyloptosis (A), intraoperative manipulation being done (B), and postoperative X-ray showing complete reduction and fixation using polyetheretherketone (PEEK) cage and anterior cervical plate (C).

reduction method only if there is no anterior compression on the spinal cord, otherwise patient can have increased neurological deficits.¹³

While attempting open reduction after failed/partial closed reduction, all the authors have used posterior approach to release the muscle/ligaments ± facetectomies. We have used only anterior single-step approach to reduce the listhesis completely and then did ACDF.

Regarding complications, CSF leaks due to high-grade dislocation (noniatrogenic) have been seen by few authors including us but none of the authors reported meningitis or wound leaks afterwards.^{12,14} Our patient had meningitis which led to hydrocephalus and subsequent septicemia leading to death of the patient.

Basilar artery thrombosis¹⁵ and vertebral artery thrombosis¹⁶ have also been reported. Our case also had left vertebral artery thrombosis preoperatively which was managed on anticoagulants postoperatively without any posterior fossa ischemic events.

Conflicts of Interest

None declared.

References

- 1 Bhojraj SY, Shahane SM. Posttraumatic cervical spondyloptosis at C6-7 with late-onset cord compression: a new clinical entity. Case report. *J Neurosurg* 1992;77(5):792-794
- 2 Akay KM, Ersahin Y, Tabur E. Cervical spondyloptosis: a case report. *Minim Invasive Neurosurg* 2002;45(3):169-172
- 3 Goffin J, Grob D. Spondyloptosis of the cervical spine in neurofibromatosis. A case report. *Spine* 1999;24(6):587-590
- 4 Ozdogan C, Gogusgeren MA, Dosoglu M. Posttraumatic cervical spondyloptosis: case report. *Turk J Trauma Emerg Surg* 1999;5:46-48
- 5 Shah KC, Rajshekhkar V. Successful management of post-traumatic C7-T1 spondyloptosis with uninstrumented ventral surgery. *Surg Neurol* 2004;62(5):431-434
- 6 Fattahi A, Tabibkhooei A. Traumatic cervical posterior spondyloptosis: report of a rare case. *Br J Neurosurg* 2019;1-2
- 7 Acikbas C, Gurkanlar D. Post-traumatic C7-T1 Spondyloptosis in a patient without neurological deficit: A case report. *Turk Neurosurg* 2010;20:257-260
- 8 Tumialán LM, Dadashev V, Laborde DV, Gupta SK. Management of traumatic cervical spondyloptosis in a neurologically intact patient: case report. *Spine* 2009;34(19):E703-E708

- 9 Sharma A. Traumatic spondyloptosis. *Indian J Neurotr* 2005;2:59
- 10 Padwal A, Shukla D, Bhat DI, Somanna S, Devi BI. Post-traumatic cervical spondyloptosis: a rare entity with multiple management options. *J Clin Neurosci* 2016;28:61-66
- 11 Srivastava SK, Agrawal KM, Sharma AK, Agrawal MD, Bhosale SK, Renganathan SR. C3-C4 spondyloptosis without neurological deficit—a case report. *Spine J* 2010;10(7):e16-e20 e
- 12 Chadha M, Singh AP, Singh AP. Spondyloptosis of C6-C7: a rare case report. *Chin J Traumatol*; 2010 13:377-379
- 13 Dahdaleh NS, Dlouhy BJ, Greenlee JDW, Smoker WRK, Hitchon PW. An algorithm for the management of posttraumatic cervical spondyloptosis. *J Clin Neurosci* 2013;20(7):951-957
- 14 Keskin F, Kalkan E, Erdi F. The surgical management of traumatic c6-c7 spondyloptosis. *J Korean Neurosurg Soc* 2013;53(1):49-51
- 15 Tumialán LM, Theodore N. Basilar artery thrombosis after reduction of cervical spondyloptosis: a cautionary report. *J Neurosurg Spine* 2012;16(5):492-496
- 16 Wong KE, Chang PS, Monasky MS, Samuelson RM. Traumatic spondyloptosis of the cervical spine: a case report and discussion of worldwide treatment trends. *Surg Neurol Int* 2017;8:89
- 17 Amacher AL. Cervical spondyloptosis. *J Neurosurg* 1993;78(5):853
- 18 Lee DG, Hwang SH, Lee CH. Clinical experience of traumatic C7-T1 spondyloptosis. *J Korean Neurosurg Soc* 2007;41:127-141
- 19 Menku A, Kurtsoy A, Tucer B, Oktem IS, Akdemir H. The surgical management of traumatic C6 - C7 spondyloptosis in a patient without neurological deficits. *Minim Invasive Neurosurg* 2004;47(4):242-244
- 20 Ramieri A, Domenicucci M, Cellocco P, Lenzi J, Dugoni DE, Costanzo G. Traumatic spondylolisthesis and spondyloptosis of the subaxial cervical spine without neurological deficits: closed re-alignment, surgical options and literature review. *Eur Spine J* 2014;23(Suppl 6):658-663
- 21 Ahn T-K, Chung Y-S, Kim M-S, Han I. High-grade traumatic spondylolisthesis of C7 on T1 with no neurological deficit. *Nerve* 2015;1:37-39
- 22 Modi JV, Soman SM, Dalal S. Traumatic cervical spondyloptosis of the subaxial cervical spine: a case series with a literature review and a new classification. *Asian Spine J* 2016;10(6):1058-1064
- 23 Kim MW, Lee SB, Park JH. Cervical spondyloptosis successfully treated with only posterior short segment fusion using cervical pedicle screw fixation. *Neurol Med Chir (Tokyo)* 2019;59(1):33-38