

## Original Article

# Peroperative evaluation of vascularity of various flaps by fluorescein technique

V. Bhattacharya, Sunish Goyal, Nepram Sanjib Singh, H. Manihar Singh\*, Sheikh Adil Bashir

Department of Plastic Surgery, Institute of Medical Sciences, Banaras Hindu University, Varanasi - 221 005; \*Department of Surgery, Regional Institute of Medical Sciences, Imphal - 795 004, India

**Address for correspondence:** V. Bhattacharya, B-33/14-16, Gandhi Nagar, Naria, Varanasi - 221 005, Uttar Pradesh, India.  
E-mail: visweswar1@rediffmail.com

### ABSTRACT

**Background:** The viability of any pedicled flap depends upon its vascularity. When a flap is dissected it becomes relatively ischaemic. Ultimately, the viability of the flap depends on the vessels incorporated in the pedicle and their perfusion capacity. There are different techniques to evaluate the blood supply of a flap.

**Aims:** This study deals with experimental and clinical efficiency of fluorescein dye technique to evaluate the vascularity of flaps of various compositions.

**Materials and Methods:** The experimental study was conducted on rats to standardize the technique. Thereafter clinical evaluation was conducted for different flaps namely fasciocutaneous, skeletonized perforator based fasciocutaneous, adipofascial, fasciocutaneous flap with adipofascial extension, fasciocutaneous flap with fascial extension and fasciocutaneous flap with split fascial extension.

**Conclusions:** The paper deals in detail with the technique and method of documentation of a fluorescein study on flaps both experimentally and clinically. The appearance of fluorescein on both the surfaces and distal margin of the flap confirmed the adequacy of vascularity soon after dissection of the flaps. It was found to be an easy, safe and reliable objective method.

### KEY WORDS

Peroperative fluorescein dye study, vascularity, flaps

### INTRODUCTION

When a flap is dissected it becomes relatively ischaemic since most of the blood supply is severed except the vessels in the pedicle which can be enough for the survivability of the flap if it is properly designed. Various methods to determine the adequacy of vascularity, both intraoperative and postoperative, have been described. The technique should be accurate, repeatable, simple, safe, easy and applicable to all types of flaps. Few techniques satisfy the above criteria. The fluorescein perfusion method

meets most of them. If it is used during the surgical procedure in a dissected flap prior to inseting, any adverse status of vascularity can be identified at that stage. This enables the surgeon to initiate timely and suitable preventive measures to improve the circulation or an additional maneuver can be planned.

The technique was standardized in an experimental model on rats. Thereafter it was clinically used on various types of flaps based on the perforators of lower and upper limbs. Antegrade and retrograde flaps of different compositions were studied.

## MATERIALS AND METHODS

The study consisted of two parts, an experimental part and then its clinical application. Formal permission was taken from the appropriate ethics committees of our institute for conducting both the animal experiments and clinical research.

### Experimental study

Twenty male Charles-Foster rats, each weighing approximately 300 gm were used. The animals were anaesthetized with intraperitoneal sodium barbitone (30 mg/kg). The dorsum was depilated. Caudally based random flaps (skin and panniculus) of  $2 \times 6$  cm<sup>2</sup> were raised and every centimeter was marked for observation. A polythene film was kept as a barrier between the flap and the bed prior to suturing to prevent absorption of dye by the flap from the bed. The femoral artery was isolated and cannulated. Fluorescein sodium (30 mg/kg) was injected 20 minutes after raising the flap. 20 minutes following the injection, flaps were observed under ultraviolet light in darkness. On day one the length of flap giving fluorescence was marked for later comparison with actual survivability. The proximal bright and intermediate zones of yellowish green fluorescence and a distal dark zone was recorded and documented photographically. Flaps were observed daily for seven days. Length of the flaps which survived were compared with fluorescence zones of day one.

### Clinical application

Thirty patients (25 males and 5 females) were studied in

whom flaps of various compositions were used in the lower and upper limbs. Informed consent was taken. The patients required reconstruction following (a) excision of tumour at knee n=1 (b) post traumatic exposed tibia in upper and middle third of leg n=6 (c) non-union or exposed fracture lower third of tibia n=9 (d) defects over ankle, heel and unstable scar dorsum of foot n=10 (f) defects over wrist following electrical burn n=3 (g) exposed tendons on dorsum of hand n=1.

All the patients were tested for sensitivity to the dye (fluorescein sodium) by injecting 0.05 ml intradermally. Fascio cutaneous, skeletonized perforator based fasciocutaneous flap, adipofascial, fasciocutaneous flap with adipofascial extension, fasciocutaneous flap with fascial extension and fasciocutaneous flap with split fascial extension were studied [Table 1].

The flaps were either antegrade or retrograde in nature. Out of 16 fasciocutaneous flaps in the lower limb, 4 were antegrade based on the proximal perforator of peroneal artery. Out of 12 retrograde flaps, 5 were perfused by lower perforators of posterior tibial artery and 7 by distal peroneal perforators. Two cases of skeletonized distal perforator based retrograde fasciocutaneous flaps were studied one each of posterior tibial and peroneal vessel. Out of 3 fasciocutaneous flaps with adipofascial extension, one was antegrade based on posterior tibial artery perforators and two were retrograde based on peroneal perforators. Two cases of fasciocutaneous flaps with fascial extensions perfused by distal peroneal perforators were studied. One split fascial flap based on distal

**Table 1: Distribution of flaps studied by fluorescein technique**

<i>Composition</i>	<i>No. of flaps</i>	<i>Antegrade retrograde</i>	<i>Supplying vessel (perforators of)</i>
Fasciocutaneous flap	16	4 12	Posterior tibial artery - 4 Posterior tibial artery - 5 Peroneal artery - 7
Skeletonized perforator based fasciocutaneous flap	2	0 2	0 Posterior tibial artery - 1 Peroneal artery - 1
Adipofascial Flaps in Lower limb	4	1 3	Posterior tibial artery - 1 Posterior tibial artery - 1 Peroneal artery - 2
Adipofascial flapUpper limb	2	0 2	0 Radial artery - 2
Fasciocutaneous flap with adipofascial extension	3	1 2	Posterior tibial artery - 1 Peroneal artery - 2
Fasciocutaneous flap with Fascial extension	2	0 2	0 Peroneal artery - 2
Split fascial flap	1	0 1	0 Posterior tibial artery - 1

posterior tibial perforators was evaluated.

Adipofascial flaps in the lower limb constituted antegrade posterior tibial artery perforator based flap (n=1), retrograde posterior tibial artery perforator based flap (n=1) and lower peroneal artery perforator based retrograde flap (n=2). In the upper limb, adipofascial flaps (n=2) based on distal radial perforators were evaluated

The patients were operated under general anaesthesia or epidural spinal anaesthesia. An area of 2x1 cm<sup>2</sup> was de-epithelialized in the distal most part of the fasciocutaneous flaps to allow visualization of fluorescence as melanin pigment of epidermis blocks the observation of the dye. 20% fluorescein dye (30 mg/kg) was injected intravenously 20 minutes after dissecting the flaps. 20 minutes after the injection the operation theater was made dark using dark blue curtains and UV light was focused on the flap. All personnel wore UV light protective eyewear. Fluorescence was observed at the distal de-epithelialized area, margins and subfascial surface in case of fasciocutaneous flaps. In other types of flap it could be observed both on the subfascial as well as the subcutaneous/suprafascial surfaces. All flaps showed yellow green fluorescence till the distal part and no area of impaired perfusion was observed.

### Photography

A medium yellow filter (Y2 of Lumix company) was used over the camera lens for taking photograph in UV light, as it absorbs reflected UV as well as violet and blue radiation. A cable-operated camera mounted on a tripod was adjusted in B-mode. Exposure time was set to 25-30 seconds and aperture was kept at 5.6. An electronic photographic flash was directed towards the ceiling which gives appropriate diffuse light. Only de-epithelialized areas and margins showed fluorescence in fasciocutaneous flaps as all patients were dark skinned. In adipofascial flaps and fascial flaps it could be observed on both the surfaces.

## RESULTS

### Experimental group

On day one, three zones of fluorescence were observed from the base of the flaps. The first zone, immediately starting from the base, showed bright yellow green fluorescence. The second zone, just distal to the first,

showed intermediate fluorescence. Both these areas were designated as having adequate vascularity and survived completely. The third zone, beyond zone two, appeared dark. On day seven the flaps survived till the zones one and two and necrosed in zone three [Figures 1 and 2]. Extent of flap survival ranged from 3 cm to 4.5 cm i.e., from 1:1.5 to 1:2.25. Yellow discoloration of skin disappeared in about 12 hours.

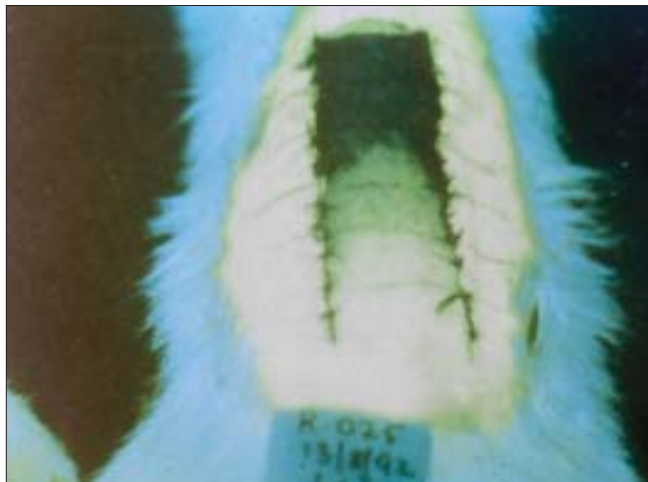
### Clinical group

Following injection of the dye yellow discoloration was seen on the whole body of the patients but was more marked over conjunctiva, palate, palm and sole where the surface is without the usual thick concentration of melanin.

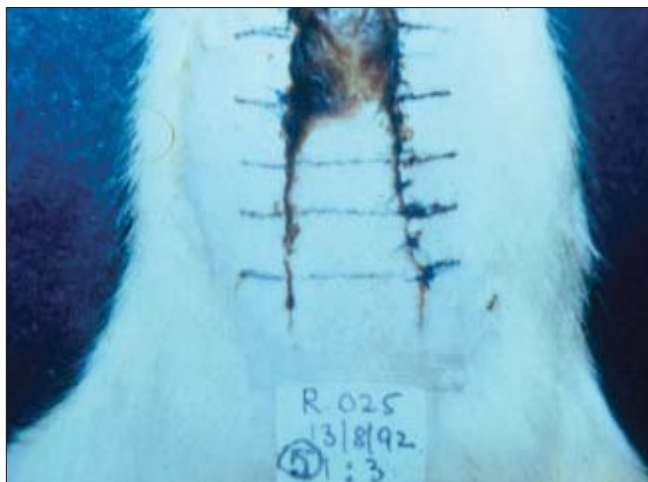
Twenty minutes after the injection of the dye the operating room was made dark. Fluorescence could be detected under UV light at the distal de-epithelialized area [Figure 3] and on the subfascial surface [Figure 4] of the fasciocutaneous flaps. It could also be detected on the margin of the flap because of exposed fascia and fat. Fluorescence could not be detected on the rest of the skin of the flap as it was blocked by melanin. In adipofascial flaps [Figure 5] and fascial flaps [Figure 6] the dye could be observed on both the surfaces. None of the patients showed hypersensitivity. Yellow discoloration of skin disappeared in 36 hours as the dye is excreted through urine, till then the flap can be repeatedly observed under ultraviolet light. No complication was encountered. In this group all flaps showed good vascularity in keeping with sound design parameters and no flap was lost partly or fully.

## DISCUSSION

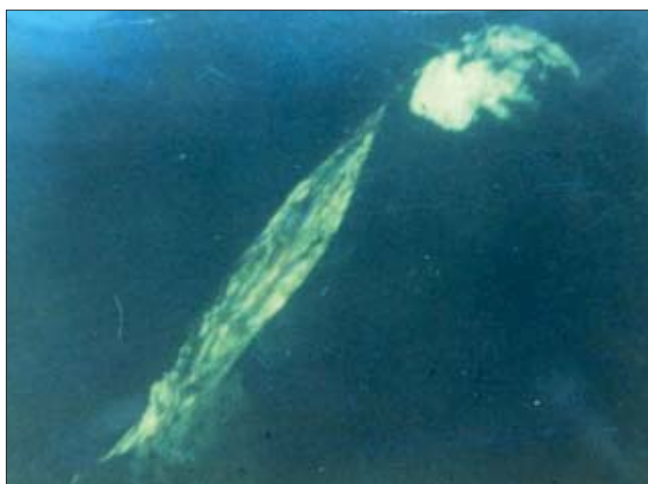Dissection of a flap causes transient reduction in the flow of blood, as it is dependent only on vessels in the pedicle. To determine the fate of the flap intra-operatively we need a technique which is not harmful to the patient, would not alter the flap physiology, is simple, cheap, applicable to all types of flap, objective and recordable. It should allow prolonged monitoring, be rapidly responsive to circulatory changes and be a simple display that could be assessed by all. Various methods available include the saline wheal test,<sup>[1]</sup> atropine test,<sup>[2]</sup> heat measuring devices,<sup>[3]</sup> photoplethysmometer,<sup>[4]</sup> the hydrogen electrode, the laser and colour dopplers,<sup>[5]</sup> near infrared reflection spectroscope microflowmeter,<sup>[5]</sup>



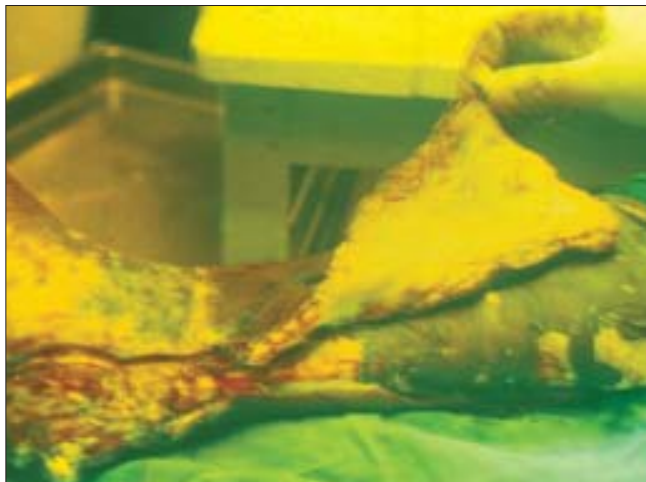
**Figure 1:** Showing three zones of fluorescence on day one in experimental model



**Figure 2:** Showing extent of survivability on day seven matching the day one observation in experimental model



**Figure 3:** Showing fluorescence at the distal de-epithelialised area and margins of a retrograde fasciocutaneous flap



**Figure 4:** Peroperative fluorescence observed on the subfascial surface in a retrograde medial skeletonized perforator based flap

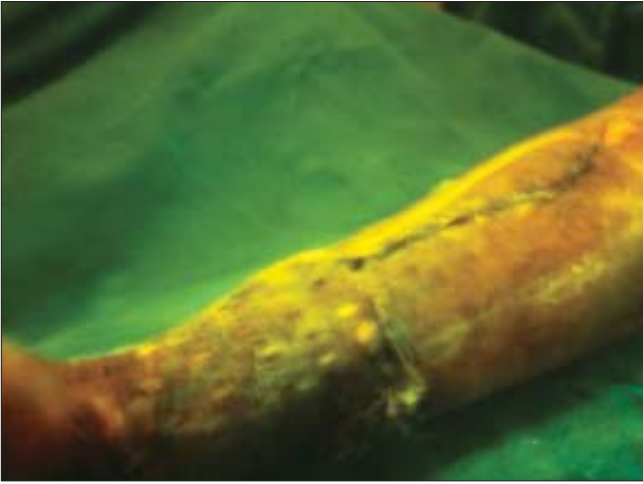


**Figure 5:** Dye visualized on the subcutaneous surface of the retrograde adipofascial flap



**Figure 6:** Brilliant fluorescence in the fascial extension of fasciocutaneous flap





**Figure 7:** Visualization of fluorescein dye through the perforated split thickness skin graft over an adipofascial flap after 24 hours

various probes which measure oxygen, CO<sub>2</sub><sup>[6]</sup> and pH.<sup>[7]</sup> There are also techniques, which study clearance of radioactive substances<sup>[8]</sup> and dyes that stain tissues. Various dyes have been used e.g., bromophenol, disulphine patent blue,<sup>[9]</sup> vicodane, xylenol orange and fluorescein.<sup>[10-14]</sup> Fluorescein study is easy, cheap, reliable and can be documented photographically. It is accurate in predicting the viability of the flaps.

Fluorescein has the unique property of emitting a yellow green fluorescence at a wavelength of 510 to 600 nm when excited by UV or blue light. In living tissue the dye appears bright yellow while areas without blood flow appear dark blue as they reflect all UV light. Fluorescein also rapidly diffuses from intravascular to extravascular space and can be used for evaluating tissue perfusion.

Ehrlich first used fluorescein in 1882 for study of fluid in the anterior chamber of the eye. Koch used it in 1922 to study the speed of blood flow. Lange and Boyd first used intravenous fluorescein in 1942 to evaluate the peripheral vascular function.<sup>[10]</sup> Dingwall and Lord modified the technique to determine the earliest possible time to transfer a tube pedicle flap.<sup>[11]</sup> Silverman *et al* described efficacy of fluorescein test to predict skin flap viability.<sup>[13]</sup>

We observed in the experimental study that the extent of survivability is not same keeping the flap breadth constant at 2 cm. Extent of flap survival ranged from 3-4.5 cm. The breadth: length ratio was 1:1.5 to 1:2.25. Majority of the flaps showed survival up to 4 cm. Three

zones were seen from proximal to distal, one with bright fluorescence which survived completely, second with intermediate fluorescence, which also survived, but some amount of epidermal necrosis was present in three animals. Third zone with no fluorescence or dark zone underwent necrosis. Similar observations were also made by other authors.

In clinical cases the dye was injected 20 minutes after dissecting the flap. Thereafter we waited 20 minutes before observing the flap under ultraviolet light. Thus, more than 40 minutes lapsed between the dissection and the observation. We felt that the period is sufficient to overcome the initial vasospasm caused by dissection, because the dye reached the distal part of the flap through the circulation. Myers and Donovan have mentioned that more than 24 hours are required to establish the vascular pattern that determines flap survival.<sup>[15]</sup> We feel that the initial vasospasm and the reorientation of the vascular pattern are two different entities, which take place in a sequence to establish the physiological haemodynamics of a flap. Therefore preoperative fluorescein study is a reliable indicator of the vascularity of a flap.

We have conducted this study in flaps of safe dimensions as per our experience. However if the fluorescein is not visualized at the distal part of a dissected flap prior to inseting, then adjuvant pharmacological therapy should be tried. This has been reported to have varying degree of efficacy in improving perfusion and survival of flaps. The most commonly used drug is low molecular weight dextran (40,000). This reduces blood viscosity and prevents RBC sludging by coating them and maintaining their electromagnetic charge. It also decreases platelet adhesiveness, inhibiting, platelet aggregation. Dextran is administered in a continuous intravenous infusion in the dose of 20 ml/Kg over 24 hours. After adequate infusion, following flap dissection, one needs to wait about an hour. If the dye is seen till the distal end, then inseting of the flap should be done. If the dye is still not seen at the distal part, the dark zone part of the flap should be excised and an additional small flap needs to be raised from the adjacent area to replace the distal excised flap.

In dark skinned people visualization of fluorescence is blocked by melanin. Hence, de-epithelialization of the distal skin is necessary. This was also described by

Asokan and Caffè.<sup>[14]</sup> The major advantage of fluorescein is that it allows observation of the whole flap at a time. It is therefore not subject to sampling error. The dye causes yellow discoloration of palm, sole and conjunctiva, which disappears in about 24 hours and urine fluorescence persists up to 36 hours. Due to this the flap can be examined repeatedly for fluorescence over the next 24 hours to assess vascularity. We observed some of these flaps 24 hours after surgery under the ultraviolet lamp where we could easily visualize the fluorescein in the sutured flap. This could be best demonstrated in adipofascial flap covered with perforated split thickness skin graft. The fluorescein could be distinctly seen through the perforations [Figure 7].

In the experimental study, the part of the flap showing bright fluorescence proved to have adequate vascularity and survived completely. The adjacent distal part showing intermediate fluorescence also survived but occasionally under went superficial patchy necrosis. The distal darkest area completely necrosed. Clinically, all the flaps showed fluorescence up to the distal end and survived completely. The problem of non visualization in dark skinned patients is overcome by deepithelialization of the distal most part of the flap. The fluorescein technique assesses the whole flap at a time and is not subject to sampling error. Complications with fluorescein dye are minimal and the dye is excreted in 36 hours through the kidney. The fluorescein study satisfies most of the criteria of an ideal technique for evaluating peroperative vascularity of flaps. It is accurate, reliable, rapid, simple, cheap, objective, recordable and harmless to the patient and the flap

## REFERENCES

1. Conway H, Stark RB, Doktor JP. Vascularisation of tubed pedicles. *Plast Reconstr Surg* 1949;4:133-8.
2. Hynes W. A simple method of estimating blood flow with special reference to the circulation in pedicle skin flaps and tubes. *Plast Reconstr Surg* 1948;1:159-66.
3. Maitz PK, Khot MB, Mayer HF, Martin GT, Pribaz JJ, Bowman HF, *et al.* Continuous and real-time blood perfusion monitoring in prefabricated flaps. *J Reconstr Microsurg* 2004;20:35-41.
4. Ben-Hur N, Mahler Y, Shulman J, Neuman Z. A study of the peripheral blood flow in skin tube flaps by photoconductive plethysmography. *Isr J Med Sci* 1966;2:218-24.
5. Scheuffler O, Exner K, Anerson R. Investigation of TRAM flap oxygenation and perfusion by near-infrared reflection spectroscopy and color-coded duplex sonography. *Plast Reconstr Surg* 2004;113:141-52; discussion 153-5.
6. Douglas B, Millikan GA. The blood circulation in pedicle flaps. Preliminary studies on a photoelectric test for determining its efficiency. *Plast Reconstr Surg* 1947;2:348-53.
7. Glinz W, Claudius L. Measurement of tissue pH for viability in pedicle flaps: Experimental studies in pigs. *Br J Plast Surg* 1972;25:111-5.
8. Conway H, Roswit B, Stark RB, Yalow R. Radioactive sodium clearance test as a test of circulatory efficiency of tubed pedicles and flaps. *Proc Soc Exp Biol Med* 1951;77:348-52.
9. Teich Alasia S. A study of vascularisation of pedicled flaps using disulphine blue. *Br J Plast Surg* 1971;24:282-8.
10. Lange K, Boyd LJ. The use of fluorescein to determine the adequacy of the circulation. *Med Clin North Am* 1942;26:143-7.
11. Dingwall JE, Lord JW Jr. The fluorescein test in the management of tubed (pedicled) flaps. *Bull John Hopkins Hosp* 1943;73:129-31.
12. Biller HF. Pedicled flaps: An experimental and clinical study. *Laryngoscope* 1972;83:1831-7.
13. Silverman DG, Norton KJ, Brousseau D. A Serial fluorometric documentation of fluorescein dye delivery. *Surgery* 1985;97:185-93.
14. Asokan R, Caffè HH. Fluorescein test in dark skinned patient. *Plast Reconstr Surg* 1980;66:766-8.
15. Myers MB, Donovan W. An evaluation of eight methods of using fluorescein to predict viability of skin flaps in the pig. *Plast Reconstr Surg* 1985;75:245-50.