

## Original Article

# Management of acute open tendo-achilles injuries in Indian lavatory pans

Sasanka S. Chatterjee, Arindam Sarkar, Ashutosh Misra

Department of Plastic Surgery, Institute of Post Graduate Medical Education and Research, Kolkata, India

**Address for correspondence:** S. S. Chatterjee, c/o Mr. P. Chatterjee, 84 SA/1B, Block-E, New Alipore, Kolkata - 700 053, India.  
E-mail: ssc\_dr2004@yahoo.co.uk

### ABSTRACT

Injuries to the Tendo-achilles are common but rarely do they present directly to plastic surgeons. Eighteen patients with acute tendo-achilles injury due to fall in the Indian type of lavatory pan came directly to the emergency department of Institute of Post Graduate Medical Education and Research, Kolkata and subsequently were treated in the Department of Plastic Surgery. Direct repair with prolene or stainless steel (SS) wires with or without flap cover were performed for management. Exercises were started 1 month later with gradual increase in activity. Complications were minor and temporary in nature. Long term results in the form of performing previous activities were excellent.

### KEY WORDS

Achilles tendon, acute Injury, Indian lavatory pan

### INTRODUCTION

Injury to Achilles' tendon may occur due to sports injuries, accidental cuts by sharp household tools, penetrating injuries and road traffic accidents. In urban India, another common mechanism of tendo-achilles injury is slipping of the foot in Indian type lavatory pans. The fall results in slipping of one foot into the hole of the pan thereby sustaining laceration or sharp cuts of skin and the tendo achilles. Squatting habit and the need to place the feet on the sides of the pan presumably lead to such accidents. There is a definite pattern of injury depending upon technique of extraction of the feet out of the hole of the pan. Absence of help and panic add to the problem as the patient is alone during injury. While in the western world, sports injuries are more common and facilities for guided physiotherapy are easily available, in India, judging by the nature of injuries and available facilities, our protocol

of management is different.

### MATERIALS AND METHODS

Eighteen patients presenting with acute open injuries of the tendo-achilles from July 1995 to October 2005 were included in this study. Of these, 15 were between March 2003 and October 2005. Seven of them were discharged after repair needing no admission. All the patients gave a history of slipping of the foot into the hole of a lavatory pan sustaining injury both during entry and extraction of the foot [Figures 1 and 2]. When the foot entered with ankle dorsiflexed, injury was severe as skin laceration was more pronounced.

The clinical profile of the patients is given in Table 1.

All patients presented within 8 hours of injury and received surgical treatment. As many as 8 patients had

**Table 1: Clinical profile of patients presenting with injuries to Tendo-achillies (TA)**

<b>Initials/ sex</b>	<b>Extent of injury/ site from insertion of TA</b>	<b>Delay in presentation following injury</b>	<b>Age (in yrs.)</b>	<b>Suture materials (repair was done with No. 1 prolene or 24G ss wire using crisscross sutures)</b>	<b>Complications/time of appearance of granuloma/ sinus after discharge</b>
AM/M	Skin laceration at two places, oblique cut at 2 cm	2 hrs.	15	Prolene, direct suture of skin with 3 '0' monofilament nylon after debridment	Granuloma, 8 weeks
AB/M	Skin laceration at two places, Transverse cuts at 2 and 5 cm	1.5 hrs.	14	Prolene, do	Minor skin edge necrosis, Granuloma and sinus, 6 weeks
SKM/F	Oblique skin and TA laceration at 7 cm	30 mins.	34	Prolene, do	Nil
TK/M	Transverse cuts of skin and TA at 3 cm	1 hr.	26	Prolene, do	Granuloma and sinus, 6 weeks
CP/M	Transverse cut at 2 and 6 cm (incomplete), multiple skin laceration	2 hr.	61	Prolene, local rotation flap after debridement	Minor skin edge necrosis, sinus, 4 weeks
AKMM	Oblique skin and TA injury at 5 cm	6 hrs.	19	Prolene, direct skin suture with 3 '0' monofilament nylon	Sinus, 4 weeks
BC/M	Transverse cut skin and TA 8 cm	4 hrs.	12	Prolene, do	Sinus, 5 weeks
GG/M	Transverse cut skin and TA at 2 cm	4 hrs.	16	Prolene, do	Granuloma and sinus, 4 weeks
RB/M	Oblique cut skin and TA at 5 cm	3 hrs.	29	Prolene, do	Sinus, 7 weeks
SB/M	Skin laceration resulting in avulsive loss and TA at 2 cm with avulsion	2.5 hrs	25	Prolene, perforator based flap advancement with 3 '0' monofilament nylon	Granuloma, 3 weeks, minor skin edge necrosis
KMM	Skin and TA at 4 cm oblique cut	2 hrs.	42	Prolene, direct skin suture with 3 '0' monofilament nylon	Granuloma, 2 weeks
CKB/F	Tranverse skin laceration with loss and TA injury at 1 cm	1.5 hrs.	32	Prolene, local rotation flap with 3 '0' monofilament nylon	Granuloma and sinus, 3 weeks
PKMM	Transverse cut skin and TA at 1.5 cm	1 hr.	23	SS wire with pull out suture on bolster, skin as before	Nil
DKB/M	Oblique cut skin and TA at 1.5 cm	8 hrs.	48	Do	Nil
RNMM	Transverse cut skin and TA at 1 cm	2.5	22	Do	Nil
PKDM	Transverse laceration skin and TA at 6 cm	2 hrs.	17	Do	Nil
SS/M	Multiple lacerations skin and TA, one complete section at 3 cm and one incomplete at 8 cm with puckered longitudinal intervening portion	1 hr.	36	Do, sural neurocutaneous island flap	Partial wound dehiscence, fibrotic reaction infection managed conservatively
MKDM	Oblique cut skin and TA at 2 cm	3 hrs.	18	SS wire pull out suture, skin with 3 '0' monofilament nylon	Nil

injury to TA within/at 2 cm of insertion of the tendon. Three patients sustained injuries at two sites of tendon [Figure 3] and in 4 cases skin lacerations demanded excision and debridment followed by reconstruction by local or regional flaps.<sup>[1]</sup> In the initial part of the study, criss cross sutures with 'No. 1' prolene was used for repair. Later on, noting the high rate of complications in the form of foreign body sinuses and granulomas, we switched over to use of stainless steel (SS) wires with bolsters at two places for ease of extraction. Post operative regime consisted of amoxicillin + clavulanic acid combination, with gentamicin and metronidazole or cefuroxime and metronidazole, all for 10 days, except gentamicin which was used for 5 days.

All legs were put in a POP cast or splint with 20° plantar flexion<sup>[2]</sup> for 3 weeks. After first dressing change on 5<sup>th</sup> post operative day, admitted patients were discharged

with advice to use crutches for 6 weeks. The skin sutures were removed 15-20 days post operatively depending on the wound condition and healing and SS wires were pulled out after 1 month. Patients were first asked to stand for increasing lengths of time but refrain from walking till 6 weeks. Between 6 and 12 weeks, patients increased activities and physiotherapy was performed but sporting activities were restricted till 6 months.

## RESULTS

When the surgical and therapeutic schedule described above was used, there was no case of re-rupture. The ultimate range of movement in the ankle was 57-70°. Three patients with follow up less than 5 months have been left out of the analysis as they have not been allowed to return to normal work yet. The follow up of the rest of the 15 patients ranged from 5 months [Figure

4] to 10 years [Figures 5-7]. Three patients were lost to follow up. The twelve patients who completed the study returned to their normal work and the period for return to normalcy ranged between 5 and 9 months. As many as 9 patients complained of some vague discomfort and 2 complained of paresthesia for about 9 months post operatively but none had permanent complaints. Minor skin edge necrosis occurred in 2 patients and partial wound dehiscence in one. The latter also showed fibrotic reaction.<sup>[2]</sup> There were no regular sportspersons in the series, though some patients occasionally described taking part in various sporting activities of local clubs. These patients did not complain of any problem while participating in their respective sport. There was one problem in all patients in whom prolene suture was used except one. They all had sinuses with or without granuloma formation beginning with mild discharge appearing post operatively after a varying period of 2 to

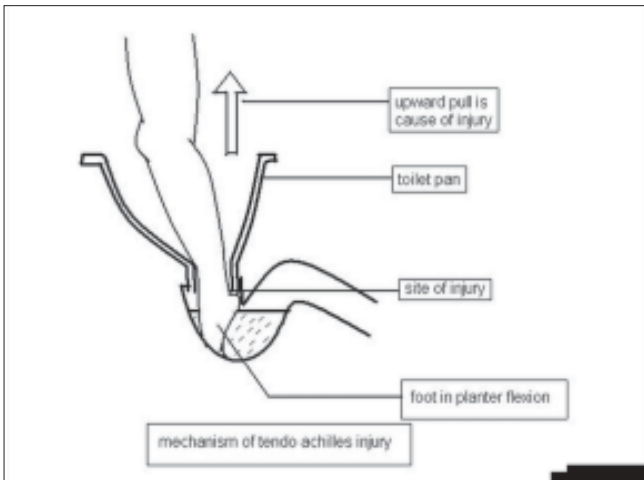
8 weeks. These gradually settled down with repeated courses of antibiotics at intervals in 5 patients but in as many as 6 patients prolene had to be removed 4 to 6 months after the operation. These were the only problems in the series with otherwise good end results. Patients in whom the tendon was repaired by SS wire did not have any such problem, except minor pressure effects on the skin at the sites of exit of the wire. This settled in 7-10 days time after pull out of the suture. Minor skin edge necrosis (<5 mm) in 3 patients responded to conservative dressings. The patient having sural neuro cutaneous flap had a partial wound dehiscence which settled with conservative treatment. All patients returned to their normal activities after a variable period of 5 to 9 months without complaints.

## DISCUSSION

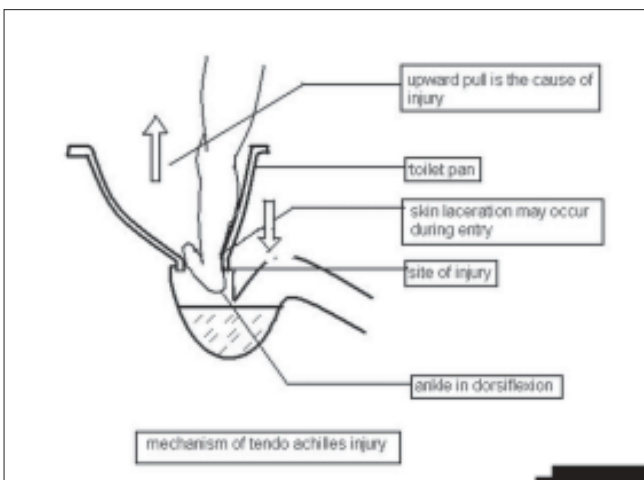
Literature is full of reports of rupture of Achilles tendon due to sports injuries.<sup>[3,4]</sup> Apart from sports injuries, Tendo-Achilles injuries may be a part of polytrauma from vehicular accidents. However, injuries due to lavatory pans are peculiar to the third world, crowded urban set up in South Asia where the population and available toilet facility ratio demands quick turnover and therefore hurry. The design of the pan and need to squat invites slipping of foot into the hole of pan. World literature has no mention of this type of injury.

In our series of eighteen, there were only two females showing their usual poise, cool and unhurried nature. Similarly, usually children are either not taken to the lavatory or are accompanied by their mother, hence the absence of children in the series. Despite contaminated nature of wounds, one advantage was early presentation by the patient, again emphasizing proximity to hospitals. Considering the ground realities faced by our patients, we remained conservative as regards starting early movements post operatively.<sup>[5-7]</sup> Our patients do not have the facilities and mind set for guided physiotherapy despite instructions. We allowed standing at one month gradually increasing the duration till 6 weeks.<sup>[8]</sup> Thereafter, activities were guided as per response of the patients.

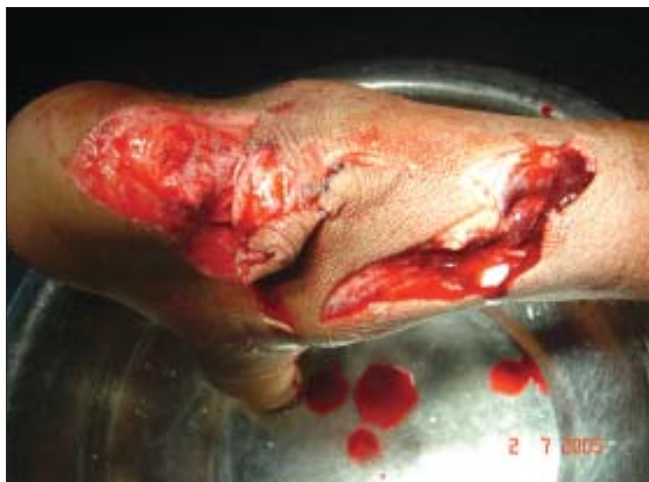Complications in tendo-achilles injuries mentioned in literature are skin edge necrosis, superficial wound infections, seroma formations, hematomas, re-rupture, fibrotic reactions, sural nerve irritations and deep vein thrombosis.<sup>[2,9]</sup> As mentioned, in our series the



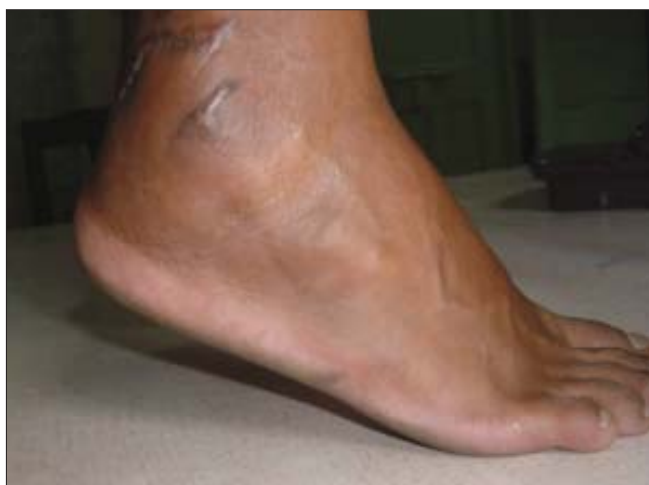**Figure 1:** Mechanism of injury in lavatory pans. Foot entering plantarflexed



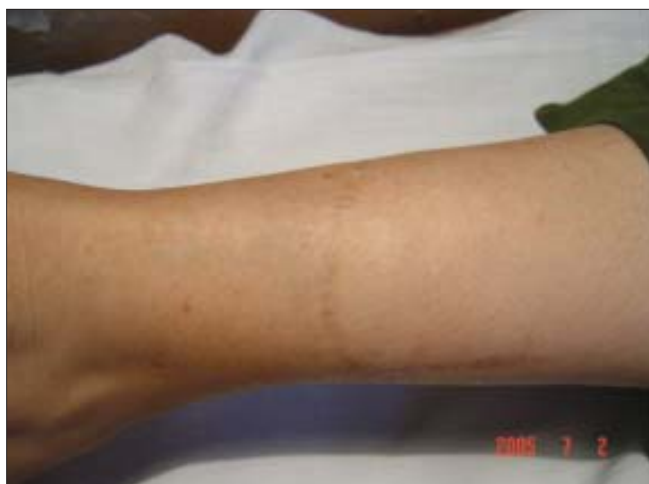**Figure 2:** Mechanism of injury in lavatory pans. Note that injury is more if the foot enters dorsiflexed



**Figure 3:** Patient sustained injury at two sites with multiple skin lacerations

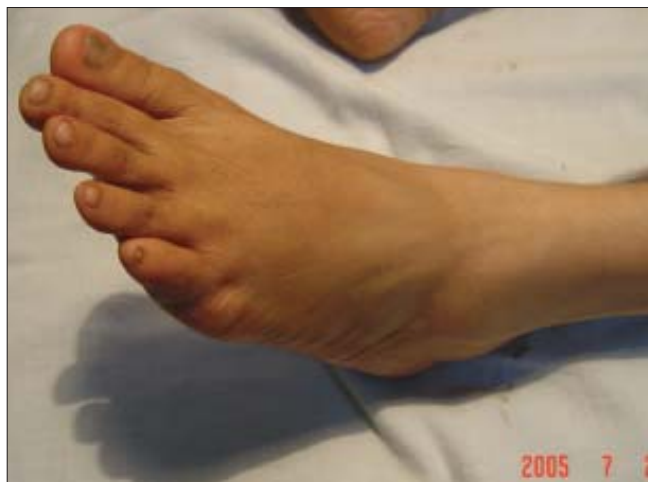

**Figure 4:** Patient sustained injury 5 months back and is able to stand on toes

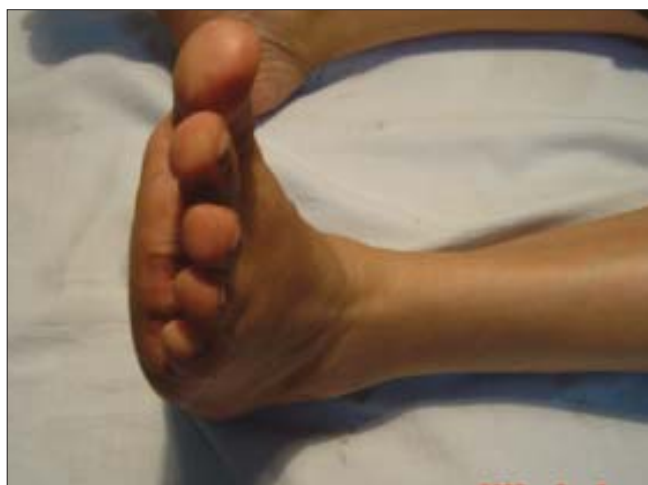

**Figure 5:** Scar of a patient with tendo achilles repaired 10 yrs. back

complications of prolene sinuses and granulomas are rather high (in 11 patients). This may be related to the presence of foreign body used for repair in contaminated injuries. Although this settled down after repeated courses



**Figure 6:** Range of motion of ankle joint in the same patient (Figure 5 )



**Figure 7:** Range of motion of ankle joint in the same patient (Figure 5 )

of antibiotics in 5 patients, we had to remove the suture knots and materials in 6 patients, Nine patients complained of some discomfort and this was perhaps due to reactions around the sural nerve while 2 complained of paresthesia. Minor skin edge necrosis and sural nerve irritation were present in 2 patients each and in one patient with partial dehiscence, we also encountered a fibrotic reaction. The range of motion we obtained is similar to other reports.<sup>[8]</sup>

## REFERENCES

1. Sadhotra LP, Singh M, Bhandari PS. A distally based superficial sural artery flap - for ankle defects. *Indian J Plast Surg* 2000;33:69-72.
2. Wills CA, Washburn S, Caiozzo V, Preitto CA. Achilles tendon rupture. A review of the literature comparing surgical versus non surgical treatment. *Clin Orthopaed Relat Res* 1986;207:156-63.
3. Cretnik A, Frank A. Incidence and outcome of rupture of Achilles tendon. *Wiener Klinische Wochenschrift* 2004;116:33-8.
4. Saltzman CL, Tearse DS. Achilles tendon injuries. *J Am Acad*

- Orthopaed Surg 1998;6:316-25.
5. Kerkhoffs GM, Strijs PA, Raaymakers EL, Marti RK. Functional treatment after surgical repair of acute Achilles tendon rupture: Wrap vs. walking cast. Arch Orthopaed Trauma Surg 2002;122:102-5.
  6. Mortensen HM, Skov O, Jensen PE. Early motion of ankle after operative treatment of a rupture of the Achilles tendon. A prospective, randomized clinical and radiographic study. J Bone Joint Surg 1999;81:983-90.
  7. Schafer D, Regazzoni P, Hintermann B. Early functional treatment of surgically managed Achilles tendon rupture. Unfallchirurg 2002;105:699-702.
  8. Porter DA, Mannarino FP, Snead D, Gabel SJ, Ostrowski M. Primary repair without augmentation for early neglected Achilles tendon ruptures in the recreational athlete. Foot Ankle Int 1997;18:557-64.
  9. Paavola M, Orava S, Leppilathi J, Kannus P, Jarvinen M. Chronic Achilles tendon overuse injury: Complications after surgical treatment. An analysis of 432 consecutive patients. Am J Sports Med 2000;28:77-82.