

## Case Report

# Emergency abdominoplasty following trauma

**M. Taifour Suliman**

King Khalid Civil Hospital, Tabuk, P. O. Box - 876, Saudi Arabia

**Address for correspondence:** M Taifour Suliman, King Khalid Civil Hospital, Tabuk, P O BOX.876, Saudi Arabia.

E-mail: mtaifour1@yahoo.com

### ABSTRACT

We report a case of modified abdominoplasty done on emergency basis to a 37 years old male with acute abdominal wall injury due to road traffic accident. We discuss the case and review the literature.

### KEY WORDS

Abdominoplasty, abdominal wall injury, emergency

### INTRODUCTION

Abdominal wall reconstruction as an emergency procedure is a difficult and rare problem. Usually it occurs as a result of trauma,<sup>[1-3]</sup> especially road traffic accidents. Reconstruction of such injuries in the acute phase is usually either direct closure of the wound or application of skin graft or, in few cases, local or free flaps.<sup>[1,2,4]</sup>

We describe repair of a traumatic abdominal wall disruption using modified abdominoplasty. To our knowledge, no similar case has been reported before.

### CASE REPORT

A 37 years old male was brought to the emergency department following severe abdominal trauma due to a road traffic accident. He was a healthy looking soldier, with no previous illness. Local examination revealed a long transverse wound extending between the anterior superior iliac spines horizontally, with degloving of the skin up to the level of the umbilicus vertically and with a laterally based triangular flap on the left side [Figure 1].

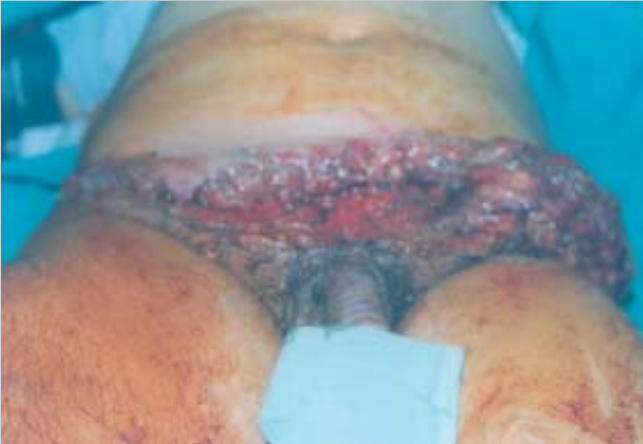There was also a 15x20 cm wound on the lateral aspect of the right thigh, with muscle tear.

He was taken to the operating room, after adequate preparation a thorough debridment was done, with excision of the degloved skin up to a level of 4 cm distal to the the umbilicus, together with the loose triangle.

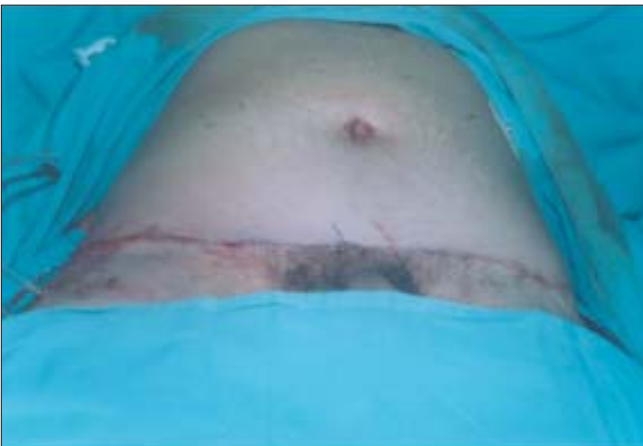
The resultant defect was closed as for an abdominoplasty [Figure 2], after mobilization of the skin above the umbilicus up to the costal margins using diathermy. Since the defect was not as large as in a classical abdominoplasty, the skin was pulled down to close the defect without mobilizing the umbilicus which was displaced distally by about 2 cm with slight tension without endangering its blood supply. The left side of the wound became infected five days postoperatively, but healed well following further debridment and antibiotic treatment. The patient was seen six months later in the outpatient clinic with no problems [Figure 3].

### DISCUSSION

Reconstruction of acute abdominal wall defects is a



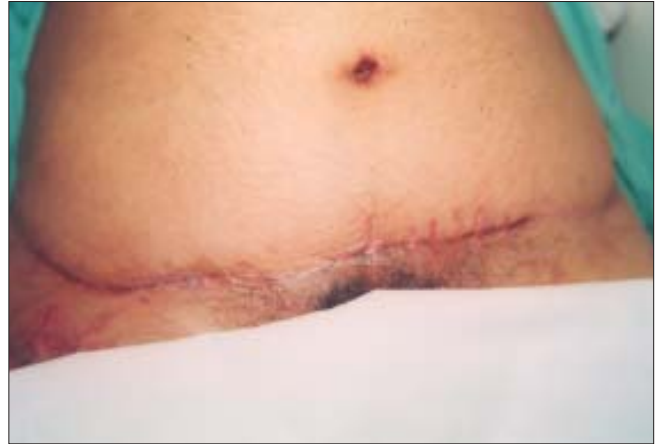**Figure 1:** The wound on the anterior abdominal wall



**Figure 2:** Immediate postoperative view after modified abdominoplasty

challenging problem for the surgeon, especially when large.<sup>[1,2]</sup> Most commonly it occurs following trauma,<sup>[1-4]</sup> as in our patient. The mechanism of injury is usually a degloving one, with the skin and subcutaneous tissue of the abdominal wall rolling-over the underlying relatively fixed fascia.<sup>[3]</sup>

Reconstructing such wounds is sometimes feasible by direct suturing if the wound is small. But in large defects, skin graft or even local or free flaps may be necessary.<sup>[1-4]</sup> In our case, the final defect after wound debridement, was too big to be closed primarily without tension, which may cause skin necrosis. So the solution was to mobilise the skin as in an abdominoplasty, but without dissecting out the umbilicus to bring it through a separate site so



**Figure 3:** The wound 6 months postoperatively

as to retain its normal anatomical position. Instead, we left it in its place and pulled down the mobilized skin to suture it to the distal suprapubic part with no tension, the umbilicus was brought slightly distally with no significant cosmetic disturbance. The patient did not complain of the slightly displaced umbilicus, which varies in height and is not always centrally placed.<sup>[5,6]</sup>

We conclude that, this modified abdominoplasty is a better option for reconstructing acute big lower abdominal wall defects as the cosmetic results are much better with no need for further operative procedures.

## REFERENCES

1. Brenneman FD, Boulanger BR, Antonyshyn O. Surgical management of abdominal wall disruption after blunt trauma. *J Trauma* 1995;39:539-44.
2. Okunski WJ, Sonntag BV, Murphy RX Jr. Staged reconstruction of abdominal wall defects after intra-abdominal catastrophes. *Ann Plast Surg* 1996;36:475.
3. Sonemez A, Bayramicli M, Numanoglu A. Degloving injury of the anterior abdominal wall. *Plast Reconstr Surg* 2002;110:363.
4. Ninkovic M, Kronberger P, Harpf C, Rumer A, Anderl H. Free innervated latissimus dorsi muscle flap for reconstruction of full-thickness abdominal wall defects. *Plast Reconstr Surg* 1998;101:971.
5. Rohrich RJ, Sorokin ES, Brown SA, Gibby DL. Is the umbilicus truly midline? Clinical and medicolegal implications. *Plast Reconstr Surg* 2003;112:259.
6. Surface Anatomy of the Abdomen <http://www.bartleby.com/107/pages/page1313.html>. (Henry Gray (1825–1861). *Anatomy of the Human Body*. 1918.)