

Cervicothoracic Junction Fractures Management: An Overview of Literature

Chinmaya Dash¹

¹Department of Neurosurgery (T&E), All India Institute of Medical Sciences, Bhubaneswar, Bhubaneswar, Odisha, India

Address for correspondence Chinmaya Dash, MCh, Department of Neurosurgery (T&E), All India Institute of Medical Sciences, Bhubaneswar, Bhubaneswar, Odisha 751019, India (e-mail: dr.chinu.dash@gmail.com).

Indian J Neurotrauma 2019;16:27–32

Abstract

Keywords

- ▶ cervicothoracic fracture
- ▶ cervicothoracic
- ▶ lower cervical fracture
- ▶ surgery for cervicothoracic fracture
- ▶ upper thoracic fracture

The cervicothoracic junction (CTJ) is a unique area of spine and is the junction between the mobile lordotic cervical spine and the rigid kyphotic thoracic spine. It extends from C6 through T4. The fractures of the CTJ are uncommon and not well known. The article focuses on biomechanics of cervicothoracic region, management strategies of fractures of cervicothoracic region, and reviews pertinent literature.

Introduction

The cervicothoracic junction (CTJ) is a unique area of spine and is the junction between the mobile lordotic cervical spine and the rigid kyphotic thoracic spine. It extends from C6 through T4. There are significant biomechanical forces acting on this region, thereby predisposing it to increasing loads and potential instability. It includes the lower brachial plexus, the thoracic outlet, and the superior mediastinum. The fractures of the CTJ are uncommon and not well known. Nichols et al reported¹ an incidence of approximately 9% of CTJ injuries out of 397 cervical spine injuries studied. However, delayed diagnosis or missed diagnosis lead to underestimation of the true incidence of CTJ injuries. Inadequate imaging and complicating comorbidities are the major factors resulting in their missed diagnosis at the initial evaluation. CTJ is a difficult zone to evaluate with X-rays as the shoulder obscures the image and hence their reliability is low. Computed tomography (CT) and magnetic resonance imaging (MRI) are of utmost value in evaluating CTJ injuries. Motor vehicle injuries and fall from height are the most common mode of injury associated with CTJ injuries. There should be a high index of suspicion in patients with concomitant head or chest injuries, concurrent spinal fractures, or acceleration-deceleration as the mechanism of injury.¹

Biomechanics and Operative Anatomy

The biomechanics at CTJ is unique as there is a transition from the lordotic mobile spine to the kyphotic and more rigid thoracic spine. This region represents a transition from the lateral masses of the cervical vertebra to the transverse processes of the thoracic spine and has a narrow spinal canal. The CTJ is exposed to significant forces, particularly in flexion and distraction. The anterior elements primarily transfer compressive forces between the adjacent vertebral bodies whereas the posterior spinal components are important for the attachment of supporting ligaments and resistance to the extremes of motion. The anterior and posterior longitudinal ligaments prevent extreme flexion and extension, whereas the intertransverse and capsular ligaments inhibit lateral bending and axial rotation. The rib cage and its sternal articulations also contribute to thoracic spine stability. Disruption to any two spinal columns at CTJ is considered unstable and should be treated accordingly. C7 vertebra is a transitional vertebra, and it has small, thin lateral masses compared with the rest of the subaxial cervical spine. Pedicle size increases gradually in width from 5.2 mm at C5 to 6.5 mm at C7. However, the height of the C7 pedicle still averages 6.9 mm. Considering the above factors, C7 vertebra is better suited for a pedicle screw rather than lateral mass screw.²

received
September 26, 2019
accepted
September 28, 2019

DOI <https://doi.org/10.1055/s-0039-1700621>
ISSN 0973-0508.

Copyright ©2019 Neurotrauma Society of India

Classification System

At present, there is no system which is unique to classify CTJ injuries. Allen and colleagues', Vaccaro et al's, and AO (Arbeitsgemeinschaft für Osteosynthesefragen) classification system have been applied to classify CTJ injuries.³

Management

Nonoperative

Cervicothoracic compression, a lateral mass, and spinous process fractures may be treated successfully with external orthosis or halo immobilization. More severe injuries, however, may require operative intervention.

Operative

The goals of management of traumatic injury to the CTJ are neural decompression, stabilization, restoration of anatomic spinal alignment, and early mobilization and rehabilitation.

Surgical Approaches

The surgical approaches to the CTJ depend upon the location of the pathology, local anatomy, medical comorbidities, and the familiarity of the operating surgeon with the local anatomy of this complex region (► **Tables 1** and **2**).

Anterior Approaches to the Cervicothoracic Junction^{4,5}

The following are the approaches:

- Used for
 - Access to the anterior C7–T1 through T1–T2 levels.
 - Decompression.
 - Reconstruction of the injured anterior spinal column.
 - Access to the lower levels may require partial resection of the manubrium and clavicle (transmanubrial window).
 - Formal sternotomy can be used for access to the upper thoracic spine below T2 (transsternal approach).
- Access to lower levels

Incision

The incision is made along the medial border of the sternocleidomastoid muscle till the sternal notch.

The position of the sternum relative to the CTJ on lateral radiograph or sagittal CT image can be used to estimate the level that can be accessed through the anterior approach.

Dissection

The platysma is divided in line with the skin incision.

The deep fascia is identified and split along the anteromedial border of the sternomastoid muscle.

Generous subplatysmal dissection facilitates easy exposure of the deeper anatomic layers.

The omohyoid muscle encountered at the level of C6 can be divided to improve exposure.

The sternohyoid and sternothyroid muscles can be divided to extend the exposure.

The carotid pulse is palpated and further dissection is performed medial to the carotid sheath.

Blunt dissection is done with a finger between the carotid sheath laterally and trachea and esophagus medially down to the prevertebral fascia.

For Transmanubrial Extension

The incision is extended along the proximal third of the sternum.

A manubriotomy may be sufficient to provide sufficient access.

For Sternoclavicular Approach

The incision is extended across the sternoclavicular joint and continued just medial to the lateral border of the manubrium.

The sternoclavicular joint is opened. The medial 3 cm of the clavicle is resected to facilitate access.

The resected clavicle segment can be used as a strut graft.

Blunt dissection is done up to the brachiocephalic trunk which is mobilized as needed.

The lung is protected using a sponge and retracted as required.

The prevertebral fascia is divided longitudinally to visualize the vertebra and the longus colli muscle.

The level is verified with fluoroscopy.

For the Trapdoor Approach⁶

The trapdoor approach is a more extensive approach wherein a low cervical dissection is combined with a transsternal approach with a thoracotomy to give a more expanded exposure. The incision is curved laterally from the midline sternotomy incision and goes along the intercostal region at the fourth intercostal space to the midaxillary line. This is followed by sternotomy with a thoracotomy at the fourth intercostal space. This approach allows access from the C3 down to the T4 or T5 level.

Closure

The split muscles are approximated and sutured.

The platysma is sutured followed by a subcutaneous and skin closure. Skin closure with a subcuticular suture enhances cosmesis.

A wound drain may be inserted through a separate stab incision.

Posterior Access to the Cervicothoracic Junction⁷

Incision

The skin and subcutaneous tissue are infiltrated with a 1:500,000 adrenaline solution to achieve hemostasis.

The exact location of the incision is identified with fluoroscopy and marked.

A midline skin incision is made centered over the marked segment.

Table 1 Various approach to cervicothoracic region enumerating indications and contraindications

Approach	Indications	Contraindications
Supraclavicular	<ul style="list-style-type: none"> • Spinal tumor or metastases • Deformity correction 	<ul style="list-style-type: none"> • Pathology below D1
Transsternal	<ul style="list-style-type: none"> • Vertebral body fractures • Spinal tumor or metastases • Infections • Herniated nucleus pulposus • Deformity correction 	<ul style="list-style-type: none"> • Poor medical condition
Transmanubrial transclavicular	<ul style="list-style-type: none"> • Vertebral body fractures • Spinal tumor or metastases • Infections • Herniated nucleus pulposus • Deformity correction 	<ul style="list-style-type: none"> • Poor medical condition
Trapdoor	<ul style="list-style-type: none"> • Vertebral body fractures • Spinal tumor or metastases • Infections • Herniated nucleus pulposus • Deformity correction 	<ul style="list-style-type: none"> • Poor medical condition
Costotransversectomy	<ul style="list-style-type: none"> • Vertebral body fractures • Infections • Herniated nucleus pulposus 	<ul style="list-style-type: none"> • Poor medical condition
Lateral extracavitary (lateral parascapular)	<ul style="list-style-type: none"> • Vertebral body fractures • Spinal tumor or metastases • Infections • Herniated nucleus pulposus • Deformity correction 	<ul style="list-style-type: none"> • Poor medical condition
Laminectomy	<ul style="list-style-type: none"> • Posterior element disease process only • Intramedullary tumors 	<ul style="list-style-type: none"> • Anterior vertebral body lesions, fractures, herniated disks, deformities
Thoracotomy/Transthoracic approach	<ul style="list-style-type: none"> • Vertebral body fractures • Spinal tumor or metastases • Infections • Herniated nucleus pulposus • Deformity correction 	<ul style="list-style-type: none"> • Poor medical condition

Dissection

The dissection is carried down in the midline through the subcutaneous tissue and the cervicodorsal fascia and paraspinous muscles to the tips of the spinous processes.

The dissection is done through the midline to minimize bleeding.

Self-retaining retractors are used to maintain soft tissue tension during exposure.

The paraspinous muscles are elevated subperiosteally from the laminae, using a Cobb elevator or cautery.

During exposure, care is taken to protect the facet joint capsule of the levels cranial or caudal to the intended fusion, to avoid unintended adjacent level joint fusion or degeneration.

Access to the anterior column can be achieved through a posterolateral approach. The two options are the posterolateral costotransversectomy and far lateral extracavitary approaches (LECA).

Posterolateral Costotransversectomy Approach⁷

Dissection is performed subperiosteally along the posterior aspect of the ribs corresponding to the anterior vertebral level(s) to be exposed.

Exposing one rib above and below decreases the soft tissue tension and improves exposure.

The posterior 5 cm of the rib are exposed subperiosteally and circumferentially taking care to avoid injury to the underlying pleura and the neurovascular bundle. The neurovascular bundle lies against the anterior inferior aspect of the rib.

A bone cutter is used to cut the rib approximately 5 cm from the costovertebral joint.

The free rib section is gradually released from its surrounding soft tissue tethers including the various costovertebral joint capsule and ligaments.

Table 2 Various approach to cervicothoracic region enumerating advantages and disadvantages of each approach

Approach	Advantages	Disadvantages
Supraclavicular	<ul style="list-style-type: none"> Relatively bloodless plane 	<ul style="list-style-type: none"> Limited access below D1
Transsternal	<ul style="list-style-type: none"> Provides access from C4 to D3 Spares the sternoclavicular joint Preserves the sternal incision of sternocleidomastoid 	<ul style="list-style-type: none"> Sternal nonunion Mediastinitis Brachial plexus injury
Transmanubrial transclavicular	<ul style="list-style-type: none"> Provides access from C5 to D3 Decreased morbidity over sternotomy approach 	<ul style="list-style-type: none"> Pleural, mediastinal, vascular injury
Trapdoor	<ul style="list-style-type: none"> Provides access from C4 to D3 Spares the sternoclavicular joint Preserves the sternal insertion of sternocleidomastoid 	<ul style="list-style-type: none"> Pleural, mediastinal, vascular injury
Costotransversectomy	<ul style="list-style-type: none"> Lower morbidity as compared with transsternal or transmanubrial approaches Provides access to the posterior and lateral part of vertebral body 	<ul style="list-style-type: none"> Limited access to anterior part of the vertebral body
Lateral extracavitary (lateral parascapular)	<ul style="list-style-type: none"> Adequate access to posterior and anterior parts of vertebral body Extensile approach can be used for whole spine if needed Allows for anterior and posterior instrumentation 	<ul style="list-style-type: none"> Associated with increased postoperative morbidity Risk of pleura; pulmonary, neural, vascular injuries. Restriction of scapular movements, intercostal muscles paralysis Prolonged surgical exposure
Laminectomy	<ul style="list-style-type: none"> Least morbid of all procedures Can be used for whole spine 	<ul style="list-style-type: none"> Provides limited exposure only Risk of postoperative deformities
Thoracotomy/Trans-thoracic approach	<ul style="list-style-type: none"> Provides excellent access to C7 and thoracic spine Allows anterior instrumentation 	<ul style="list-style-type: none"> Associated with increased postoperative morbidity Risk of pleura; pulmonary, neural, vascular injuries. Restriction of scapular movements, intercostal muscles paralysis Prolonged surgical exposure

The lateral vertebral body and annulus are exposed subperiosteally.

A malleable spatula is used to retract soft tissues anterior and lateral to the anterior column of the spine.

Lateral Extracavitary Approach⁸

The main difference in the lateral extracavitary approach is the use of a plane of dissection lateral to the paraspinal muscles. This more lateral plane allows a more transverse angle of approach to the spinal canal and the anterior spinal column. Approximately 8 to 10 cm of posterior rib is resected. After the paraspinal muscle mass is elevated from the midline, it is released along its lateral border and the entire muscle mass may be then mobilized medially or laterally as needed with a Penrose drain.

Closure

Drains are usually inserted via a separate stab incision.

The muscles are approximated over a deep suction drain using interrupted sutures taking care to obliterate all dead space.

The subcutaneous layers and skin are sutured.

A postoperative upright chest radiograph to evaluate for possible pneumothorax is mandatory.

Anterior and posterior approaches to the CTJ are complicated procedures because of the inherent anatomic restraints and the biomechanics particular to this region. The posterior approach is commonly used in CTJ injuries⁹ and combined anterior and posterior approach may be used in selected cases depending on the pathology. Teng et al¹⁰ suggested utilization of preoperative MRI in deciding the anterior approach for CTJ.

The low anterior cervical approach or the Smith–Robinson approach addresses the pathology ventral to the cervical spinal cord. However, the low cervical approach is limited in exposure of the caudal and upper thoracic spine, especially the T2 vertebra, and depends on the body habitus and the anatomy of sternum and manubrium. The superiority of right-sided versus left-sided approach has been debatable in the literature. However, most surgeons do favor right-sided approach because of the more variable course of left recurrent laryngeal nerve and left thoracic duct.¹¹

The ventral fractures located distally as low as T4, can be accessed by extending the low anterior approach by

performing a partial median sternotomy.⁴ The additional exposure is gained by achieving sternotomy till the second intercostal space. A transsternal or transmanubrial approach is usually needed for access to the T3–T4 level. Typically, the superior portions of the great vessels overlie T3–T4; however, in the kyphotic patient, this can extend as high as T2.

When access below T4 is required, a thoracotomy may be necessary. However, it is limited in the exposure of the cervical, and thoracotomy cannot be used to access the lower cervical spine. To have exposure of lower cervical spine along with thoracotomy, a hemi-clamshell or trapdoor approach can be used, consisting of a partial median sternotomy, anterior thoracotomy, and a neck incision. The “carotid” incision is extended to the sternum and swung around horizontally at the fourth intercostal space to the anterior axillary line. Access from C3 potentially down to T4–T5 can be achieved in this manner. The primary advantage of this approach is that it can be used for an anterolateral pathology and provides an excellent visualization of spinal cord anteriorly, but is limited in its ability to assess to the posterior chest wall and neural foramina.

A transthoracic approach provides access to the CTJ through an inferior trajectory and used to gain access to the middle and lower thoracic spine. The thoracotomy is performed at the level of third rib and requires the mobilization and retraction of the scapula

There are numerous posterior approaches to the CTJ injuries. A laminectomy is performed if the pathology lies posterior to the spinal cord and involves the posterior elements. The costotransversectomy is a posterolateral approach exposing the posterior and anterolateral aspects of thoracic vertebra. The LECA affords superior exposure of the ventral thoracic cord through a posterolateral approach. A paramedian or midline incision is made and the erector spinae muscles reflected medially. The resection of proximal 10 cm of the rib reveals the entire vertebral segment from the ventral aspect to the posterior elements of the vertebral body.

The transpedicular approach can be performed for ventral and lateral decompression and requires facet resection and removal of the pedicle. However, this procedure may be risky in CTJ due to thin pedicles and proximity of neural elements in close proximity to the pedicle.

The pedicle screw insertion is routinely used for C7 level¹² and in the upper thoracic region (T1–T3) for CTJ injuries. For C7 pedicle screws, four techniques can be used:

- (1) The original technique described by Abumi and Kaneda.¹³
- (2) Pedicle axis view by fluoroscopy.
- (3) The laminoforaminotomy technique.
- (4) Computer-assisted navigation techniques.

Implantation of pedicle screws in the upper thoracic spine, specifically in vertebra T1, T2, and T3, needs precise knowledge of the posterior projection of the pedicles and of their orientation in space.¹⁴ In a cadaveric study carried by Ebraheim et al,¹⁵ for T1–T2, the projection point of the pedicle axis was approximately 7 to 8 mm medial to the lateral edge of the superior facet and 3 to 4 mm superior to the midline of the transverse process. For T3–T12, this point was 4 to 5 mm medial to the lateral margin of the facet and 5 to 8 mm superior to the midline of the transverse process. The transverse angle of the pedicle axis was found to be 30 to 40 degrees at T1–T2, 20 to 25 degrees at T3–T11, and 10 degrees at T12.

Kretzer et al¹⁶ reported the first use of translaminar screws in the upper thoracic spine. Biomechanical studies have demonstrated equal efficacy between translaminar and upper thoracic pedicle screws (→ Fig. 1).

Conclusion

CTJ traumas are rare and frequently missed. CTJ has a unique biomechanics as there is a transition from a mobile, lordotic cervical spine to a relatively more rigid and kyphotic thoracic spine. CT scan and MRI are required to identify and define

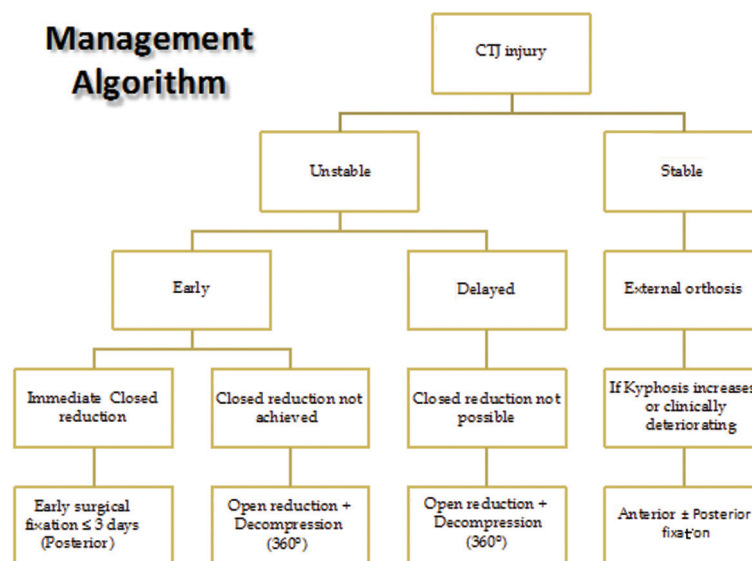


Fig. 1 Management algorithm.

the pattern of injury along with preoperative planning. Combined anterior and posterior approaches and posterior approach alone are commonly employed for such injuries with the ultimate goal of neural decompression, stabilization, restoration of anatomic spinal alignment, and early mobilization and rehabilitation.

Conflict of Interest

None.

References

- 1 Nichols CG, Young DH, Schiller WR. Evaluation of cervicothoracic junction injury. *Ann Emerg Med* 1987;16(6):640–642
- 2 Bayoumi AB, Efe IE, Berk S, Kasper EM, Toktas ZO, Konya D. Posterior rigid instrumentation of C7: surgical considerations and biomechanics at the cervicothoracic junction. A review of the literature. *World Neurosurg* 2018;111:216–226
- 3 Vaccaro AR, Koerner JD, Radcliff KE, et al. AO spine subaxial cervical spine injury classification system. *Eur Spine J* 2016;25(7):2173–2184
- 4 Cauchoix J, Binet JP. Anterior surgical approaches to the spine. *Ann R Coll Surg Engl* 1957;21(4):234–243
- 5 Gieger M, Roth PA, Wu JK. The anterior cervical approach to the cervicothoracic junction. *Neurosurgery* 1995;37(4):704–709
- 6 Christison-Lagay ER, Darcy DG, Stanelle EJ, Dasilva S, Avila E, La Quaglia MP. “Trap-door” and “clamshell” surgical approaches for the management of pediatric tumors of the cervicothoracic junction and mediastinum. *J Pediatr Surg* 2014;49(1):172–176, discussion 176–177
- 7 Lubelski D, Abdullah KG, Steinmetz MP, et al. Lateral extracavitary, costotransversectomy, and transthoracic thoracotomy

approaches to the thoracic spine: review of techniques and complications. *J Spinal Disord Tech* 2013;26(4):222–232

- 8 Holland CM, Bass DI, Gary MF, Howard BM, Refai D. Thoracic lateral extracavitary corpectomy for anterior column reconstruction with expandable and static titanium cages: clinical outcomes and surgical considerations in a consecutive case series. *Clin Neurol Neurosurg* 2015;129:37–43
- 9 Lee GYF, Massicotte EM, Rampersaud YR. Clinical accuracy of cervicothoracic pedicle screw placement: a comparison of the “open” lamino-foraminotomy and computer-assisted techniques. *J Spinal Disord Tech* 2007;20(1):25–32
- 10 Teng H, Hsiang J, Wu C, et al. Surgery in the cervicothoracic junction with an anterior low suprasternal approach alone or combined with manubriotomy and sternotomy: an approach selection method based on the cervicothoracic angle. *J Neurosurg Spine* 2009;10(6):531–542
- 11 Kilburg C, Sullivan HG, Mathiason MA. Effect of approach side during anterior cervical discectomy and fusion on the incidence of recurrent laryngeal nerve injury. *J Neurosurg Spine* 2006;4(4):273–277
- 12 Joaquim AF, Mudo ML, Tan LA, Riew KD. Posterior subaxial cervical spine screw fixation: A review of techniques. *Global Spine J* 2018;8(7):751–760
- 13 Abumi K, Kaneda K. Pedicle screw fixation for nontraumatic lesions of the cervical spine. *Spine* 1997;22(16):1853–1863
- 14 Kim YJ, Lenke LG, Bridwell KH, Cho YS, Riew KD. Free hand pedicle screw placement in the thoracic spine: is it safe? *Spine* 2004;29(3):333–342, discussion 342
- 15 Ebraheim NA, Xu R, Ahmad M, Yeasting RA. Projection of the thoracic pedicle and its morphometric analysis. *Spine* 1997;22(3):233–238
- 16 Kretzer RM, Sciubba DM, Bagley CA, Wolinsky J-P, Gokaslan ZL, Garonzik IM. Translaminar screw fixation in the upper thoracic spine. *J Neurosurg Spine* 2006;5(6):527–533