


Resection of Bone Tumor Guided by Gamma Probe and Evaluation of Postoperative Pain*

Ressecção de tumor ósseo guiada por Gamaprobe e avaliação do quadro algico pós-operatório

Alberto Ramos Gomes¹ Felipe Younes Quatrin² Nadiane Maciel Becker² Ruan Carlo Zanella²
Thércio Murilo Souza Rocha³

¹Onco-orthopedics, Fundação Hospitalar de Blumenau, Hospital Santo Antônio, Blumenau, SC, Brazil

²Orthopedics and Traumatology Department, Hospital Santo Antônio, Blumenau, SC, Brazil

³Nuclear Medicine, Clínica Cintilium – Medicina Nuclear, Blumenau, SC, Brazil

Address for correspondence Ruan Carlo Zanella, Rua Tobias Barreto, 263 - Apartamento 63 - Bairro Vila Nova, Blumenau, SC, 89035-070, Brasil (e-mail: ruan.zanella@gmail.com).

Rev Bras Ortop 2020;55(1):115–120.

Abstract

Keywords

- ▶ osteoma, osteoid/
diagnostic imaging
- ▶ osteoma, osteoid/
surgery
- ▶ bone neoplasms/
diagnostic imaging
- ▶ bone neoplasms/
surgery
- ▶ pain

Resumo

Palavras-chave

- ▶ osteoma osteóide/
diagnóstico por
imagem
- ▶ osteoma osteóide/
cirurgia
- ▶ neoplasias ósseas/
diagnóstico por
imagem
- ▶ neoplasias ósseas/
cirurgia
- ▶ dor

Osteoid osteoma is a benign neoplasm commonly found in young men, but that can be found in every age, which affects mainly long bones, clinically characterized by continuous and limiting pain that is relieved by salicylates. It is a small lesion composed of immature osteoid tissue, central hypervascularization and surrounding sclerotic area. Its diagnosis is performed by the clinic and aided by imaging tests, such as common radiography and computed tomography. Radiography shows a central radiolucent lesion and peripheral sclerosis. The biopsy takes place only in cases of diagnostic doubt. Surgical treatment involves resection of the niche, providing greater symptomatic relief, as well as percutaneous techniques. The technique of radioisotope-guided resection has good acceptance in the scientific community for its fast surgical procedure directed to the lesion; however, the percutaneous technique that stands out is radiofrequency ablation. In the present study, all of the patients submitted to the technique presented total improvement of the pain.

O osteoma osteóide é uma neoplasia benigna comum em homens jovens; porém, pode atingir qualquer idade, acomete preferencialmente ossos longos, e é caracterizada por dor contínua e limitante que é aliviada por salicilatos. É uma lesão de tamanho pequeno, composta por tecido osteóide imaturo, hipervascularização central e área esclerótica circundante. O diagnóstico é realizado pela clínica e auxiliado por exames de imagem, como radiografia comum e tomografia computadorizada. À radiografia, apresenta-se como uma lesão radiolúcida central e esclerose periférica. A biópsia está indicada somente nos casos de dúvida diagnóstica. O tratamento cirúrgico envolve a ressecção do nicho, proporcionando maior alívio sintomático, assim como as técnicas percutâneas. A técnica de ressecção guiada por radioisótopo tem boa aceitação na comunidade científica por tornar o procedimento cirúrgico mais rápido e dirigido para a lesão, ainda que o padrão ouro de tratamento seja a técnica percutânea de ablação por radiofrequência. É válido ressaltar que, no presente estudo, todos os pacientes submetidos à ressecção cirúrgica apresentaram regressão do quadro algico.

* Work performed at Hospital Santo Antonio, Blumenau, SC, Brazil.

Introduction

Osteoid osteoma is a benign neoplasm that mostly affects young men (up to 4:1). Although usually occurring between the 2nd and 3rd decade of life, it can affect patients at any age.¹ It is a self-limiting disease, with an average duration of 3 years.² Originally described by Jaffe³ in 1935 as a benign tumor with a predilection for the long bones of the lower limbs, osteoid osteoma is surrounded by a niche (also called nidus) and is characterized by immature osteoid tissue, central hypervascularization, an adjacent sclerotic area, and small size, ranging from 1 to 10 mm.^{4,5}

Clinically, it presents as perennial pain with greater intensity at night, sometimes relieved by salicylates and nonsteroidal anti-inflammatory drugs (NSAIDs).

Plain radiography (► **Figure 1**) and computed tomography (CT; considered the gold standard) (► **Figure 2**) are used as diagnostic adjuncts.^{1,6} Bone scintigraphy with 99-technetium flow (► **Figure 3**) has a 100% sensitivity in the diagnosis of osteoid osteoma; in addition, it is the test that detects the

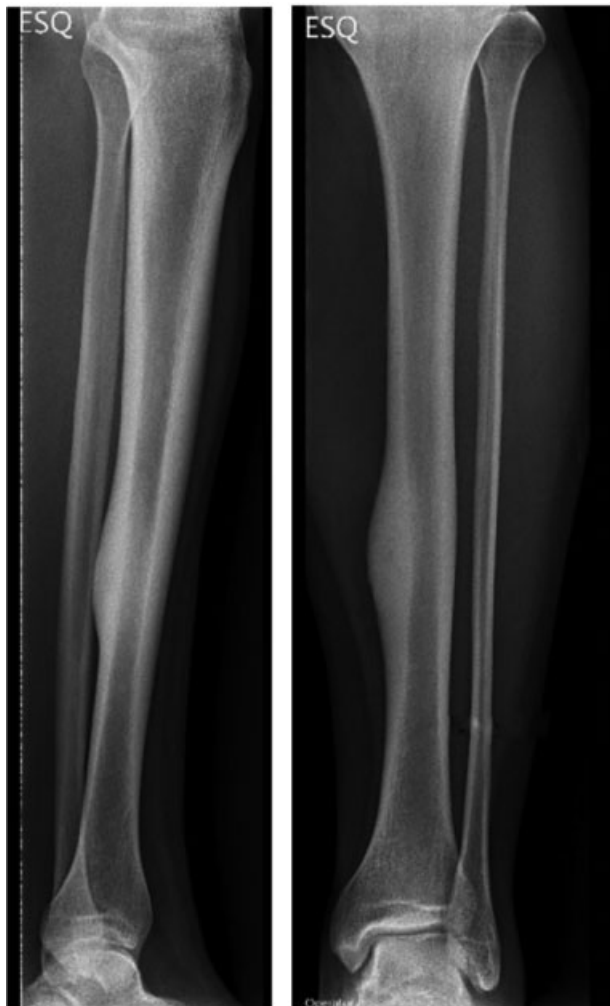

Fig. 1 Anteroposterior and lateral plain radiographs of the leg demonstrating a hyperdense area with local periosteal reaction, local sclerosis signs and a small hypodense area closer to the lateral cortical region of the tibial neck, which may correspond to an osteoid osteoma niche.

tumor with most precision, since the large increase in radiopharmaceutical uptake makes biopsy rarely necessary.

Being extremely sensitive, scintigraphy confirms the diagnosis and reduces the delay in its establishment, especially in early-stage lesions, since it shows changes before radiographies. The main differential diagnoses for osteoid osteoma are chondroblastoma, bone infarction and chronic osteomyelitis.

Macroscopically, the niche can be identified as a well-defined, violet-tinted lesion, usually surrounded by a sclerotic halo. Microscopically, it is composed of fibrovascular tissue with immature bone trabecula which are delimited by prominent halo-shaped osteoblasts.

Surgical treatment provides rapid symptomatic relief, with a high success rate ranging from 88 to 100%; in addition, it is associated with few relapses, and it allows both histological examination and surgical removal of the entire niche. Several techniques have been developed, including en bloc resection of osteoid osteoma and adjacent bone and niche curettage to remove part of the surrounding reactive bone. The main challenge, however, is the exact location of the niche.⁷⁻⁹ Gamma probe-guided surgical en bloc resection may solve this issue, reducing the size of the incision, increasing the likelihood of removing the entire niche and allowing diagnostic confirmation by pathological examination.⁶

The gamma probe-guided resection method is performed in two stages; the first stage is performed at a nuclear medicine center, in which the patient is submitted to a technetium bone scintigraphy with subsequent demarcation of the affected topography according to the images obtained. The second stage takes place in the operating room, using a gamma ray probe as a scanning tool.¹⁰

Nowadays, however, radiofrequency ablation is considered the most accepted method for percutaneous destruction of the niche, mainly because of its significant advantages over other techniques. Radiofrequency ablation is a fast, safe and effective technique, suitable for most patients, and it can be performed in most centers.^{11,12}

The present study aims to describe the gamma probe-guided bone tumor resection technique and to evaluate the postoperative pain improvement.

Materials and Methods

This is a prospective study conducted in 14 osteoid osteoma patients who underwent gamma probe-guided resection in an accredited hospital between May 2010 and May 2017. Medical records, pre- and postoperative pain analogue scale scores and patient satisfaction were analyzed. In total, 11 (78.47%) patients were male and 3 (21.43%) were female, with ages ranging from 3 to 41 years old (► **Table 1**).

Due to the character of the study, an Informed Consent Form and a data sheet with relevant aspects, such as date of surgery, topography, pre- and postoperative analogue pain scale and the technique used, were provided.

Patients submitted to another surgical technique were excluded from the present study.

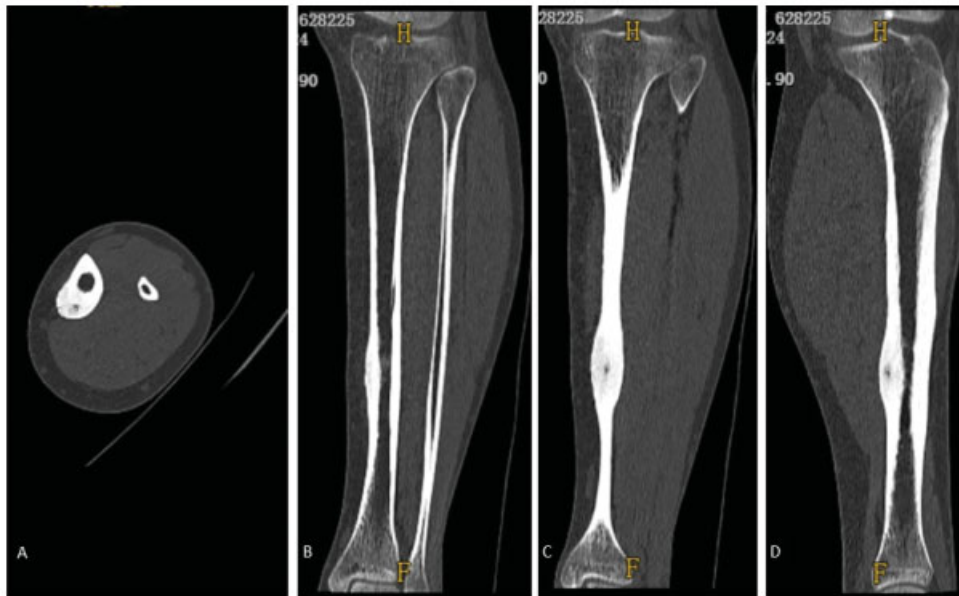


Fig. 2 Computed tomography scans of the leg, A = axial section, B = coronal section, C = coronal section in a more posterior plane, D = sagittal section, showing lateral tibial cortical thickening and a lower density area in the juxtaposed posterolateral cortical region, consistent with an osteoid osteoma niche.

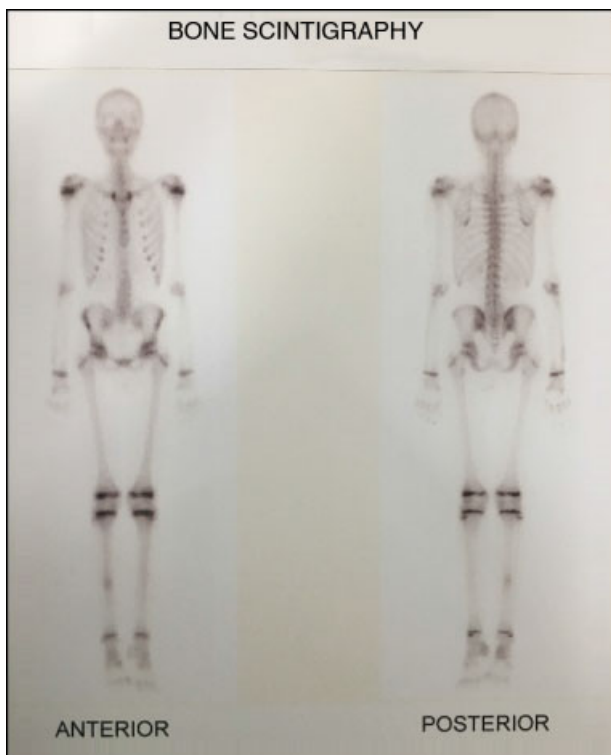


Fig. 3 Technetium-99 flow scintigraphy image, with increased uptake in the right tibial diaphyseal region.

Table 1 Patient distribution according to gender and respective percentual values

Gender	Male	Female
Total (n = 14)	n = 11	n = 3
Percentage (%)	78.47%	21.43%

Technique Description

The patients underwent surgery under general anesthesia or regional block in the operating room.

On the day of surgery, patients underwent the first stage of treatment at the nuclear medicine center, where a technetium-99 bone scintigraphy following an injection of 1,110 MBq of MDP-^{99m}Tc in adults; for children, this dose was corrected according to age and body weight. Images were obtained ~ 2 hours after the injection of the radioisotope. Aided by technetium-99 flow scintigraphy (→ **Figure 4**), the sites of highest uptake by the gamma ray probe were marked on the skin (→ **Figures 5A** and **5B**) to assist in the incision at the operating room. After demarcation, the patient was referred to the operating room, where the second stage of treatment was performed. Patients were anesthetized with the appropriate technique for each case and tumor resection began. The incision was based on preoperative examinations and markings resulting from reading the niche-emitted radiation. After surgical access and location of the supposed lesion site, the probe was positioned in a 90° angle to the bone surface to identify the niche, which was the point of highest radiation emission. After determining the point of greatest uptake, an en bloc resection was performed.

After collecting the material required for anatomopathological analysis, about 1 to 2 mm of the cavity was enlarged and submitted to a curettage, followed by cleaning with 0.9% saline solution (→ **Figure 5**). Next, the gamma probe was used in the resected area to confirm a decrease in uptake. Tissues were sutured in planes. Bone grafting was performed as required by the surgical site.

Postoperatively, after anesthetic recovery, the procedural success could be assessed by its correlation with pain relief.

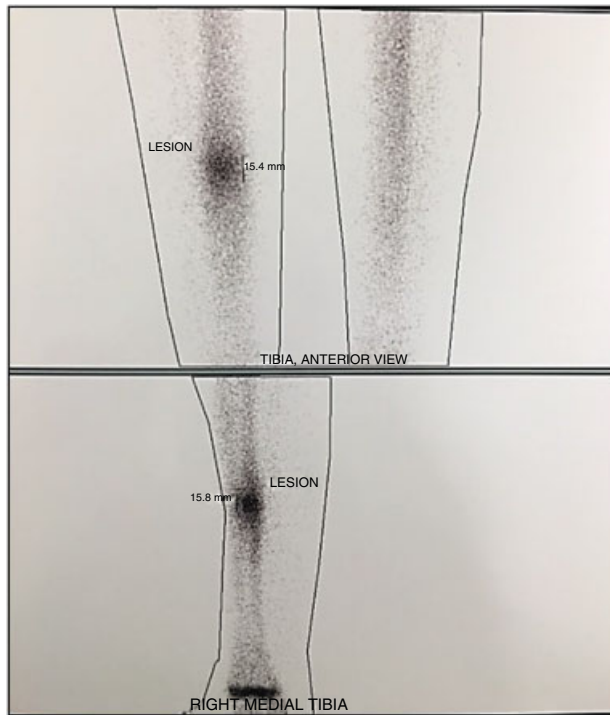


Fig. 4 Image focused on the tibial region in the anterior and medial to lateral position, showing increased uptake in the posterolateral region, which is the site of skin demarcation.

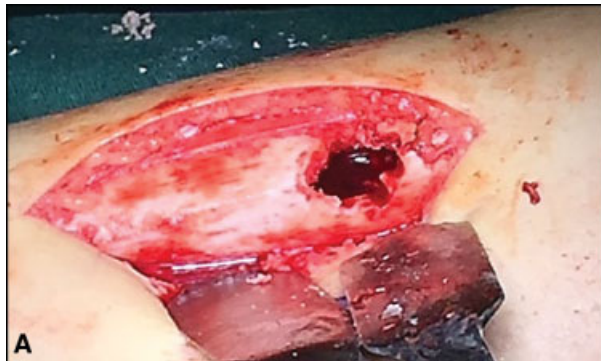

Fig. 5 (A) Skin incision at the site marked for en bloc resection guided by previous images and gamma probe uptake. After resection, the lesion was enlarged with curettage. (B) Intraoperative gamma probe equipment to identify lesions previously demarcated by nuclear medicine.

Table 2 Pain assessment in the evaluated patients and respective percentual values

	Total Relief	Partial Relief	No Change
Total (n = 14)	n = 14	0	0
Percentage (%)	100%	0%	0%

Table 3 Segmental distribution in affected patients and respective percentual values

	Lower Limb	Upper Limb
Total (n = 14)	n = 11	n = 3
Percentage (%)	78.47%	21.43%

Table 4 Distribution of affected bones and respective percentual values

Affected Segment	Total (n = 14)	Percentage (%)
Humerus	n = 1	7.14%
Tibia	n = 6	42.85%
Fibula	n = 1	7.14%
Femur	n = 4	28.57%
Scapula	n = 2	14.3%

A total relief in the pain reported prior to the surgery indicates that the niche resection was complete.

Results

In total, 11 (78.47%) patients were male and 3 (21.43%) were female. All 14 (100%) patients underwent a gamma probe-guided resection. All of the patients reported complete symptomatic relief (100%) (► **Table 2**). Eleven (78.47%) lesions were located in the lower limbs, and 3 (21.43%) were found in the upper limbs (► **Table 3**). The most affected bone was the tibia (n = 6; 42.85%), followed by the femur (n = 4; 28.57%); other bones were affected less frequently (► **Table 4**).

The most affected age group was the 3rd decade of life (n = 5; 35.7%), followed by the 2nd and 4th decades, which were similarly affected (n = 3; 21.4%), the 1st decade (n = 2; 14.3%) and, finally, the 5th decade of life (n = 1; 7.2%).

The prevalence of osteoid osteoma peaked at the 2nd decade of life, which ranges from 21 to 30 years old. Patients between 0 and 10 years old consisted ~ 15% of our casuistry; both the age groups ranging from 11 to 20 years old and from 31 to 40 years old comprised 20% of the sample, and the last age group, from 41 to 50 years-old, accounts for ~ 5% of the sample (► **Figure 6**)

Discussion

Osteoid osteoma is described in the literature as a frequent benign tumor lesion that affects mainly young men, being

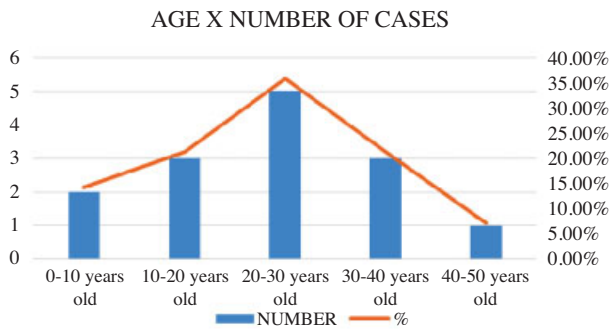


Fig. 6 Relation between age and number of cases in the analyzed patients and respective percentual values.

more common during the 2nd and 3rd decades of life; these data were confirmed by the present study.^{6,13} The lesion is clinically diagnosed, and its findings is corroborated by plain radiography and CT. Although the diagnosis is confirmed by a pathological examination, this procedure is not necessary, since the small niche size allows an excisional biopsy to be curative.

The ideal surgical technique is not a consensus in the literature due to the small sample sizes and studies limitations. Although Ehara et al¹⁴ and Campanacci et al¹² compared two surgical techniques for osteoid osteoma resection, they did not compare niche localization techniques, which is the impasse of surgical approach. This fact led the scientific community to look for new techniques to identify the niche and, consequently, to reduce morbidity and obtain more consistently satisfactory results.

The localization technique aided by CT was developed for this purpose, but it still presented some drawbacks. The fact that the patient underwent two invasive procedures, namely marking during needle tomography and a definitive surgical procedure, would be deemed negative points; however, they do not occur with marking during technetium-99 flow scintigraphy.^{6,14-16}

In recent years, percutaneous techniques have become the treatment of choice for osteoid osteoma, with success rates ranging from 80 to 100%,⁹ including percutaneous niche excision and niche destruction using injectable ethanol, cryoablation, laser or radiofrequency ablation.^{11,12,17} Since these techniques are minimally invasive, they are safely performed under local, regional or sedation anesthesia, allowing niche destruction with no significant adjacent bone excision; in addition, they can be performed in an outpatient facility or during short-term hospitalizations. Recovery is fast, and complications and relapses are rare, thus providing an alternative to conventional techniques.^{11,18,19}

Percutaneous techniques have limited application in recurrent osteoid osteomas, especially those located in the spine, near neurological structures, or in very small bones.^{5,17} In such cases, open resection techniques are the best choice. In addition, procedures using trephines, although percutaneous, are more aggressive and related to fractures because of the increased cortical fragility in the diaphysis of long bones.^{20,21}

Radioisotope-guided resection is a safe technique. It can be performed in any facility with a nuclear medicine center, and it reduces the number of procedures for the patient and the size of the incision (which was not evaluated in the present work, but may be assessed in the future). In addition, guidance to the incision site is more reliable, and intra-operative tumor niche location is more accurate. Although the diagnosis can be confirmed through a pathological examination, Sim et al²² state that negative results do not exclude the correct diagnosis, since the niche material is friable and it can often be poorly selected at the time of collection due to its small size.

Since the cause of severe pain is the presence of the niche, this technique is considered successful because the postoperative pain relief rate was 100%. Other confirmed literature parameters were the prevalence of long bones and involvement of the lower limbs.⁴

Conclusion

Radioisotope-guided resection is a safe and definite technique, although it is not the current gold standard. It is considered an appropriate option for osteoid osteoma treatment with 100% immediate postoperative pain relief.

Although there are disadvantages of surgical resection in relation to minimally invasive techniques, such as a larger surgical incision and the need for a close relationship with nuclear medicine, especially regarding scintigraphy, it is essential to emphasize that advantages, such as cost reduction, scintigraphic accuracy and specimen collection for anatomopathological analysis, make this technique an excellent choice. In addition to the characteristics mentioned above, it is believed that technical precision allows for a shorter surgical time, which may be assessed in further studies.

Conflict of Interests

The authors have no conflict of interests to declare.

References

- Canale ST, Beaty JH. Campbell cirurgia ortopédica. 12ed. Rio de Janeiro: Elsevier; 2017
- Jesus-Garcia R. Diagnóstico e tratamento de tumores ósseos. Rio de Janeiro: Elsevier; 2013
- Jaffe HL. Osteoid osteoma. A benign osteoblastic tumor composed of osteoid and atypical bone. Arch Surg 1935;31(05):709-728
- Sousa M, Freitas D, Cardoso P. Osteoma Osteóide? Rev Port Ortop Traumatol 2014;22(01):135-141
- Lee EH, Shafi M, Hui JH. Osteoid osteoma: a current review. J Pediatr Orthop 2006;26(05):695-700
- Endo RR, Gama NF, Nakagawa SA, Tyng CJ, Chung WT, Pinto FFE. Osteoid osteoma - radiofrequency ablation treatment guided by computed tomography: a case series. Rev Bras Ortop 2017;52(03):337-343
- Rankine JJ. The diagnosis and percutaneous treatment of osteoid osteomas. Curr Orthop 2007;21(06):464-470
- Papathanassiou ZG, Megas P, Petsas T, Papachristou DJ, Nilas J, Siablis D. Osteoid osteoma: diagnosis and treatment. Orthopedics 2008;31(11):1118
- Nielsen GP, Rosenberg AE. Bone-forming tumors. In: Folpe AL, Inwards CY. Bone and Soft Tissue Pathology: a volume in the

- series foundations in diagnostic pathology. Philadelphia: Churchill Livingstone; 2010:309–328
- 10 Etchebehere M, Etchebehere EC, Reganin LA, Amstalden EM, Cliquet A Jr, Camargo EE. Intraoperative localization of an osteoid-osteoma using a gamma probe. *Int Orthop* 2004;28(06):379–383
 - 11 Vigorita VJ. *Orthopaedic pathology*. 2nd ed. Philadelphia: Lippincott Williams & Wilkins; 2008:339–348
 - 12 Campanacci M, Ruggieri P, Gasbarrini A, Ferraro A, Campanacci L. Osteoid osteoma. Direct visual identification and intralesional excision of the nidus with minimal removal of bone. *J Bone Joint Surg Br* 1999;81(05):814–820
 - 13 David A, Rios AR, Tarragô RP, Oliveira GK, Garzela MM, Oliveira RK. Excisão de osteoma osteóide por trefina orientada pela tomografia computadorizada. *Rev Bras Ortop* 1997;32(05):396–400
 - 14 Ehara S, Rosenthal DI, Aoki J, Fukuda K, Sugimoto H, Mizutani H, et al. Peritumoral edema in osteoid osteoma on magnetic resonance imaging. *Skeletal Radiol* 1999;28(05):265–270
 - 15 Gangi A, Dietemann JL, Gasser B, Mortazavi R, Brunner P, Mourou MY, et al. Interstitial laser photocoagulation of osteoid osteomas with use of CT guidance. *Radiology* 1997;203(03):843–848
 - 16 Lindner NJ, Ozaki T, Roedl R, Gosheger G, Winkelmann W, Wörtler K. Percutaneous radiofrequency ablation in osteoid osteoma. *J Bone Joint Surg Br* 2001;83(03):391–396
 - 17 Sluga M, Windhager R, Pfeiffer M, Dominkus M, Kotz R. Peripheral osteoid osteoma. Is there still a place for traditional surgery? *J Bone Joint Surg Br* 2002;84(02):249–251
 - 18 Yang WT, Chen WM, Wang NH, Chen TH. Surgical treatment for osteoid osteoma – experience in both conventional open excision and CT-guided mini-incision surgery. *J Chin Med Assoc* 2007;70(12):545–550
 - 19 Moser T, Buy X, Goyault G, Tok C, Irani F, Gangi A. Image-guided ablation of bone tumors: review of current techniques. *J Radiol* 2008;89(04):461–471
 - 20 Yildiz Y, Bayrakci K, Altay M, Saglik Y. Osteoid osteoma: the results of surgical treatment. *Int Orthop* 2001;25(02):119–122
 - 21 Parlier-Cuau C, Champsaur P, Nizard R, Hamze B, Laredo JD. Percutaneous removal of osteoid osteoma. *Radiol Clin North Am* 1998;36(03):559–566
 - 22 Sim FH, Dahlin CD, Beabout JW. Osteoid-osteoma: diagnostic problems. *J Bone Joint Surg Am* 1975;57(02):154–159