


# Radiographic Analysis of Intra-articular Fractures of the Calcaneus in patients undergoing Minimally Invasive Surgical Treatment in a Tertiary Hospital\*

## *Análise radiográfica de fraturas intra-articulares de calcâneo em pacientes submetidos a tratamento cirúrgico minimamente invasivo em hospital terciário*

Glauter Carlos Félix<sup>1</sup> Marcelo Silveira Matias<sup>1</sup> Réjelos Charles Aguiar Lira<sup>1</sup>  Nelson Silveira Matias<sup>1</sup> Clodoaldo José Duarte de Sousa<sup>1</sup> Luiz Holanda Pinto Neto<sup>1</sup>

<sup>1</sup> Orthopedics and Traumatology Service, Instituto Doutor José Frota, Fortaleza, CE, Brazil

Address for correspondence Réjelos Charles Aguiar Lira, MD, Instituto Dr José Frota, Rua Barão do Rio Branco, 1816, Centro, Fortaleza, CE, 60025-061, Brasil (e-mail: rejeloscharles@hotmail.com).

Rev Bras Ortop 2020;55(2):226–231.

### Abstract

**Objective** This paper aims to evaluate patients with articular calcaneal fractures treated with a minimally invasive surgical technique between January 2015 and August 2016, with emphasis on radiographic results.

**Methods** Retrospective study of 49 patients with 64 displaced calcaneal fractures treated with open reduction by minimal lateral access to the subtalar joint and minimal fixation. Pre- and postoperative radiographic studies were performed to measure the angles of Böhler and Gissane.

**Results** The average angle of Böhler before surgery was 2.5°, increasing to an average value of 25.3° after the minimally invasive surgical treatment. The average angle of Gissane before surgery was 136.3°, decreasing to an average value of 114.3° after the procedure.

**Conclusion** The minimally invasive surgical technique improves the radiographic parameters of intra-articular calcaneal fractures, with appropriate anatomical restoration of anatomical shape.

### Keywords

- ▶ calcaneus
- ▶ minor surgical procedures
- ▶ radiography

### Resumo

**Objetivo** Avaliar pacientes com fraturas intra-articulares de calcâneo tratados entre janeiro de 2015 e agosto de 2016 com técnica cirúrgica minimamente invasiva, com ênfase no resultado radiológico.

**Métodos** Estudo retrospectivo de 49 pacientes com 64 fraturas intra-articulares de calcâneo, submetidos a tratamento cirúrgico minimamente invasivo. As lesões foram tratadas com redução aberta por acesso mínimo lateral à articulação subtalar e fixação

\* Study performed at the Orthopedics and Traumatology Service, Instituto Doutor José Frota, Fortaleza, Ceará, Brazil.

**Palavras-chave**

- ▶ calcâneo
- ▶ procedimentos cirúrgicos menores
- ▶ radiografia

mínima. Foi realizado estudo radiográfico no pré- e no pós-operatório para aferição dos ângulos de Böhler e de Gissane.

**Resultados** O ângulo de Böhler médio dos casos antes da cirurgia foi de 2,5°, apresentando aumento da média dos ângulos para 25,3° após o tratamento cirúrgico minimamente invasivo. O ângulo de Gissane médio dos casos antes da cirurgia foi de 136,3°, apresentando diminuição da média dos ângulos para 114,3° na análise após a cirurgia.

**Conclusão** A técnica cirúrgica minimamente invasiva permite melhora dos parâmetros radiográficos (ângulos de Böhler e Gissane) nas fraturas intra-articulares de calcâneo, com sua adequada recuperação da forma anatômica.

**Introduction**

Calcaneal fractures are the most common tarsal bones injuries,<sup>1,2</sup> representing 2% of all fractures. They are displaced and intra-articular in 60 to 75% of the cases, in which surgical correction is indicated.<sup>3-5</sup>

Calcaneal fractures often result in disability and prolonged absence from work activities; in addition, they are more prevalent in the economically active population.<sup>3,4,6,7</sup>

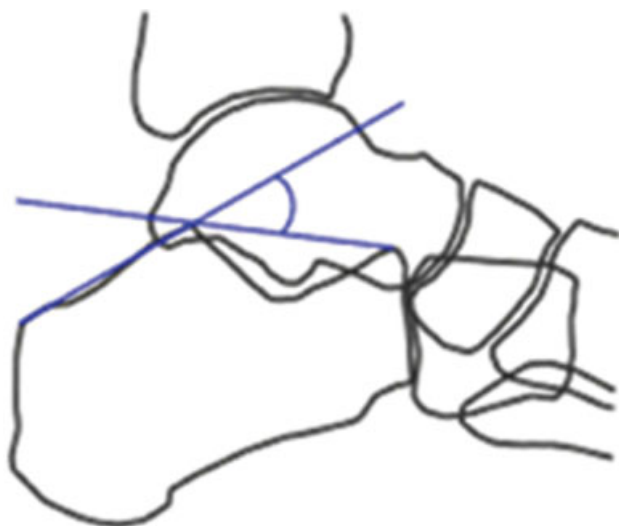
Despite the introduction of modern surgical techniques, unsatisfactory results are common.<sup>8,9</sup> Over the past 20 years, many authors have preferred the extended lateral access route and internal fixation with plate and screws.<sup>10,11</sup> In such cases, up to 43.5% of the patients evolved with soft tissue complications, requiring secondary procedures for synthesis material removal.<sup>12</sup> Other authors have published results from less invasive methods, with economical access routes and minimal fixation using wires and screws, and reported lower complication rates.<sup>8</sup>

The angles of Böhler and Gissane indicate changes in the joint facet and qualify fracture resolution<sup>3,5</sup> (► **Figures 1 and 2**).

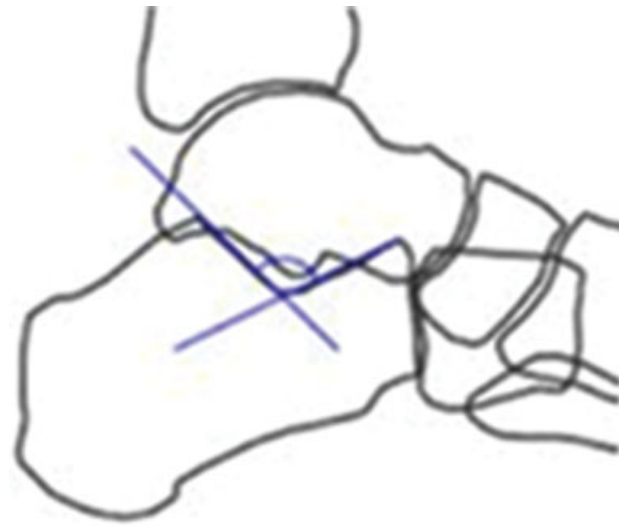
This study aims to evaluate the radiographic profile of intra-articular calcaneal fractures by assessing radiographically the angles of Böhler and Gissane, before and after surgical treatment with a minimally invasive technique.

**Materials and Methods**

This is a descriptive, retrospective study including patients with intra-articular calcaneal fractures treated at a referral trauma hospital in the state of Ceará, Brazil, from January 2015 to August 2016. During this period, 146 patients with calcaneal fracture were seen. Patients under 18 years-old, undergoing conservative treatment, or conventional therapy ('L' lateral access route and internal fixation with plate and screws), with incomplete medical records, lost to follow-up, or who died during follow-up were excluded from the study. Thus, 49 patients undergoing minimally invasive surgical treatment were selected for this series; since 15 subjects had bilateral calcaneal fractures, a total of 64 injuries were analyzed (N = 64).



**Fig. 1** Schematic representation of Böhler angle.



**Fig. 2** Schematic representation of Gissane angle.

Data were collected from medical records using a structured script including age, gender, and trauma mechanism. In addition, the angles of Böhler and Gissane were measured in pre- and postoperative radiographs with a standardized goniometer. Normal values were defined as 20 to 40° and 100 to 120° for the Böhler and Gissane angles, respectively.

### Surgical Technique

The surgical procedure is performed with the patient under spinal anesthesia and positioned in lateral decubitus. Asepsis and antisepsis are performed, followed by sterile fields placement. Next, a minimal lateral surgical access to the subtalar joint, guided by a line between the inferior aspect of the lateral malleolus and the fourth toe, is made. Dissecting through anatomical planes, the subtalar joint is approached for open reduction of the fracture using levers or bone hooks. Then, an internal fixation with 3.5 mm/4.5 mm cannulated screws or percutaneous Kirschner wires is performed under radiology with image intensifier.

### Data Analysis

Data were compiled and analyzed using the Statistical Package for Social Science (SPSS) version 21.0 software (IBM Corp., Armonk, NY, USA). Mean, median, and standard deviation values were calculated for continuous variables, and percentages were determined for categorical variables. A t-test for paired samples compared the angles of Böhler and Gissane. A confidence interval of 95% and a  $p$ -value  $< 0.05$  were considered statistically significant.

### Ethical Issues

The study was duly authorized by the research Ethics committee under protocol No. 1.710.233 from September 2, 2016.

### Results

In total, 49 patients with intra-articular calcaneal fractures were analyzed. Since there were 15 cases of bilateral fractures (30.61%), a total of 64 fractures were analyzed. Six of these (9.37%) were open fractures. There was a predominance of male patients (89.79%), with a 9:1 ratio to females (►Figure 3). The mean age of the patients was 39 years (ranging from 18–70 years-old). Thirty-six (71.42%) patients reported falls as trauma mechanisms, with an average fall height of approximately 4.5 meters. In addition, 10 (20.4%) patients reported traffic accidents and 3 (6.12%) reported firearm injuries as trauma mechanisms (►Figure 4). Sixteen (32.65%) of the 49 patients reported work-related accidents. The right foot was affected in 48% cases and the left foot was injured in 52% subjects.

All fractures were analyzed through lateral calcaneal radiographs for evaluating the angle of Böhler (whose normal reference value ranges from 20–40°) and the angle of Gissane (whose normal reference value ranges from 100–120°) measurements. The mean angle of Böhler before surgery was 2.5° (median, 0°), increasing to an average value of 25.3° (median, 24°) after minimally invasive surgical treatment ( $p < 0.001$ ). The mean angle of Gissane before

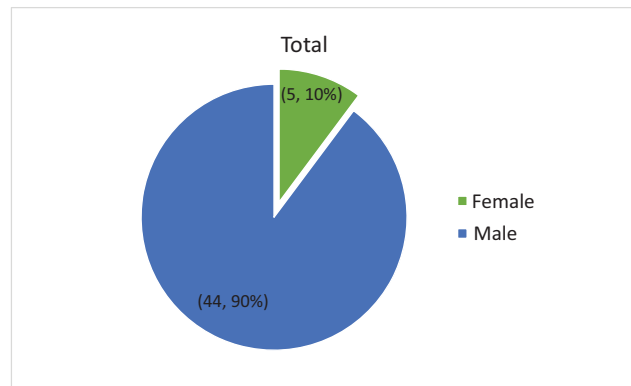


Fig. 3 Patients with calcaneal fractures according to gender. Fortaleza, CE, Brazil, 2017.

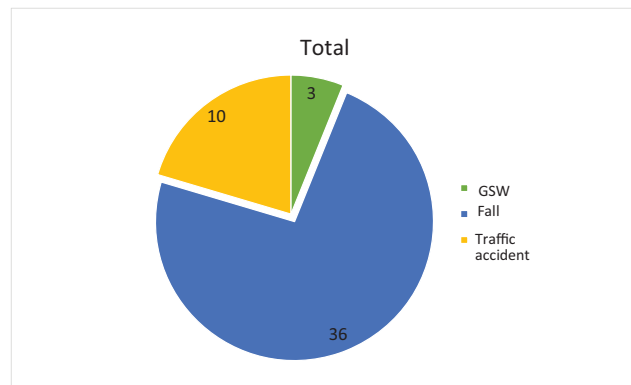


Fig. 4 Calcaneal fractures according to trauma mechanism. Fortaleza, CE, Brazil, 2017. GSW, gunshot wound.

surgery was 136.3° (median, 140°), decreasing to an average value of 114.3° (median, 116°) in the postoperative period ( $p < 0.001$ ) (►Tables 1 and 2).

### Discussion

Calcaneal joint fractures have significant morbidity, constituting severe injuries that often cause disabling and permanent sequelae. They usually affect young males in an economically active age group and may cause great socioeconomic impairment. In the studied sample, 89.79% of the patients were male, with a mean age of 39 years-old, reinforcing the statement that these injuries affect individuals in full exercise of their socioeconomic functions. In the literature, the most frequent causal agent reported was falls, which is consistent with our sample (71.42%).<sup>13</sup>

Although this is a widely studied fracture, there is still no consensus on its classification, treatment, and ideal surgical technique.<sup>14</sup> The literature is scarce on high-level evidence studies on surgical techniques for calcaneal fractures. Many studies report several surgical techniques, but few compare them. In terms of functionality, according to the American Orthopedic Foot and Ankle Society (AOFAS) questionnaire, a minimally invasive percutaneous fixation technique using Kirschner wires has superior results and fewer complications when compared with more invasive techniques.<sup>15</sup>

**Table 1** Patients characterization regarding personal data, injury features and Böhler and Gissane angles before and after a minimally invasive surgical treatment. Fortaleza, CE, Brazil, 2017

Patient	Foot	Age	Gender	Trauma mechanism	Height (m)	Work-related accident	Fracture	Preoperative Böhler angle (degrees)	Postoperative Böhler angle (degrees)	Preoperative Gissane angle (degrees)	Postoperative Gissane angle (degrees)
1	R	29	m	Traffic accident		No	Closed	-10	26	120	120
1*	L						Closed	2	28	118	116
2	L	35	m	Fall	6	No	Closed	22	24	146	140
2*	R						Closed	10	20	140	129
3	L	52	m	Fall	4	No	Closed	-10	5	116	114
4	R	35	m	Fall	2.5	No	Closed	-5	26	150	118
4*	L						Closed	8	22	142	126
5	R	16	m	Fall	5	No	Closed	10	46	146	116
5*	L						Closed	20	35	138	122
6	R	45	m	Fall	4	No	Closed	0	20	146	124
7	R	36	m	Fall	4	Yes	Closed	0	26	140	110
7*	L						Closed	5	20	145	112
8	R	40	m	Fall	3	Yes	Closed	0	18	144	100
9	L	26	m	Fall	16	Yes	Closed	0	22	152	124
10	R	55	m	Fall	3	Yes	Closed	0	20	140	112
11	L	65	m	Fall	4	No	Closed	-12	22	140	108
11*	R						Closed	4	30	138	118
12	L	31	m	Fall	5	Yes	Closed	0	24	150	114
13	L	47	m	Fall	7	Yes	Closed	2	28	142	124
13*	R						Closed	5	24	132	115
14	L	54	m	Fall	2	Yes	Closed	12	20	56	110
15	R	19	m	Fall	14	No	Closed	0	22	146	122
15*	L						Closed	10	29	132	115
16	R	30	m	Traffic accident		No	Open	0	24	148	110
17	R	40	m	Fall	3	Yes	Closed	10	28	128	106
18	R	35	m	Fall	3.5	Yes	Closed	12	38	140	135
18*	L					No	Closed	14	54	138	115
19	R	30	m	Traffic accident		No	Closed	0	24	100	110
20	R	52	m	Fall	2	No	Closed	16	24	138	104
21	R	58	m	Fall	15	Yes	Closed	8	26	136	124
21*	L						Closed	10	29	140	126
22	R	35	f	Traffic accident		No	Open	-6	20	128	114
23	R	45	m	Gunshot wound		No	Open	-12	2	120	118
24	L	44	m	Fall	3	No	Closed	-10	12	130	120
25	R	26	m	Fall	2	Yes	Closed	30	30	158	118
26	R	33	m	Fall	2	Yes	Closed	-10	30	140	124
27	L	37	m	Fall	3	Yes	Closed	-12	28	44	108
28	L	48	f	Gunshot wound		No	Open	6	20	128	114
29	L	35	m	Fall	2	Yes	Closed	-8	34	138	110
30	R	57	m	Fall	3	No	Closed	12	22	156	120
31	L	37	m	Fall	3	No	Closed	0	26	158	106
32	L	44	m	Fall	4	Yes	Closed	-2	26	138	112

(Continued)

**Table 1** (Continued)

Patient	Foot	Age	Gender	Trauma mechanism	Height (m)	Work-related accident	Fracture	Preoperative Böhler angle (degrees)	Postoperative Böhler angle (degrees)	Preoperative Gissane angle (degrees)	Postoperative Gissane angle (degrees)
32*	R						Closed	5	24	132	114
33	L	37	f	Traffic accident		No	Closed	0	22	148	122
34	R	13	m	Fall	3	No	Closed	-2	20	156	130
35	R	34	m	Fall	4	No	Closed	4	22	148	116
36	R	32	m	Traffic accident		No	Closed	6	24	142	128
36*	L						Closed	14	30	124	108
37	L	67	m	Fall	3	No	Closed	10	28	156	120
38	R	24	m	Fall	4	No	Closed	2	22	154	130
39	L	70	m	Traffic accident		No	Closed	12	22	130	118
40	R	52	m	Fall	4	No	Closed	0	20	112	108
40*	L						Closed	-22	12	152	118
41	R	59	f	Fall	3	No	Closed	-8	32	170	116
42	L	49	m	Fall	3	No	Closed	14	38	146	108
43	L	58	f	Fall	4	No	Closed	6	14	152	122
44	R	26	m	Fall	4	Yes	Closed	6	30	140	108
44*	L							0	26	148	112
45	R	16	m	Gunshot wound		No	Open	10	36	120	120
46	L		m	Traffic accident		No	Open	4	30	110	118
47	R	26	m	Traffic accident		No	Closed	-2	42	142	108
48	R	29	m	Traffic accident		No	Closed	0	20	138	102
49	R	29	m	Fall	4	No	Closed	0	24	140	102
49*	L						Closed	4	22	138	112

Abbreviations: R, right; L, left; m, male, f, female.

\*contralateral fracture at the same patient.

**Table 2** Comparison of the average values of the Böhler and Gissane angles before and after a minimally invasive surgical treatment. Fortaleza, CE, Brazil, 2017

	Preoperative (standard deviation)	Postoperative (standard deviation)	<i>p</i> -value*
Böhler angle, average value	2.5° (9.5)	25.3° (8.6)	< 0.001
Gissane angle, average value	136.3° (21.3)	114.3° (8.2)	< 0.001

\*t-test.

Here, we report surgical outcome of 49 patients (64 injuries) with calcaneal joint fractures treated through a minimally invasive surgical method under the premise of possible functional recovery with no treatment complications, which should be deemed unacceptable.

The comparison of pre- and postoperative radiographies revealed an improvement in the angle of Böhler, from 2.5 to 25.3° (which is within the normal range, i.e., from 20–40°)

and in the angle of Gissane, from 136.3 to 114.3° (which is also within the normal range, i.e., from 100–120°). The comparison between mean pre- and postoperative angles in this sample showed a high statistical significance, according to the t-test ( $p < 0.001$ ), suggesting a positive association between good results regarding the angles of Böhler and Gissane and the use of minimally invasive surgical technique.

Calcaneal anatomical parameters recovery may be similar between the minimally invasive technique and the conventional technique, as shown by Yeo et al,<sup>16</sup> who compared the postoperative radiographic results of the conventional technique with broad lateral approach (correction of the angles of Böhler and Gissane average values to 25.5° and 119.0°, respectively) with the minimally invasive technique by subtalar approach (correction of the angles of Böhler and Gissane to 26.5° and 115.5°, respectively). These authors also showed a lower rate of surgical wound complications when the minimally invasive technique was performed.

In a meta-analysis, Wang et al<sup>17</sup> demonstrated that the conventional technique presented more postoperative complications compared to the minimally invasive technique but

found no statistical difference when comparing the postoperative radiographic results of the angles of Böhler and Gissane.

Loucks e Buckley<sup>5</sup> conducted a prospective randomized study to assess the angle of Böhler and its correlation with fracture treatment outcomes. They observed that surgical treatment improved the values and functional conditions of the angle. These results from the radiographic evaluation reflect the adequate recovery of the calcaneal anatomical shape with the surgical technique employed. Angle restoration is directly related to the quality of fragment reduction.

The improvement of these angles does not guarantee that the functional result will be successful, and this study does not intend to perform a functional evaluation.

A limitation of this study is the lack of calcaneal fractures grouping per severity. Some patients did not have adequate images for fracture classification in their medical records. This can make it difficult to understand which groups of fractures are most amenable to minimally invasive surgical treatment with good radiographic results.

## Conclusion

In our sample, the minimally invasive surgical technique improved the angles of Böhler and Gissane in intra-articular calcaneal fractures, resulting in an adequate recovery of the anatomical shape.

### Conflict of Interests

The authors have no conflict of interests to declare.

## References

- 1 Fernandes TD, Santos ALG. Fraturas dos ossos do pé no adulto. In: Hebert S, Barros Filho TEP, Xavier R, Pardini Junior AG. Ortopedia e traumatologia princípios e práticas. 4ª ed. Porto Alegre: Artmed; 2009:1529–1530
- 2 Costa P, Cardoso H. Fratura do calcâneo. Rev Port Ortop Traumatol 2013;21(01):109–115
- 3 Sanders RW, Clare MP. Fractures of calcaneus. In: Court-Brown C, Heckman JD, McKee M, McQueen MM, Ricci W, editors. Rockwood and Green's fractures in adults. 8th ed. Philadelphia: Lippincott Raven Publishers; 2015:2639–2685
- 4 Contreras MK, Muniz AS, Souza JB, Avila AV. Biomechanical evaluation of intra articular calcaneal fracture and clinical radiographic correlation. Acta Ortop Bras 2004;12(02):104–111
- 5 Loucks C, Buckley R. Bohler's angle: correlation with outcome in displaced intra-articular calcaneal fractures. J Orthop Trauma 1999;13(08):554–558
- 6 Essex-Lopresti P. The mechanism, reduction technique, and results in fractures of the os calcis. Br J Surg 1952;39(157):395–419
- 7 Netzahualcóyotl Blass JPF, Gutiérrez MI, Makkozzay PTH. Resultado clínico-radiológico del tratamiento quirúrgico de las fracturas intra-articulares del calcáneo. Acta Ortop Mex 2004;18(01):21–24
- 8 Lopes AS, Pinto RZ, Gonçalves EL, Melo GL, Leal RT. Surgical treatment of displaced intra-articular fractures of the calcaneus using a less invasive approach. Rev Bras Ortop 2008;43(10):426–432
- 9 Lara LC, Franco NF, Montesi DN, Macedo CF, Chagas FF, Bicudo LR. Tratamento das fraturas articulares do calcâneo: avaliação dos resultados. Rev ABTPe 2009;3(01):22–28
- 10 Prado Júnior I, Rocha MA, Rezende RR. Tratamento cirúrgico das fraturas intraarticulares desviadas do calcâneo, através de osteossíntese interna, sem enxerto ósseo. Rev Bras Ortop 1999;34(07):421–429
- 11 Harvey EJ, Grujic L, Early JS, Benirschke SK, Sangeorzan BJ. Morbidity associated with ORIF of intra-articular calcaneus fractures using a lateral approach. Foot Ankle Int 2001;22(11):868–873
- 12 Paula SP, Biondo ML, Luzzi R. Evolução das fraturas intra-articulares desviadas do calcâneo com tratamento cirúrgico. Acta Ortop Bras 2006;14(01):35–39
- 13 Köberle G, Oliveira AC, Sandoval PS. Fraturas intra-articulares do calcâneo. Rev Bras Ortop 1996;31(06):477–480
- 14 Sanders R. Displaced intra-articular fractures of the calcaneus. J Bone Joint Surg Am 2000;82(02):225–250
- 15 Pelliccioni AA, Bittar CK, Zabeu JL. Tratamento cirúrgico de fraturas intraarticulares de calcâneo sanders II e III: revisão sistemática. Acta Ortop Bras 2012;20(01):39–42
- 16 Yeo JH, Cho HJ, Lee KB. Comparison of two surgical approaches for displaced intra-articular calcaneal fractures: sinus tarsi versus extensile lateral approach. BMC Musculoskelet Disord 2015;16:63
- 17 Wang XJ, Su YX, Li L, Zhang ZH, Wei XC, Wei L. Percutaneous poking reduction and fixation versus open reduction and fixation in the treatment of displaced calcaneal fractures for Chinese patients: A systematic review and meta-analysis. Chin J Traumatol 2016;19(06):362–367