


Does A Vertebra Fracture Cause A Tumor? A Dorsolumbar Paraspinal Desmoid Tumor: Case Report

Uma fratura de vértebra causa um tumor? Tumor desmoide paraespinal dorsolombar: Relato de caso

Zeki Serdar Ataizi¹ Gulay Simsek² Fulya Colak Ataizi³ Serdar Ercan¹ 

¹ Department of Neurosurgery, Yunus Emre State Hospital, Eskisehir, Turkey

² Department of Pathology, Yunus Emre State Hospital, Eskisehir, Turkey

³ Department of Radiation Oncology, Yunus Emre State Hospital, Eskisehir, Turkey

Address for correspondence Serdar Ercan, MD, Department of Neurosurgery, Yunus Emre State Hospital, Uluonder Mah. Salih Bozok Cd No:23, Tepebasi, Eskisehir, 26190, Turkey (e-mail: sdrercn@gmail.com).

Arq Bras Neurocir 2020;39(1):58–60.

Abstract

Extraabdominal desmoid tumors are uncommon soft-tissue tumors. The etiology of the tumor is still unclear. Injury is one of the etiological factors of soft-tissue tumors. A 41-year-old female patient who had a traumatic vertebral body fracture on the thoracic spine was treated conservatively. Two and a half years later, she presented a painful, palpable swelling on the thoracolumbar region. In the present report, we discuss the patient, who underwent a surgery to remove the desmoid tumor (aggressive fibromatosis), within the context of the current literature. The literature on desmoid tumor caused by a trauma is rare. This is the first case that demonstrates an extraabdominal desmoid tumor following a spinal fracture. The swelling on the region of the trauma must be examined carefully and desmoid tumor must be kept in mind as a possible diagnosis.

Keywords

- ▶ trauma
- ▶ vertebral fracture
- ▶ extra-abdominal desmoid tumor

Resumo

Tumores desmoides extra-abdominais são tumores incomuns de tecidos moles. A etiologia do tumor ainda não está clara. A lesão é um dos fatores etiológicos dos tumores de tecidos moles. Uma paciente do sexo feminino, com 41 anos de idade, com fratura traumática do corpo vertebral na coluna torácica, foi tratada de forma conservadora. Dois anos e meio depois, ela apresentou um inchaço doloroso e palpável na região toracolombar. No presente relato, o caso da paciente, que foi submetida à cirurgia para extração do tumor desmoide (fibromatose agressiva), foi discutido no contexto da literatura atual. A literatura sobre tumor desmoide causado por trauma é rara. Este é o primeiro caso que apresenta um tumor desmoide extraabdominal após fratura da coluna vertebral. O inchaço na região do trauma deve ser examinado cuidadosamente, e o tumor desmoide deve ser considerado como possível diagnóstico.

Palavras-chave

- ▶ trauma
- ▶ fratura vertebral
- ▶ tumor desmoide extra-abdominal

received
September 16, 2019
accepted
October 3, 2019

DOI <https://doi.org/10.1055/s-0039-3399538>.
ISSN 0103-5355.

Copyright © 2020 by Thieme Revinter Publicações Ltda, Rio de Janeiro, Brazil

License terms



Introduction

Desmoid tumors are slow-growing tumors of benign nature, which originate in the muscle, connective tissue, fascia, and aponeurosis and are rarely malignant but frequently invasive.¹ Desmoid tumors, which present a prevalence of 0.03% among all tumors, were first described by McFarlane in 1832.^{2,3} The etiology of a large number of soft-tissue tumors is still unknown today. Several cases of desmoid tumors developing in the same region of previous isolated trauma are present in the literature.⁴⁻⁶

Case Report

A 41-year-old female patient presented with a growing painful mass on the left side, extending from the medial to the lower back region. The patient had fallen 2.5 years prior to developing the painful mass, and subsequently had a stable compression fracture of the 11th thoracic (T11) vertebral body (►Fig. 1a). The fracture was treated conservatively. No skin injuries, including laceration, abrasion, or ecchymosis, were observed on the thoracic and lumbar spine regions. However, 6 months later, an initially small swelling in the neighborhood of the T11 vertebral body occurred, which grew over time. Physical examination revealed a gross mass lesion in the left dorsolumbar region, which could be clearly seen through the skin and was not mobile due to the adherence of surrounding tissue. With the exception of the mass, physical examination of the thorax and abdomen went well, and the results of the laboratory evaluation were within normal range. Magnetic resonance imaging of the

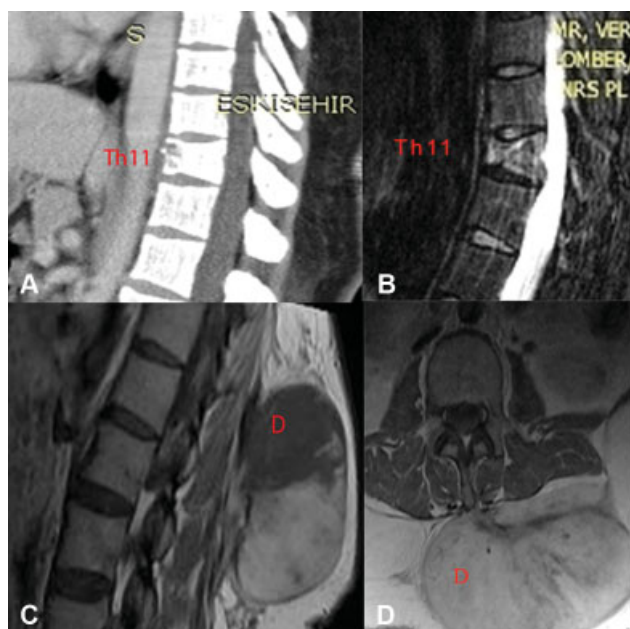


Fig. 1 (A) Computed tomography (CT) scan of spine after trauma. T11: compression fracture at the T11 level (B) Magnetic resonance imaging scan of T11 demonstrates the fracture-related edema. (C) Sagittal scan of vertebral body after 6 months. A desmoid tumor (10 × 6 × 7 cm) can be observed at T11 and L2 levels. (D) Axillary scan of vertebral body and desmoid tumor. Abbreviations: T: thoracic vertebra, D: desmoid tumor.

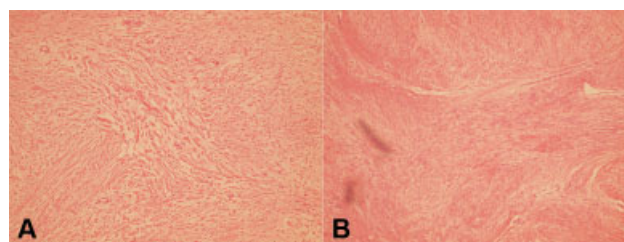


Fig. 2 (A) Layers of tumor cells with pale eosinophilic cytoplasm and spindle shaped. (B) The collagen in desmoid tumor may be keloidal.

patient revealed a 10 × 6 × 7 cm soft-tissue mass at the T11 and L2 levels, which was hypointense in T1 sequence, hyperintense in T2 sequence, and heterogeneous after administration of the contrast agent (►Fig. 1b). Destruction of the spinous process due to the tumor could not be detected. The patient underwent a surgical operation, and the mass was removed completely. Due to the extensive invasion and the insufficient cleavage, an extended surgical resection was performed. The histopathological evaluation of the mass revealed a desmoid tumor (►Fig. 2). The patient has been followed-up for 2 years with no recurrence.

Discussion

Desmoid tumors are benign and locally aggressive invasive tumors that originate in the muscle, connective tissue, fascia, and aponeurosis.⁴ The cause of desmoid tumors is still unknown. However, these tumors are associated with genetic abnormalities, such as familial adenomatous polyposis and Gardner syndrome as well as with sex hormones in the pregnancy and postpregnancy periods, and also with isolated and surgical traumas and invasive interventions. Approximately 25% of the patients have had a previous trauma. In addition to desmoid tumors, lipomas and lymphomas are also mentioned among the tumors that are associated with trauma. The incidence of desmoid tumors is 0.03% among all tumors.^{4,7-9} However, the percentages of patients with familial adenomatous polyposis and Gardner syndrome are 32% and 29%, respectively.¹⁰ Desmoid tumors are more common among females.¹¹ Reitamo et al reported that 80% of desmoid tumors are seen in women, and 50% of them occur in the 3rd and 5th decades of life.¹² The majority of the cases are reported more frequently between adolescence and 40 years of age.¹

Currently, there is no definitive and effective treatment for these tumors, which are usually treated by extensive surgical excision. The distant metastases are extremely rare,¹³ although local recurrence can happen, and conservative therapeutic management must be ensured. Asymptomatic patients are treated conservatively. Radiotherapy, cytostatic agents, hormonal drugs, non-steroidal antiinflammatory drugs and antiviral drugs are alternative methods that can be used in the treatment of desmoid tumors.^{2,14,15}

The association between the tumor and trauma is unclear. Ewing¹⁶ has listed a criteria of tumor formation and suggested that trauma is theoretically a possible factor in tumor development. In light of this criteria, the case described in the present study exhibits a similar perspective of cause-effect

relationship, localization and neighborhood, histological type of the tumor, and latent period between the events. The uncontrolled cell proliferation in the region of the trauma explains the formation of desmoid tumors better.⁴ In the case presently discussed, the radiological and physical examination was performed in the early period of the trauma and accepted normal, except for the T11 vertebral body fracture. The tumor supports the theory about tumor formation in the latent period of injury, occurring in the neighborhood of the injury zone. Previous studies have presented cases in which the trauma had occurred directly to the soft tissue. However, the trauma was indirect in our case. The valuable feature of our case is that it is the first reported case of a desmoid tumor formation developed after compression fracture of a vertebral body without any direct trauma to the skin.

In conclusion, in the presence of a rapid growth of the skin on the trauma region, desmoid tumors should be considered in the differential diagnosis of conservatively treated compression fracture. Despite the availability of a wide variety of treatment options, the best option for the treatment of desmoid tumors will be radical resection with surgery.

Ethical Publication Statement

The authors confirm that they have read the Journal's position on issues involved in ethical publication and affirm that this report is consistent with those guidelines.

Authors' contributions

Zeki Serdar Ataizi and Serdar Ercan performed the clinical examination and surgical treatment, and were major contributors in writing the manuscript. Gulay Simsek and Fulya Ataizi performed the histopathological examination of the tumor, and analyzed and interpreted the data of the patient.

Conflict of Interests

The authors have no conflict of interests to declare.

References

- 1 Sonmez E, Altinors N, Gulsen S, Ozen O. Extraabdominal desmoid tumor appearing following resection of thoracolumbar schwannoma. *Turk Neurosurg* 2011;21(02):246–248
- 2 Ferenc T, Sygut J, Koczyński J, et al. Aggressive fibromatosis (desmoid tumors): definition, occurrence, pathology, diagnostic problems, clinical behavior, genetic background. *Pol J Pathol* 2006;57(01):5–15
- 3 Güzey FK, Emel E, Bas NS, Ozkan N, Turgut H, Sel B. Aggressive postoperative lumbar fibromatosis after the placement of instrumentation for treatment of spondylolisthesis. Case report. *J Neurosurg Spine* 2006;4(04):338–341
- 4 Cohen S, Ad-El D, Benjaminov O, Gutman H. Post-traumatic soft tissue tumors: case report and review of the literature a propos a post-traumatic paraspinal desmoid tumor. *World J Surg Oncol* 2008;6:28
- 5 Skhiri H, Zellama D, Ameer Frih M, et al. [Desmoid cervical tumour following the placing of an internal jugular catheter]. *Presse Med* 2004;33(02):95–97
- 6 Kulaylat MN, Karakousis CP, Keane CM, McCorvey D, Bem J, Ambrus JL Sr. Desmoid tumour: a pleomorphic lesion. *Eur J Surg Oncol* 1999;25(05):487–497
- 7 Shields CJ, Winter DC, Kirwan WO, Redmond HP. Desmoid tumours. *Eur J Surg Oncol* 2001;27(08):701–706
- 8 Jones IT, Jagelman DG, Fazio VW, Lavery IC, Weakley FL, McGannon E. Desmoid tumors in familial polyposis coli. *Ann Surg* 1986;204(01):94–97
- 9 Lotfi AM, Dozois RR, Gordon H, et al. Mesenteric fibromatosis complicating familial adenomatous polyposis: predisposing factors and results of treatment. *Int J Colorectal Dis* 1989;4(01):30–36
- 10 Naylor EW, Gardner EJ, Richards RC. Desmoid tumors and mesenteric fibromatosis in Gardner's syndrome: report of kindred 109. *Arch Surg* 1979;114(10):1181–1185
- 11 Lopez R, Kemalyan N, Moseley HS, Dennis D, Vetto RM. Problems in diagnosis and management of desmoid tumors. *Am J Surg* 1990;159(05):450–453
- 12 Reitamo JJ, Häyry P, Nykyri E, Saxén E. The desmoid tumor. I. Incidence, sex-, age- and anatomical distribution in the Finnish population. *Am J Clin Pathol* 1982;77(06):665–673
- 13 Gronchi A, Casali PG, Mariani L, et al. Quality of surgery and outcome in extra-abdominal aggressive fibromatosis: a series of patients surgically treated at a single institution. *J Clin Oncol* 2003;21(07):1390–1397
- 14 Dalén BPM, Geijer M, Kvist H, Bergh PM, Gunterberg BUP. Clinical and imaging observations of desmoid tumors left without treatment. *Acta Orthop* 2006;77(06):932–937
- 15 Lynch JJ, Parvizi J, Scheithauer BW, Krauss WE. Development of postoperative fibromatosis after resection of an intraspinal meningioma. Case report. *J Neurosurg* 1999;90(1, Suppl):121–124
- 16 Ewing J. The modern attitude toward traumatic cancer. *Bulletin of the New York Academy of Medicine* 1935;11(05):281