

Successful Management of Esophageal Perforation with Self-Expandable Metal Stent following Pneumatic Dilation for Achalasia Cardia

Abhai Verma¹ Samir Mohindra¹ Vivek Anand Saraswat¹ Uday Chand Ghoshal¹

¹Department of Gastroenterology, Sanjay Gandhi Post Graduate Institute of Medical Sciences, Lucknow, Uttar Pradesh, India

Address for correspondence Abhai Verma, MD, DM, Department of Gastroenterology, Sanjay Gandhi Post Graduate Institute of Medical Sciences, Lucknow, Uttar Pradesh, India (e-mail: drabhai@yahoo.com).

J Digest Endosc 2019;10:183–185

Abstract

Keywords

- achalasia cardia
- perforation
- pneumatic dilation

Achalasia cardia is the most common cause of motor dysphagia. Pneumatic dilation (PD) of lower esophageal sphincter remains the cornerstone of treatment. However, it is associated with esophageal perforation in some cases. We present a case of esophageal perforation following PD of achalasia cardia which was successfully managed with esophageal stent.

Introduction

Achalasia cardia is a motility disorder of esophagus characterized by aperistalsis of esophageal body with abnormally high resistance at lower esophageal sphincter (LES) due to lack of its relaxation during swallowing. The main pathophysiology behind achalasia is loss of inhibitory neurons in lower esophagus.¹ Esophageal manometry is the gold standard for diagnosis of achalasia cardia. There are many modes of treatment available for this disorder, which include pharmacotherapy with smooth muscle relaxant (calcium channel blockers and nitrates), botulinum toxin injection at LES, pneumatic dilation (PD), and Heller's myotomy (HM). Recently, per-oral endoscopic myotomy has been added to this armamentarium. In spite of so many treatment options, PD remains the cornerstone of treatment. PD is a simple day care procedure which involves dilation of the LES with a pneumatic balloon. Studies have shown that the success rate of PD is approximately 90%.^{2,3} The most dreaded complication of PD is esophageal perforation, which can occur in 2 to 4% cases.^{2,4} We describe here one of the cases of achalasia cardia who had esophageal perforation following PD and was successfully managed by covered self-expanding metal stent (SEMS).

Case Report

A 26-year-old male presented to us with complaints of dysphagia for solids, as well as liquids, for 2 years. He also reported occasional regurgitation of liquids and chest pain.

He denied any odynophagia, heartburn, hoarseness of voice, persistent cough, and insomnia. During this period, he lost 4 kg of weight. Esophagogastroduodenoscopy (EGD) revealed mildly dilated esophagus with liquid residue and abnormal resistance at LES. Stomach was normal. Barium swallow showed bird beak appearance at LES. Barium esophagogram and high-resolution esophageal manometry was diagnostic of achalasia cardia (►Figs. 1A). After discussion with patient, PD was done with 3 cm Rigiflex balloon. First, a guidewire was placed in stomach with the help of a gastroscope. Then under fluoroscopic guidance LES was dilated. Complete obliteration of waist of the balloon was achieved at 6 pound per square inch pressure. Balloon was inflated for 1 minute after which it was deflated and gradually withdrawn. The whole procedure was done under sedation. About 1 hour after the procedure, patient complained of increasing chest pain which was localized to the retrosternal area. It was severe requiring parenteral analgesics. Clinical examination revealed blood pressure of 110/60 mm Hg, pulse rate of 120/min, and respiratory rate of 22/min. Saturation at room air was 96%. There was no evidence of surgical emphysema in the chest and neck. An urgent computerized tomography (CT) scan of the thorax with oral contrast was done. Due to severe pain, the patient was unable to drink the contrast. However, CT scan showed pneumomediastinum with left-sided pleural effusion (►Fig. 1B). The patient was treated with analgesics, intravenous fluids, and antibiotics. A repeat EGD was done approximately 4 hours after the first procedure which revealed a 6- to 8-mm rent in lower esophagus approximately 3-cm

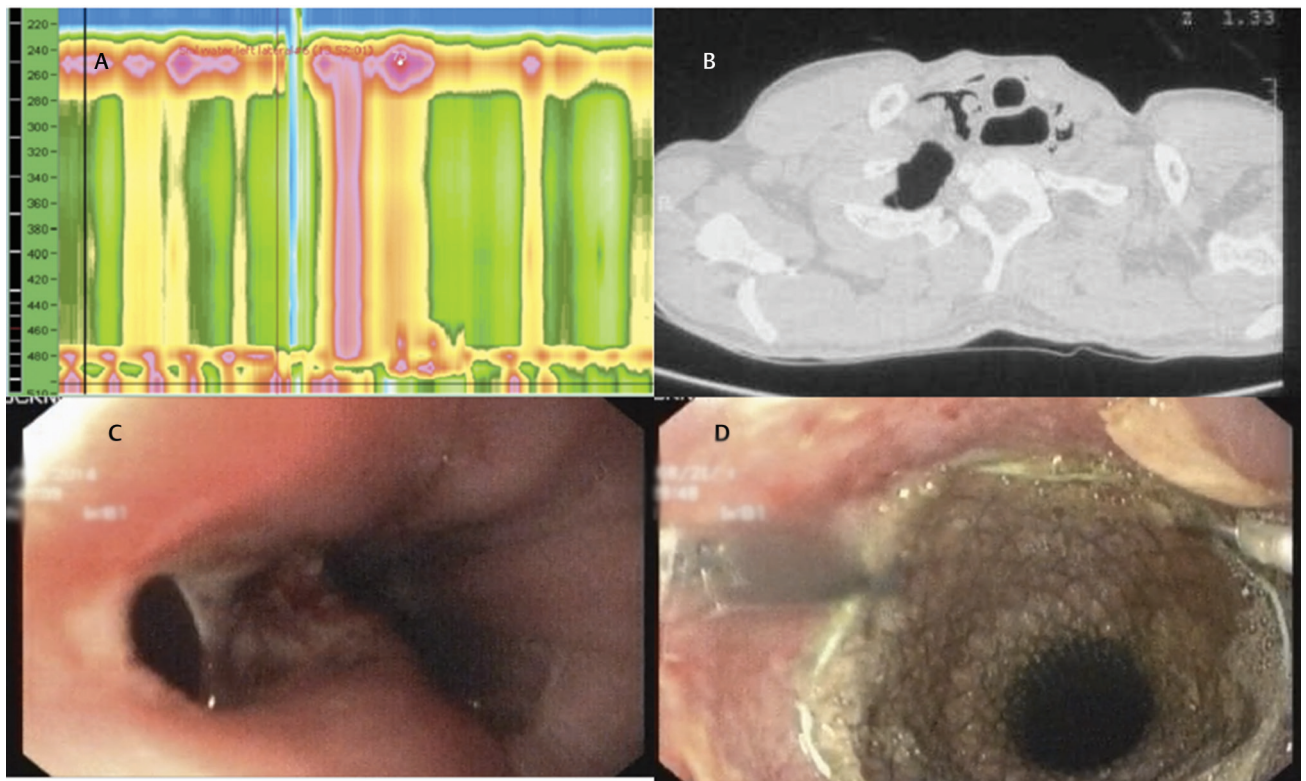


Fig. 1 (A) Esophageal manometry suggestive of type II achalasia cardia; (B) computed tomography scan of thorax after pneumatic dilation showing pneumomediastinum; (C) rent seen in lower esophagus following pneumatic dilation; (D) Esophageal self-expanding metal stent with hemoclips.

proximal to Z-line (►Fig. 1C). Fully covered esophageal metal stent of length 10 cm and diameter 2.3 cm was deployed in the lower esophagus (►Fig. 1D, ►Video 1). To avoid migration, two hemoclips were applied at the upper end of stent to anchor it to esophageal mucosa. Immediate postprocedure contrast study of esophagus showed no leak. On day 2, the patient became febrile. A tube was placed in the left pleural cavity. The patient was allowed orally from day 2. His pain and fever subsided in 3 days, and the intercostal drainage tube was removed on day 5. The patient was discharged on day 7 with normal oral intake. A repeat endoscopy was done after 2 weeks which showed the stent at same position as at the time of deployment. The stent was removed after 4 weeks. EGD done after stent removal showed a small ulcer at the site of perforation; however, no rent was seen. Contrast study of esophagus was done after stent removal also showed no leakage of contrast.

Discussion

PD is the most preferred procedure for the treatment of achalasia cardia with results comparable to HM.² The most dreaded

complication of PD is an esophageal perforation. Various series have reported perforation rates of 1 to 5%^{2,4-6} following PD. There is variation in the perforation rates reported in various series because of difference in techniques, size of balloon used, duration of dilation, and maximum pressure applied. The standard management for esophageal perforation varies depending on the duration of the presentation. The standard procedure for perforations detected within 6 hours is primary surgical repair. However, perforations presenting after 6 hours may require esophagostomy with or without tube drainages, as the chances of mediastinitis are high. Gradually more and more conservative approaches involving stents and clips have been advocated for these situations where risk of mediastinitis is minimal.

In our patient, esophageal perforation was detected within 6 hours and so the options were either primary surgical repair of the rent or endoscopic management. The size of the rent was too large for conservative management.⁶ As over the scope, clips were not immediately available at our center a covered SEMS was placed. Previously Siersema et al⁷ have reported the use of SEMS for traumatic nonmalignant perforation of the esophagus. In their series, 9 out of 11 patients could be salvaged from surgery. Out of 11 patients in this series, only one had achalasia cardia. Another case report by Elhanafi et al⁸ also described the similar use of SEMS for esophageal perforation following PD for achalasia cardia.

Endoscopists always worry about stent migration, especially when placed in a dilated esophagus like in achalasia cardia. In the present case, we used hemoclips to fix the stent to the esophageal wall. Although hemoclips are expected to fall off after few days; but during this time, the stent is expected to

Video 1

Achalasia perforation managed by esophageal self-expanding metal stent. Online content including video sequences viewable at: www.thieme-connect.de/products/ejournals/html/10.1055/s-0039-3399623.

expand fully and embed well in the esophageal mucosa. A few studies reported the use of SEMS for treatment of achalasia cardia.^{9,10} In these studies, specially designed SEMS for the treatment of achalasia cardia were used. Stent migration rate was 5%.

Timing of stent removal is also varies in various studies. Stents have been retained from few days to several weeks. Early removal of the stent is associated with risk of incomplete closure of perforation. On the other side, removal of the stent quite late makes the job difficult as the stent gets well embedded in esophageal mucosa. In the present case, we removed the stent after 4 weeks based on our previous experiences. However, as mentioned previously, it is a debatable issue.

Conclusion

In conclusion, the present case demonstrates successful non-surgical management of esophageal perforation following PD with removable esophageal stents. Therefore, we recommend the use of esophageal stents for managing perforations in appropriate situations.

Funding

None.

Conflict of Interest

None declared.

References

1 Ghoshal UC, Daschakraborty SB, Singh R. Pathogenesis of achalasia cardia. *World J Gastroenterol* 2012;18(24):3050–3057

2 Boeckxstaens GE, Annese V, des Varannes SB, et al; European Achalasia Trial Investigators. Pneumatic dilation versus laparoscopic Heller's myotomy for idiopathic achalasia. *N Engl J Med* 2011;364(19):1807–1816

3 Ghoshal UC, Rangan M. A review of factors predicting outcome of pneumatic dilation in patients with achalasia cardia. *J Neurogastroenterol Motil* 2011;17(1):9–13

4 Ghoshal UC, Rangan M, Misra A. Pneumatic dilation for achalasia cardia: reduction in lower esophageal sphincter pressure in assessing response and factors associated with recurrence during long-term follow up. *Dig Endosc* 2012;24(1):7–15

5 Zori AG, Kirtane TS, Gupte AR, et al. Utility of clinical suspicion and endoscopic re-examination for detection of esophagogastric perforation after pneumatic dilation for achalasia. *Endoscopy* 2016;48(2):128–133

6 Vanuytsel T, Lerut T, Coosemans W, et al. Conservative management of esophageal perforations during pneumatic dilation for idiopathic esophageal achalasia. *Clin Gastroenterol Hepatol* 2012;10(2):142–149

7 Siersema PD, Homs MY, Haringsma J, Tilanus HW, Kuipers EJ. Use of large-diameter metallic stents to seal traumatic non-malignant perforations of the esophagus. *Gastrointest Endosc* 2003;58(3):356–361

8 Elhanafi S, Othman M, Sunny J, et al. Esophageal perforation post pneumatic dilatation for achalasia managed by esophageal stenting. *Am J Case Rep* 2013;14:532–535

9 Cheng YS, Ma F, Li YD, et al. Temporary self-expanding metallic stents for achalasia: a prospective study with a long-term follow-up. *World J Gastroenterol* 2010;16(40):5111–5117

10 Zhao JG, Li YD, Cheng YS, et al. Long-term safety and outcome of a temporary self-expanding metallic stent for achalasia: a prospective study with a 13-year single-center experience. *Eur Radiol* 2009;19(8):1973–1980