

# Endovascular Treatment of Hepatic Venous Outflow Obstruction after Liver Transplant

Mithil B. Pandhi, DO<sup>1</sup> Andrew J. Lipnik, MD<sup>1,2</sup> Matthew M. Niemeyer, MD<sup>1,2</sup>

<sup>1</sup>Department of Radiology, University of Illinois Hospital & Health Sciences System, Chicago, Illinois

<sup>2</sup>Division of Interventional Radiology, University of Illinois Hospital & Health Sciences System, Chicago, Illinois

Address for correspondence Matthew M. Niemeyer, MD, Department of Radiology, Division of Interventional Radiology, University of Illinois Hospital & Health Sciences System, 1740 West Taylor Street, MC 931, Chicago, IL 60612 (e-mail: mniemeye@uic.edu).

Dig Dis Interv 2019;3:277–286.

## Abstract

Liver transplantation provides definitive treatment to address acute or chronic end-stage liver disease and its complications. Hepatic venous outflow obstruction is an infrequent complication of liver transplantation that affects graft survival by compromising outflow via transplant hepatic veins or inferior vena cava. It can occur in the early postoperative phase or in a delayed manner, resulting in venous congestion, graft dysfunction, graft failure, and death. This article addresses the pathophysiology of venous outflow obstruction as it relates to different surgical techniques and patient populations, the noninvasive tools for diagnosis, and the endovascular options for treatment along with their safety, efficacy, and durability.

## Keywords

- ▶ hepatic venous outflow obstruction
- ▶ liver transplant
- ▶ stent
- ▶ stenosis

Chronic liver disease is the 12th leading cause of mortality in the United States, responsible for approximately 40,545 deaths in 2016.<sup>1</sup> Liver transplantation provides definitive treatment to address acute or chronic end-stage liver disease and its complications once medical therapy is no longer effective.<sup>2</sup> Improvements in immunosuppression and surgical techniques have led to contemporary graft failure rates below 10% at 1 year, and 5-year survival rates for living donors nearing 75%.<sup>3</sup> Surgical techniques have also evolved over time to address the rising need for liver transplantation in the setting of a relatively stable deceased donor pool.<sup>4</sup> Transplant graft options include whole, partial, or split deceased donor liver transplant (DDLT), and living donor liver transplant (LDLT). Donor type (deceased vs. living), graft type (whole vs. partial), and surgeon/center experience determine the surgical anastomoses of the hepatic venous outflow. The overall rate of hepatic venous outflow dysfunction in adult recipients is between 1 and 4%,<sup>5</sup> and the type of anastomosis impacts its prevalence.<sup>6</sup> This review specifically addresses the current understanding of posttransplant venous outflow complications, their diagnosis, and management.

## Hepatic Venous Outflow Obstruction Pathophysiology

Post liver transplant vascular complications can be categorized based on the location of the lesion within either the inflow or outflow vessels. Inflow lesions affect vascular supply via the transplant hepatic artery or portal vein and impact graft survival via ischemia. Outflow lesions involve the transplant hepatic veins and inferior vena cava (IVC), and affect graft survival via a phenomenon termed hepatic venous outflow obstruction (HVOO).

Patients experiencing HVOO commonly present with congestive symptoms including ascites, pleural effusion, peripheral edema, abdominal pain, elevated liver enzymes, new onset splenomegaly, renal dysfunction, intestinal congestion, and, ultimately, fulminant graft dysfunction, hypotension, and multi-organ failure.<sup>6–12</sup> Mortality rates with HVOO have been reported up to 24%.<sup>13,14</sup>

HVOO can be subdivided by time frame: early and late postoperative. Early postoperative phase HVOO occurs within 28 days of surgery and is typically secondary to surgical technical factors such as tight anastomotic sutures, kinking

received  
April 14, 2019  
accepted after revision  
October 15, 2019  
published online  
November 21, 2019

Issue Theme Transplant Interventions;  
Guest Editors, Andrew J. Lipnik, MD and  
Jeet Minocha, MD

Copyright © 2019 by Thieme Medical  
Publishers, Inc., 333 Seventh Avenue,  
New York, NY 10001, USA.  
Tel: +1(212) 584-4662.

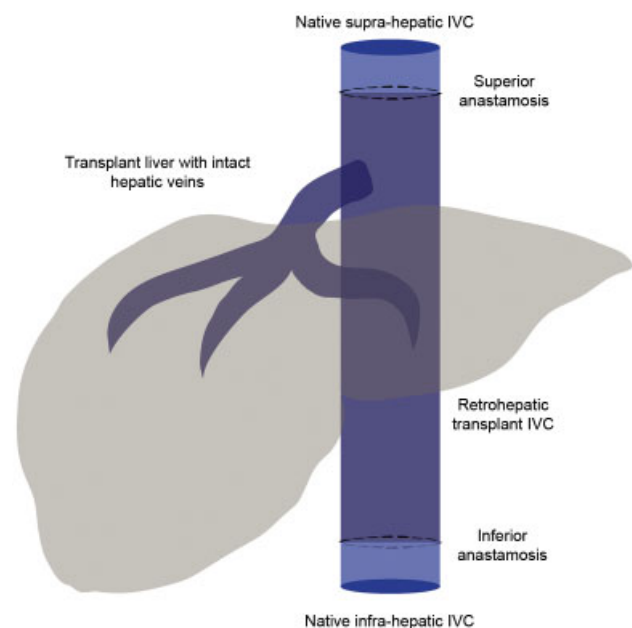
DOI <https://doi.org/10.1055/s-0039-3400494>.  
ISSN 2472-8721.

or twisting of the outflow tract, and compression from the graft or adjacent fluid collection.<sup>5,7,15-18</sup> Unlike the native recipient liver, which has multiple natural points of fixation in the abdomen such as the falciform ligament, the transplanted liver can rotate on its vascular pedicle leading to kinking or twisting of the outflow tract, and may be more common in liver donor or split liver transplants.<sup>13</sup> Late postoperative phase HVOO likely results from neointimal hyperplasia, fibrosis due to inflammation, or anastomotic compression due to graft maturation.<sup>10,15,16,19,20</sup>

## Surgical Technique for Hepatic Venous Outflow

Various surgical techniques are used to reconstruct the hepatic venous outflow during liver transplant, with the two most common being conventional orthotopic liver transplant (OLT) and piggyback liver transplant (PBLT).<sup>21</sup> The choice of surgical technique has implications with respect to venous outflow complications, imaging diagnosis, and endovascular treatment approaches.

Conventional OLT is utilized in the setting of whole liver DDLT. Operative technique involves complete hepatectomy with or without veno-venous bypass, and cross-clamping of the recipient retrohepatic IVC for resection and creation of new end-to-end caval anastomoses<sup>21,22</sup> (→ Fig. 1). Hypotension during the anhepatic phase, retroperitoneal bleeding, longer vascular reconstruction times, and complications of veno-venous bypass are classic shortcomings of conventional OLT.<sup>23,24</sup> These end-to-end drainage pathways tend to be adequately sized; however, outflow complications involving the superior and inferior caval anastomoses may still occur.



**Fig. 1** Schematic illustration of the conventional venous outflow surgical technique demonstrates separate supra-hepatic and infra-hepatic end-to-end caval anastomoses. The retrohepatic inferior vena cava (IVC) is removed en-bloc during the recipient hepatectomy.

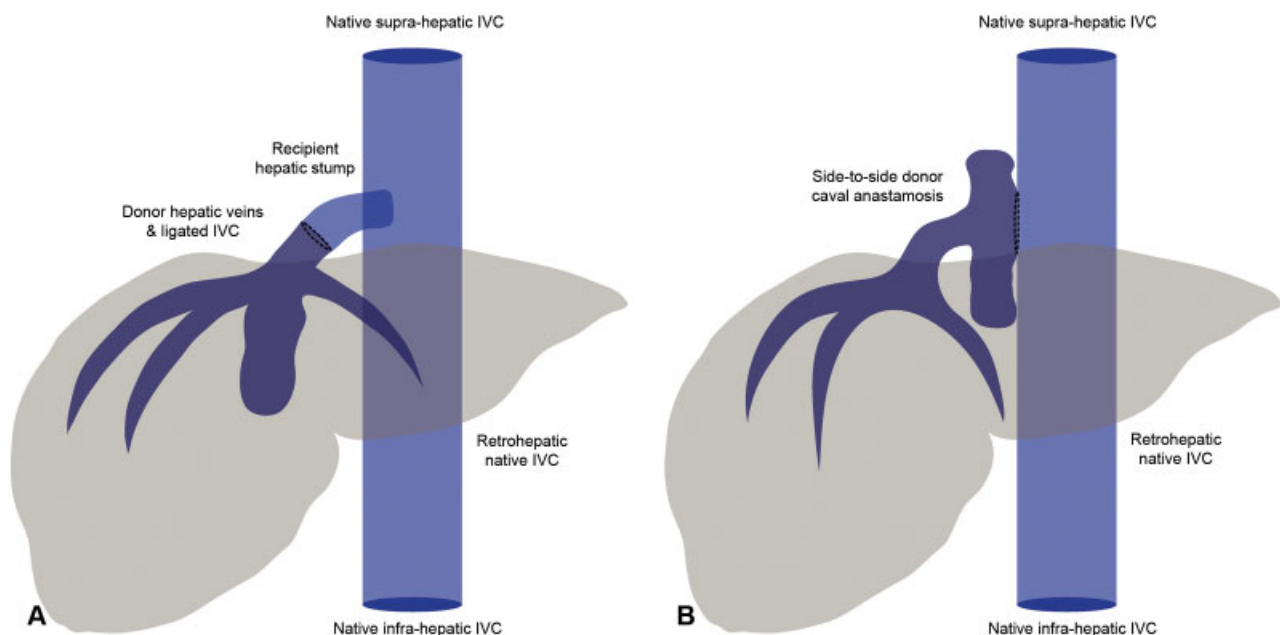
The PBLT technique shortens the anhepatic phase and obviates the need for veno-venous bypass by preserving the recipient IVC through the construction of a venous cuff between the recipient hepatic veins and the donor outflow venous tract.<sup>21,23-26</sup> The most common iterations of this technique include a venous cuff incorporating the right hepatic vein and middle hepatic vein, the middle hepatic vein and left hepatic vein, or all three hepatic veins.<sup>21,27</sup> This venous cuff is then fashioned into an end-to-end<sup>26</sup> or side-to-side caval anastomosis<sup>28,29</sup> (→ Fig. 2), sometimes with an additional anastomosis-enlarging cavotomy.<sup>21,30-32</sup> PBLT is commonly performed in LDLT, split or reduced graft placement, and pediatric transplants, as anatomic variations and size mismatch between graft and recipient can make conventional technique difficult.<sup>33,34</sup>

Overall, HVOO is a rare complication of OLT. In adults, recent rates of HVOO vary between 1 and 4%,<sup>5,35-37</sup> while historical rates vary widely and are reported to be between 0.5 and 13%.<sup>4,13,14,23,30,38-48</sup> Comparatively, HVOO occurs with a slightly higher frequency in the pediatric population. Recent rates vary between 0 and 5%,<sup>49-54</sup> with historical rates reported to be 5 to 27%.<sup>55-60</sup> Prospective data on outflow complications for specific combinations of graft types and donor types are challenging to generate given the complexity of transplant interventions, technical factors, operator variability, and evolving center experience. While a recent randomized clinical trial<sup>61</sup> and prior analysis of randomized clinical trials reported no difference in vascular complications between conventional and piggyback transplantation methods,<sup>27</sup> retrospective analyses demonstrate that conventional OLT has a lower rate of HVOO compared to PBLT. As PBLT is more often utilized in LDLT, split graft placement, and pediatric transplantation, it has been implicated in higher rates of HVOO in these instances.<sup>5,23,42,62</sup> For example, a review of 600 pediatric liver transplants revealed HVOO rates of 1% for whole liver grafts, 2% for living-related grafts, and 4% for reduced or split liver grafts.<sup>6</sup> Discrepant and/or small size of the venous anastomoses and varying drainage patterns to the IVC have been suspected in these settings.<sup>5,18,49,63,64</sup> Moreover, anatomical variations such as torsion or kinking that coincide with graft maturation may promote physical obstruction.<sup>4,5,65</sup>

It is important to recognize that there are many variant drainage patterns within the liver. In the setting of LDLT and split liver transplant, these variations can require individualized anastomoses between the donor graft and recipient. For example, a cryopreserved iliac vein conduit and/or polytetrafluoroethylene (PTFE) graft may be necessary with separate segment 5 and 8 tributaries, or a donor accessory inferior right hepatic vein draining separately into the IVC.<sup>66</sup> While specific anastomotic variants are beyond the scope of this paper, it is essential to understand the anatomy prior to interpreting diagnostic studies or intervening on any patient post liver transplant.

## Noninvasive Diagnosis

Noninvasive modalities, such as Doppler ultrasound (DUS) and computed tomography (CT), play an important role in the detection of posttransplant complications. DUS is an



**Fig. 2** Schematic illustrations of the piggyback venous anastomotic techniques. (A) The end-to-end piggyback technique preserves the native retrohepatic inferior vena cava (IVC) via an anastomosis between donor cava and a venous cuff created from the native hepatic veins. (B) Side-to-side piggyback technique also preserves the native retrohepatic IVC with an anastomosis between the donor IVC and venous cuff created from the native hepatic veins. The superior and inferior donor IVC are surgically ligated.

excellent screening tool in the evaluation of posttransplant liver dysfunction secondary to its widespread availability, portability, lack of ionizing radiation or iodinated contrast, and relative affordability compared to CT and magnetic resonance imaging. Although widely available, DUS is heavily dependent on the operator performing the exam, and evaluation can be limited in obese patients as well as in the setting of overlying bowel gas. CT will frequently be used to confirm DUS findings prior to intervention, or in the setting of a limited DUS evaluation.

The preservation of a biphasic or triphasic waveform on DUS essentially excludes the possibility of HVOO,<sup>67</sup> which can present as a dampened, monophasic waveform with a pulsatility index of 0.45 or less. These findings are nonspecific, however, and often seen in the posttransplant setting.<sup>67–69</sup> Ancillary findings may include a visible stenosis on grayscale imaging, color aliasing at the stenosis, reduced hepatic venous velocities below 10 cm/s,<sup>70</sup> and reversal of normal antegrade flow within the hepatic and/or portal venous system.

Similar findings are present when the IVC is involved. Velocities may increase up to fourfold in the diseased segment with associated Doppler aliasing artifact. Moreover, associated dilation of the proximal hepatic veins can be observed along with loss of phasicity and dampening of the expected biphasic or triphasic waveform.<sup>69,71</sup>

CT has a reported sensitivity of 100% with a positive predictive value of 81% in patients with HVOO.<sup>20</sup> Furthermore, CT has demonstrated better sensitivity and specificity in comparison with DUS (97 vs. 87% and 86 vs. 68%, respectively) with the benefit of attenuation differences, which may suggest vascular congestion.<sup>72</sup> Coronal reconstructions of the IVC may be particularly useful for the detection of caval complications.<sup>73</sup>

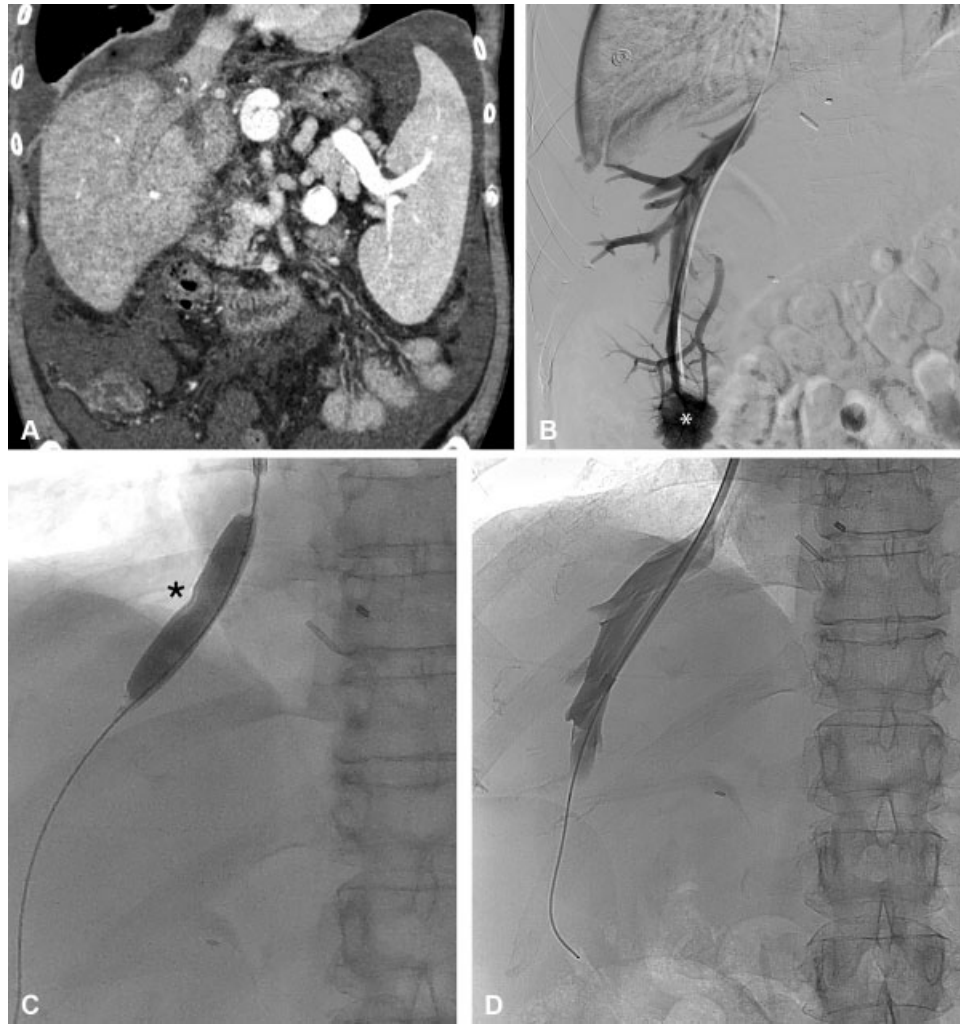
## Venography and Endovascular Intervention

### Hepatic Veins

Conventional venography allows for assessment of anastomotic narrowing, relative vascular flow, and measurement of venous pressures. Additionally, therapeutic intervention can then be performed immediately following confirmation of suspected HVOO. Transjugular access is typically utilized to perform venography within the hepatic veins and IVC, although anatomy can occasionally favor a transfemoral approach. If a severe anastomotic stenosis or occlusion precludes transjugular selection of the hepatic veins, ultrasound-guided percutaneous transhepatic puncture of a dilated hepatic vein can be performed to assist with catheterization.<sup>74</sup>

Measurement of a pressure gradient across the anastomosis can support diagnosis of a venographic stenosis; however, a validated threshold gradient remains to be determined. Some authors suggest a more stringent threshold gradient of >10 mm Hg,<sup>40,75</sup> while others have argued that gradients >3 mm Hg can be symptomatic,<sup>31</sup> reporting clinical improvements with treatment of gradient ranges between 3 and 5 mm Hg.<sup>20,42</sup>

Treatments for HVOO are primarily endovascular, with surgical revision infrequently performed secondary to the difficult exposure required to reach the outflow anastomosis. Venoplasty is often the initial intervention. Although high rates of initial patency are described,<sup>4,33,76</sup> HVOO often recurs following venoplasty, requiring serial dilation or stent placement. After identification of the stenotic segment, prolonged inflation of an angioplasty balloon is performed until the stenotic waist is reduced (► Fig. 3). The balloon size should be slightly oversized by 1 to 2 mm with respect to the diameter of the hepatic vein. Kubo et al demonstrated



**Fig. 3** A patient with ascites and hydrothorax, 8 months after piggyback technique liver transplant. (A) Coronal postcontrast computed tomography demonstrates a high-grade stenosis of the hepatic venous anastomosis with associated abdominal ascites and right pleural effusion. (B) Selective digital subtraction venogram with catheter positioned in the right hepatic vein demonstrates the high-grade anastomotic stenosis (arrow). A trans-anastomotic pressure gradient of 20 mm Hg confirms the venographic findings. The inferior vena cava is not opacified with contrast as the catheter is occlusive across the stenosis and there is intraparenchymal reflux (white asterisk) through the sinusoids and into the portal vein (arrowhead). Notably, pathology from concomitant transjugular liver biopsy demonstrated zone-three congestion and necrosis, consistent with hepatic venous outflow obstruction. (C) Venoplasty is performed with a 12 mm plain balloon, demonstrating a waist at the anastomotic stenosis (black asterisk). (D) After venoplasty, antegrade flow in the hepatic vein and across the anastomosis is reestablished, and the pressure gradient across the stenosis improves to 4 mm Hg.

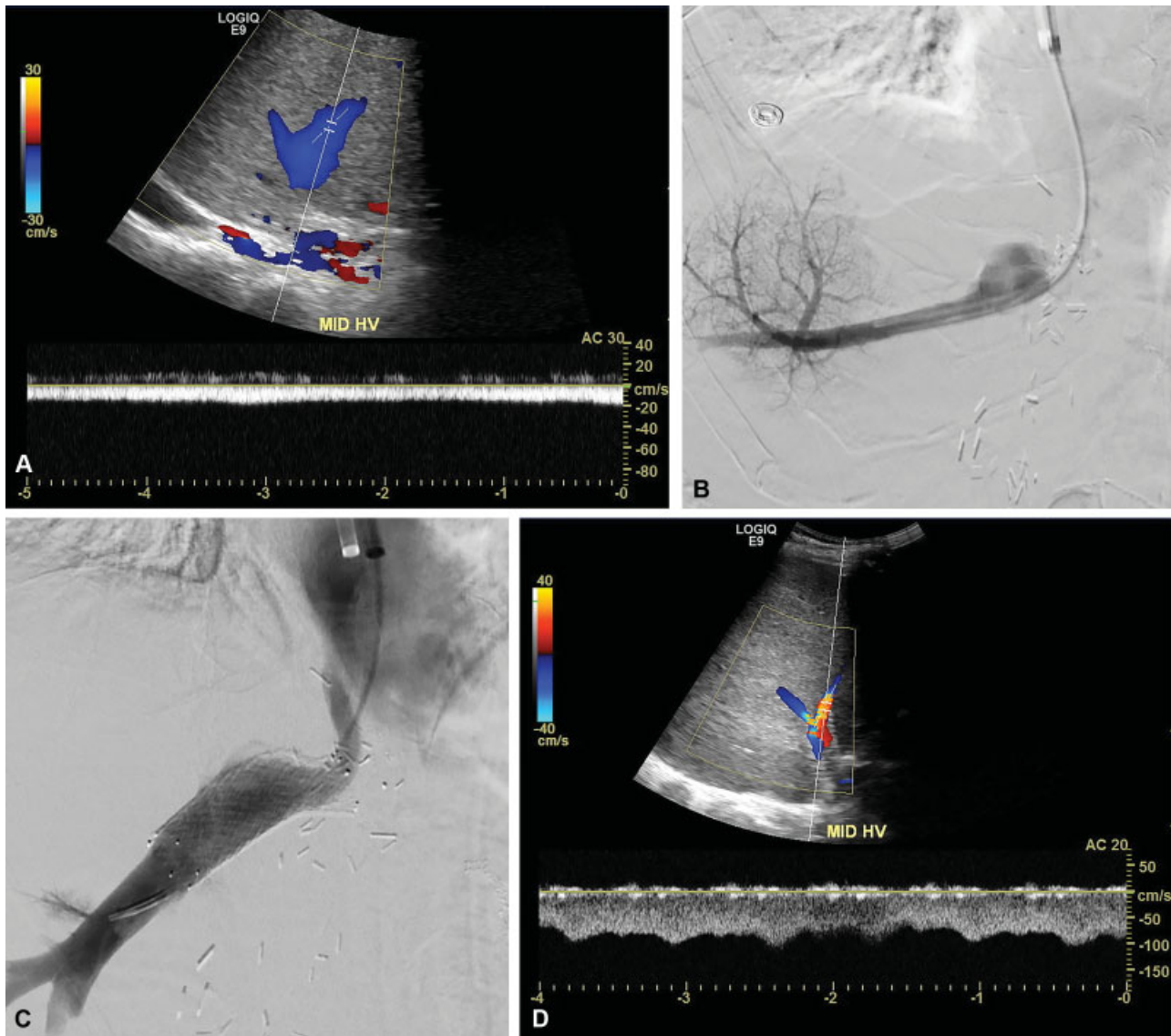
restenosis in 55% of patients, a primary patency rate of 60% at 5 years, and an assisted patency rate of 100% at the end of the 5 years follow-up period in the patients with restenosis.<sup>4</sup> Similar assisted patency rates (95–100%) are reported in pediatric patients with HVOO,<sup>62,77</sup> with 76 to 79% of patients requiring no more than two to three dilations.<sup>53,77</sup>

Some favor angioplasty over primary stent placement because indwelling stents are inherently thrombogenic, promote neointimal hyperplasia, and their presence may complicate future surgical intervention or retransplantation.<sup>42,53,77</sup> These considerations are particularly important in the pediatric population in which an initially appropriately sized stent may become a fixed stenosis as the child and graft grow.<sup>53,60</sup> For this reason, stent placement may be deferred in pediatric liver patients until maturity in favor of serial angioplasty.

Emerging data highlight a role for primary stenting (► **Fig. 4**) in the setting of HVOO with promising long-term stent patency rates at 5 to 10 years (► **Table 1**). Early postoperative HVOO may provide a unique scenario for primary stent placement as venoplasty can theoretically disrupt the newly created transplant anastomosis.<sup>42</sup> Moreover, the causes of early postoperative HVOO may not respond well to venoplasty alone, given its inability to address kinking, vascular torsion, or ongoing compression. Even with these considerations, Kim et al recently reported lower patency rates after stent placement than other cohorts, attributing their findings to high rates of kinking that were not amenable to stenting.<sup>37</sup>

Comparison between balloon-expandable and self-expanding stents in the setting of HVOO is yet to be performed. Balloon-expandable stents are often utilized to treat hepatic venous





**Fig. 4** A 59-year-old male 3 months after split liver transplant with piggyback anastomosis presents with rising bilirubin and liver enzymes. (A) Transplant hepatic venous Doppler examination demonstrates a monophasic waveform with decreased velocities and diminished pulsatility indices in the right and middle hepatic veins. (B) Selective venogram with catheter positioned in the hepatic vein demonstrates a high-grade anastomotic stenosis with catheter occlusion across the stenotic segment (arrow). The measured trans-stenotic gradient is 23 mm Hg. (C) After primary stent placement across the anastomotic stenosis with a 14 mm x 4 cm self-expanding nitinol stent, there is improved hepatic venous flow and a significantly reduced gradient now measuring 5 mm Hg. The stent is appropriately oversized with respect to the size of the hepatic vein and is well positioned across the stenosis without excessive protrusion into the inferior vena cava. (D) At 2-year follow-up, a Doppler ultrasound demonstrates stent patency with an improved, biphasic waveform, and a sustained improvement in hepatic vein velocities.

**Table 1** Long-term stent patency rates in hepatic venous outlet obstruction

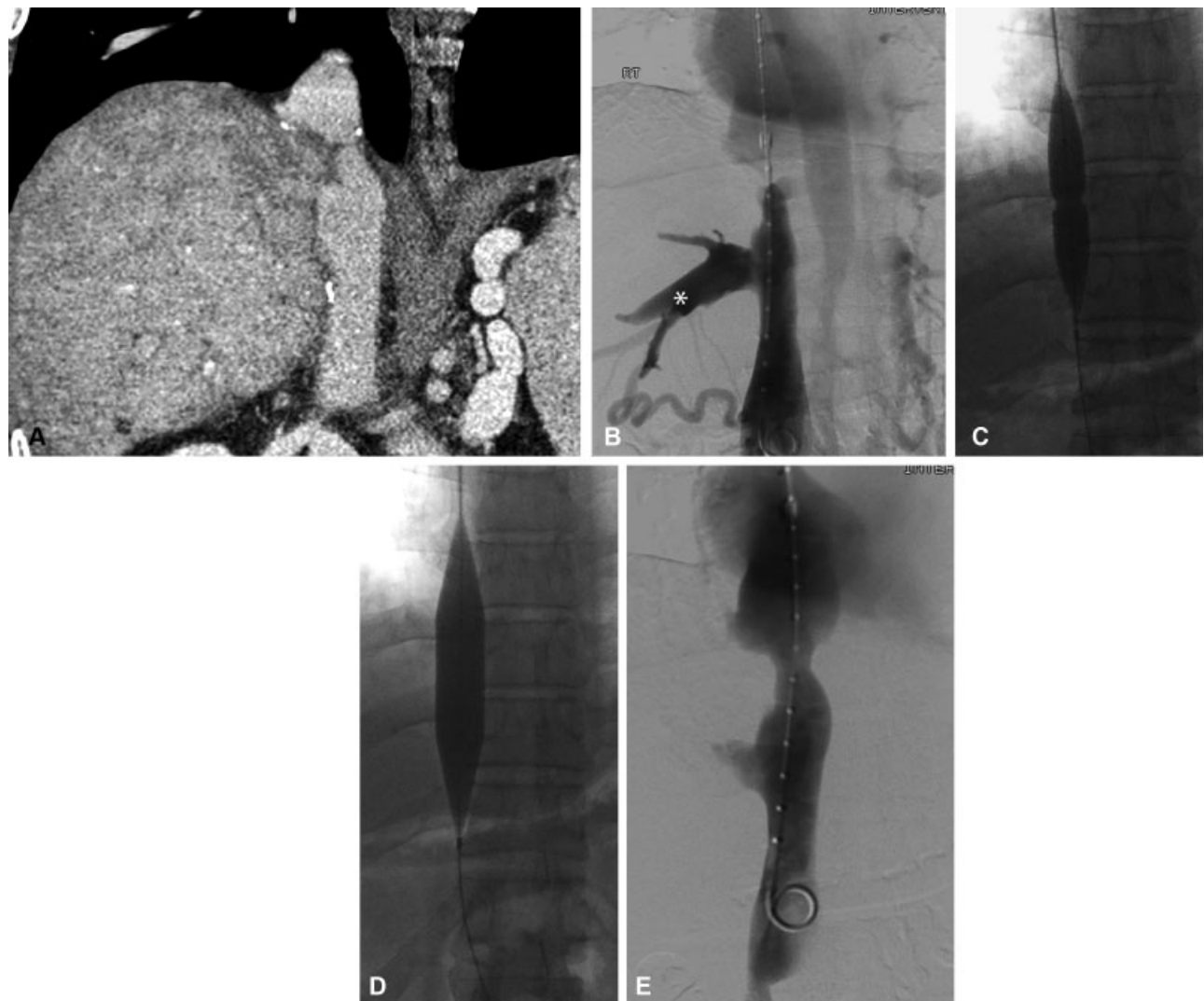
	1-year patency (%)	3-year patency (%)	5-year patency (%)	10-year patency (%)
Ko et al <sup>42</sup>	82	75	72	NA
Chu et al <sup>35</sup>	94	94	94	NA
Jang et al <sup>20</sup>	88	88	88	88
Early	70	70	70	70
Late				
Kim et al <sup>37</sup>	76	46	56	NA
Early	40	20	20	
Late				

This document was downloaded for personal use only. Unauthorized distribution is strictly prohibited.

stenosis given their higher radial strength and ease of precise placement.<sup>74</sup> Wang et al utilized short balloon-expandable stents in the setting of HVOO and saw high patency rates.<sup>33</sup> Ko et al and Chu et al demonstrated high patency rates with self-expanding stents<sup>35,42</sup> with increased stent diameter demonstrating an association with patency.<sup>42</sup> Reported stent diameters range from 8 to 14 mm within the hepatic veins.<sup>74</sup> In the pediatric population, utilization of large self-expanding stents may allow the stent to grow with the patient, potentially reducing concern for future stenosis or stent migration.<sup>62,77</sup> Data on pediatric stent placement is lacking although high rates of clinical success and patency have been previously reported.<sup>77,78</sup> Recent data show high rates of stent patency up to 13.5 years (median 6 years)<sup>62</sup> and 17 years (median 7.5 years)<sup>54</sup> in low-powered studies.

Complications related to hepatic vein angioplasty and stent placement are rare.<sup>42</sup> While there is a theoretical risk of anastomotic rupture after angioplasty in the early post-transplant setting, multiple studies cite a rate of 0%.<sup>4,53</sup> Bleeding complications following angioplasty at later time points are very unlikely given the retroperitoneal location and postoperative scarring.

Another rare, albeit feared, complication is stent migration, which can occur secondary to respiratory (and cardiac) motion, or due to the complex and dynamic anatomy of the hepatic venous anastomoses. In one retrospective study involving 152 pediatric liver transplant patients, 18 of whom required intervention for HVOO, no stent placements were complicated by stent migration.<sup>62</sup> In two additional retrospective studies, stent migration occurred in only one



**Fig. 5** A 35-year-old man with piggyback technique liver transplant 10 years prior developed new enlarged abdominal wall collaterals. (A) Coronal image from the venous phase of a computed tomographic scan of the abdomen demonstrates a high-grade stenosis (arrow) of the suprahepatic inferior vena cava (IVC). There is hepatic congestion evidenced by heterogeneous enhancement of the liver. (B) Digital subtraction venogram with 5 French pigtail catheter positioned in the infrahepatic IVC from right internal jugular venous access demonstrates a 90% stenosis involving the suprahepatic IVC (arrowheads) with a trans-stenotic gradient of 14 mm Hg. Contrast refluxes into the hepatic veins (asterisk) and multiple collateral varices (arrow) are opacified. (C) Serial venoplasty is performed, first with a 14 mm balloon, demonstrating a waist (arrowheads) at the stenosis. (D) Prolonged venoplasty with an 18 mm balloon demonstrates resolution of the waist. (E) Post venoplasty digital subtraction venogram demonstrates improved luminal gain with a residual stenosis of < 50%, and an improved trans-stenotic pressure gradient of 1 mm Hg. After venoplasty, abdominal wall collaterals resolved.

patient per study—in one case, the stent migrated slightly into the IVC requiring no further intervention,<sup>76</sup> and in the second case, migration occurred into the right atrium, requiring retrieval over the wire with balloon assistance.<sup>37</sup> At the authors' institution, general anesthesia is often used to limit respiratory motion, as deep inspiration during stent deployment can result in maldeployment necessitating stent retrieval from the IVC or right atrium. Selection of the appropriate stent size is also critical in preventing migration. In the event that a stent migrates or is minimally misplaced into the IVC, the stent can be stabilized by placement of an overlapping stent.<sup>74</sup> However, if a stent migrates or extends too far centrally into the right atrium, the consequences can be severe and life threatening, potentially requiring cardiac surgery for removal if it cannot be retrieved through standard endovascular techniques.

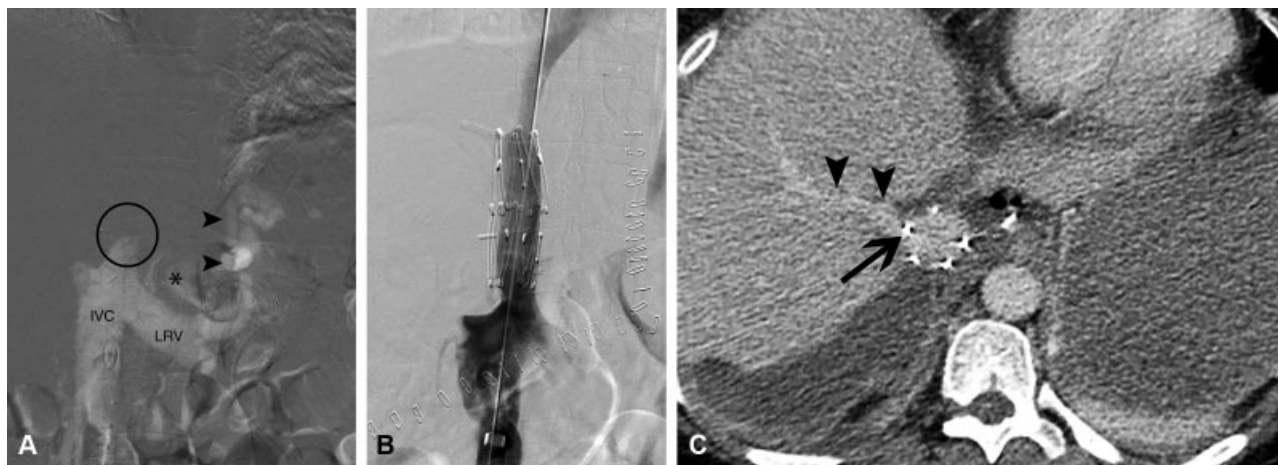
### Inferior Vena Cava

Caval complications posttransplantation most frequently result from stenosis of the suprahepatic IVC or infrahepatic IVC anastomoses in standard technique liver transplants. Historically, venoplasty (→Fig. 5) has been successful but resulted in recurrence rates near 50%.<sup>75,79–82</sup> Small retrospective studies utilizing caval stent placement show high rates of technical and clinical success with primary assisted patency rates of 94<sup>83</sup> and 100%<sup>82</sup> reported at 1 and 7 years, respectively. Given these rates of success, caval stenting is often considered to be a first-line intervention<sup>39,84</sup> with stent sizes ranging between 14 and 24 mm.<sup>74</sup> Additionally, Parvinian and Gaba<sup>85</sup> proposed the utilization of a cutting balloon over stepwise sessions to augment caval luminal caliber, reporting successful luminal expansion from 2 to 3 mm to 10 to 11 mm. This technique, akin to addressing biliary strictures, would provide an alternative route when caval stenting is undesirable.<sup>85</sup>

Complication profiles for venoplasty and stenting of IVC stenosis are similar to those seen with hepatic venous stenosis. While there is a theoretical risk of anastomotic rupture after venoplasty, particularly in the early postoperative setting, there are no documented cases of rupture in the literature.<sup>39</sup> Stent migration, while potentially serious, is rare.<sup>39</sup> The open architectural design and high radial force of the Gianturco Z-stent (Cook Medical, Bloomington, IN) make it a desirable choice for use in the IVC. The stent interstices do not obstruct the hepatic outflow when placed across the confluence (→Fig. 6). This also allows future venoplasty and stenting of the hepatic veins if a concomitant hepatic venous stenosis warrants treatment. Additionally, anchoring barbs are incorporated into the struts, a design feature intended to reduce migration.<sup>74</sup>

### Conclusion

HVOO is an infrequent complication of liver transplantation that affects graft survival by compromising outflow via transplant hepatic veins or IVC. While conventional OLT creates end-to-end drainage pathways between the native and transplant IVC, PBLT technique involves creation of an anastomotic cuff between the recipient hepatic veins and donor outflow tract. PBLT is commonly used in LDLT, split/reduced graft transplant, and pediatric transplant, and is implicated in higher rates of HVOO due to the complex and variable anatomy encountered in these scenarios. HVOO can occur in the early postoperative phase or in a delayed manner, resulting in clinical signs and symptoms of venous congestion, renal failure, and graft dysfunction or failure. Ultrasound is the best noninvasive screening tool to evaluate the venous anastomoses, and may demonstrate a monophasic hepatic waveform, a visible stenosis, reduced hepatic venous velocities, or reversal of flow within the hepatic and/or portal venous system. Conventional venography is



**Fig. 6** A 33-year-old woman with abdominal and lower extremity edema and hyperbilirubinemia 10 days after deceased donor liver transplant. (A) Digital subtraction venography performed with CO<sub>2</sub> contrast agent demonstrates near complete occlusion of the infrarenal inferior vena cava (IVC) (black circle) and a 16 mm Hg gradient from the IVC to the right atrium. Additionally, there is reversal of flow into the portal venous system (not pictured) through an existing gastrorenal shunt (black arrowheads) via the left renal vein (LRV). (B) Angiogram postplacement of a 2.5 × 5.0 cm nitinol Z-stent within the IVC demonstrates resolution of the obstruction and reduction of the IVC to right atrium gradient to 2 mm Hg. Note that there is no filling of the gastrorenal shunt following stent placement. (C) Axial computed tomography image demonstrates a Z-stent strut across the hepatic vein origin (circle); however, flow is preserved as expected given the large Z-stent interstices.



the gold standard for confirming the diagnosis of HVOO, providing both visual assessment of a stenosis and manometric evaluation of a significant pressure gradient. Furthermore, it facilitates endovascular treatment of significant lesions with either serial angioplasty or stent placement, both of which demonstrate efficacy and high rates of long-term assisted-patency in adult and pediatric populations.

#### Disclosure Statement

MP, AL, and MN have nothing to disclose.

#### Conflict of Interest

None.

#### References

- Xu J, Murphy SL, Kochanek KD, Bastian B, Arias E. Deaths: Final Data for 2016. In: *Statistics NCfH*. ed. Vol. 672018.
- Martin P, DiMartini A, Feng S, Brown R Jr, Fallon M. Evaluation for liver transplantation in adults: 2013 practice guideline by the American Association for the Study of Liver Diseases and the American Society of Transplantation. *Hepatology* 2014;59(03):1144–1165
- Kim WR, Lake JR, Smith JM, et al. OPTN/SRTR 2016 annual data report: liver. *Am J Transplant* 2018;18(Suppl 1):172–253
- Kubo T, Shibata T, Itoh K, et al. Outcome of percutaneous transhepatic venoplasty for hepatic venous outflow obstruction after living donor liver transplantation. *Radiology* 2006;239(01):285–290
- Arudchelvam J, Bartlett A, McCall J, Johnston P, Gane E, Munn S. Hepatic venous outflow obstruction in piggyback liver transplantation: single centre experience. *ANZ J Surg* 2017;87(03):182–185
- Buell JF, Funaki B, Cronin DC, et al. Long-term venous complications after full-size and segmental pediatric liver transplantation. *Ann Surg* 2002;236(05):658–666
- Zajko AB, Claus D, Clapuyt P, et al. Obstruction to hepatic venous drainage after liver transplantation: treatment with balloon angioplasty. *Radiology* 1989;170(3 Pt 1):763–765
- Parrilla P, Sánchez-Bueno F, Figueras J, et al. Analysis of the complications of the piggy-back technique in 1112 liver transplants. *Transplant Proc* 1999;31(06):2388–2389
- Aucejo F, Winans C, Henderson JM, et al. Isolated right hepatic vein obstruction after piggyback liver transplantation. *Liver Transpl* 2006;12(05):808–812
- Koc S, Akbulut S, Soyer V, et al. Hepatic venous outflow obstruction after living-donor liver transplant: single center experience. *Exp Clin Transplant* 2017
- Piardi T, Lhuair M, Bruno O, et al. Vascular complications following liver transplantation: a literature review of advances in 2015. *World J Hepatol* 2016;8(01):36–57
- Beaubien-Souligny W, Pépin M-N, Legault L, et al. Acute kidney injury due to inferior vena cava stenosis after liver transplantation: a case report about the importance of hepatic vein Doppler ultrasound and clinical assessment. *Can J Kidney Health Dis* 2018; 5:2054358118801012–2054358118801012
- Navarro F, Le Moine MC, Fabre JM, et al. Specific vascular complications of orthotopic liver transplantation with preservation of the retrohepatic vena cava: review of 1361 cases. *Transplantation* 1999;68(05):646–650
- Akun E, Yaprak O, Killi R, Balci NC, Tokat Y, Yuzer Y. Vascular complications in hepatic transplantation: single-center experience in 14 years. *Transplant Proc* 2012;44(05):1368–1372
- Someda H, Moriyasu F, Fujimoto M, et al. Vascular complications in living related liver transplantation detected with intraoperative and postoperative Doppler US. *J Hepatol* 1995;22(06):623–632
- Fujimoto M, Moriyasu F, Someda H, et al. Recovery of graft circulation following percutaneous transluminal angioplasty for stenotic venous complications in pediatric liver transplantation: assessment with Doppler ultrasound. *Transpl Int* 1995;8(02):119–125
- Chen YS, Chen CL, Liu PP, et al. Successful treatment of hepatic vein thrombosis following reduced-size liver transplantation. *Transplant Proc* 1998;30(07):3203–3204
- Quintela J, Fernández C, Aguirrezabalaga J, et al. Early venous outflow obstruction after liver transplantation and treatment with cavo-cavostomy. *Transplant Proc* 2009;41(06):2450–2452
- Sayers RD, Watt PA, Muller S, Bell PR, Thurston H. Endothelial cell injury secondary to surgical preparation of reversed and in situ saphenous vein bypass grafts. *Eur J Vasc Surg* 1992;6(04):354–361
- Jang JY, Jeon UB, Park JH, et al. Efficacy and patency of primary stenting for hepatic venous outflow obstruction after living donor liver transplantation. *Acta Radiol* 2017;58(01):34–40
- Beal EW, Bennett SC, Whitson BA, Elkhannas E, Henry ML, Black S. Caval reconstruction techniques in orthotopic liver transplantation. *World J Surg Proc* 2015;5:41–57
- Starzl TE, Marchioro TL, Vonkaulla KN, Hermann G, Brittain RS, Waddell WR. Homotransplantation of the liver in humans. *Surg Gynecol Obstet* 1963;117:659–676
- Nishida S, Nakamura N, Vaidya A, et al. Piggyback technique in adult orthotopic liver transplantation: an analysis of 1067 liver transplants at a single center. *HPB (Oxford)* 2006;8(03):182–188
- Reddy KS, Johnston TD, Putnam LA, Isley M, Ranjan D. Piggyback technique and selective use of veno-venous bypass in adult orthotopic liver transplantation. *Clin Transplant* 2000;14(4 Pt 2):370–374
- Calne RY, Williams R. Liver transplantation in man. I. Observations on technique and organization in five cases. *BMJ* 1968;4(5630):535–540
- Tzakis A, Todo S, Starzl TE. Orthotopic liver transplantation with preservation of the inferior vena cava. *Ann Surg* 1989;210(05):649–652
- Gurusamy KS, Pamecha V, Davidson BR. Piggy-back graft for liver transplantation. *Cochrane Database Syst Rev* 2011;(01):CD008258
- Belghiti J, Panis Y, Sauvanet A, Gayet B, Fékété F. A new technique of side to side caval anastomosis during orthotopic hepatic transplantation without inferior vena cava occlusion. *Surg Gynecol Obstet* 1992;175(03):270–272
- Belghiti J, Noun R, Sauvanet A. Temporary portocaval anastomosis with preservation of caval flow during orthotopic liver transplantation. *Am J Surg* 1995;169(02):277–279
- Cescon M, Grazi GL, Varotti G, et al. Venous outflow reconstructions with the piggyback technique in liver transplantation: a single-center experience of 431 cases. *Transpl Int* 2005;18(03):318–325
- Ducerf C, Rode A, Adham M, et al. Hepatic outflow study after piggyback liver transplantation. *Surgery* 1996;120(03):484–487
- Gerber DA, Passannante A, Zacks S, et al. Modified piggyback technique for adult orthotopic liver transplantation. *J Am Coll Surg* 2000;191(05):585–589
- Wang SL, Sze DY, Busque S, et al. Treatment of hepatic venous outflow obstruction after piggyback liver transplantation. *Radiology* 2005;236(01):352–359
- Robles R, Parrilla P, Acosta F, et al. Complications related to hepatic venous outflow in piggy-back liver transplantation: two- versus three-suprahepatic-vein anastomosis. *Transplant Proc* 1999;31(06):2390–2391
- Chu HH, Yi NJ, Kim HC, et al. Longterm outcomes of stent placement for hepatic venous outflow obstruction in adult liver transplantation recipients. *Liver Transpl* 2016;22(11):1554–1561
- Pitchaimuthu M, Roll GR, Zia Z, et al. Long-term follow-up after endovascular treatment of hepatic venous outflow obstruction following liver transplantation. *Transpl Int* 2016;29(10):1106–1116



- 37 Kim KS, Lee JS, Choi GS, et al. Long-term outcomes after stent insertion in patients with early and late hepatic vein outflow obstruction after living donor liver transplantation. *Ann Surg Treat Res* 2018;95(06):333–339
- 38 Sze DY, Semba CP, Razavi MK, Kee ST, Dake MD. Endovascular treatment of hepatic venous outflow obstruction after piggyback technique liver transplantation. *Transplantation* 1999;68(03):446–449
- 39 Weeks SM, Gerber DA, Jaques PF, et al. Primary Gianturco stent placement for inferior vena cava abnormalities following liver transplantation. *J Vasc Interv Radiol* 2000;11(2 Pt 1):177–187
- 40 Borsa JJ, Daly CP, Fontaine AB, et al. Treatment of inferior vena cava anastomotic stenoses with the Wallstent endoprosthesis after orthotopic liver transplantation. *J Vasc Interv Radiol* 1999;10(01):17–22
- 41 Uzochukwu LN, Bluth EI, Smetherman DH, et al. Early postoperative hepatic sonography as a predictor of vascular and biliary complications in adult orthotopic liver transplant patients. *AJR Am J Roentgenol* 2005;185(06):1558–1570
- 42 Ko GY, Sung KB, Yoon HK, et al. Early posttransplant hepatic venous outflow obstruction: long-term efficacy of primary stent placement. *Liver Transpl* 2008;14(10):1505–1511
- 43 Wojcicki M, Post M, Pakosz-Golanowska M, et al. Vascular complications following adult piggyback liver transplantation with end-to-side cavo-cavostomy: a single-center experience. *Transplant Proc* 2009;41(08):3131–3134
- 44 Audet M, Piardi T, Panaro F, et al. Four hundred and twenty-three consecutive adults piggy-back liver transplantations with the three suprahepatic veins: was the portal systemic shunt required? *J Gastroenterol Hepatol* 2010;25(03):591–596
- 45 Pérez-Saborido B, Pacheco-Sánchez D, Barrera-Rebollo A, et al. Incidence, management, and results of vascular complications after liver transplantation. *Transplant Proc* 2011;43(03):749–750
- 46 Umehara M, Narumi S, Sugai M, et al. Hepatic venous outflow obstruction in living donor liver transplantation: balloon angioplasty or stent placement? *Transplant Proc* 2012;44(03):769–771
- 47 Khalaf H. Vascular complications after deceased and living donor liver transplantation: a single-center experience. *Transplant Proc* 2010;42(03):865–870
- 48 Khorsandi SE, Athale A, Vilca-Melendez H, et al. Presentation, diagnosis, and management of early hepatic venous outflow complications in whole cadaveric liver transplant. *Liver Transpl* 2015;21(07):914–921
- 49 Sommovilla J, Doyle MM, Vachharajani N, et al. Hepatic venous outflow obstruction in pediatric liver transplantation: technical considerations in prevention, diagnosis, and management. *Pediatr Transplant* 2014;18(05):497–502
- 50 Tannuri U, Tannuri ACA, Santos MM, Miyatani HT. Technique advance to avoid hepatic venous outflow obstruction in pediatric living-donor liver transplantation. *Pediatr Transplant* 2015;19(03):261–266
- 51 Kitajima T, Kaido T, Iida T, et al. Left lobe graft poses a potential risk of hepatic venous outflow obstruction in adult living donor liver transplantation. *Liver Transpl* 2016;22(06):785–795
- 52 Zhang Z-Y, Jin L, Chen G, et al. Balloon dilatation for treatment of hepatic venous outflow obstruction following pediatric liver transplantation. *World J Gastroenterol* 2017;23(46):8227–8234
- 53 Galloux A, Pace E, Franchi-Abella S, Brancheau S, Gonzales E, Pariente D. Diagnosis, treatment and outcome of hepatic venous outflow obstruction in paediatric liver transplantation: 24-year experience at a single centre. *Pediatr Radiol* 2018;48(05):667–679
- 54 Lu KT, Cheng YF, Chen TY, et al. Efficiency of transluminal angioplasty of hepatic venous outflow obstruction in pediatric liver transplantation. *Transplant Proc* 2018;50(09):2715–2717
- 55 Emond JC, Heffron TG, Whittington PF, Broelsch CE. Reconstruction of the hepatic vein in reduced size hepatic transplantation. *Surg Gynecol Obstet* 1993;176(01):11–17
- 56 Egawa H, Inomata Y, Uemoto S, et al. Hepatic vein reconstruction in 152 living-related donor liver transplantation patients. *Surgery* 1997;121(03):250–257
- 57 de Villa VH, Chen CL, Chen YS, et al. Outflow tract reconstruction in living donor liver transplantation. *Transplantation* 2000;70(11):1604–1608
- 58 Akamatsu N, Sugawara Y, Kaneko J, et al. Surgical repair for late-onset hepatic venous outflow block after living-donor liver transplantation. *Transplantation* 2004;77(11):1768–1770
- 59 Tannuri U, Mello ES, Carnevale FC, et al. Hepatic venous reconstruction in pediatric living-related donor liver transplantation—experience of a single center. *Pediatr Transplant* 2005;9(03):293–298
- 60 Sakamoto S, Egawa H, Kanazawa H, et al. Hepatic venous outflow obstruction in pediatric living donor liver transplantation using left-sided lobe grafts: Kyoto University experience. *Liver Transpl* 2010;16(10):1207–1214
- 61 Brescia MD, Massarollo PC, Imakuma ES, Mies S. Prospective randomized trial comparing hepatic venous outflow and renal function after conventional versus piggyback liver transplantation. *PLoS One* 2015;10(06):e0129923
- 62 Choi JW, Jae HJ, Kim H-C, et al. Long-term outcome of endovascular intervention in hepatic venous outflow obstruction following pediatric liver transplantation. *Liver Transpl* 2015;21(09):1219–1226
- 63 Ye Q, Zeng C, Wang Y, et al. Risk factors for hepatic venous outflow obstruction in piggyback liver transplantation: the role of recipient's pattern of hepatic veins drainage into the inferior vena cava. *Ann Transplant* 2017;22:303–308
- 64 Khan S, Silva MA, Tan YM, et al. Conventional versus piggyback technique of caval implantation; without extra-corporeal veno-venous bypass. A comparative study. *Transpl Int* 2006;19(10):795–801
- 65 Ng SS, Yu SC, Lee JF, Lai PB, Lau WY. Hepatic venous outflow obstruction after piggyback liver transplantation by an unusual mechanism: report of a case. *World J Gastroenterol* 2006;12(33):5416–5418
- 66 Ito K, Akamatsu N, Togashi J, et al. Outflow reconstruction using cryopreserved homologous venous grafts in living donor liver transplantation. *Transplant Proc* 2017;49(01):109–114
- 67 Ko EY, Kim TK, Kim PN, Kim AY, Ha HK, Lee MG. Hepatic vein stenosis after living donor liver transplantation: evaluation with Doppler US. *Radiology* 2003;229(03):806–810
- 68 Chong WK, Beland JC, Weeks SM. Sonographic evaluation of venous obstruction in liver transplants. *AJR Am J Roentgenol* 2007;188(06):W515–21
- 69 Singh AK, Nachiappan AC, Verma HA, et al. Postoperative imaging in liver transplantation: what radiologists should know. *Radiographics* 2010;30(02):339–351
- 70 Huang TL, Chen TY, Tsang LL, et al. Hepatic venous stenosis in partial liver graft transplantation detected by color Doppler ultrasound before and after radiological interventional management. *Transplant Proc* 2004;36(08):2342–2343
- 71 Nghiem HV. Imaging of hepatic transplantation. *Radiol Clin North Am* 1998;36(02):429–443
- 72 Hwang HJ, Kim KW, Jeong WK, et al. Right hepatic vein stenosis at anastomosis in patients after living donor liver transplantation: optimal Doppler US venous pulsatility index and CT criteria—receiver operating characteristic analysis. *Radiology* 2009;253(02):543–551
- 73 Ito K, Siegelman ES, Stolpen AH, Mitchell DG. MR imaging of complications after liver transplantation. *AJR Am J Roentgenol* 2000;175(04):1145–1149
- 74 Darcy MD. Management of venous outflow complications after liver transplantation. *Tech Vasc Interv Radiol* 2007;10(03):240–245
- 75 Raby N, Karani J, Thomas S, O'Grady J, Williams R. Stenoses of vascular anastomoses after hepatic transplantation: treatment with balloon angioplasty. *AJR Am J Roentgenol* 1991;157(01):167–171

- 76 Ko GY, Sung KB, Yoon HK, et al. Endovascular treatment of hepatic venous outflow obstruction after living-donor liver transplantation. *J Vasc Interv Radiol* 2002;13(06):591-599
- 77 Yabuta M, Shibata T, Shibata T, et al. Long-term outcome of percutaneous interventions for hepatic venous outflow obstruction after pediatric living donor liver transplantation: experience from a single institute. *J Vasc Interv Radiol* 2013;24(11):1673-1681
- 78 Carnevale FC, Machado AT, Moreira AM, et al. Midterm and long-term results of percutaneous endovascular treatment of venous outflow obstruction after pediatric liver transplantation. *J Vasc Interv Radiol* 2008;19(10):1439-1448
- 79 Zajko AB, Sheng R, Bron K, Reyes J, Nour B, Tzakis A. Percutaneous transluminal angioplasty of venous anastomotic stenoses complicating liver transplantation: intermediate-term results. *J Vasc Interv Radiol* 1994;5(01):121-126
- 80 Rose BS, Van Aman ME, Simon DC, Sommer BG, Ferguson RM, Henry ML. Transluminal balloon angioplasty of infrahepatic caval anastomotic stenosis following liver transplantation: case report. *Cardiovasc Intervent Radiol* 1988;11(02):79-81
- 81 Pfammatter T, Williams DM, Lane KL, Campbell DA Jr, Cho KJ. Suprahepatic caval anastomotic stenosis complicating orthotopic liver transplantation: treatment with percutaneous transluminal angioplasty, Wallstent placement, or both. *AJR Am J Roentgenol* 1997;168(02):477-480
- 82 Lorenz JM, van Beek D, Funaki B, et al. Long-term outcomes of percutaneous venoplasty and Gianturco stent placement to treat obstruction of the inferior vena cava complicating liver transplantation. *Cardiovasc Intervent Radiol* 2014;37(01):114-124
- 83 Huber TJ, Hammer S, Loss M, et al. Primary stent angioplasty of the inferior vena cava after liver transplantation and liver resection. *Cardiovasc Intervent Radiol* 2014;37(04):949-957
- 84 Lee AY. Thrombosis in cancer: an update on prevention, treatment, and survival benefits of anticoagulants. *Hematology (Am Soc Hematol Educ Program)* 2010;2010(01):144-149
- 85 Parvinian A, Gaba RC. Sequential venoplasty for treatment of inferior vena cava stenosis following liver transplant. *J Clin Imaging Sci* 2014;4:50