Article published online: 2020-02-04

Periorbital Inner Canthal Arteriovenous Malformations: Percutaneous Glue Embolization in Three Cases

Krishnan Nagarajan[1] Arul A. S. Babu[1] Sekar Sabarish[1] Swamiappan Elango[1]
Krishna Ramesh Babu[2] Sunil Kumar Saxena[3]

[1]Department of Radio-Diagnosis, Jawaharlal Institute of Postgraduate Medical Education & Research (JIPMER), Pondicherry, India
[2]Department of Ophthalmology, Jawaharlal Institute of Postgraduate Medical Education & Research (JIPMER), Pondicherry, India
[3]Department of Otorhinolaryngology, Jawaharlal Institute of Postgraduate Medical Education & Research (JIPMER), Pondicherry, India

Address for correspondence Krishnan Nagarajan, MD, DM, Department of Radio-Diagnosis, Jawaharlal Institute of Postgraduate Medical Education & Research (JIPMER), Pondicherry 600506, India (e-mail: lknagarajan1@gmail.com).

J Clin Interv Radiol ISVIR 2020;4:55–59

Abstract

Inner canthal or palpebral arteriovenous malformations (AVMs) are uncommon and difficult lesions to treat if they are of high-flow type. Though they may present with mainly cosmetic reasons, they derive feeders from the ophthalmic artery and are associated with dangerous anastomoses. Percutaneous liquid embolic agent has been used to treat various head and neck vascular malformations and tumors and, if done in meticulous attention to detail, can offer cure or control before surgical excision. We report three adults who presented with medial canthal swelling and on imaging diagnosed to have high-flow AVMs. They underwent percutaneous n-butyl cyanoacrylate (glue) embolization and subsequently operated to excise the embolized malformation without any blood loss or complications.

Keywords
- inner canthal AVM
- arteriovenous malformations
- liquid embolic agents
- glue embolization

Introduction

Arteriovenous malformations (AVMs) are described as developmental hamartomas consisting of an abnormal nidus of dysplastic vascular channels with feeding arteries and draining veins and absence of normal intervening capillary network.[1] AVMs of the eyelid and canthus are uncommon with only few isolated case reports and small case series.[2-5] Endovascular treatment of these highly vascular lesions prior to surgical removal by selective embolization of the arterial feeders has been documented.[3] However, endovascular embolization in lid lesions is technically challenging, due to the complex nature of the arterial supply of the orbit and its adnexa with its rich anastomoses.[6] Percutaneous direct puncture of the nidus and venous pouch is a more efficient alternative to transarterial embolization in these superficial lesions. In this report, we describe our experience and outcomes in treating three cases of superficial periorbital inner canthal AVMs using percutaneous direct nidus puncture embolization.

Case 1

A 55-year-old female presented with rapidly increasing painful, pulsatile swelling over the medial canthus of the right eye for 3 months. The swelling was pulsatile with throbbing pain. Computed tomography (CT) angiogram revealed compact nidus of 3 × 2 cm size with prominent bilateral ophthalmic arteries, superior ophthalmic veins, and frontal scalp arteries and veins (►**Fig. 1A**, **B**). Digital subtraction angiography (DSA) revealed nidus at the medial canthus of right eye with feeders from bilateral ophthalmic artery of internal carotid arteries, external carotid (ECA) branches of facial (bilateral), and right internal maxillary arteries. The venous drainage was noted into bilateral angular, superior ophthalmic, and scalp veins (►**Fig. 1C**, **D**). In the same sitting, percutaneous embolization was attempted after placing table-side lead protection sheet for radiation during fluoroscopic roadmap injection of glue. The nidus close to dilated venous sac

Published online
February 04, 2020

DOI https://doi.org/10.1055/s-0039-3401328
ISSN 2457-0214.

©2020 by Indian Society of Vascular and Interventional Radiology

License terms

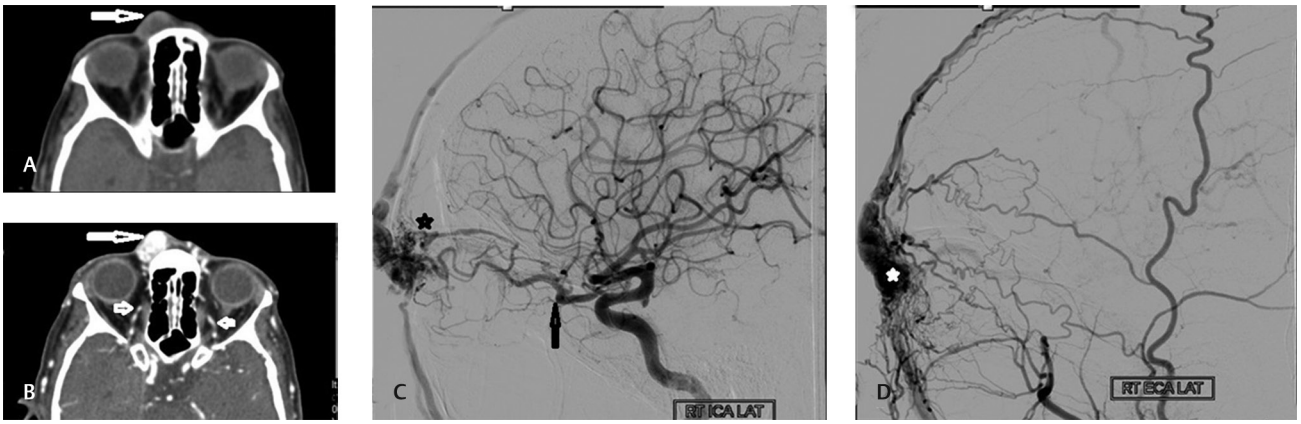

Fig. 1 Case 1. Plain (**A**) and contrast (**B**) computed tomography (CT) showing soft tissue density lesion (long arrows) in the right inner canthus with homogenous enhancement. Also noted are prominent bilateral ophthalmic arteries (short arrows in **B**). Left internal carotid artery (ICA) (**C**) and external carotid artery (ECA) (**D**) digital subtraction angiography (DSA) in lateral projections showing the arteriovenous nidus (*) fed by ophthalmic artery (arrow in **C**), ECA branches (facial, internal maxillary, and superficial temporal) with venous drainage into the bilateral angular veins, superior ophthalmic, and scalp veins.

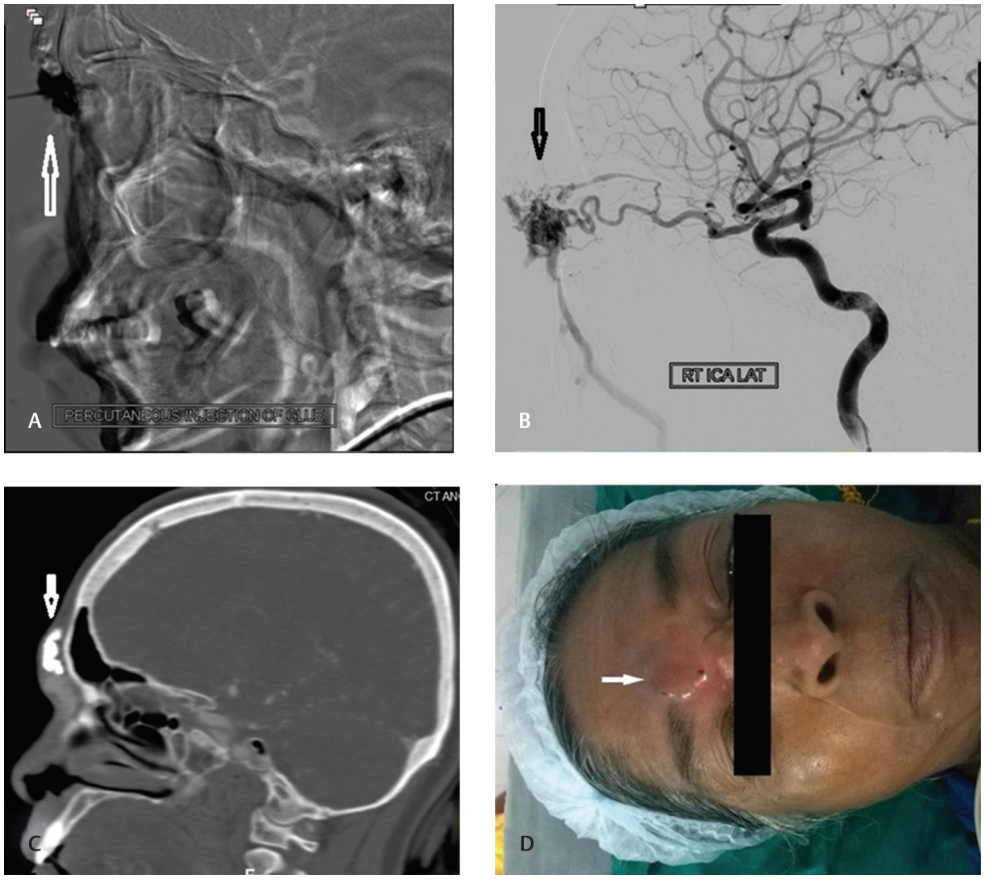

Fig. 2 Roadmap fluoroscopy image (lateral **A**) showing the needle (arrow) of percutaneous glue injection. Digital subtraction angiography (DSA) of the right internal carotid artery (ICA) (lateral **B**) showing residual nidus (arrow). Postembolization computed tomography (CT) (sagittal reformation **C**) showing glue cast (arrow). Clinical photograph (**D**) after embolization showing right supraorbital swelling with adjacent edema.

was punctured with a 20G scalp vein needle (►**Fig. 2A**). We used 20G to avoid glue clogging with a thinner gauge needle. Contrast agent was injected to confirm the position of the needle within the nidus and to look for any reflux into the arterial side. After direct confirmation of the anatomic details and dynamic status (drainage vein and flow), and flush with 5% dextrose to avoid interaction of glue and prior contrast injected, 50% solution of n-butyl

cyanoacrylate (n-BCA, Endocryl, Endotech, India) glue in lipiodol was injected under fluoroscopy roadmap till glue filled the major part of the nidus. After injection of glue, the needle was removed and check angiogram was done, which showed partial (60%) obliteration of the nidus with normal filling of bilateral ophthalmic arteries (►**Fig. 2B**). The patient had relief of pain and reduction in pulsatility. On 1-month follow-up, the swelling was static with glue cast in CT (►**Fig. 2C**). Second session of percutaneous glue injection was done 3 months later again using similar technique with 50% n-BCA glue. The firm swelling was excised in toto without blood loss. Histopathology showed thick-walled blood vessels with inflammatory infiltrate, occasional giant cells, and refractive foreign material due to glue.

Case 2

A 45-year-old female presented with gradually increasing, pulsatile swelling over the right inner canthus close to the nasal bridge. CT angiogram showed compact nidus of 1 cm size over the medial canthus of the right eye with prominent right ophthalmic artery and vein (►**Fig. 3A**, **B**). DSA showed small high-flow nidus fed by right ophthalmic artery, ECA branches of superficial temporal, internal maxillary, and facial arteries, and venous outflow into superior ophthalmic and angular veins (►**Fig. 3C**, **D**). Using the same technique as the previous patient, 50% solution of n-BCA (Endocryl) glue in lipiodol solution was injected into the nidus percutaneously. Postembolization angiogram showed complete obliteration of the AVM nidus with preserved ophthalmic artery. Plain CT done after 2 days showed the glue cast within the nidus (►**Fig. 3E**). The patient underwent surgical excision after 3 weeks.

Case 3

A 37-year-old male presented with a pulsatile swelling of 3 × 1 cm size over the inner aspect of the left upper eye lid for 6 years. Eye motility and ophthalmologic examination were normal. CT angiogram showed intensely enhancing nidus with prominent left ophthalmic artery and vein (►**Fig. 4A**, **B**). DSA revealed moderate-flow nidus in upper eyelid with feeders from the left ophthalmic artery, left superficial temporal, and internal maxillary branches of ECA and minimally from the right ophthalmic artery (►**Fig. 4C**, **D**). Venous drainage was into the superior ophthalmic, angular, and scalp veins. Though the flow was slightly slower than previous patients, similar percutaneous technique was used and 50% solution of n-BCA (Endocryl) glue in lipiodol was injected under direct fluoroscopy till the entire nidus filled. Postembolization angiogram showed near-complete obliteration of the AVM nidus (►**Fig. 4E**). CT done on the next day revealed glue cast with palpebral edema which resolved with topical and medical management (►**Fig. 4F**). There was a reduction in the swelling at 6 weeks' follow-up and it was excised. ►**Table 1** summarizes the clinical and angiographic findings of all three patients.

Discussion

Head and neck region is a common location for vascular anomalies and tumors of various types. Of these, simple sporadic type (type IV) AVMs as per the International Society for the Study of Vascular Anomalies classification (revised 2018),

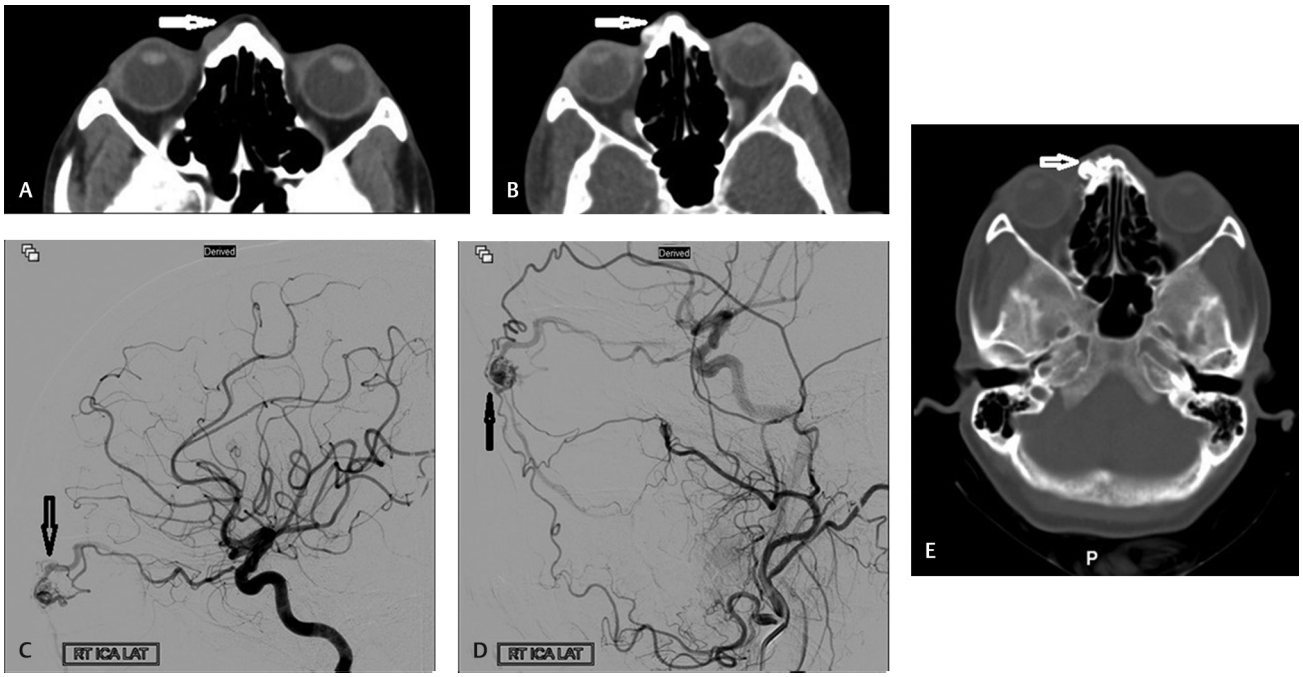

Fig. 3 Case 2. Plain (**A**) and contrast (**B**) computed tomography (CT) showing small soft tissue density lesion (arrows) along the right nasal bridge close to the inner canthus. Digital subtraction angiography (DSA) of the right internal carotid artery (ICA) (**C**) and external carotid artery (ECA) (**D**) in lateral projections showing small nidus (arrows) fed mainly by ophthalmic artery, facial, internal maxillary, and superficial temporal with venous drainage into the angular and superior ophthalmic veins. Postembolization CT axial section (**E**) showing glue cast (arrow) in the lesion.

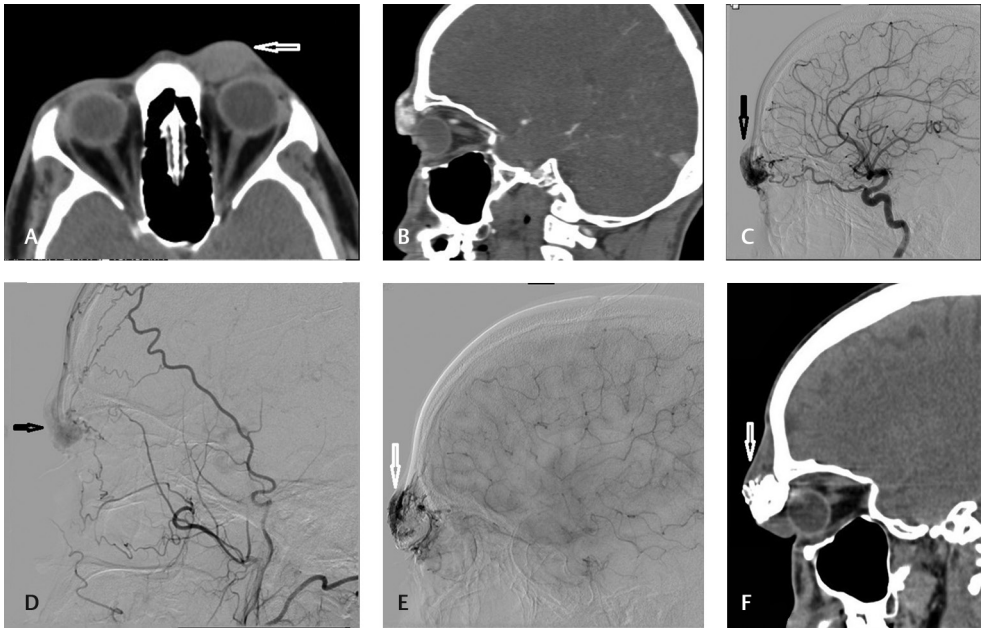

Fig. 4 Case 3. Plain (**A**) and contrast sagittal reformation (**B**) computed tomography (CT) showing soft tissue density lesion (arrow) in the left inner canthus and eyelid with intense enhancement. Digital subtraction angiography (DSA) of the left internal carotid artery (ICA) (**C**) and external carotid artery (ECA) (**D**) in lateral projections showing moderate-flow arteriovenous malformation (AVM) (arrow) fed by the left ophthalmic and superficial temporal artery with drainage into scalp veins. Postembolization DSA left ICA (lateral **E**) showing near-complete obliteration of the nidus (arrow). CT (**F**) done on the day after showing glue cast (*) with lid edema.

Table 1 Summary of clinical and angiographic findings

S. No.	Demography	Lesion location	Onset and Schobinger grade	Arterial feeders	Venous drainage	No. of embolization sessions	Result of embolization	Surgical excision
1	55/F	Right medial canthus and nasal bridge	Spontaneous II	Bilateral ophthalmic A., facial A., and internal maxillary A.	Bilateral superior ophthalmic vein & angular veins	2	Complete	Yes, excised in toto
2	45/F	Right medial canthus	Spontaneous I	Right ophthalmic A., superficial temporal A., facial A.	Right superior ophthalmic & angular vein	1	Complete	Yes, excised in toto
3	37/M	Left inner canthus & upper eyelid	Spontaneous II	Left ophthalmic A., superficial temporal A., internal maxillary A.	Left superior ophthalmic & angular vein	1	Near-complete	Yes, excised in toto

Abbreviation: A, artery.

are common type of high-flow malformations. These lesions are now more dealt in endovascular method of treatment in single sitting or staged procedure. Percutaneous direct puncture embolization is a simple and safe technique for the treatment of superficial AVMs in accessible locations compared with transarterial embolization.[6] It is sometimes difficult to gain distal access and perform superselective embolization of feeders particularly the ophthalmic artery.[7] Apart from the risk of incomplete embolization and retained microcatheter tip with transarterial embolization,[3] inadvertent embolization or reflux of embolic agent into the central retinal artery can lead to severe visual deficits.[8] Percutaneous approach to embolization of these lesions has proved to be equally efficacious and safe with immediate obliteration of vascularity and relief of symptoms.[6,9]

In their series of craniofacial AVMs, Han et al used percutaneous glue injection in 14 craniofacial AVMs including 9 lesions with feeders from ophthalmic artery and used venous compression during the percutaneous glue injection.[9] Phadke et al reported a case of medial canthal AVM treated

using percutaneous glue embolization and recommended the use of occlusion of feeding arteries to reduce the arterial inflow and manual compression to promote venous stasis.[2] Ou et al[6] described three (scalp: 2 and nasal bridge: 1) cases of AVMs fed by the ophthalmic artery in their series of four patients and achieved complete obliteration by percutaneous glue injection. Pekkola et al[10] described 19 craniofacial AVMs treated with ethanol sclerotherapy including a periorbital/nasal lesion which recurred after previous particle embolization and local resection. Su et al[4] described 16 cases of periorbital AVMs over a period of 4 years out of which 13 had ophthalmic artery feeders. They used absolute alcohol, either transarterial or percutaneously under general anesthesia, for embolization in 28 sittings. Decock et al described the occlusion of the draining vein by transvenous approach to prevent iatrogenic embolization of the superior ophthalmic vein and cavernous sinus.[11] In our cases, we did not use any occlusive technique. As the nidus was distally away from the central retinal branch of the ophthalmic artery, it was decided to stop injection if there is any reflux back into the distal ophthalmic artery. Adequate compression may not be anatomically achievable in the inner canthus for all lesions, and in fact, may even cause inadvertent changes in the flow dynamics within the nidus or draining veins. We did not encounter any reflux of embolic agent into the arterial side or incomplete embolization though it can happen if glue concentration is inappropriate for the flow characteristics of the malformation. High-flow AVMs at the inner canthal region pose a considerable treatment challenge, requiring interdisciplinary approach for its management for acceptable cosmetic and functional outcome.

Source of Support
None.

Conflict of Interest
None.

Acknowledgments
None.

References

1 Warrier S, Prabhakaran VC, Valenzuela A, Sullivan TJ, Davis G, Selva D. Orbital arteriovenous malformations. Arch Ophthalmol 2008;126(12):1669–1675
2 Phadke RV, Diwakar H, Mohan S, Parihar A, Singh T. Direct sac puncture and N-butyl cyanoacrylate embolization of medial canthal arteriovenous malformation supplied by the external carotid artery and the internal carotid artery branches. Australas Radiol 2006;50(4):389–391
3 Samaniego EA, Fisher M, Hasan D, et al. Embolization of palpebral and orbito-frontal fistulas: technical and anatomical considerations in treating high-flow superficial skin lesions with liquid embolics. J Neurointerv Surg 2018;10(3):240–244
4 Su LX, Jia R-B, Wang D-M, Lv MM, Fan XD. Absolute ethanol embolization of arteriovenous malformations in the periorbital region. Cardiovasc Intervent Radiol 2015;38(3):632–641
5 Mishra KR, Aggarwal S, Baranwal VK. A rare case of arteriovenous malformation of the upper eyelid. Arch Med Heal Sci 2015;3(2):288
6 Ou CH, Wong HF, Yang MS, Yang TH, Ho TL. Percutaneous direct puncture embolization for superficial craniofacial arteriovenous malformation. Interv Neuroradiol 2008;14(Suppl 2):19–22
7 Juszkat R, Żabicki B, Stanistawska K, et al. Eyelid arteriovenous malformation treated with pre-surgical embolization: a case report. Interv Neuroradiol 2018;24(3):327–330
8 Shaver J. Eyelid arteriovenous malformation treated with embolization leading to a branch retinal artery occlusion. Optometry 2011;82(12):744–750
9 Han MH, Seong SO, Kim HD. Chang K-H, Yeon KM, Han MC. Craniofacial arteriovenous malformation: preoperative embolization with direct puncture and injection of n-butyl cyanoacrylate. Radiology 1999;211(3):661–666
10 Pekkola J, Lappalainen K, Vuola P, Klockars T, Salminen P, Pitkäranta A. Head and neck arteriovenous malformations: results of ethanol sclerotherapy. AJNR Am J Neuroradiol 2013;34(1):198–204
11 Decock C, Stefaan R, Vandenbroecke C, Claerhout I, Defreyne L. Diagnosis and treatment of a superficial upper eyelid arteriovenous malformation. Orbit 2008;27(4):301–303