


# Radiographic Evaluation of the Consolidation of Humerus Surgical Neck Fractures Treated With Percutaneous Fixation\*

## *Avaliação radiográfica da consolidação das fraturas desviadas do colo cirúrgico do úmero tratadas com fixação percutânea*

Ivan Fadanelli Simionato<sup>1</sup>  João Pedro Farina Brunelli<sup>1</sup> Marco Tonding Ferreira<sup>1</sup>  
Fabio Yoshihiro Matsumoto<sup>1</sup> Almiro Gerszon Britto<sup>1</sup> Fernando Carlos Mothes<sup>1</sup>

<sup>1</sup>Shoulder and Elbow Surgery Group, Santa Casa de Misericórdia de Porto Alegre, RS, Brazil

Address for correspondence Ivan Fadanelli Simionato, MD, Rua Barão do Cotegipe 124/202, Bairro São João, Porto Alegre, 90540020, Brasil (e-mail: Simionato.md@gmail.com).

Rev Bras Ortop 2020;55(3):347–352.

### Abstract

**Objective** To evaluate radiographically the postoperative results of patients with fracture of the proximal humerus in two parts of the surgical neck treated with threaded percutaneous fixation.

**Methods** We evaluated the radiographic results of percutaneous fixation with threaded pins on the treatment of proximal humerus fractures in our service. Preoperative and postoperative images of 42 patients were evaluated, evaluating radiographs until 8 weeks postoperatively. We considered on evaluation the fracture deviation on preoperative images, the loss of reduction and no consolidation.

**Results** Our consolidation rate was 90.4%, with loss of reduction in 16.6% of the cases and no consolidation rates in just 4 operated cases. We observed a predominance of a specific fracture pattern in the cases with loss of reduction.

**Conclusion** The present study allows us to consider the percutaneous fixation technique with threaded pins as an alternative in our therapeutic arsenal for the proximal humerus fracture of the surgical neck. Contraindications are considered for low fracture trait on the metaphysis and with medial/lateral cortical impairment.

### Keywords

- ▶ humeral fractures
- ▶ humeral neck fractures/surgery
- ▶ fracture fixation internal
- ▶ radiography

### Resumo

**Objetivo** Avaliar radiograficamente os resultados pós-operatórios dos pacientes com fratura da extremidade proximal do úmero em duas partes do colo cirúrgico tratados com fixação percutânea com fios rosqueados.

**Métodos** Avaliamos radiograficamente os resultados da fixação percutânea com fios rosqueados das fraturas da extremidade proximal do úmero realizadas em nosso serviço. Foram avaliadas as imagens pré- e pós-operatórias de 42 pacientes, avaliando-

\* Study performed by the Shoulder and Elbow Surgery Group, Santa Casa de Misericórdia de Porto Alegre, Rio Grande do Sul, Brazil

**Palavras-chave**

- ▶ fraturas do úmero
- ▶ fraturas do colo umeral/cirurgia
- ▶ fixação interna de fraturas
- ▶ radiografia

se radiografias com até 8 semanas de pós-operatório. Consideramos na avaliação o desvio da fratura pré-operatório, a perda da redução e a consolidação da fratura.

**Resultados** O índice de consolidação nos casos avaliados foi de 90,4%, com perda da redução em 16,6% dos casos e não obtida a consolidação em apenas 4 casos. Foi observada uma predominância de determinado padrão de fratura nos casos que perderam a redução.

**Conclusão** O estudo permitiu considerar a técnica de fixação percutânea com fios rosqueados uma alternativa no arsenal terapêutico da fratura da extremidade proximal do úmero do colo cirúrgico, com contra-indicação para os traços de fratura baixos na metáfise e com acometimento da cortical medial/lateral.

## Introduction

Proximal humerus fractures are extremely common in orthopedic practice. Its incidence is expected to increase even more due to the longevity and higher activity level of the elderly population. According to Horak et al<sup>1</sup> they represent 5% of all fractures.<sup>1</sup> Conservative treatment of dislocated fractures does not result in good outcomes, and most cases are surgically treated.<sup>2,3</sup> Although common, these fractures are still considered a therapeutic challenge, with a wide range of fixation techniques, but still no clear evidence of superiority between them, especially when the wide variability of individual characteristics and of fracture patterns are considered.<sup>4</sup> Rigid implants, although widely used, may not be suitable for some patients, especially those with osteoporotic bones.<sup>2,4,5</sup> Arthroplasty surgeries have not been able to obtain better functional results compared with reconstructive surgeries, which are mostly reserved as salvage methods for synthesis failures.<sup>2,6,7</sup> This is reinforced by the concept of controlled impaction, well demonstrated by Resch et al<sup>7</sup> in different studies. In addition, some authors believe that the ideal implant would be a semi-rigid device that allows the bone compaction process and fracture remodeling during the healing process and concurrently offers stability to osteosynthesis.<sup>2,8-11</sup> Supported by the literature and based on these principles, we feel that the use of threaded pins, respecting concepts of controlled impaction/semi-rigid fixation, is an appropriate technique for proximal humeral fractures treatment.

The primary objective of the present study was to evaluate proximal humerus fractures consolidation by radiographic examination of patients submitted to percutaneous fixation with threaded pins. The secondary objective was to identify aspects predisposing to loss of reduction.


## Material and Methods

The present study evaluated retrospectively 46 patients with acute, proximal humeral fractures surgically treated with reduction and percutaneous 3.5-mm threaded pins fixation within 2 weeks from the day of trauma. Four patients who, although treated with this technique, presented three-part fractures not requiring an intervention at the greater tubercle after closed reduction, were excluded. As such, the sample

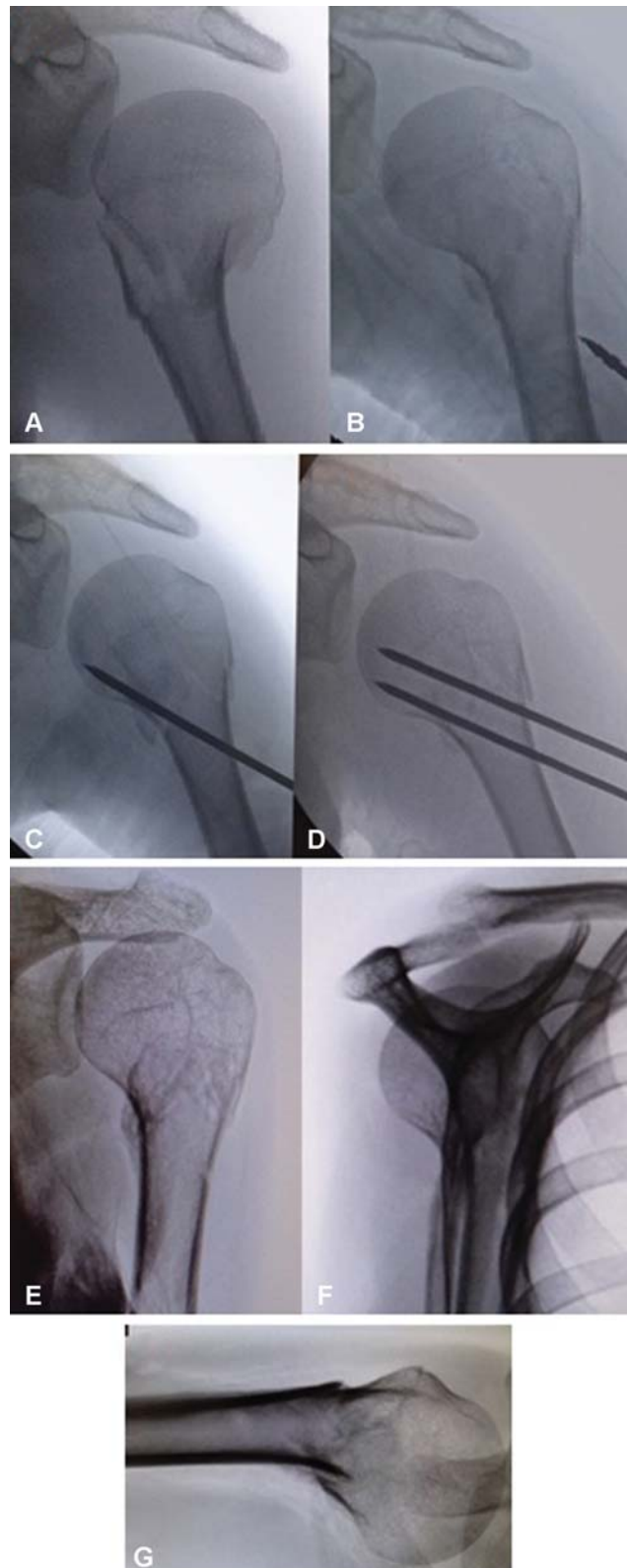
consisted of 42 patients. All of the patients were operated on by four senior surgeons from our service. The sample included 35 women and 7 men, who were followed-up for a minimum period of 2 months postoperatively. A total of 11 patients were from the public healthcare system, and 31 patients were from the private healthcare system. Threaded pins reduction and positioning were performed under intraoperative radiological visualization using an image intensifier. Maintenance of fracture reduction and lesion consolidation were evaluated at anteroposterior, scapular and Velpeau radiographic views at the 1<sup>st</sup>, 2<sup>nd</sup> and 4<sup>th</sup> weeks postoperatively. The Velpeau view is an alternative to the axillary view without sling removal; the patient is placed in 20° to 30° posterior inclination, with the trunk under the chassis, which is located inferiorly to the shoulder, and then the beam is positioned superiorly to the shoulder, perpendicularly to the horizontal plane (▶ **Figure 1**). Threaded pins were removed between the 4<sup>th</sup> and 5<sup>th</sup> weeks after the procedure. In addition, radiographs were taken on the 2<sup>nd</sup>, 4<sup>th</sup>, and 8<sup>th</sup> weeks after the removal of the wire (▶ **Figures 2-5**). The patients were immobilized with a Velpeau sling during the postoperative period until the removal of the pin. Passive shoulder movements were only allowed after the removal of the implants. Nonconsolidation was defined as cases requiring reintervention or evolving to pseudarthrosis within 4 to 5 weeks. Loss of reduction was defined as any surgical humeral neck deviation in postoperative radiographs performed up to the removal of the pin compared to intraoperative radiographs.

## Results

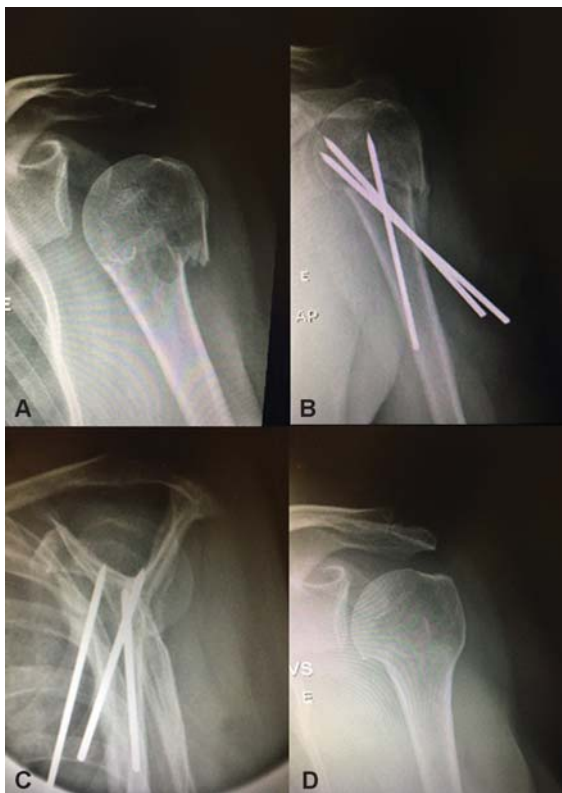The mean age of the 42 patients included in the study was 58.5 years old, whereas the median age was 63.5 years old (▶ **Table 1**). From the total of 42 patients, 38 presented fracture consolidation (90.4%) (▶ **Table 2**). In addition, reduction was sustained in 35 patients (83.3%) and lost in 7 patients (16.6%) (▶ **Table 3**). Among the 7 patients with loss of the surgically obtained reduction, only 3 presented no fracture consolidation (42.8%). All of the cases of loss of reduction presented the surgical neck medialization after pin fixation. The three patients with no consolidation were submitted to a reintervention with a locked proximal humerus plate (▶ **Figure 6**). One patient had loss of reduction



**Fig. 1** Velpeau radiographic view.

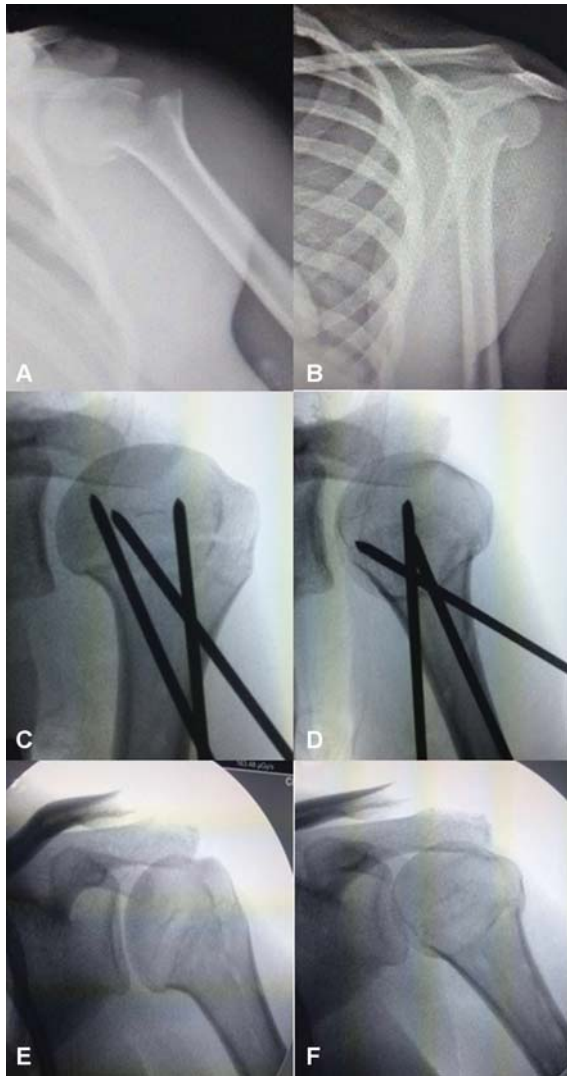


**Fig. 3** Preoperative radiograph (A); Intraoperative radiographs (B, C, D); Postoperative radiograph after 4 months (E, F, G).



**Fig. 2** Preoperative radiograph (A); Postoperative radiograph after 4 weeks (B, C); Postoperative radiograph after 2 months (D).

at the immediate postoperative period and he was submitted to a reintervention within 24 hours, consisting of open reduction and fixation with threaded pins; although evolving to consolidation, this subject was excluded from the good outcome group. Thus, 4 patients were included in the



**Fig. 4** Preoperative radiograph (A, B); Intraoperative radiographs (C, D); Postoperative radiograph after 4 months (E, F).

**Table 1** Age of the patients

Mean age (years old)	58.47619048
Median age (years old)	63.5
Range (years old)	15–85

**Table 2** Consolidation rate (percentage)

CONSOLIDATION		
YES	NO	TOTAL
38	4	42
0.904	0.095	1

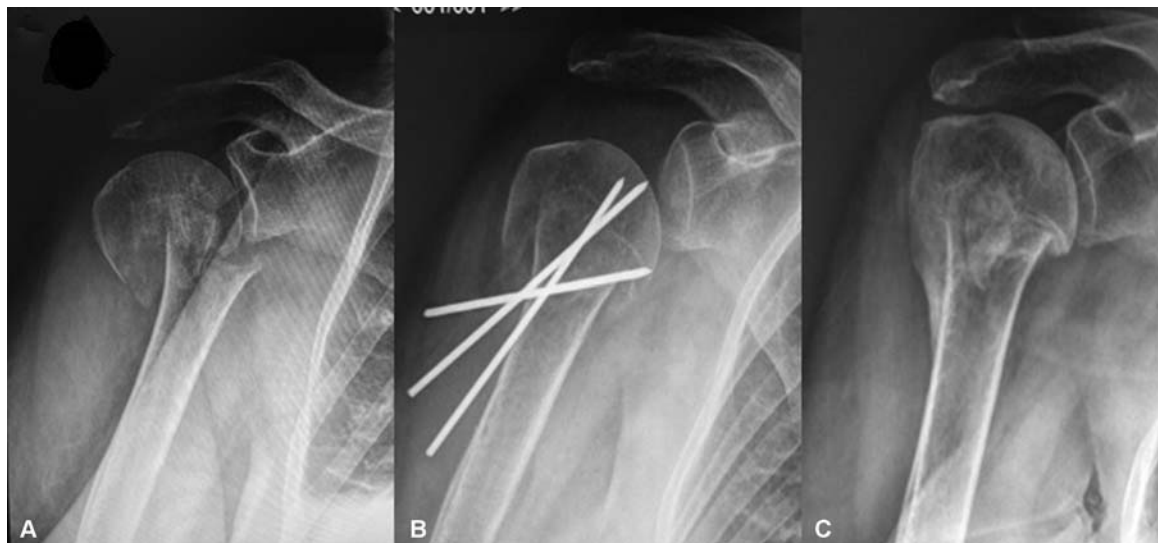**Table 3** Loss of reduction rate (percentage)

LOSS OF REDUCTION		
YES	NO	TOTAL
7	35	42
0.166667	0.833333333	1

nonconsolidation group (9.5%). The mean age of the patients with sustained reduction, loss of reduction and submitted to reintervention was 56.6 ( $\pm 17.6$ ), 66.7 ( $\pm 15.7$ ) and 73.6 ( $\pm 8.6$ ) years old, respectively. (→ **Table 4**). Cases with loss of reduction included a more distal fracture and some lesions with fragment comminution, in contrast to cases with sustained postoperative reduction.

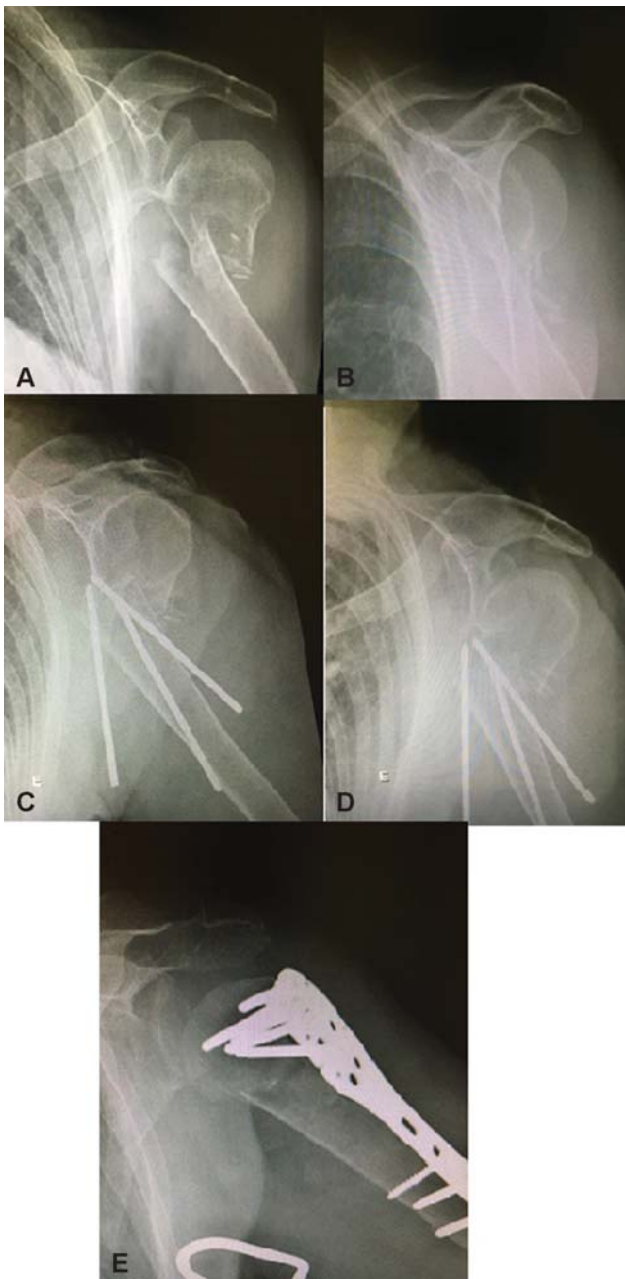
**Discussion**

The treatment of proximal humerus fractures is controversial. Several techniques are described, ranging from sling immobilization to arthroplasty replacement. Since different



**Fig. 5** Preoperative radiograph (A); Postoperative radiographs after 4 weeks (B); Postoperative radiograph after 3 months (C).





**Fig. 6** Preoperative radiograph (A, B); Postoperative radiographs after 2 weeks with loss of reduction (C, D); Postoperative radiograph 2 months after revision with locking plate (E).

therapeutic modalities in the same fracture pattern show similar radiographic and functional results, there is no gold standard. The current literature reports a considerably high complication rate related to rigid implants, such as loss of reduction, nonconsolidation and screws cut-out, which is fairly frequent in fixations with locked screw plate, either due to material mispositioning, fracture remodeling or late necrosis.<sup>10,12,13</sup>

The percutaneous fixation technique follows the principles of implant design advocated by Resch, that is, controlled impaction, peak force direction and semi-rigid implant.<sup>2</sup> We believe that humeral neck fixation with threaded pins allows some guided accommodation of the fracture focus, favoring consolidation. Resch and Hertel describe these two phenom-

**Table 4** Patients with loss of reduction

PATIENTS WITH LOSS OF REDUCTION			
DEVIATION	AGE	CONSOLIDATION	HEALTHCARE SYSTEM
Medial	84	Absent	PRIVATE
Valgus	62	Present	PRIVATE
Medial/Anterior/Varus	85	Present	PRIVATE
Medial/Anterior	74	Absent	PUBLIC
Medial/Anterior	63	Absent	PUBLIC
Medial/Varus	64	Present	PUBLIC
Varus	35	Present	PRIVATE

ena as *guide impaction* and *sintering effect*.<sup>2,7,9</sup> Since the pins are removed after consolidation, they can be placed in a subchondral position, where the humeral head bone is denser, improving fixation. Implant removal avoids the risk of late complications, such as proximal epiphyseal cut-out. Due to their lower morbidity, another advantage of percutaneous pins is the lower aggression to muscular and vascular tissues around the shoulder, resulting in less pain, shorter hospitalization, better cosmesis and, most importantly, lower damage to the fracture focus vascularization. Since the clavipectoral fascia is not opened, the fracture hematoma is maintained, which contributes to bone healing. This may be one of the reasons why we noticed a bone callus formation in most control radiographies taken at between 3 to 4 weeks, which is less common in open osteosynthesis with absolute stability.<sup>14-16</sup> Another advantage of percutaneous fixation with threaded pins is its lower cost compared to the fixation with plate and locked rods in humeral neck fractures.

In our service, percutaneous fixation with threaded pins has been shown as an alternative for the surgical treatment of proximal humeral neck fractures due to the favorable outcomes observed at the radiographic evaluation, with a 90.4% consolidation index, similar to the rates reported in the literature.<sup>17</sup> In patients < 60 years old, the fracture consolidation rate was 100%.

As a disadvantage, threaded pins are not as effective in providing stability for fracture fixation as locked plates. In cases with loss of reduction, a lower trace (towards the diaphysis) and a comminution of both the medial and lateral cortical necks were observed.<sup>9,10,18</sup> This finding is consistent with the notion that anatomical fracture reduction and medial cortical support reconfiguration are critical to consolidation.<sup>10</sup> The mean age of the patients with loss of reduction ( $66.71 \pm 15.7$  years old) and those submitted to reintervention using another method ( $71.2 \pm 8.5$  years old) were higher compared to the mean age from all patients ( $58.47 \pm 18.3$  years old) (► **Table 5**). This corroborates reports from the literature that older patients have more osteoporotic bones, making it harder to fix and maintain reduction regardless of the implant.

**Table 5** Mean age (years old) of patients with sustained reduction, loss of reduction or submitted to reintervention

Group	Mean age (years old)	Standard deviation
Sustained reduction	56.2	18.1
Loss of reduction	66.7	15.7
Reintervention	71.25	8.5

Compared to methods following the same fixation principles, such as the Humerusblock system (an implant that attaches a device to the humeral shaft to lock wires), the present study had a similar rate of reintervention and revision with locked plates.<sup>19</sup> Some complications related to the fixation method, including proximal or distal wire migration, can be observed when using threaded pins or the Humerusblock system; such complications require wire removal if the treatment is complete or, at least, retroceding the migrated wire.<sup>20</sup>

## Conclusion

Percutaneous fixation of deviated fractures of the humeral surgical neck with threaded pins may be considered in the treatment of this type of fracture, with consolidation (90.4%), complication and nonconsolidation rates (9.5%) similar to those observed with other fixation methods. Since advanced age, medial cortical loss, and metaphyseal extension were related to an increased loss of reduction and possibly to nonconsolidation, these factors should be taken into account when indicating this technique.

### Conflict of Interests

The authors have no conflict of interests to declare.

## References

- Horak J, Nilsson BE. Epidemiology of fracture of the upper end of the humerus. *Clin Orthop Relat Res.* 1975;112:250–253
- Resch H. Proximal humeral fractures: current controversies. *J Shoulder Elbow Surg* 2011;20(05):827–832
- Tepass A, Blumenstock G, Weise K, Rolaufts B, Bahrs C. Current strategies for the treatment of proximal humeral fractures: an analysis of a survey carried out at 348 hospitals in Germany, Austria, and Switzerland. *J Shoulder Elbow Surg* 2013;22(01):e8–e14
- Resch H, Tauber M, Neviasser RJ, et al. Classification of proximal humeral fractures based on a pathomorphologic analysis. *J Shoulder Elbow Surg* 2016;25(03):455–462
- Hertel R. Fractures of the proximal humerus in osteoporotic bone. *Osteoporos Int* 2005;16(Suppl 2):S65–S72
- Gupta AK, Harris JD, Erickson BJ, et al. Surgical management of complex proximal humerus fractures—a systematic review of 92 studies including 4500 patients. *J Orthop Trauma* 2015;29(01):54–59
- Resch H, Povacz P, Fröhlich R, Wambacher M. Percutaneous fixation of three- and four-part fractures of the proximal humerus. *J Bone Joint Surg Br* 1997;79(02):295–300
- Grubhofer F, Wieser K, Meyer DC, Catanzaro S, Schürholz K, Gerber C. Reverse total shoulder arthroplasty for failed open reduction and internal fixation of fractures of the proximal humerus. *J Shoulder Elbow Surg* 2017;26(01):92–100
- Hertel R, Hempfing A, Stiehler M, Leunig M. Predictors of humeral head ischemia after intracapsular fracture of the proximal humerus. *J Shoulder Elbow Surg* 2004;13(04):427–433
- Krappinger D, Bizzotto N, Riedmann S, Kammerlander C, Hengg C, Kralinger FS. Predicting failure after surgical fixation of proximal humerus fractures. *Injury* 2011;42(11):1283–1288
- Sukthankar AV, Leonello DT, Hertel RW, Ding GS, Sandow MJ. A comprehensive classification of proximal humeral fractures: HGLS system. *J Shoulder Elbow Surg* 2013;22(07):e1–e6
- Ortmaier R, Filzmaier V, Hitzl W, et al. Comparison between minimally invasive, percutaneous osteosynthesis and locking plate osteosynthesis in 3- and 4-part proximal humerus fractures. *BMC Musculoskelet Disord* 2015;16:297
- Südkamp N, Bayer J, Hepp P, et al. Open reduction and internal fixation of proximal humeral fractures with use of the locking proximal humerus plate. Results of a prospective, multicenter, observational study. *J Bone Joint Surg Am* 2009;91(06):1320–1328
- Jaura G, Sikdar J, Singh S. Long Term Results of PHILOS Plating and Percutaneous K-Wire Fixation in Proximal Humerus Fractures in The Elderly. *Malays Orthop J* 2014;8(01):4–7
- Matziolis D, Kaeae M, Zandi SS, Perka C, Greiner S. Surgical treatment of two-part fractures of the proximal humerus: comparison of fixed-angle plate osteosynthesis and Zifko nails. *Injury* 2010;41(10):1041–1046
- Seyhan M, Kocaoglu B, Nalbantoglu U, Aydin N, Guven O. Technique of Kirschner wire reduction and fixation of displaced two-part valgus angulated proximal humerus fractures at the surgical neck. *J Orthop Trauma* 2012;26(06):e46–e50
- Magovern B, Ramsey ML. Percutaneous fixation of proximal humerus fractures. *Orthop Clin North Am* 2008;39(04):405–416, v
- Carbone S, Moroder P, Arceri V, Postacchini R, Gumina S. The amount of humeral head impaction of proximal humeral fractures fixed with the Humerusblock device. *Int Orthop* 2014;38(07):1451–1459
- Moroder P, Tauber M, Carbone S, Auffarth A, Resch H. Modern minimally invasive treatment of proximal humeral fractures. *Tech Orthop* 2013;28:281–286
- Bogner R, Hübner C, Matis N, Auffarth A, Lederer S, Resch H. Minimally-invasive treatment of three- and four-part fractures of the proximal humerus in elderly patients. *J Bone Joint Surg Br* 2008;90(12):1602–1607