


# Cost and Value of Routine Histopathologic Analysis after Adenoidectomy and Tonsillectomy

Berit Hackenberg<sup>1</sup> Magdalena Pölzl<sup>1</sup> Christoph Matthias<sup>1</sup> Julian Künzel<sup>1</sup> 

<sup>1</sup>Department of Otolaryngology and Head and Neck Surgery, University Hospital Mainz, Mainz, Germany

Address for correspondence Julian Künzel, MD, Head and Neck Surgery, University Hospital of Regensburg, Franz-Josef-Strauß-Allee 11, 93053 Regensburg, Germany (e-mail: julian.kuenzel@ukr.de).

Int Arch Otorhinolaryngol 2020;24(4):e429–e433.

## Abstract

**Introduction** Tonsillectomy and adenoidectomy are common procedures. Most surgeries in children and young adults are recommended due to recurring infections or obstructive constraints. However, occult malignant findings are reported in the literature. The clinical guidelines still refrain from recommending routine histopathologic analyses when discussing these procedures.

**Objective** The present study aims to define the value of a routine histopathologic analysis after tonsillectomy, adenoidectomy and tonsillotomy.

**Methods** We conducted a prospective survey including all German ear, nose and throat (ENT) departments, asking physicians about their current clinical practice and opinion. Furthermore, we reviewed all patients attending our department for tonsillectomy/adenoidectomy/tonsillotomy or a combination of these procedures between 2011 and 2016. In addition to this, a cost analysis was conducted to assess the financial burden of a routine histopathologic analysis.

**Results** Most German ENT departments perform a routine histopathologic analysis after tonsillectomy/adenoidectomy/tonsillotomy. Despite this, only a minority deemed this approach necessary. Our retrospective review of the histopathologic analysis after tonsillectomy/adenoidectomy/tonsillotomy in our department rendered a cohort size of 2,157 patients. Within this group, there were no occult malignant findings. We found a yearly burden of 2,509,401€ for routine histopathologic analyses in patients under the age of 15 years in Germany in 2016.

**Conclusion** We found a divergence between the physicians opinions and their current clinical practice concerning the question of whether to conduct routine histopathologic analyses. Even though there was no occult malignant finding in our cohort, unsuspected malignant findings are reported in the literature. Therefore, we call for a discussion on clinical practice guidelines.

## Keywords

- ▶ tonsillectomy
- ▶ adenoidectomy
- ▶ pathology
- ▶ neoplasms

## Introduction

Tonsillectomy (TE) and adenoidectomy (AE) are two of the most common surgeries conducted on a daily basis in Germany.<sup>1</sup> There are many reasons to indicate these procedures. The tonsils and adenoids belong to the lymphoid tissue, and they are known as Waldeyer tonsillar ring. As the body's

first defense against antigens and pathogens entering the aerodigestive tract, they play a key role in the development of a competent immune system. Therefore, the diseases prone to attack this tissue start affecting the patients from an early age. In children, tonsillar hyperplasia can be a common cause of obstructive sleep apnea, difficulties in swallowing, and

received  
March 3, 2019  
accepted  
November 11, 2019

DOI <https://doi.org/10.1055/s-0039-3402493>.  
ISSN 1809-9777.

Copyright © 2020 by Thieme Revinter Publicações Ltda, Rio de Janeiro, Brazil

License terms



general growth retardation.<sup>2-5</sup> Moreover, adenoid hyperplasia can restrict middle ear ventilation and lead to effusions, conductive hearing loss, and, eventually, a delay in the child's speech development.<sup>6,7</sup> Furthermore, infectious diseases of the tonsils are common in all age groups, with a peak in incidence in early school ages and among young adults.<sup>8</sup> Acute tonsillitis can be caused by a variety of viruses and bacteria, and the bacterial form can lead to the formation of abscesses and require emergency surgery.

With increasing age, the tonsils, albeit decreasing in size and function, are prone to be the sight of oropharyngeal tumors. While squamous cell carcinomas are mostly restricted to older patients, malignant diseases of the lymphatic tissue can occur in all age groups.<sup>9</sup> When the clinical signs of malignancy are lacking, sometimes these tumors are diagnosed only through a thorough histopathologic investigation. Retrospective reviews regarding occult malignancies (defined as malignant findings in the histopathologic analysis without a clinical suspicion prior to surgery) after TE, AE and tonsillectomy (TT) present cohort sizes ranging from 61 to 15,120 patients.<sup>10,11</sup> In 1 study,<sup>12</sup> the rate of occult malignant findings was as high as 2.3%. Despite the frequency of TE and AE, the question of whether to examine the specimen histopathologically – especially in young patients and without suspicion of a malignant disease – seems to remain unclear, and is not discussed in the current clinical practice guidelines.<sup>8,13-15</sup>

The present article seeks to answer this question through a retrospective review of all tonsillectomies and adenoidectomies conducted in children and adults at the Department of Otolaryngology of a German university hospital in Mainz between 2011 and 2016 regarding the histopathological reports. In addition, a prospective survey was sent to all German ear, nose and throat (ENT) departments asking for their proceedings and opinion.

## Method

### Prospective Survey of ENT departments in Germany

A prospective survey was conducted including all German ENT departments. Names and addresses of all departments were provided by the German Society of Otorhinolaryngology and Head and Neck Surgery (Deutsche Gesellschaft für Hals-Nasen-Ohren-Heilkunde, Kopf- und Hals-Chirurgie e.V., Bonn, DGHNO-KHC).<sup>16</sup> A questionnaire developed by the authors was sent to all departments, and it contained five questions with many subitems.

The first three questions were on the ENT departments standard procedure concerning routine histopathologic analyses of the specimens after TE and TT in children or adults, and after AE in children. In the fourth item, the ENT doctors were asked about their opinion concerning routine histopathologic analyses of the specimens after AE in children and after TT or TE in children or adults. All items asked explicitly about surgeries with inconspicuous anamnesis and without clinical findings to focus on routine procedures. The questions were dichotomous, and could be answered with yes or no. A fifth item asked for individual comments and was

phrased as an open question. The original questionnaire is provided in the appendix.

### Retrospective Review of Histopathologic Reports in University Hospital Mainz

A retrospective review of histopathologic reports in the ENT department at University Hospital Mainz was completed by searching the department's electronic medical records (EMRs) for all AE, TT and TE procedures performed during January 2011 and November 2016. The search was based on Operation and Procedure Code (OPS) codes, a German procedure classification published by the German Institute of Medical Documentation and Information on behalf of the Federal Ministry of Health.<sup>17</sup> The EMRs were searched for the following procedure codes: AE (5-285.0, 5-282.X, and 5-282.0), TT (5-281.5, 5-985.X, and 5-985.1) and TE (5-281.0, 5-282.X, and 5-282.0). Procedures combined in one surgery (that is TT and AE) were reviewed separately. Revisional surgery of the adenoids was only included when combined with a TT or TE.

The following data were collected for each patient: patient ID, date of birth, age at intervention, date of surgery, surgical procedure, clinical findings, smoking status, diagnosis and histopathologic report. The inclusion criterion was one of the following diagnoses: adenoid hypertrophy, tonsillar hypertrophy, acute or chronic tonsillitis, mononucleosis, and elective surgery after peritonsillar abscess. Patients with clinical suspicion of malignancy who were consequently undergoing surgery as a diagnostic procedure (that is, diagnostic TE in patients with cancer of unknown primary origin [CUP] syndrome) were excluded from the study. Furthermore, patients with acute abscesses and adult patients undergoing AT were excluded. The study population was divided into children and adults using 18 years of age as a cut-off point. Combined surgery (that is, AE and TT) was counted severally since both tissue samples were sent in separately. The data collection and statistical evaluation were completed using the Microsoft Excel (Redmond, WA, US) and the International Business Machines (IBM) Statistical Package for the Social Sciences (SPSS, Armonk, NY, US) software.

The histopathologic analysis was conducted at the Institute of Pathology at University Hospital Mainz. The specimens submitted to analysis were first assessed macroscopically, including the measurement of the size and notation of the distinctive features. After that, lamellation was performed perpendicular to the mucosal surface, with a thickness of 5 mm for the tonsils, and of 3 mm to 4 mm for the adenoids. Then, paraffin embedding and microtome cutting were completed with a thickness of 2 µm to 4 µm. Most specimens were stained with hematoxylin and eosin.

## Results

### Prospective Survey of ENT departments in Germany

There are 162 ENT departments in Germany according to the DGHNO-KHC. Of these, 68 (42%) participated in the survey. Most departments do in fact perform routine histopathologic analyses for all three procedures. The rate of histopathologic analysis increased from AE over TT to TE. The departments

**Table 1** Questionnaire for German ENT departments, part 1

	Yes	No
1. Is there a routine histopathologic analysis of the specimen after <b>adenoidectomy</b> in children ( $\leq 18$ years) at your department?	37 (54%)	31 (46%)
2. Is there a routine histopathologic analysis of the specimen after <b>tonsillotomy</b> in children ( $\leq 18$ years) or adults without presurgical clinical suspicion at your department?		
2.a children:	45 (66%)	23 (34%)
2b. adults:	57 (84%)	9 (13%)
3. Is there a routine histopathologic analysis of the specimen after <b>tonsillectomy</b> in children ( $\leq 18$ years) or adults without presurgical clinical suspicion at your department?		
2a. children:	52 (76%)	16 (24%)
2b. adults:	64 (94%)	4 (6%)

were more likely to conduct histopathologic analyses for all three procedures when they treated adult patients. The full results are presented in **Table 1**.

When asked whether they considered routine histopathologic analysis in children undergoing AE or TT reasonable, a minority answered 'yes.' There was no consensus regarding TE patients – 50% of all participants deemed routine histopathologic analysis in children useful. In adult patients, the histopathologic analysis was evaluated as useful, especially after TE (87%) (**Table 2**).

The concluding open question of our survey was answered by 25 (37%) participants. In total, 3 participants (12%) viewed the histopathologic analysis as a question of legal or ethical nature, and 5 participants (20%) based their decision on presurgical clinical findings. For 7 participants (28%), age was a decisive factor when ordering a histopathologic report. It needs to be noted that there was no cut-off agreed upon.

**Table 2** Questionnaire for German ENT departments, part 2

	Yes	No	Missing
4. Do you deem routine histopathologic analyses for the following surgeries necessary?			
Adenoidectomy in children ( $\leq 18$ years)	19 (28%)	47 (69%)	2 (3%)
Tonsillotomy in children ( $\leq 18$ years)	25 (37%)	41 (60%)	2 (3%)
Tonsillectomy in children ( $\leq 18$ years)	34 (50%)	32 (47%)	2 (3%)
Tonsillotomy in adults	53 (78%)	11 (16%)	4 (6%)
Tonsillectomy in adults	59 (87%)	8 (12%)	1 (1%)

**Table 3** Patient demographics

	Male	Female
n	1,108	1,049
%	51	49
Age – mean (in years)	12.44	15.72
Age – median (in years)	4.92	14.59
Age – minimum (in months)	5	2
Age – maximum (in years)	71	77

The age in which a histopathologic analysis should be recommended to the patients ranged from 6 to 25 years.

**Retrospective Review of Histopathologic Reports at University Hospital Mainz**

The study sample was composed of 2,157 patients. Their ages ranged from 2 months to 77 years, with a peak at 3 to 4 years and at 25 years. There was no significant difference concerning gender. Patient demographics are presented in **Table 3**. Of these patients, 20 (1%) had malignancies in their past clinical history (lymphoma, leukemia, neuroblastoma, retinoblastoma, testicular cancer, breast cancer, and thyroid cancer). Altogether, 2,565 surgeries were conducted. The majority were ATs (1,207), followed by TEs (1,062) and TTs (296). Of these, 408 surgeries were combined procedures (AT and TE, or AT and TT) (**Fig. 1**).

Most tissue specimens (2,538; 99%) were processed histopathologically. No incidental findings of malignancy were observed in any of the cases. In five specimens, benign clinical findings (cyst or papilloma) were reported.

**Cost Analysis**

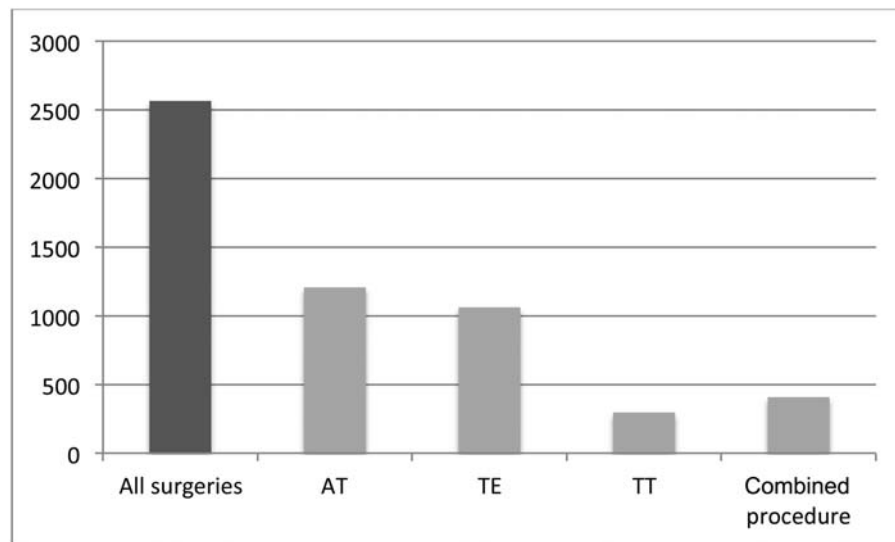
A cost analysis was conducted to assess the financial burden of routine histopathologic reviews after AE, TE and TT. Surgeries lacking a histopathological review were excluded from the calculation. All costs of the histopathological reports were assessed based on the German Medical Fee Index (Gebührenordnung für Ärzte, GOÄ).<sup>18</sup> Individual costs were multiplied by the number of procedures and presented as “cost per year.”

According to the GOÄ, the histopathologic analysis of adenoids and tonsils costs 29.50€ and 34.62€ respectively. Therefore, our study cohort caused a burden of 81,772.76€ (35,105€ for AE, 10,143.66€ for TT, and 36,524.10€ for TE). This leads to running expenses of ~ 13,820.75€ each year for histopathologic analyses after AE, TT or TE.

There were 34,247 AEs, 21,636 TEs and 11, 698 combined AE/TE procedures for patients under the age of 15 years in Germany in 2016.<sup>1</sup> This means a yearly burden of 2,509,401€ for routine histopathologic analyses after AE, TT and TE.

**Discussion**

The tonsillar and adenoid tissues play a central role in developing a competent immune system. Many diseases attack this region, and they affect patients in all age groups.



**Fig. 1** Surgeries conducted.

Even though AE, TT and TE are three of the most common procedures performed in German ENT departments, the question of whether to routinely conduct a histopathologic review remains unclear. This uncertainty is mirrored by the fact that current clinical practice guidelines refrain from discussing this question.

Therefore, the practicing ENT specialist is the one who decides whether or not to send a specimen for further histopathologic analysis. To shed some light on this issue regarding decision making, we conducted a prospective survey among German ENT departments asking for their current clinical practice and their opinion. Our survey showed that most ENT departments conduct routine histopathologic analyses, especially after TE and in adult patients. In opposite to this daily practice, not all physicians deemed it necessary in children. Most ENT departments conduct routine histopathologic analyses after ATs even though only a third of all participants deemed it necessary. This clear divergence might be attributable to the fact that clinical guidelines regarding this question are still lacking.

In our own retrospective review of histopathologic results after TE/AT/TT, there were no occult malignant findings in a cohort of 2,157 patients. This is in line with previous results published in the literature.<sup>19</sup> The result might entice one to discard routine histopathologic analyses, and this has been discussed in the literature before.<sup>35-37</sup> Most authors state the fear of overlooking a malignant finding as the most important reason to conduct a histopathologic analysis. Previous studies reported on rates of occult malignant findings ranging up to 2.3%, although most studies did not find unsuspected malignancies. Therefore, from a medical viewpoint, it seems necessary to base the decision regarding the routine histopathologic analysis on clinical suspicion. Beaty et al<sup>38</sup> defined criteria for suspicious clinical history and findings. Furthermore, it has been observed that the rate of occult malignant findings is higher in adult patients. Hence, routine histopathologic analyses might not seem necessary in young patients without clinical suspicion of malignancy.

Furthermore, we could show that the routine histopathologic analysis is in fact a noticeable financial burden to any health system. In medicine, resources are scarce. Advances in diagnostic procedures and treatment strategies force the practicing physician to choose what is best for the patient, but also what is bearable for the healthcare system. Although the cost of a single histopathologic analysis seems small, as aforementioned, the sum of all routine examinations does in fact yield a noticeable financial burden to the healthcare system.

Despite these considerations, it needs to be noted that the practicing physicians do not only carry a medical responsibility for their patients, but also an ethical and a legal one. The mere fact that there can indeed be occult malignant findings in the lymphatic tissues of the tonsils and adenoids, albeit occurring with a very small rate, might oblige the physician to always perform a histopathologic analysis, even in the absence of clinical suspicion.

These factors are certainly important for the reflection on this topic, but lie beyond the scope of the present paper, and will therefore not be further discussed.

## Conclusion

We found a divergence between the physicians opinions and their current clinical practice concerning the question of whether to conduct a routine histopathologic analysis. Especially in children, a routine histopathologic analysis after AE is regularly conducted but not deemed necessary. This practice does in fact cause a noticeable financial burden to the healthcare system.

Therefore, we call for a discussion on clinical practice guidelines. The question of whether to conduct a routine histopathologic analysis needs to be discussed further and eventually included in the clinical practice guidelines.

## Conflict of Interests and funding

The study was presented at the 89th DGHNO Annual Meeting, held on May 9th–12<sup>th</sup>, 2018 in Lübeck, Germany.

This work contains essential parts of the doctoral thesis of Magdalena Pözl.

## References

- Statistisches Bundesamt. Die 20 häufigsten operationen bei kindern. <https://www.destatis.de/DE/ZahlenFakten/GesellschaftStaat/Gesundheit/Krankenhaeuser/Tabellen/DRGOperationenKinder.html>. Updated 2018. Accessed 09/05, 2018.
- Bar A, Tarasiuk A, Segev Y, Phillip M, Tal A. The effect of adenotonsillectomy on serum insulin-like growth factor-I and growth in children with obstructive sleep apnea syndrome. *J Pediatr* 1999;135(01):76–80
- Hodges S, Wailoo MP. Tonsillar enlargement and failure to thrive. *Br Med J (Clin Res Ed)* 1987;295(6597):541–542
- Schiffmann R, Faber J, Eidelman AI. Obstructive hypertrophic adenoids and tonsils as a cause of infantile failure to thrive: reversed by tonsillectomy and adenoidectomy. *Int J Pediatr Otorhinolaryngol* 1985;9(02):183–187
- Richards W, Ferdman RM. Prolonged morbidity due to delays in the diagnosis and treatment of obstructive sleep apnea in children. *Clin Pediatr (Phila)* 2000;39(02):103–108
- Schönweiler R. [Examination of 1,300 children for incidence and therapy of hearing disorders in pediatric speech disorders]. *Laryngorhinotologie* 1992;71(12):637–643
- Upadhyia I, Datar J. Treatment options in otitis media with effusion. *Indian J Otolaryngol Head Neck Surg* 2014;66(Suppl 1):191–197
- AWMF. Therapie entzündlicher erkrankungen der gaumenmandeln - tonsillitis. [http://www.awmf.org/uploads/tx\\_szleitlinien/017-024I\\_S2k\\_Tonsillitis\\_Gaumenmandeln\\_2015-08\\_01.pdf](http://www.awmf.org/uploads/tx_szleitlinien/017-024I_S2k_Tonsillitis_Gaumenmandeln_2015-08_01.pdf). Updated 2015. Accessed 05/09, 2018
- Smith A, Crouch S, Lax S, et al. Lymphoma incidence, survival and prevalence 2004–2014: sub-type analyses from the UK's Haematological Malignancy Research Network. *Br J Cancer* 2015;112(09):1575–1584
- Adoga AS, Ma An DN, Nuhu SI. Is routine histopathology of tonsil specimen necessary? *Afr J Paediatr Surg* 2011;8(03):283–285
- Daneshbod K, Bhutta RA, Sodagar R. Pathology of tonsils and adenoids: a study of 15,120 cases. *Ear Nose Throat J* 1980;59(11):466–467
- Oluwasanmi AF, Wood SJ, Baldwin DL, Sipaul F. Malignancy in asymmetrical but otherwise normal palatine tonsils. *Ear Nose Throat J* 2006;85(10):661–663
- Mitchell RB, Archer SM, Ishman SL, et al. Clinical practice guideline: Tonsillectomy in children (update). *Otolaryngol Head Neck Surg* 2019;160(02):187–205
- Royal College of Surgeons. Commissioning guide: Tonsillectomy. [https://www.google.de/url?sa=t&rc=j&q=&esrc=s&source=web&cd=1&ved=2ahUKewiNgunvjvunhAhVGC-wKHaziDIIQFjAAegQIBhAC&url=https%3A%2F%2Fwww.rcseng.ac.uk%2F-%2Fmedia%2Ffiles%2Frcs%2Fstandards-and-research%2Fcommissioning%2Fent-uk-tonsillectomy-revised-commissioning-guide-2016-published.pdf&usq=AOvVaw3TEv6Oxh\\_U3MkoWAcXz81m](https://www.google.de/url?sa=t&rc=j&q=&esrc=s&source=web&cd=1&ved=2ahUKewiNgunvjvunhAhVGC-wKHaziDIIQFjAAegQIBhAC&url=https%3A%2F%2Fwww.rcseng.ac.uk%2F-%2Fmedia%2Ffiles%2Frcs%2Fstandards-and-research%2Fcommissioning%2Fent-uk-tonsillectomy-revised-commissioning-guide-2016-published.pdf&usq=AOvVaw3TEv6Oxh_U3MkoWAcXz81m). Updated 2016. Accessed 04/2019, 2019
- Scottish Intercollegiate Guidelines Network. Management of sore throat and indications for tonsillectomy - A national clinical guideline. <https://www.sign.ac.uk/assets/sign117.pdf>. Updated 2010. Accessed 04/2019, 2019
- DGHNO. Deutsche gesellschaft für hals-nasen-ohren heilkunde, kopf-hals-chirurgie e.V., Bonn. 2018
- Bundeministerium für Gesundheit. DIMDI - deutsches institut für medizinische dokumentation und information. <https://www.dimdi.de/static/de/index.html>. Updated 2018. Accessed 21.05.2018, 2018
- Gutermann Publisher Ltd. GOÄ gebührenordnung für ärzte. <http://www.e-bis.de/goae/defaultFrame.htm>. Updated 2011. Accessed 21.05.2018, 2018
- Aydin A, Erkiç S, Bayazit YA, Koçer NE, Ozer E, Kanlikama M. Relation between actinomycosis and histopathological and clinical features of the palatine tonsils: a comparative study between adult and pediatric patients. *Rev Laryngol Otol Rhinol (Bord)* 2005;126(02):95–98
- Bast F, Uecker K, Chadha P, Göbel D, Schrom T. Is there a need for a histological examination of the adenoid tissue after adenoidectomy? *Int J Pediatr Otorhinolaryngol* 2015;79(06):821–824
- Bizzell JG, Richter GT, Bower CM, Woods GL, Nolder AR. Routine pathologic examination of tonsillectomy specimens: A 10-year experience at a tertiary care children's hospital. *Int J Pediatr Otorhinolaryngol* 2017;102:86–89
- Cinar F. Significance of asymptomatic tonsil asymmetry. *Otolaryngol Head Neck Surg* 2004;131(01):101–103
- Dost P. [Histological examination following adenoidectomy and tonsillectomy in children. Surprising results are very rare]. *HNO* 2006;54(01):16–19
- Erdag TK, Ecevit MC, Guneri EA, Dogan E, Ikiz AO, Sutay S. Pathologic evaluation of routine tonsillectomy and adenoidectomy specimens in the pediatric population: is it really necessary? *Int J Pediatr Otorhinolaryngol* 2005;69(10):1321–1325
- Erkiç S, Aydin A, Koçer NE. Histological features in routine tonsillectomy specimens: the presence and the proportion of mesenchymal tissues and seromucinous glands. *J Laryngol Otol* 2002;116(11):911–913
- Hajioannou J, Tsiouva S, Exarchos S, et al. Histopathologic examination of routine tonsillectomies in times of Greek austerity. Necessity or luxury? A retrospective study of 823 patients. *Clin Otolaryngol* 2014;39(04):235–237
- Harley EH. Asymmetric tonsil size in children. *Arch Otolaryngol Head Neck Surg* 2002;128(07):767–769
- Kalcioglu MT, Gurses I, Erdem T. Is the pathological examination of routine tonsillectomy and adenoidectomy specimens necessary? A retrospective study of 559 adenoidectomy and 1132 tonsillectomy specimens and a literature review. *B-ENT* 2010;6(02):91–95
- Nelson ME, Gernon TJ, Taylor JC, McHugh JB, Thorne MC. Pathologic evaluation of routine pediatric tonsillectomy specimens: analysis of cost-effectiveness. *Otolaryngol Head Neck Surg* 2011;144(05):778–783
- Rebecchi G, Pontes TE, Braga EL, Matos WM, Rebecchi F, Matsuyama C. Are histologic studies of adenotonsillectomy really necessary? *Int Arch Otorhinolaryngol* 2013;17(04):387–389
- Reiter ER, Randolph GW, Pilch BZ. Microscopic detection of occult malignancy in the adult tonsil. *Otolaryngol Head Neck Surg* 1999;120(02):190–194
- Strong EB, Rubinstein B, Senders CW. Pathologic analysis of routine tonsillectomy and adenoidectomy specimens. *Otolaryngol Head Neck Surg* 2001;125(05):473–477
- Verma SP, Stoddard T, Gonzalez-Gomez I, Koempel JA. Histologic analysis of pediatric tonsil and adenoid specimens: is it really necessary? *Int J Pediatr Otorhinolaryngol* 2009;73(04):547–550
- Yasan H, Doğru H, Candir O, Tüj M, Bircan S. Incidence of unexpected pathology in routine adenoidectomy specimens. *Int J Pediatr Otorhinolaryngol* 2006;70(01):95–98
- Dohar JE, Bonilla JA. Processing of adenoid and tonsil specimens in children: a national survey of standard practices and a five-year review of the experience at the Children's Hospital of Pittsburgh. *Otolaryngol Head Neck Surg* 1996;115(01):94–97
- Garavello W, Romagnoli M, Sordo L, Spreafico R, Gaini RM. Incidence of unexpected malignancies in routine tonsillectomy specimens in children. *Laryngoscope* 2004;114(06):1103–1105
- Williams MD, Brown HM. The adequacy of gross pathological examination of routine tonsils and adenoids in patients 21 years old and younger. *Hum Pathol* 2003;34(10):1053–1057
- Beatty MM, Funk GF, Karnell LH, et al. Risk factors for malignancy in adult tonsils. *Head Neck* 1998;20(05):399–403