Septal Deviation after Septorhinoplasty: Causes and Surgical Management

Neil N. Luu, BA[1] Oren Friedman, MD[2]

[1] Department of Otorhinolaryngology, Perelman School of Medicine, University of Pennsylvania, Philadelphia, Pennsylvania
[2] Department of Otorhinolaryngology - Head and Neck Surgery, Perelman School of Medicine, University of Pennsylvania, Philadelphia, Pennsylvania

Address for correspondence Oren Friedman, MD, Department of Otorhinolaryngology - Head and Neck Surgery, Perelman School of Medicine, University of Pennsylvania, 3400 Civic Center Boulevard, Philadelphia, PA 19104 (e-mail: orenfriedman@hotmail.com).

Facial Plast Surg 2020;36:72–77.

Abstract

Revision rhinoplasty exists because the perfect primary rhinoplasty technique does not. The benefit of revision surgery is that it offers us the opportunity to study and identify what did not work well during previous surgery. Thoughtful approaches to technique and outcomes allow us to recognize which maneuvers are dependable and worth repeating, and which are not reliable and therefore worth avoiding. As surgeons seek safer, more predictable results to improve patient outcomes, new techniques emerge which we then apply, study, and modify again, based on what works and what does not over the short term and the long term. There is no substitute for experience or for learning from trusted surgeons' experiences. Revision rhinoplasty presents many challenges including surgically induced anatomical changes, weakened structural support, a lack of available tissue for reconstruction, tissue remodeling responses, and other iatrogenic and wound healing complications. The septum, as the primary source of structural nasal integrity, forms the foundation for functional and aesthetic rhinoplasty. Herein, we describe strategies in septorhinoplasty for patients who have undergone prior nasal septal surgery.

Keywords
- revision rhinoplasty
- septoplasty
- nasal septum
- nasoseptal reconstruction

The nose serves extremely important functions that make it an essential organ for life and life quality. It warms, humidifies, and cleans the air that passes into the respiratory system to allow for proper gas exchange in the lung, and it enhances our sense of taste and food perception and protects us from noxious stimuli through the olfaction sense. To perform these important functions, the anatomy of the nose is intricately developed and physiologically complex. As we beautify the shape of the nose through alterations to the nasal tip, reduction of protuberances along the nasal dorsum, or straightening a crooked nose, we also pay close attention to improving nasal functions through repairing the nasal valve and septal deformities.[1,2] Regardless of whether a rhinoplasty is performed for functional, cosmetic, or dual reasons, revision surgery rates are reported with frequencies as high as 15% of cases.[3–5] The septum plays a central role in revision rhinoplasty, and is a most common cause of nasal obstruction and deformity in previously operated noses.

Common Causes of Revision Rhinoplasty

Establishing realistic expectations for patients prior to surgery is perhaps the single most important step we could take to minimize the need for revision nasal surgery. As such, it is important to understand the factors that bring patients in for revision surgery. Constantian described the motivations for secondary rhinoplasty in a study involving 150 patients in a prominent, busy New England practice. He found that the two most common reasons were the introduction of a new deformity (41%) or a failure to correct an original deformity (33%).[6] Other reasons included the "perceived loss of personal, familial, or ethnic characteristics" (15%), desire to improve

Issue Theme Challenges in Rhinoplasty; Guest Editor: Robin Lindsay, MD

DOI https://doi.org/10.1055/s-0040-1701642.
ISSN 0736-6825.

upon an already acceptable result (10%), and new/unrelieved airway obstruction (1%). Often in revision rhinoplasty, there are numerous aesthetic deformities involving different regions of the nose. Adamson found that 50% of patients had one single deformity, 30% had two deformities, and 20% had three or more deformities leading to revision rhinoplasty,[7] while Vuyk et al found 80% of patients coming for revision rhinoplasty had two or more deformities.[8] Our personal experience that the most common causes of nasal airway obstruction following rhinoplasty include septal deviation and nasal valve dysfunction are confirmed by Goudakos et al who identified these findings in more than 90% of cases.[9]

Nasal airway obstruction is recognized as a most common cause for revision rhinoplasty. In a prospective observational outcomes study conducted at a tertiary care medical center in Boston, 40 patients with a history of failed septoplasty were evaluated for revision surgery.[10] Findings from preoperative nasal examination demonstrated moderate or severe internal nasal valve narrowing in 38 (95%) patients, internal nasal valve collapse in 19 (48%), external nasal valve narrowing in 18 (45%), or external nasal valve collapse in 16 (40%). The most common anatomical cause of obstruction was internal nasal valve narrowing in 38 (95%) patients, dorsal septum deflection in 26 (65%), and narrowed middle vault in 16 (40%). Other than nasal valve collapse and persistent septal deviation after primary surgery, inferior turbinate hypertrophy was also found to contribute to persistent nasal airway obstruction.[11,12] Nasal valve collapse may involve the internal valve, the external valve, or both, and numerous treatments exist for every clinical situation, allowing us to manage both form and function effectively.[13–16]

The Nasal Septum

The nasal septum is the primary source of structural nasal integrity, and as such it forms both the aesthetic and functional foundation of the nose. A thorough understanding of its anatomy is critical for the surgeon. During embryological development, the nasal septum forms as a downward growth from the nasofrontal prominence and fuses with the palatal shelves to divide the nasal cavity into two separate chambers.[17] The septum is composed of both bony and cartilaginous components. The bony components include the maxillary crest, the perpendicular plate of the ethmoid bone, and the vomer, while the cartilaginous component is composed of the quadrangular cartilage (QC) which varies in thickness from one patient to another, and in different regions of the septum compared with others (QC).[18] The attachment of the QC to the bony septum and nasal bones is named the "keystone area" and acts as a major support mechanism of the septum and must be maintained for dorsal and tip support. The fibrous attachments between the ventral surface of the cartilaginous septum and the bony maxillary crest add important structural support for the nose. There are several additional support structures for the septum[19]—the paired upper lateral cartilages, attached to the cartilaginous septum dorsally and together, form the boundaries of the internal nasal valve—this region is often implicated in nasal obstruction requiring revision surgery. The paired lower lateral cartilages, attached to the septum via the membranous septum soft tissue attachments to the medial cruri, act to support the nasal tip. Finally, the paired inferior turbinates are outgrowths that regulate nasal airflow and when hypertrophied, can lead to nasal obstruction.

Principles of Septal Surgery

Outstanding breathing and aesthetic surgical results may only be obtained with proper management of the septum. Abnormalities of the septum are often the root cause of saddle nose, pollybeak, dorsal deviation, crooked nose, foreshortened nose, retracted or hanging columella, tip ptosis, and other aesthetic deformities. A long-standing dogma dictates that when performing septoplasty, we leave at least a 10- to 15-mm wide segment of caudal and dorsal septal cartilage intact to maintain adequate long-term septal support.[20] Recent studies have also looked at the thickness of the septum in these caudal and dorsal regions and found that the thickness of the L-strut may even be more important than the width of the L-strut remnant.[21–23] It may be safe to leave less than a 10-mm wide dorsal strut if spreader grafts are used to thicken the septum in the dorsal segment. Similarly, applying caudal septal battening grafts which thicken the septum may provide the structural support necessary to maintain the shape of the nose even when there is less than a 10-mm caudal strut.

Metzenbaum described the swinging door technique for mobilization, repositioning, and then fixation to the midline of deviated caudal septal deformities.[24] Numerous methods for suturing the septum to the maxillary crest and nasal spine have been described,[15,25] as well as scoring techniques to help straighten concavities in the septal cartilage.[16] Metzinger et al described a technique of applying perpendicular plate of ethmoid bone, and Dyer offered an alternative plating technique to maintain the caudal end of the septum in the midline.[26–28] Kridel et al described the "tongue-in-groove" technique for the management of the caudal septum, finding that by securing the caudal septum between the medial crura, the caudal septum is held in place in the midline.[29] Placing the caudal septum between the medial crura has also been shown to provide outstanding tip support.[30] The concept of attaching the caudal septum to the medial crura for excellent long-term tip support serves as the foundation for modern structural rhinoplasty techniques that apply caudal septal extension grafts to stabilize and secure the nasal tip by overlapping the medial crura and the new caudal septal extension graft construct.[31] More severe septal deviations require more complex reconstructive efforts to achieve proper airway and cosmesis. When the deviations are located in the dorsal or caudal portions of the septum, the challenges become particularly difficult as these are the areas of the septum that directly affect the shape of the nose, and surgical weakening of these support structure risks creating nasal deformity. At the same time, neglecting to straighten these areas risks persistent nasal obstruction, crooked nose, tip ptosis, and other potential deformities. Leaving an overly weakened L-strut during nasal

surgery runs the risk of postoperative contractile forces causing long-term twists of the septum, airway obstruction, and nasal deformities. In such cases, Rees reported good outcomes with the removal of the osseocartilaginous septum and replacing it as a free graft to re-establish a straight and functional nose.[32] Toriumi and Gubisch described their experiences with complex techniques whereby the majority of the bony and cartilaginous nasal septum is removed, restructured on the back table, and then reinserted into the septal space to provide for a straight septum.[33,34] When there are deviations of the cartilaginous septum in the dorsal and caudal segments that cannot be straightened with sutures, cross-hatching, or splinting techniques, these extracorporeal subtotal septal reconstructions may help ensure a straight, well-supported septum and nose with good long-term outcomes. In such situations, the caudal replacement graft is secured into a notch created in the nasal spine and extended spreader grafts secure the dorsal aspect of the caudal septal replacement to either a segment of septal cartilage that remains attached to the bony septum at the keystone area, or to the nasal bones themselves through a drill hole if there is no remaining cartilage attached to the perpendicular plate of the ethmoid at the keystone region. In revision rhinoplasty, much of the septal cartilage has already been removed in the primary surgeon's attempt to improve the airway through standard septoplasty techniques. Maximizing the use of any remaining bone and cartilage is a first priority in such circumstances, but this still often leaves the surgeon with inadequate material for nasoseptal reconstruction. In such circumstances, rib graft or ear cartilage may be used to recreate the central support of the nose, the L-strut.[33–35] Extreme procedures such as recreation of the L-strut through extracorporeal septoplasty, or reconstruction of the L-strut with rib or ear cartilage grafts still carry quite a significant risk and have a very steep learning curve. More simple techniques have been described to help simplify the creation of a straight and strong L-strut such as the anterior septal reconstruction.[36]

A Few Surgical Pearls for Rhinoplasty following Previous Septal Surgery

When septoplasty has previously been performed well, and a straight L-strut with adequate 15 mm of caudal and dorsal L-strut segments has been left, contractile forces associated with the wound healing process may still cause a buckling of the septal cartilage remnant, in particular at the junction of the caudal and dorsal components of the L-strut. In such circumstances, several techniques may be used to help straighten the residual septum, and each may be achieved through either the external or the endonasal approach. These strategies may be employed through a minimalist approach and in that way, we may preserve the native nasal support mechanisms, and we may even stabilize areas that are at risk of future weakening or have already been weakened and distorted by scar contracture following previous surgery:

1. Strengthen the junction of the caudal and dorsal segments of the L-strut with a bridging graft between these two segments to help maintain straightness of the L-strut during the healing process when scar contracture forces are at play and threatening to twist the L-strut. This bridging graft may involve either cartilage or bone.
2. If already crooked, score the concave side of the twisted dorsal or caudal septum, and batten the scored area with a battening spreader graft, or bilateral spreader grafts, or a battening caudal septal graft, to maintain the now straightened septum (►**Fig. 1**). Battening grafts may be either cartilage or bone.
3. If there is wound healing–related tension that has caused a buckling associated scar contracture at the junction of the caudal and dorsal segments of the L-strut, correction may be achieved by completely breaking the tension on the buckled component by complete cartilage transection of that area (►**Fig. 2**), followed by repositioning of the caudal strut posteriorly onto the remnant dorsal strut, and suture securing these two segments to one another. This reduces tension on the construct, and serves as a native battening-type spreader graft, which can further be reinforced with additional stabilizing spreader grafts.

Revision septoplasty is frequently performed to address redeviation or remnant septal deviations following prior surgery. As opposed to primary septoplasty, the long-term success of revision septoplasty has been variable and studies show discrepancies in patients' subjective and objective measures of success—that is, subjective measures of improvement have, in some studies, been shown to deteriorate even in the setting of an objectively surgically corrected septum.[37] A study by Gillman et al showed that septal deviations persistent from prior surgery most commonly involved the dorsal or caudal septum, the dorsal cartilaginous septum (92%) or the anterior bony septum (the perpendicular plate of the ethmoid bone, 79%), and the caudal septum (72%).[27] A separate study conducted by Derin et al pinpointed pathologies that were unaddressed during primary surgery—caudal septal deviation-nostril asymmetry was reported in 20% of cases.[12]

Revision septoplasty requires special attention when addressing the cartilaginous versus bony septum.[25] Given the complexity of revision septorhinoplasty involving septal reconstruction, facial plastic surgeons often advocate for use of an external approach with subtotal reconstruction or extracorporeal septoplasty techniques, which allow for both increased flexibility and visualization of key anatomical structures and complete control of the final construct.[25] Several studies have highlighted the usefulness of using spreader and/or batten grafts in reconstructive surgery involving septal deviation.[38–40] In fact, Sclafani et al used simple geometric models to examine forces affecting the nasal valve after dorsal reduction and spreader graft placement and showed that spreader grafts are helpful in offsetting the reduction in cross-sectional area of the nasal valve.[41] We, too, have had excellent success with complex reconstructive techniques in revision rhinoplasty where prior septoplasty has been performed, but we have also found it to be unnecessary in the vast majority of cases, including those where there is a residual dorsal and caudal

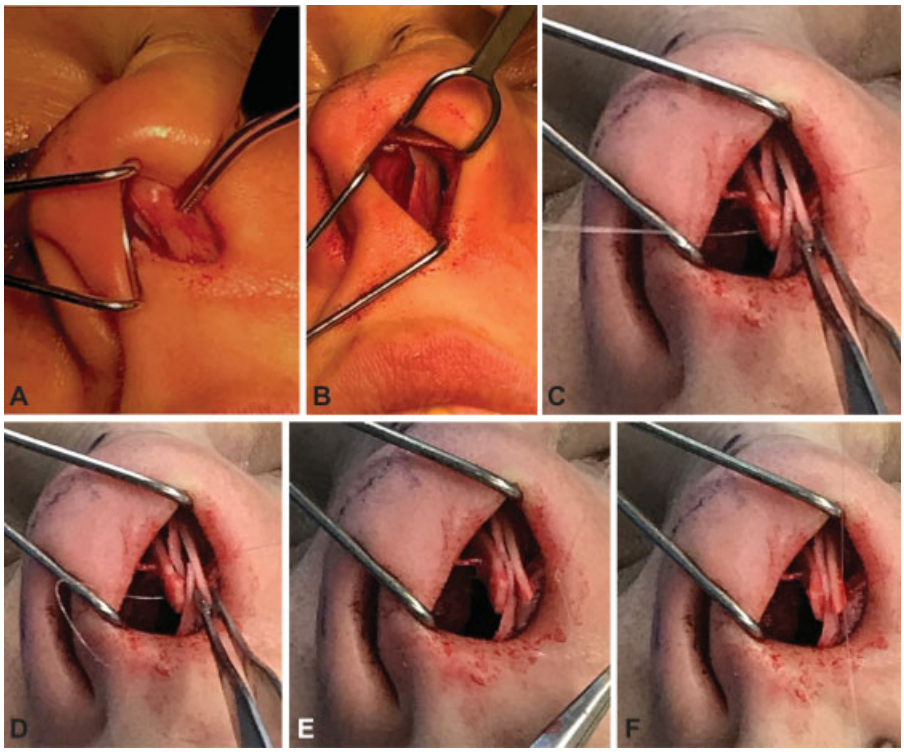

Fig. 1 (A–F) Endonasal placement of spreader grafts to help stabilize that freed up segment of septal cartilage, showing how the segment can go from crooked to straight with the help of endonasal spreaders.

deviation of the L-strut following prior septorhinoplasty. We find it more simple, yet extremely effective, to approach the nose through an endonasal approach in which most of the established support mechanisms are left untouched, and we strengthen, thicken, and straighten the L-strut construct to provide for improved functional and aesthetic outcomes. We have found decreased overall operative time, minimized local tissue and postoperative edema, and faster recovery time. In fact, Kayabasoglu et al described a retrospective study for their "marionette septoplasty" technique for severe, caudal nasal septal deviation whereby their technique required significantly less surgical time and resulted in a significantly shorter duration of postoperative edema with no statistically significant difference with respect to nasal

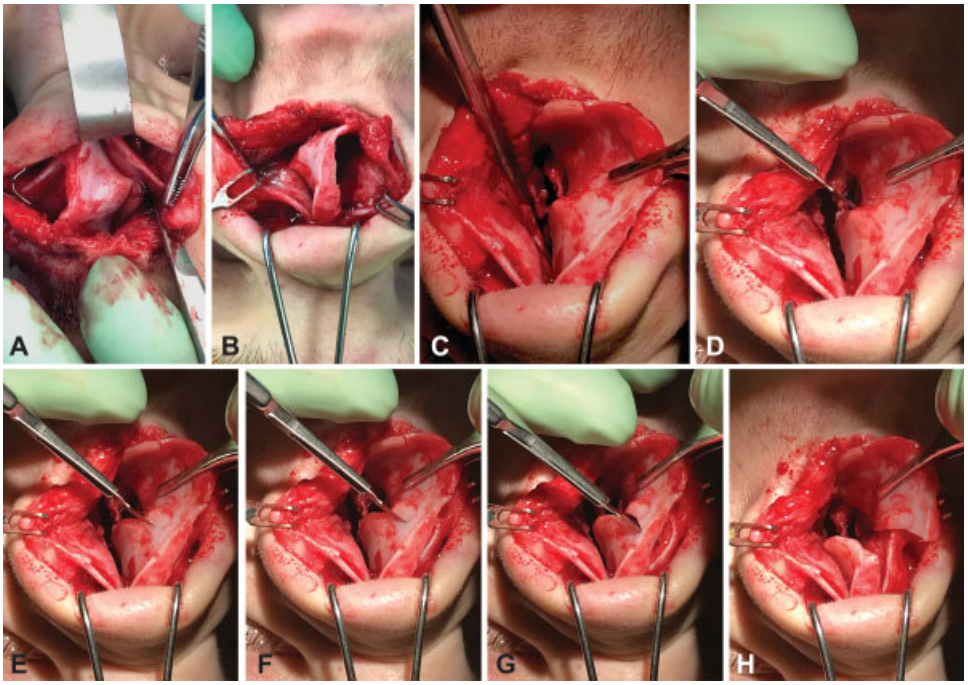

Fig. 2 (A–H) Severe caudal septal deviation corrected with complete transection at the point of greatest tension.

function and tip support.[42] Ultimately, the choice of an open versus closed/endonasal approach is left to the experience, comfort, and discretion of the operating surgeon. Chaaban and Shah described the indications for open septoplasty and Gubisch reported improved outcomes with the open approach later in his career as compared with the endonasal approach he used earlier in his career.[43,44] However, there have been no high-level, rigorous studies or analyses on the advantages of one approach over the other and the operating surgeon should weigh their own experience and comfort with the patient's needs and wishes as they decide on the best surgical approach.

Conclusion

The techniques discussed here highlight some tools available to rhinoplasty surgeons as they address complications associated with revision septorhinoplasty in patients with a history of septoplasty. We summarize some relevant surgical techniques, and then focus specifically on septal reconstruction in secondary septorhinoplasty which is often complicated by formation of scar tissue, the lack of autologous cartilage, in addition to tissue quality and anatomical changes related to the primary operation. Surgical changes in nasal anatomy and skin, unexpected healing factors, scar tissue formation, weakened cartilage, bone, and skin support, and reduced blood supply may all contribute to the need for revision rhinoplasty. Anticipating these issues and establishing strong structural support to withstand the wound healing forces helps improve results in primary surgery and reduce the rate of revisions. It is clear that the septum forms the primary structural support for the nose, and as such, it is the primary determinant of a well-built rhinoplasty.

Conflict of Interest
None.

References

1 Friedman O, Cekic E, Gunel C. Functional rhinoplasty. Facial Plast Surg Clin North Am 2017;25(02):195–199
2 Ghosh A, Friedman O. Surgical treatment of nasal obstruction in rhinoplasty. Clin Plast Surg 2016;43(01):29–40
3 Neaman KC, Boettcher AK, Do VH, et al. Cosmetic rhinoplasty: revision rates revisited. Aesthet Surg J 2013;33(01):31–37
4 Spataro E, Piccirillo JF, Kallogjeri D, Branham GH, Desai SC. Revision rates and risk factors of 175 842 patients undergoing septorhinoplasty. JAMA Facial Plast Surg 2016;18(03):212–219
5 East C, Kwame I, Hannan SA. Revision rhinoplasty: what can we learn from error patterns? An analysis of revision surgery. Facial Plast Surg 2016;32(04):409–415
6 Constantian MB. What motivates secondary rhinoplasty? A study of 150 consecutive patients. Plast Reconstr Surg 2012;130(03): 667–678
7 Adamson PA. The failed rhinoplasty. In: Gates GA. Current Therapy in Otolaryngology - Head Neck Surgery. 4th ed. Toronto, ON: BC Decker; 1990:137–144
8 Vuyk HD, Watts SJ, Vindayak B. Revision rhinoplasty: review of deformities, aetiology and treatment strategies. Clin Otolaryngol Allied Sci 2000;25(06):476–481
9 Goudakos JK, Daskalakis D, Patel K. Revision rhinoplasty: retrospective chart review analysis of deformities and surgical maneuvers in patients with nasal airway obstruction—five years of experience. Facial Plast Surg 2017;33(03):334–338
10 Chambers KJ, Horstkotte KA, Shanley K, Lindsay RW. Evaluation of improvement in nasal obstruction following nasal valve correction in patients with a history of failed septoplasty. JAMA Facial Plast Surg 2015;17(05):347–350
11 Becker SS, Dobratz EJ, Stowell N, Barker D, Park SS. Revision septoplasty: review of sources of persistent nasal obstruction. Am J Rhinol 2008;22(04):440–444
12 Derin S, Sahan M, Deveer M, Erdogan S, Tetiker H, Koseoglu S. The causes of persistent and recurrent nasal obstruction after primary septoplasty. J Craniofac Surg 2016;27(04):828–830
13 Spielmann PM, White PS, Hussain SS. Surgical techniques for the treatment of nasal valve collapse: a systematic review. Laryngoscope 2009;119(07):1281–1290
14 Friedman O, Cook TA. Conchal cartilage butterfly graft in primary functional rhinoplasty. Laryngoscope 2009;119(02):255–262
15 Ellis MS. Suture technique for caudal septal deviations. Laryngoscope 1980;90(09):1510–1512
16 Wright WK. Principles of nasal septum reconstruction. Trans Am Acad Ophthalmol Otolaryngol 1969;73(02):252–255
17 Neskey D, Eloy JA, Casiano RR. Nasal, septal, and turbinate anatomy and embryology. Otolaryngol Clin North Am 2009;42 (02):193–205, vii
18 Most SP, Rudy SF. Septoplasty: basic and advanced techniques. Facial Plast Surg Clin North Am 2017;25(02):161–169
19 Oneal RM, Beil RJ Jr, Schlesinger J. Surgical anatomy of the nose. Otolaryngol Clin North Am 1999;32(01):145–181
20 Freer OT. The correction of deflections of the nasal septum with a minimum of traumatism. J Am Med Assoc 1902;38(10):636–642
21 Paul N, Messinger K, Liu YF, Kwon DI, Kim CH, Inman JC. A model to estimate L-strut strength with an emphasis on thickness. JAMA Facial Plast Surg 2016;18(04):269–276
22 Mowlavi A, Masouem S, Kalkanis J, Guyuron B. Septal cartilage defined: implications for nasal dynamics and rhinoplasty. Plast Reconstr Surg 2006;117(07):2171–2174
23 Hwang K, Huan F, Kim DJ. Mapping thickness of nasal septal cartilage. J Craniofac Surg 2010;21(01):243–244
24 Metzenbaum M. Dislocation of the lower end of the nasal septal cartilage: a treatise dealing with dislocations of the lower end of the nasal septal cartilage in the new-born (injury sustained at birth), in infants and in young children and with their anatomic replacement by orthopedic procedures. Arch Otolaryngol 1936; 24(01):78–88
25 Sillers MJ, Cox AJ III, Kulbersh B. Revision septoplasty. Otolaryngol Clin North Am 2009;42(02):261–278, viii
26 Metzinger SE, Boyce RG, Rigby PL, Joseph JJ, Anderson JR. Ethmoid bone sandwich grafting for caudal septal defects. Arch Otolaryngol Head Neck Surg 1994;120(10):1121–1125
27 Gillman GS, Egloff AM, Rivera-Serrano CM. Revision septoplasty: a prospective disease-specific outcome study. Laryngoscope 2014; 124(06):1290–1295
28 Dyer WK, Kang J. Correction of severe caudal deflections with a cartilage plating rigid fixation graft. Arch Otolaryngol Head Neck Surg 2000;126(08):973–978
29 Kridel RW, Scott BA, Foda HM. The tongue-in-groove technique in septorhinoplasty. A 10-year experience. Arch Facial Plast Surg 1999;1(04):246–256, discussion 257–258
30 Kim DW, Gurney T. Management of naso-septal L-strut deformities. Facial Plast Surg 2006;22(01):9–27
31 Ballin AC, Kim H, Chance E, Davis RE. The articulated alar rim graft: reengineering the conventional alar rim graft for improved contour and support. Facial Plast Surg 2016;32(04): 384–397
32 Rees TD. Surgical correction of the severely deviated nose by extramucosal excision of the osseocartilaginous septum and

replacement as a free graft. Plast Reconstr Surg 1986;78(03): 320–330
33 Toriumi DM. How I do it head and neck and plastic surgery: A targeted problem and its solution: Subtotal reconstruction of the nasal septum: A preliminary report. The Laryngoscope 1994;104 (07):906–913
34 Gubisch W. Extracorporeal septoplasty for the markedly deviated septum. Arch Facial Plast Surg 2005;7(04):218–226
35 Haack S, Gubisch W. Reconstruction of the septum with an autogenous double-layered conchal L-strut. Aesthetic Plast Surg 2014;38(05):912–922
36 Most SP. Anterior septal reconstruction: outcomes after a modified extracorporeal septoplasty technique. Arch Facial Plast Surg 2006;8(03):202–207
37 Jeong JI, Hong SD, Kim SJ, Dhong H-J, Chung S-K, Kim HY. Temporal differences in improvement of nasal obstruction between primary and revision septoplasty. Am J Rhinol Allergy 2016;30(04): 134–138
38 Atespare A, Boyaci Z. The use of spreader grafts in revision septoplasty. J Craniofac Surg 2016;27(07):1656–1660
39 Kim D-Y, Nam SH, Alharethy SE, Jang YJ. Surgical outcomes of bony batten grafting to correct caudal septal deviation in septoplasty. JAMA Facial Plast Surg 2017;19(06):470–475
40 Jin HR, Kim DW, Jung HJ. Common sites, etiology, and solutions of persistent septal deviation in revision septoplasty. Clin Exp Otorhinolaryngol 2018;11(04):288–292
41 Sclafani AP, Victor W, Sclafani MS. Geometric modeling of the nasal valve. Facial Plast Surg 2017;33(04):444–450
42 Kayabasoglu G, Nacar A, Yilmaz MS, Altundag A, Guven M. A novel method for reconstruction of severe caudal nasal septal deviation: marionette septoplasty. Ear Nose Throat J 2015;94(06): E34–E40
43 Chaaban M, Shah AR. Open septoplasty: indications and treatment. Otolaryngol Clin North Am 2009;42(03):513–519
44 Gubisch W. Twenty-five years experience with extracorporeal septoplasty. Facial Plast Surg 2006;22(04):230–239