

Original Article

AN ANATOMICAL STUDY OF PRIMARY PATTERN OF ARTERIES OF UPPER LIMB WITH RELEVANCE TO THEIR VARIATIONS

Suresh Bidarkotimath¹, Ramakrishna Avadhani² & Arunachalam Kumar³

¹Assistant Professor, Department of Anatomy, A J Institute of Medical Sciences, Mangalore - 575 004.

²Professor & Head, Department of Anatomy, Yenepoya Medical College, Mangalore - 575 018.

³Professor of Anatomy, K.S. Hegde Medical Academy, Nitte University, Mangalore - 575 018.

Correspondence:

Arunachalam Kumar

E-mail : dean.kshema@nitte.edu.in

Abstract :

A detailed description of the vascular pattern of upper limbs especially their variations in their origin, course and branching pattern is of utmost importance anatomically in general and clinically in particular. These variations have drawn attention of surgeons, physicians, radiologist and interventionists due to the advanced surgical procedures practiced in vascular surgeries, plastic (reconstructive) surgeries and also for diagnostic and therapeutic approaches. 50 cadavers (100 upper limbs) were used for the study, which were dissected as the part of routine dissection for teaching undergraduate students at our institution. Length of the normal and variant arteries with mean, standard deviation, 'p' and 't' values are noted in each of the limbs. The following variations are observed - i) high division of brachial artery ii) higher origin of profunda brachii artery, iii) high origin of radial artery, iv) absence of common interosseous artery. The variations are of particular importance to the surgeons operating in the area, especially for those involved in vascular reconstructive surgeries. So it is prudent to do pre-operative studies of the brachial and antebrachial arteries and their branching patterns, to prevent possible complications post operatively.

Keywords: brachial artery, radial artery, ulnar artery, interosseous artery, accessory arteries.

Introduction :

The earliest of the studies cited on morphology of the upper limb arterial variation pattern provide insufficient statistical data. On the other hand there have been controversies about the terminology, as some authors advised topographical names to the brachial and antebrachial arteries while others believed that the arterial variations should be individual entities. The existence of arterial variations in the upper limb was explained, based on findings from adult cadavers thinking that these variations represent the embryonic stage¹. Variations have been observed in the arterial patterns of the upper limb, where there is absence of brachial artery, radial artery, ulnar artery, and their branches. Also there may be difference in the origin of these arteries and their courses which may interfere with therapeutic, diagnostic and surgical procedures². Recent study of anatomical variation testified the heterogeneity of our knowledge in this regard, where the median artery in the forearm is the point of study. It is reported that the incidence of variations ranges from 4.4 % to 8.3 % in various samples¹². Further

they have included nonhomogeneous sample or incomplete extremities and have failed to describe the related morphological feature of each of the separate patterns, throughout their whole length in the arm and forearm¹³.

Dimension of the brachial artery and flow-mediated dilatation (FMD) are associated with severity of cardiovascular diseases. Radial artery has been used for harvesting purpose in (CABG) coronary artery bypass grafting⁵. The radial forearm flaps are used in cosmetic surgeries, like for burns, contractures of neck, nasal reconstruction, correction of post-burn contractures of the neck and island flaps are used to replace soft tissue defects of the hand. Such flaps are also called as Chinese flap^{8,9}. The brachial and ante-brachial arteries are also the arteries of choice in treatment for chronic renal failure (CRF) for dialysis by making an autogenous fistula⁸. While considering all these factors, study of vascular pattern of upper limb and its variations assume great importance to prevent and avoid possible complications and achieve best results after operations as well as therapeutic and

diagnostic interventions. So the present work is an attempt to study the origin, course, relation, variations and anomalies of brachial and ante brachial arteries in human cadavers.

Materials and Methods:

Fifty cadavers (100 limbs) were used during a routine dissection carried out at our institute. Longitudinal incision was taken through the deep fascia along the midline of arm and then brachial artery was identified and cleaned and its origin and branches were identified. Venae comitantes were identified and removed, variations were noted.

Results:

The following parameters were observed in both the right and left limbs. 1) length of the normal and variant arteries. 2) Mean, Standard Deviation, 'p' and 't' values are noted. After statistical analysis the following were concluded– i) High division of brachial artery ii) higher origin of profunda brachii artery, iii) High origin of radial artery.

Measurements in male right and left upper limb

The length of the brachial artery varied between 23 ± 8.64 cm ($p=0.819$; $t=0.233$), radial artery between 22.99 ± 3.03 cm ($p=0.866$; $t=0.172$) and ulnar artery between 23.62 ± 1.67 ($p=0.853$; $t=0.18$).

Measurements in female- right and left upper limb

The lengths of the brachial artery varied between 22.65 ± 0.77 cm. ($p=0.819$, $t=0.233$), radial artery varied between 21.74 ± 0.53 cm. ($p=0.866$, $t=0.172$) and that of ulnar artery varied between 23.45 ± 0.53 cm. ($p=0.853$, $t=0.188$).

The values of point of origin of branches of brachial artery:
Male- right and left side

The lengths of the profunda brachii artery varied between 1.42 ± 0.84 cm ($p=0.281$, $t=1.091$), nutrient artery varied between 2.49 ± 0.16 cm ($p=0.427$, $t=0.801$), the superior ulnar collateral artery varied between 10.79 ± 0.25 cm ($p=0.566$, $t=0.578$) and that of inferior ulnar collateral artery varied between 15.79 ± 0.23 ($p=0.887$, $t=0.143$)

Female- right and left side

The profunda brachii artery 1.23 ± 0.22 cm ($p=0.722$, $t=0.363$), the nutrient artery 2.23 ± 0.11 cm ($p=1$, $t=0$), the superior ulnar collateral artery 10.75 ± 0.18 cm ($p=0.827$, $t=0.222$), and that of inferior ulnar collateral artery 15.77 ± 0.18 cm ($p=0.832$, $t=0.216$).

In all 50 cadavers, the brachial artery is continuation of axillary artery at the lower border of teres major muscle. Higher division of the brachial artery is noted in 2 cases. In both cadavers brachial artery bifurcated in the middle of the arm into radial and ulnar artery. Here the radial artery was seen passing superficial to the biceps brachii muscle slightly lateral to the bicipital aponeurosis, running along the lateral aspect of forearm, going directly towards the anatomical snuff box (Fig. 1 and 4). The ulnar artery, taking its short course in the arm, entered forearm deep to the bicipital aponeurosis. In a male cadaver aged 57 years in the course of dissection of axillary region, it was observed that the profunda brachii artery, originated from the 3rd part of axillary artery and continued downwards between medial and lateral roots of median nerve (Fig. 2). This artery was seen to be in close contact with the subscapularis muscle in its initial part. In a 30 year old male cadaver it was observed that the radial artery was originating at a higher level, it measured 44.2 cms. and originated from 2nd part of the axillary artery, medial to the medial root of median nerve descending downwards, obliquely in the front of the arm crossing the brachial artery lying superficial to it at the level of middle of the arm from medial to lateral side. Here the brachial artery continued as prominent ulnar artery. In a 55 year old male cadaver the common interosseous artery was absent, anterior interosseous artery was observed as a branch of ulnar artery and posterior as a direct branch of brachial artery.

Discussion:

Arterial variation in the upper limb was noted for the first time by von Haller in 1813. He made embryological studies on the variation of arterial pattern of upper limb but the exact findings were not obtained. The arteries develop from the axial trunk and extend from the axilla to the fingers. The proximal segment regresses to form the inactive adult pattern¹. The anomalous blood vessels may

be due to

- i) The choice of unusual paths in the primitive vascular plexuses.
- ii) The presence of vessels that are normally obliterated.
- iii) The disappearance of vessels that are normally retained.
- iv) Incomplete development.
- v) Fusion and absorption of the parts which are usually distinct (26).

McCormack in 1956 dissected 750 cadavers and found variations in respect of origin and course of the arteries of upper limb, the percentage of variations noticed by them was 18.53%. In this study bilateral variation occurred in 6.32%, while in 24.45% there was unilateral variation². Most of these variations occurred more frequently on the right side by a ratio of 1.2:1, the variations of the axillary artery as compared with those of origin of brachial artery showed disparity. The variant vessels arising from left side of the axillary artery were found with a ratio of 3:1 (18 left and 6 right), while those from the brachial artery were found predominantly on the right side in a ratio of 1.5: 1 (65 right and 43 left)²

Series of variations are observed in the human brachio-antebrachial arteries. The terminal branches of brachial artery in the cubital fossa shows two types of observations: (a) Bifurcation into ulnar artery and median-interosseus arterial trunk. (b) Three divisions of brachial artery: - the ulnar artery, common interosseus artery and the median artery³. Duplication of the brachial artery also occurred, one superficial and another deep to the median nerve. In some, superficial brachial artery ended by anastomosing around the elbow joint; whereas in other it continues lower in antebrachial region³. It is the homologue of the superficial brachial artery observed in monkeys, others called it as Vasa aberrantia⁶. Trifurcation of the brachial artery in left upper limb was observed, where the brachial artery gives ulnar, radial, and common interosseus arteries⁷

Structural and haemodynamic changes are observed in brachial artery by using Doppler ultrasound sonographic

evaluation. This has been done in healthy individuals to know the diameter of the brachial artery and flow velocities. This is done before and after exercises. The following parameters were observed; i) Diameter of the artery. ii) Peak systolic maximum velocity. iii) End diastolic minimum velocity. iv) Time averaged mean flow velocity. v) Volume of blood flow. vi) Flow wave form pattern. These measurements play important role in haemodynamic mechanism during arm exercises. They noticed that arterial diameter did not significantly contribute to the increase in blood flow during moderate intensity exercises¹⁰.

Dimension of the brachial artery and flow-mediated dilatation are associated with severity of cardiovascular diseases due to numerous risk factors like advancing age, stress and strain. Non invasive brachial analysis has useful approach for detailed study of cardiovascular system and impact of cardiovascular diseases and other risk factors in population. Radial artery has been used for harvesting purpose in cardiovascular diseases especially in coronary artery bypass grafting (CABG)⁵

Classification of arm arterial variations :

- I. Brachial artery passes in front of the median nerve and continues as:
 - A. Arteria brachialis superficialis superior.
 - B. Arteria brachialis inferior.
- II. Double brachial artery i.e., superficial and deep:
 - A. Brachialis superficial superior.
 - B. Brachialis inferior:-
 1. Superficial and deep reunite.
 2. Superficial continues as the radial:
 - a. without anastomosis.
 - b. with anastomosis.
 3. Superficial brachial continues as
 - a. Ulnar. b. Median.
 - c. Ulnar and Median.
 4. Superficial brachial as the radial and superficial antebrachial¹¹.

The primitive axial artery and the superficial brachial artery have been implicated in the normal morphogenesis of the arteries of the upper limb. The axillary, brachial and

interosseus arteries are derived from the primitive axial artery. Median artery arises as a branch of interosseus artery. This artery has a major haemodynamic function during SS III and SS IV (Singer's stage), and regresses at the SS V (-CS21) (-Carnegie's stage) remaining as a residual artery³.

Superficial brachial artery subdivides (found in 12.3% dissections) into three types:

- a) Those superficial brachial arteries which continue in cubital fossa and bifurcate as usual into radial and ulnar arteries (3.6%)
- b) Superficial brachial artery continues as radial artery and known as "High origin of the radial artery" (5 to 9%)
- c) Superficial brachial artery continues as ulnar artery and known as (2.8%) "High origin of the ulnar artery"¹².

In kinesiological study of the brachial artery dimensions, flow-mediated reactivity study are conducted to know the relative age related changes like dimensions, reactivity, and physical function. Research reveals an increase in resting Brachial Artery diameter with age up to approximately 65 years, after which change in diameter appears to reach plateau. The age-associated increase in resting Brachial Artery diameter may have been marked in the studies conducted in 19 out of 28 individuals, over the age of 80 years. The data obtained is compared with that of the mean Brachial Artery diameter in the study sample. In addition the peripheral resistance in arteriolar beds increases with age⁵.

Profunda brachii artery :

The profunda brachii (deep brachial) artery may arise from the third part of the axillary artery (16%, Anson) or in common with one or more branches of that vessel, (19% of individuals, Poynter), or arise as a common trunk with superior ulnar collateral (22%, Anson), axillary (16%) or anterior and posterior (7%, Anson) circumflex humeral artery¹³.

The origin of profunda brachii artery is quite variable. There are 7 types of origin for this artery.

Type I: Branch of brachial artery in 54.7% cases (55% by Anson, 1966)

Type Ia: Origin of arteria profunda brachii by 2 separate branches (seen in 0.7% dissections)

Type Ib: Origin of arteria profunda brachii by 3 separate branches (seen in 0.3% dissections)

Type II: Arising as a common trunk with superior ulnar collateral in 22.3% cases (22% by Anson, 1966)

Type III: Arising at lower border of teres major so can be considered to be arising from axillary or brachial in 8% cases.

Type IV: Branch of 3rd part of axillary artery in 8.7% cases (16.0% by Anson, 1966)

Type V: Arising as a common trunk with posterior circumflex humeral in 4% cases (13% by Keen, 1961 and 7% by Anson, 1966)

(Former includes 6% cases before entry of posterior circumflex humeral into quadrangular space and 7% cases after its entry into quadrangular space.)

Type VI: Arising as a common trunk with subscapular and both circumflex humeral from axillary artery in 0.7% cases.

Type VII: Absent arteria profunda brachii in 0.7% cases¹⁴.

Radial artery :

Instances of the origin of the radial artery proximal to the intercondylar line formed the largest group of gross variations. Such variations were observed by McCormack in 107 cadavers and the frequency is 14.27%, of all specimens studied and 77% of all variations. Out of this group 16 variations arise from axillary artery (2.13% of total 11.5% of variations) whereas 91 arise from some part of the brachial artery (12.14% of total, 65.5% of variations)².

The variations of radial artery are into 2 groups:

Type I: Variant which is more common involves a single dorsal division and is entirely superficial as in the case described by Gruber (1870).

Type II: Dorsal division further dividing into 2 branches, superficial and deep, as described by Quain (1844)¹⁵.

On the basis of type of anastomotic connection without reference to the point of origin, the radial artery is divided into four groups:

Group I:-The radial artery has no significant gross anastomosis with other major vessels in their course through the arm and forearm.

Group II: - Anastomosis is established with the deep or regular brachial artery in the antecubital region, the communicating vessel in those passes anterior to the biceps tendon.

Group III: The radial artery anastomosis with brachial artery and passes posterior to the biceps tendon.

Group IV: The radial artery anastomosis with the median artery in the forearm².

In another variety an atypical radial artery (ARA) was found in routine dissection. The atypical radial artery was present in left upper limb of an 82 year old female cadaver. The second part of the axillary artery gave typical thoraco-acromial trunk and a second branch that arose more distally. The atypical radial artery ran parallel to the brachial artery and terminated as the sole contribution to the deep palmar arterial arch and did not contribute to the superficial palmar arch. The radial artery arose from superficial brachial artery in 5% of cases¹⁰.

High origin of radial artery was seen in approximately 12.5% of cases. Out of that only 0.2% of low origin of the radial artery was reported¹². The absence of radial artery has been rarely reported with an estimated incidence of less than 0.03%⁴. The higher origin of the radial artery found by an author, wherein he noticed that radial artery originated from the medial side of the brachial artery at a higher level than usual, which was 16.7 cm below the coracoid process. Then the artery crossed over the brachial artery running to the lateral side and descended in front of the forearm over the aponeurosis of the biceps brachii muscle¹⁶. Atypical radial artery, which arose from the second part of the axillary artery; it gave typical thoracoacromial trunk and second branch more distally. This gave lateral thoracic artery proximally, and the thoracodorsal artery and a typical radial artery where it terminated as the sole contribution to the deep palmar arterial arch and not giving a branch to superficial palmar arch¹⁰.

Radial artery variations were observed in 9.6% patients who had undergone transradial coronary intervention (TRI), where ultrasonography of the radial artery was performed prospectively in 115 patients selected to undergo elective TRI. They include 6 tortuous configurations (5.2 %), two stenoses (1.7 %); two hypoplasias (1.7 %) and one radioulnar loop (0.9 %). The hypoplastic radial arteries and the radioulnar loop were inaccessible for catheterization and coronary intervention was planned via the femoral artery¹⁷.

In recent advances the radial artery is used in reconstructive micro vascular surgeries and also in plastic surgeries. The Chinese forearm flap based on the radial artery is extremely versatile. The radial forearm flap is ideal for intra-oral reconstruction, where a thin palpable predominantly hair-less skin is used to replace oral mucosa. The forearm flap is fascio-cutaneous flap based on the radial artery. Venous drainage is provided by venae comitantes of the artery^{8,9}

Ulnar artery:

The argument would be postulated that the ulnar artery system was the second to develop likewise the superficial brachial-radial arteries. A superficial ulnar artery was first to develop and later anastomotic connections develop in the cubital fossa between the brachial and superficial-ulnar artery, after which the proximal part of the superficial artery degenerated or atrophied. The distal part of the ulnar artery is derived from the medial terminal branch of the anterior interosseus artery¹.

The incidence of variations of superficial ulnar artery ranges from 0.6% to 9.4%. High origin of superficial ulnar artery was observed, where the frequency of unilateral variations is higher than bilateral. In living persons, Hazlett postulated a presence of superficial ulnar artery in 2.7% cases out of 542 persons studied by inspiration and palpation method¹⁸.

The existence of superficial ulnar artery has been documented by various investigators. Weathersby found 3 cases in 451 upper limbs (0.6%); Quain found 29 cases in 442 upper limbs (6.8%); Rodriquez-Baeza found 8 cases in

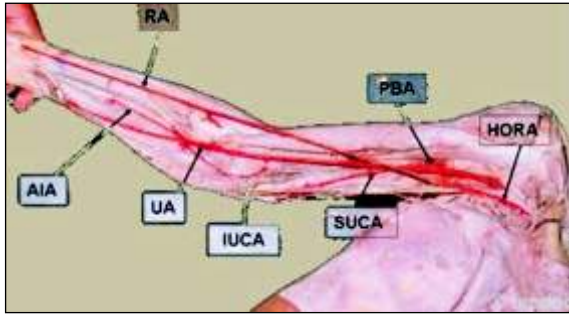


Fig: 1 HORA – high division of radial artery, SUCA – superior ulnar collateral artery, IUCA – inferior ulnar collateral artery, UA – ulnar artery AIA – anterior interosseous artery

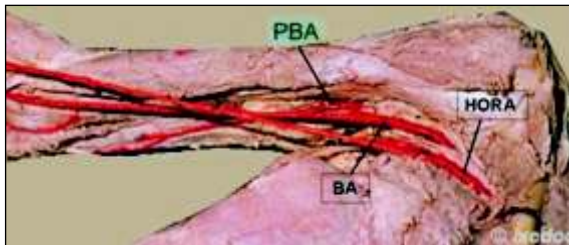


Fig 2: HORA – high division of radial artery, BA – brachial artery, PBA – profunda brachii artery

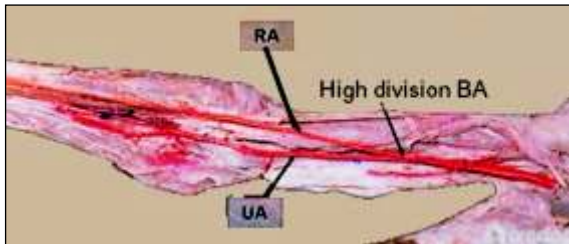


Fig 3: BA - brachial artery, UA - ulnar artery, RA – radial artery

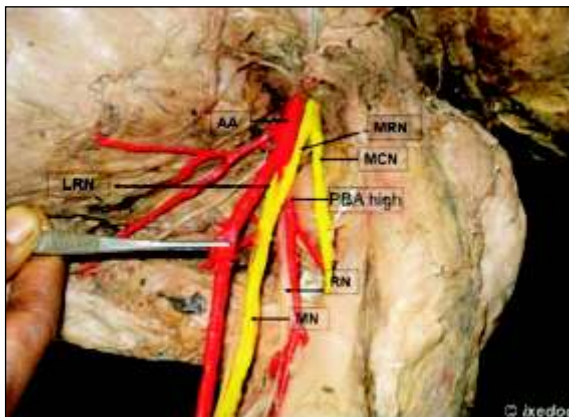


Fig 4 : PBA –profunda brachii artery, RN – radial nerve, LRM- lateral root of median nerve, MRM – median root of median nerve. MN – median nerve, AA – axillary artery

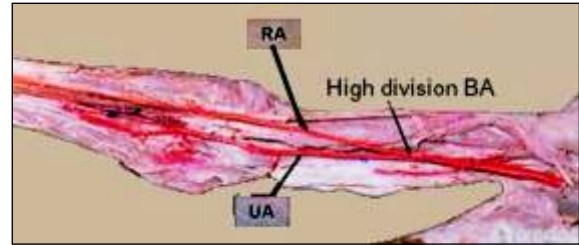


Fig: 4 BA - brachial artery, RA- radial artery, UA - ulnar artery

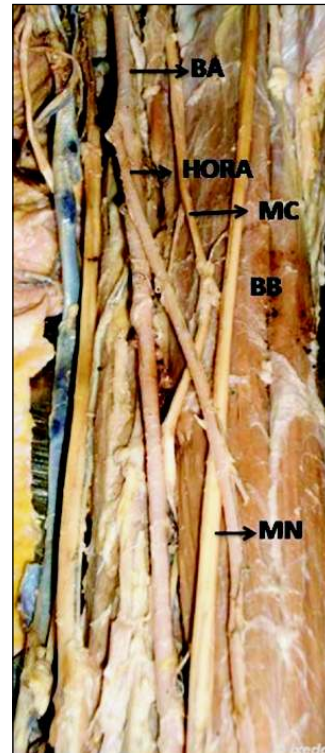


Fig 5: HORA – high division of radial artery, MN –median nerve, MC – medial cutaneous nerve, BB – biceps brachii

151 upper limbs (5.3%); Nakatani found that superficial ulnar artery in 150 upper limbs (0.7%); Ugletta and Kadir found 1% by the angiographic method. Devansh reported the incidence of superficial ulnar artery in 9.2% during the elevation of radial flap and 9% in Indians (18). In a separate study the ulnar and radial arteries were running superficial to superficial flexor group of muscle in 75% cases. In a rare case of variations of brachial artery the superficial ulnar artery originating from deep brachial artery was observed(19,20). In living persons, Hazlett postulated a presence of superficial ulnar artery in 2.7% cases out of 542 persons studied by inspiration and palpation method¹⁸.

In the present study the variations of brachial artery were found in three cases, which is 10% of the 60 limbs

dissected. The profunda brachii artery was arising from 3rd part of axillary artery, in one instance of 60 limbs dissected (1.6%). As followed according to Type IV, Type V, Type VI, classification¹⁴. The radial artery arising from 2nd part of axillary artery out of 60 limbs dissected (1.6%).

Conclusions :

In the present study, the values of length, point of origin of the arteries of right and left upper limbs were compared. On applying significant tests the values were found to be statistically significant. Structural and haemodynamic

changes were observed in brachial artery by using Doppler ultrasound sonographic evaluation. We noticed that arterial diameter did not significantly contribute to the blood flow increase during moderate intensity exercises.

In recent advances the radial artery is used in reconstructive micro vascular surgeries and also in plastic surgeries. The Chinese forearm flap based on the radial artery is extremely versatile. The radial forearm flap is ideal for intra-oral reconstruction to replace oral mucosa.

References :

- Rodriguez Niedenuhr M, Vazpuez T, Parkin IG and Sanudo JR. Arterial pattern of upper limb: update of anatomical variations and embryological development. *Eur J Anat* 2003; 1:21-28.
- McCormack LJ, Cauldwell EW, Anson BJ. Brachial and antebrachial arterial patterns. *Surg Gynecol Obstetr.* 1953; 96: 43-54.
- Bacza- Rodriguez A, Nebot J, Ferreria B, Reina F, Perez J, SanudoJR. An anatomical study and ontogenetic explanation of 23 cases with brachio-antebrachial arteries. *J Anat* 1995; 187:47- 479.
- Poteat W. Report of a rare human variation: Absence of the radial artery. *Anat Rec* 1986; 214:89-95.
- Christina M King. Brachial artery dimensions, Flow mediated reactivity, and physical function in older adults. Louisiana State University and Agricultural and Mechanical College. Dept of Kinesology. 2004 May.
- Kazuya Yoshinaga, Ichiro Tanil and Kodo Kodama. Superficial brachial artery crossing over the ulnar and median nerves from posterior to anterior: embryological significance. *Anatomical Science International.* 2003; 78(3):177-180.
- Nakatani Toshioi, Tanaka Shigenori. Superficial brachial artery continuing as the common interosseous artery. *J Anat* 1997; 199:155-157.
- Rodriguez-Niedenuhr M, Burton GJ, Deu J and Sanudo JR. Development of the arterial pattern in the upper limb of staged human embryos: normal development and anatomic variations. *J Anat* 2001; 199:547-566.
- Rodriguez-Niedenuhr M, Sanudo JR, Vazpuez T, Nearn L, Logan B and Parkin I. Anastomosis at the level of the elbow joint connecting the deep or normal brachial artery with major areterial variations of the upper limb. *J Anat* 2000; 196:115-119.
- Marios Loukas and Brian Curry. A case of an atypical radial artery. *Clin Anat* 2006; 19:706-707.
- Ozcan Hasan, Oztekin Pelin Seher, Zergeroolu Ali Murat, Eroz Gulriz, Fycycylar Hakan, Ostuner Evren. Doppler ultrasound evaluation of the structural and hemodynamic changes in the brachial artery following two differ exercise protocols. www.dirjournal.org
- Patanaik VVG, Kasley G, Singla Raju K. Branching pattern of brachial artery-A morphological study. *J Anat Soc India.* 2002; 51(2):176-186.
- Icten N, Sully Y, Tuncer I. Variant high-origin radial artery: a bilateral case. *Surg Radio Anat* 1996; 18(1):63-6.
- Nakatani T, Tanaka S, Mizukami S: Superficial brachial arteries observed in bilateral arms. *Kaibogaku Zasshi.* 1996 Aug; 71(4):308-12.
- Wood SJ, Arahams PH. Bilateral superficial radial artery at the wrist associated with a radial origin of a unilateral median artery. *J Anat* 1997; 189:691-693.
- Sargon MF, Tanyeli E, Surucu HS, Yazar F, Arifoglu Y. A complicated variation of the upper extremity vascularisation. *Kaibogaku Zasshi.* 1996 Jun; 71(3):211-4.
- Naoyuki Yokoyama, Satoshi T, Masahiko O, Yutaka K, Satoshi Hoshion et al. Anatomic variations of the radial artery in patients undergoing transradial coronary intervention. *Cath and Cardio Inter.* 2000 April; 49(4):357-362.
- Cuneyt Bozer, Enis Ulucam, Tune Kutoglu. A case of originated high superficial ulnar artery. *Tarkia Journal of Sciences* 2004; 2(3):70-73.
- Hollinshead WH., *Anatomy for Surgeons.* 2nd Ed. New York: Harper and Row, Publishers; 1969.
- Sadeghi HM, Sicillano S, Reyhler H. The use of ulnar microvascular free flap as an emergency solution after a complication during radial forearm free-flap raising: A case report. *Int J Oral Maxillofac Surg.* 1997 Aug; 26(4):287-9.
- Ganzales-Compta X. Origin of the radial artery from the axillary artery and associated hand vascular anomalies. *J Hand Surg (Am)* 1991 Mar; 16(2):293-6.
- Hennerer M and George J. High incidence of the median artery of the forearm on a sample of recent South American cadavers. *J Anat* 1992; 180:185-188.
- Patanaik VV Gopichand, Kasley G, Singla Raju K. Anomalous course of radial artery and a variant of deep palmar arch- A case report. *Anat Soc India.* 2000 Jun; 49(1):54-57.
- Foucher G, vanGenechten F, Merel N and Michon J. A compound radial artery forearm flap in hand surgery: an original modification of the Chinese forearm flap. *British Journal of plastic Surgery.* 1984; 37:139-148.
- Jayakumari S, Gayatri Rath and Jyoti Arora. Unilateral double axillary and brachial arteries: Embryological basis and clinical implications. *Int. J. Morphol.* 2006; 24(3):463-468.
- Dorros G, Lewin RF. The brachial artery method to transluminal internal mammary artery angioplasty. *Cathet Cardiovas Diagn.* 1986; 12(5):341-6.