Article published online: 2020-05-04

NUJHS Vol. 2, No.3, September 2012, ISSN 2249-7110
Nitte University Journal of Health Science

Case Report

HYPERHOMOCYSTEINEMIA AND PULMONARY EMBOLISM WITHOUT DEEP VEIN THROMBOSIS IN A YOUNG PATIENT PRESENTING AS PNEUMONIA - A RARE CASE REPORT

Akshatha Rao Aroor[1], Nazir Rahim Attar[2], Rama Prakasha S.[3], Dileep K.S.[4], Raghav Sharma[5], P. S. Prakash[6]

[1 & 3]Assistant Professor, [2 & 5]Professor, [6]Professor and HOD, Department of Medicine,
[4]Assistant Professor, Department of Orthopaedics, K.S. Hegde Medical Academy,
Nitte University, Deralkatte, Mangalore - 575 018, Karnataka, India.

Correspondence:
Akshatha Rao
Assistant Professor, Dept. of General Medicine, K. S. Hegde Medical Academy, Deralakatte, Mangalore - 575 018
E-mail : aksdil5@hotmail.com

Abstract :

We report a 40 year old male who presented with fever, dyspnoea, right sided pleuritic chest pain and hemoptysis. His physical examination and chest X-ray revealed features of right sided consolidation with pleural effusion. Worsening of his condition despite adequate antibiotic therapy prompted us to consider an alternative cause. Repeat ECG after 3 days showed S1q3T3 pattern. CT angiogram evidenced thrombus in right pulmonary artery and doppler study of both the lowerlimbs showed normal superficial and deep venous system. Hypercoagulation workup revealed high levels of homocysteine. This is a rare case report of hyperhomocysteinemia presenting as pulmonary embolism without documented deep vein thrombosis, and the patient presented with classical clinical and radiological findings of pneumonia.

Keywords : Pulmonary embolism, homocysteine, pneumonia, deep venous thrombosis

Introduction :

High levels of homocysteine increases the risk of deep vein thrombosis(DVT), pulmonary embolism, ischemic heart disease and stroke. [1,2] Few cases of hyperhomocysteinemia complicating deep vein thrombosis and pulmonary embolism have been reported in literature. [3] However, reported cases of pulmonary embolism in the absence of DVT are very rare. [4] Moreover, given the overlapping clinical features of pneumonia and pulmonary embolism, there is a considerable potential for confounding these diagnoses, especially when the risk factors for the latter is low. DVT with pulmonary embolism (PE) may present with a similar clinical, radiological and laboratorial characteristics of community acquired pneumonia, representing a diagnostic challenge to the physician, especially in its difficulty in the differential diagnosis during treatment process. [5] Here we report a case of pulmonary embolism due to high levels of homocysteine without deep vein thrombosis.

Access this article online
Quick Response Code

Case report :

A 40 year old male nonsmoker with no known systemic disease was admitted to our hospital with one week history of high grade fever, dyspnoea, productive cough with hemoptysis and right sided pleuritic chest pain. On admission his physical examination revealed toxic looking man with tachypnoea (respiratory rate 26 per minute), tachycardia (heart rate 110 per minute), fever (temperature 101^{0}F), cyanosis with SPO_2 84% at room air, normal blood pressure and crackles in right infraxillary area with features of right sided pleural effusion. Chest X-ray showed right lower zone consolidation with right sided effusion. [Figure 1] Sputum culture revealed *Acinetobacter baumanii* and the patient was treated with antibiotics as per culture and sensitivity pattern.

Base line ECG showed sinus tachycardia. Repeat ECG after 3 days revealed S_1Q_3T3. 2D ECHO showed dilated right atrium and right ventricle with pulmonary hypertension, PASP of 60mmHg and normal left ventricular function. [Figure 2] D-dimer was positive and CT angiogram showed thrombus in right pulmonary artery. [Figure 3] His hematological investigations are shown in table 1. Serum homocysteine level was elevated (observed value: 26.56 micromol/l, normal: 3.7 to 13.9 micromol/l) and plasma protein C activity was decreased (observed value: 45%, normal: 67-195%). Serum vitamin B12 level was 450 pg/ml (normal: 200 to 900), serum folic acid level was 6 ng/ml (normal 3 to 16). Rest of the hypercoagulation profile work-up which included protein S activity, lupus anticoagulant, antiphospholipid level antibodies and antithrombin activity were normal.

Discussion :

Hyperhomocysteinemia has been identified as an independent risk factor of atherosclerotic and thromboembolic disease. It can result from either genetic or nutritional disturbances. Hyperhomocysteinemia is commonly caused by genetic alteration in enzymes involved in homocysteine metabolism, dietary deficiency of folic acid, vitamin B12 or vitamin B6, chronic renal insufficiency, lifestyle factors (smoking, chronic alcohol, high coffee intake), end-stage diabetes, hypothyroidism, systemic lupus erythematosus, hyperproliferative disorder and medications (methotrexate, sulphonamides, or antacid). Elevations of homocysteine of 16 to 30, 31 to 100 and >100 micromol/litre are classified as mild, moderate and severe hyperhomocysteinemia respectively. The increased risk of venous thrombosis in general population due to mild hyperhomocysteinemia remains unclear. Toxic effect of homocysteine on vascular endothelium is one of the hypothesis on the mechanism by which hyperhomocysteinemia causes thrombosis.

Clinically, features of pulmonary embolism are of consolidation/effusion, and diagnosis may be delayed in mild cases and often mistaken for pneumonia. [6] PE can present with cough, fever, chest pain, hemoptysis, C-reactive protein elevation and pulmonary opacity, so that bacterial pneumonia could represent a confounding diagnosis. [7] Noninfectious diseases should also be suspected and included in the differential diagnosis of patients with presumptive diagnosis of pneumonia but who present with treatment failure or disease progression, especially young patients or those without comorbidities.

In our patient, coagulation profile was normal except for mild elevation of homocysteine levels and low plasma protein C activity. Venous doppler of both the lower limbs did not reveal evidence of DVT. Common causes of hyperhomocysteinemia were ruled out by normal values of vitamin B12, folic acid and renal function tests. There was no leg pain, no swelling during initial presentation. Also, pulmonary infection may increase the risk for venous thromboembolism (VTE). In previous literature Alikhan et al., reported that acute respiratory infection was an independent risk factor in the generation of venous thrombosis. [8] Accurate diagnosis of PE is important as mortality is substantial without treatment. Study done by D A Sandler concluded that DVT was present in at least 83% of patient with fatal pulmonary embolism. [9] In the remainder, it is thought that the thrombus would have already dislodged and embolised. [10] Also, some asymptomatic subjects might have had subclinical thrombosis that no one was able to diagnose before some complicated situation. Vitamin B12 and folic acid supplementation is known to lower the homocysteine concentrations regardless of the cause. Hence patient was treated with vitamin B12 and folic acid along with adequate dose of heparin infusion followed by oral anticoagulant. Patient was asymptomatic at discharge and at follow up for upto 6 months.

In conclusion, an unusual presentation of pneumonia in young patients merit special attention, and a high index of suspicion is warranted for early detection of pulmonary embolism in a young patient without obvious risk factors for the same for appropriate therapy and prevention of mortality. It also emphasizes the importance of assessment of homocysteine levels in all patients presenting with pulmonary embolism, especially in those with unprovoked thromboses (without acquired risk factors for VTE) and in younger individuals.

Table 1: Investigation reports

Investigation	Patient values	Normal values
Hb%	11.8g%	13-17gm%
Total leucocyte count	12,300/cu.mm	4,000-10,000/cu.mm
Differential count	N75%,L20%,E5%,M0%	N40-80%,L20-40%,E1-6%,M2-10%
ESR	90mm/hour	0-15mm/hour
Random blood glucose	112mg/dl	70-150mg/dl
Blood urea	39mg/dl	13-45mg/dl
Serum creatinine	1.4mg/dl	<1.4mg/dl
Total protein	8.5g/dl	6.6-8.3g/dl
Albumin	4.4g/dl	3.5-5.0g/dl
Total bilirubin	2.0mg/dl	<1.0mg/dl
Direct bilirubin	1.0mg/dl	<0.25mg/dl
SGOT	100mg/dl	<40mg/dl
SGPT	109mg/dl	<40mg/dl
Alkaline phosphatase	120U/L	60-170U/L
Sodium	137.2mmol/L	135-148mmol/L
Potassium	4.4mmol/L	3.5-5.0mmol/L

Figure 2: 2 D echocardiography showing dilated right atrium and right ventricle.

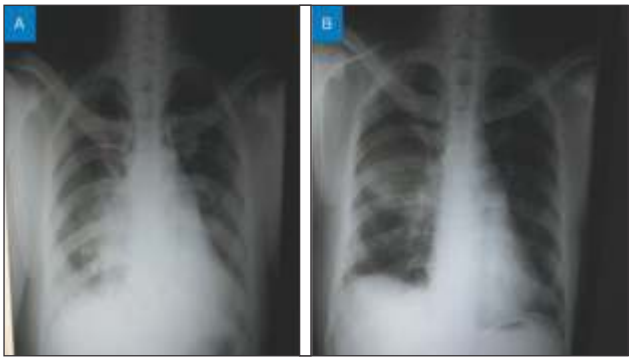

Figure 1: A. Chest X-ray on admission showing right lower lobe consolidation/effusion. B. Repeat chest X-Ray after four weeks showing resolution of the opacity with clear CP angle.

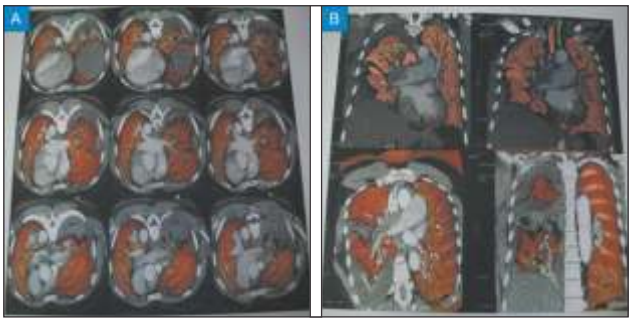

Figure 3: CT pulmonary angiogram showing large filling defect in the right main pulmonary artery extending into the lower lobe arteries with infarction/consolidation of right lower lobe. It also evidenced dilated right atrium and right ventricle with minimal right sided pleural effusion.

References :

1. Ueland PM, Refsum H, Beresford SAA and Vollset SE. The controversy over homocysteine and cardiovascular risk. Am J Clin Nutr 2000;72:324–32.
2. Selhub J, Jacques PF, Bostom AG, D'Agostino RB, Wilson PW, Belanger AJ et al. Association between plasma homocysteine concentrations and extracranial carotid-artery stenosis. N Engl J Med 1995;332:286–91.
3. S I Dani, S Thanvi, J M Shah, J Prajapti, S Jain, H Joshi. Hyperhomocysteinemia masquerading as pulmonary embolism. The Journal Of Association Of Physicians Of India 2003;51:914-5.
4. Caldera A, Mora J, Kotler M, Eiger G. Pulmonary Embolism in a Patient With Pernicious Anemia and Hyperhomocysteinemia. Chest 2002;122; 1487-1488.
5. Alves dos Santos JW, Torres A, Michel GT, de Figueiredo CW, Mileto JN, Foletto VG, Jr., de Nobrega Cavalcanti MA. Non-infectious and unusual infectious mimics of community-acquired pneumonia. Respir Med 2004;98:488-94.
6. Hampson NB. Pulmonary embolism: difficulties in the clinical diagnosis. Semin Respir Infect 1995;10:123-30.
7. Rosendaal FR. Thrombosis in the young: epidemiology and risk factors. A focus on venous thrombosis. Thromb Haemost 1997;78:1-6.
8. Alikhan R, Cohen AT, Combe S, Samama MM, Desjardins L, Eldor A, Janbon C, et al. Risk factors for venous thromboembolism in hospitalized patients with acute medical illness: analysis of the MEDENOX Study. Arch Intern Med 2004;164:963-8.
9. Sandler DA, Martin JF. Autopsy proven pulmonary embolism in hospital patients: are we detecting enough deep vein thrombosis? Journal of Royal Society of Medicine 1989;82:203-05.
10. Riedel M. Acute pulmonary embolism: pathophysiology, clinical presentation and diagnosis. Heart 2001;85:229-40.