

STUDY OF ACCESSORY FORAMEN TRANSVERSARIA IN CERVICAL VERTEBRAE

Pretty Rathnakar¹, Remya K.² & Swathi³

^{1,3}Assistant Professors, ²Lecturer, Department of Anatomy,
K.S. Hegde Medical Academy, Nitte University, Deralakatte, Mangalore.

Correspondence :

Pretty Rathnakar

Assistant Professor, Department of Anatomy, K.S Hegde Medical Academy, Deralakatte, Mangalore.

E-mail : prettyshrinath@gmail.com

Abstract:

The cervical vertebrae presents foramen transversaria in each transverse process. In all but the seventh cervical vertebra, the foramen normally transmits vertebral artery and vein and a branch from the cervicothoracic ganglion.

140 cervical vertebrae were studied. Variations were noticed in the number of foramen transversarium unilaterally and bilaterally. Variations in foramen transversarium may indicate the variation in course of vertebral arteries

Keywords : Foramen transversaria, cervical vertebra, vertebral artery

Introduction:

The cervical vertebrae presents foramen transversaria in each transverse process. In all but the seventh cervical vertebra, the foramen normally transmits vertebral artery, vein and a branch from the cervicothoracic ganglion.¹

The foramen transversarium is a result of the special formation of the cervical transverse processes. It is formed by the vestigial costal element fused to the body and the true transverse process of the vertebra. The vertebral vessels and nervous plexus are caught between these two bony parts. The foramen transversarium is closed laterally by the costotransverse bar, a thin plate of bone connecting the rib element to the original transverse process.²

The present study has important clinical implications for head and neck and vascular surgeons and radiologists.

Materials and Methods:

140 cervical vertebrae obtained from the Department of Anatomy and collected from the students were studied. Presence of unilateral or bilateral accessory foramen transversarium was noted.

Results:

8 out of 140(5.7%) vertebrae presented accessory foramen transversaria.

Unilateral Accessory Foramen Transversaria

5 vertebrae (3.6%) had unilateral accessory foramen (table).

Bilateral Accessory Foramen Transversaria

2 vertebrae (1.42%) had bilateral double foramen transversaria.

One of the vertebra showed multiple foramen transversaria on right side and incomplete accessory foramen transversarium on the left.


ACCESSORY FORAMEN	RIGHT	LEFT
DOUBLE	3 (2.14%)	1(0.7%)
INCOMPLETE	1(0.7%)	NIL

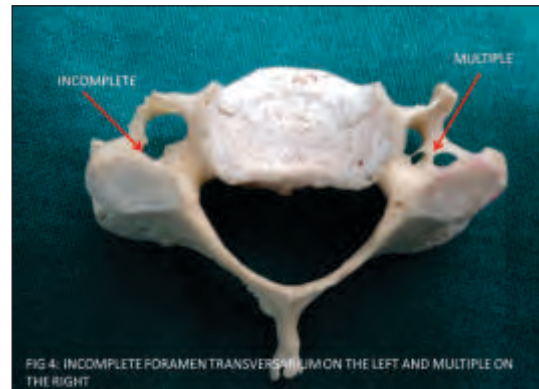
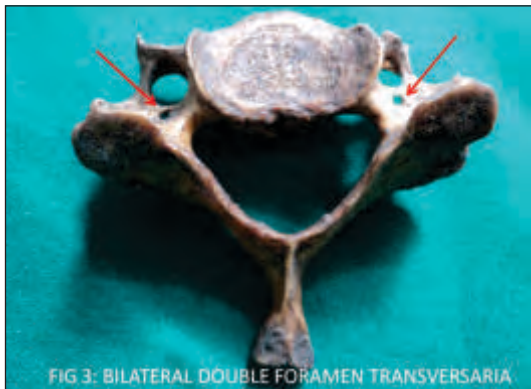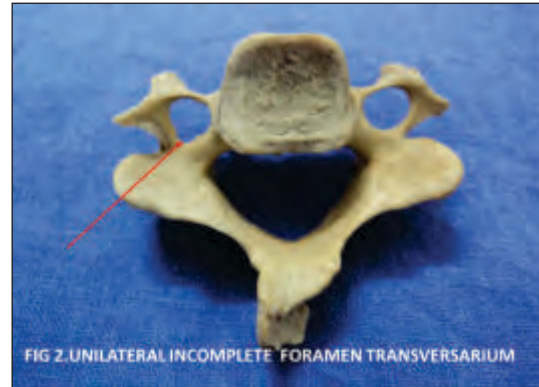
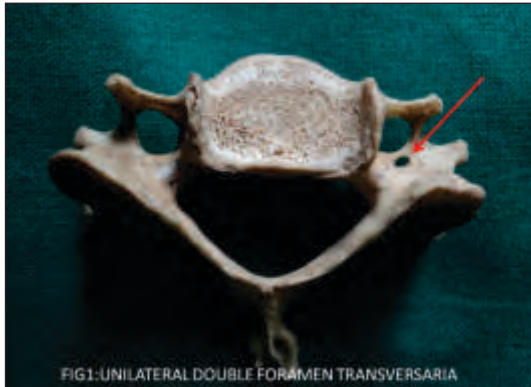Table : Unilateral Accessory Foramen Transversaria.

Discussion :

Foramen transversarium transmits vertebral artery and vein in all cervical vertebrae except seventh.

Since the vertebral vessels are responsible for the formation of the foramen transversarium, it can be assumed that variations in the course of the vertebral vessels will cause variation in foramen transversarium





vice versa variations of the foramen transversarium can be useful in estimating the variations of the vessels. An absence of foramen transversarium could mean absence of the vertebral artery or the artery running along the transverse process and not through the foramen transversarium. A narrowing of the foramina may indicate narrowness of the vessels.

Double foramen transversaria could mean duplicate vertebral arteries.²

The accessory foramina may be present to compartmentalise the contents of foramen transversarium.

The present study showed 5.7% vertebrae having accessory foramen transversaria ,unilateral (3.6 %)being more common than bilateral(1.42%).

A study reported 16 vertebrae having accessory foramen transversarium out of 200 cervical vertebrae studied .³

A study of 132 vertebrae reported double foramen transversaria unilaterally and bilaterally in two different

cervical vertebrae .⁴

Jarostaw et al reported accessory foramina most common at the level of C6.⁵

A study observed accessory foramen transversarium in 1.6% of the cases ,unilateral being more common than bilateral.⁶

El Shaarawy et al. observed that the accessory foramina transversaria were most common at the lower cervical vertebrae (C5, C6 and C7), mostly in C6.⁷

Conclusion :

In the present study we observed 8 out of 140 cervical vertebrae having accessory foramen transversaria . This is of clinical significance as the vertebral artery passes through it and presence of accessory foramen transversaria could mean variations in the number and course of vertebral artery. These variations are noteworthy to head and neck and vascular surgeons and radiologists in studying computed tomography and MRI scans.

References:

1. Standring S, Gray's anatomy. 40th Ed, 2008; pp718, Elsevier, Spain.
2. Taitz C, Nathan H, Arensburg B. Anatomical observations of the foramina transversaria. *J Neurol Neurosurg Psychiatry* 41; 19:170-176.
3. Sharma A, Singh K, Gupta V, Srivastava S. Double foramen transversarium in cervical vertebra an osteological study. *J. Anat. Soc. India* 2010; 59(2): 229-31.
4. Das S, Suri R, Kapur V: Double foramen transversaria: An osteological study with clinical implications. *Int Med J* 2005; 12:311-13
5. Ysocki J L, Bubrowski M, Reymond J, K Wiatkowski. Anatomical variants of the cervical vertebrae and the first thoracic vertebra in man. *Via medica* 2003; 62:357-63.
6. Murlimanju B.V, Prabhu V L, Shilpa K, Rai R, Dhananjaya K.V.N. Accessory Transverse Foramina in the Cervical Spine: Incidence, Embryological Basis, Morphology and Surgical Importance. *Turkish Neurosurgery* 2011; 21(3): 384-87.
7. El Shaarawy EAA, Sabry SM, El Gammaroy T, Nasr L E. Morphology and morphometry of the foramina transversaria of cervical vertebrae: A correlation with the position of the vertebral artery. *Kasr El Aini Medical Journal* June 2010 (series online). Accessed on May 2013.