

IMMEDIATE PARTIAL DENTURE PROSTHESIS - A CASE REPORT

Vinaya Bhat¹ & S. Sriram Balaji²

¹Professor, ²P.G. Student, Department of Prosthodontics and Implantology,
A.B. Shetty Memorial Institute of Dental Sciences, Nitte University, Mangalore - 575 018. Karnataka, India.

Correspondence

Vinaya Bhat

Professor, Department of Prosthodontics and Implantology, A.B. Shetty Memorial Institute of Dental Sciences,
Nitte University, Mangalore, Karnataka - 575 018, India.

Mobile : +91 94819 21180 E-mail : drvinayabhat@gmail.com

Abstract :

Prosthodontic management of a patient who requires immediate denture needs lot of understanding from the operator. Immediate dentures must be compatible both biologically and physiologically with the oral environment. Also the co operation exhibited by the patient towards the treatment protocol also plays a major role in its success. This case report describes a patient treated with immediate partial denture prosthesis.

Keywords : Immediate partial denture, Immediate tooth replacement.

Introduction :

A plethora of options are available for the replacement of missing dentition. It presents a greater challenge when teeth have to be replaced immediately after extraction. Whether by implants or by conventional acrylic dentures, immediate replacement of teeth has its own difficulty. In spite of the difficulties involved immediate denture is always an able answer for replacing lost dentition. Immediate denture is a dental prosthesis constructed to replace the lost dentition and associated structures of maxilla and mandible and inserted immediately following removal of remaining teeth¹.

An immediate denture must be compatible both biologically and physiologically with the oral environment. It should restore mastication, speech and deglutition to as near normal as possible. It must also be aesthetically compatible and preserve the remaining oral tissues. Immediate denture presents numerous advantages¹ such

as, a) the denture acts as a protective splint for the extraction wound and prevents injury, b) protection of the blood clot, c) no compromise in functions of oral cavity like speech, deglutition and

mastication, d) no period of edentulousness for the patient and e) maintaining of vertical dimension of occlusion. Though the advantages are seemingly convincing, it also has disadvantages¹ like a) stimulation provided by the natural teeth is absent, b) it involves a precise and time consuming protocol, c) absence of anterior try for aesthetics.

All the aforementioned factors must be kept in mind before proceeding with the construction of immediate denture. In this article the authors describe a case report of an immediate denture prosthesis.

Case Report :

A male patient aged 52 years reported to the department of Prosthodontics, A B Shetty Memorial Institute of Dental Sciences, Mangalore, with the chief complaint of missing upper posterior teeth. Routine case history was recorded. It revealed that maxillary posterior teeth were extracted two years ago and were not replaced. A detailed Intra oral examination revealed grade III mobility of remaining natural teeth which made fabrication of conventional cast partial denture prosthesis impossible. Other treatment possibilities were explored accordingly and fabrication of immediate denture was finalized. The treatment protocol of the patient was divided into three phases namely a) Examination of the patient b) consultation and interview of

Access this article online

Quick Response Code



the patient c) treatment phase.

Initial patient examination included evaluation of local and systemic factors like condition of the teeth to be extracted, position of the teeth in the arch, presence of either bony or soft tissue undercuts and muscular coordination of the patient. Also various systemic conditions which pose threat for the fabrication of prosthesis were examined and ruled out accordingly. An orthopantomograph of the patient was procured (Fig 1). In the interview phase, the patient was explained about the procedure involved in the fabrication of the prosthesis. The expectation of the patient from the prosthesis was noted down. The role of patient in maintenance and care of the dentures were also explained at this phase of treatment planning.

Extra oral and intra oral photographs of the patient were made. Extra oral photographs included profile and frontal view (Fig 2a, 2b). Intra oral photographs of maxilla and mandible (Fig 3a, 3b) were made with special care of anterior teeth which helps in shade selection. The existing vertical dimension at rest and occlusion were recorded and noted down.

The primary impression was recorded using irreversible hydrocolloid and casts were poured using type IV dental stone. Base for the cast were fabricated as per necessary dimensions. Temporary denture base was made on maxillary cast using auto polymerizing acrylic resin and occlusion rims were constructed. Tentative jaw relations were recorded and a facebow transfer was done. The casts were mounted on a semi-adjustable articulator (Fig 4). The teeth to be extracted were marked on the cast represented by a cross mark using a black marker pen. This was done for easy identification of the teeth to be extracted when referred to an oral surgeon. Posterior try in was done and tentative jaw relation was verified. The teeth to be extracted were scraped on the cast using BP blade. It was scraped in such a way that 2mm of the cast from the attached gingiva was removed (Fig 5a, 5b). This was done to compensate for the shrinkage of soft tissues post extraction. All the undercuts and sharp margins were rounded off on the cast. Teeth selection was done before

extraction keeping in mind the shade, shape and size of the teeth to be extracted, to mimic them as far as possible. Then teeth arrangement was carried out and wax up was done (Fig 6). The denture was processed using heat polymerized acrylic resin.

Then the patient was referred to the Department of Oral and Maxillo Facial Surgery, A B Shetty Memorial Institute of Dental Sciences, Mangalore, for extraction of the specified teeth. Extraction of the teeth were done as atraumatically as possible and sutures were placed across the extraction socket. Then the denture was tried in mouth with utmost care to prevent injury to the extraction socket. All the sharp margins were rounded off. Occlusion was analyzed using articulating paper and premature contacts in the denture were removed. Care was taken to maintain the vertical dimension to the original height (Fig 7). Post denture insertion instructions were given to the patient. He was asked not to remove the dentures for 24 hours after the insertion of the prosthesis. This aids in stabilization of the blood clot that was formed. Also need for a soft diet was strictly emphasized for the patient. Then the patient was scheduled for a 24 hour recall appointment (Fig 8a, 8b & Fig 9a, 9b).

On 24 hour recall check up, patient did not show any discomfort while chewing and speaking. The patient was asked to continue using the prosthesis and was rescheduled after a week for further check up. After one week sutures were removed and healing was found to be satisfactory (Fig 10a, 10b). Patient was happy with the denture and its performance during mastication. Patient was kept on a regular recall schedule to improve the fit of denture upon healing.

Discussion :

Immediate dentures provide a valuable and reliable treatment option when proper case selection, treatment planning and other procedures are followed carefully. This article highlights the procedures involved in fabrication of immediate denture.

Success of this treatment procedure depends on various

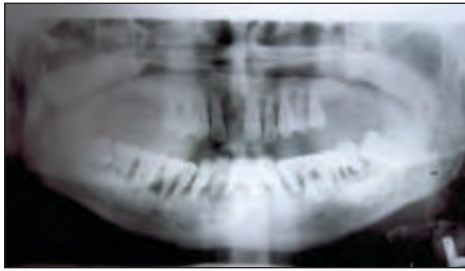


Fig. 1 : Orthopantomograph (OPG) of the patient



Fig. 2 a : Pre op frontal view

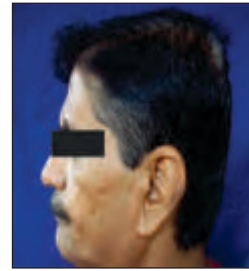

Fig. 2 b : profile view

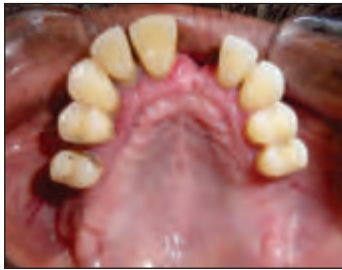

Fig. 3 a : Intraoral Maxilla

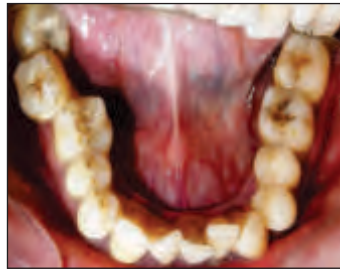

Fig. 3b Mandible



Fig. 4 : Mounted diagnostic casts.

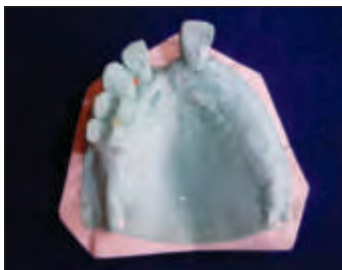

Fig. 5a : Modified cast - Maxilla

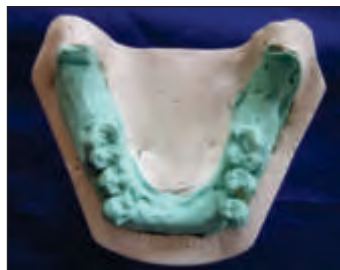

Fig. 5b : Mandible



Fig. 6 : Waxed up casts



Fig. 7 : Immediate post op

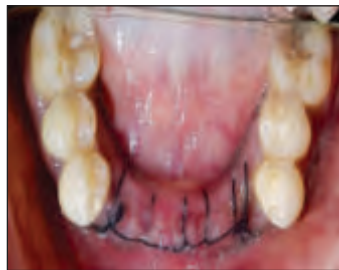

Fig. 8 a : One day post op intra oral mandible

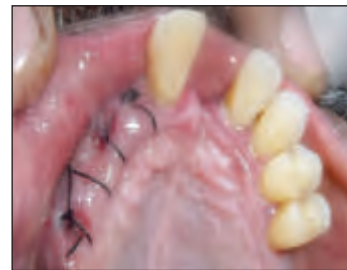

Fig. 8b : Maxilla



Fig. 9a : one day post op frontal view

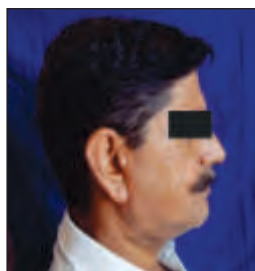

Fig. 9b : profile view

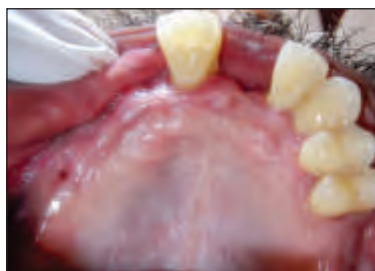

Fig. 10 a : One week post op maxilla

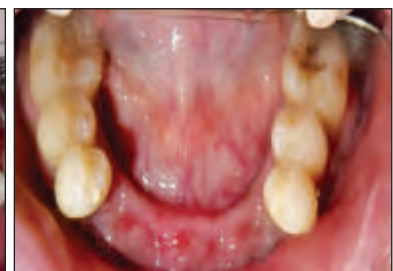

Fig. 10 b : Mandible

factors like case selection, diagnosis and treatment planning, meticulous surgical protocol, properly contoured and finished prosthesis and eagerness of the patient towards the treatment.

Case selection plays a major role in success of an immediate denture. Not all cases are eligible candidates for an immediate denture. This can be identified by initial examination of the patient. The patient must be free from medical conditions which may threaten the success of treatment.

The role played by oral surgeon in such a treatment procedure is very important. Good understanding between the prosthodontist and oral surgeon is essential. Teeth extraction must be carried out in a least traumatic way. Errors like fracture of cortical plate, tearing of muco periosteal flap must be avoided, which may reduce the rate of success of the treatment. When patients require total extraction and an immediate complete denture, a clear acrylic surgical stent may be fabricated to act as a guide to the surgeon while bone contouring. This will ensure a comfortable wearing of the prosthesis immediately after extraction.

Modification of cast at the intended area is very critical in the fabrication of an immediate denture. Standard² used three pencil markings placed at a distance of 2mm each to assist in cast modification. Jerbi³ scribed three markings on the facial surface dividing it into cervical, middle and apical thirds. Recently Phoenix and Fleigel⁴ proposed spatial modelling technique for cast modification. Though there are numerous techniques proposed, they are aimed at providing space for prosthetic teeth and need for avoiding radical alveoloplasty⁴.

A properly contoured and finished prosthesis greatly assists in healing of the wound. It will act as a stent or bandage to protect the wound from external trauma and prevents food debris and saliva coming in contact with the wound. Additionally it also protects the blood clot. Any sharp margins on the denture may cause inflammation of

the oral mucosa which may cause an additional burden on healing which must be avoided. The cameo surface of the denture must be polished well so that food accumulation will be prevented and oral hygiene can be maintained easily by the patient. Also the denture must not exhibit any harmful forces on the ridge which may cause blanching of the underlying tissues. Pressure indicating pastes can be used in such cases to indentify the pressure spots in tissue surface of the denture and relieve them accordingly.

The patient's cooperation towards the treatment also plays a major role in success. Philosophical patients are the best candidates for this kind of treatment procedure^{5,6,7}. To achieve this, the three stage treatment planning has to be done. In consultation interview phase all the procedures involved in fabrication of an immediate denture must be clearly explained to the patient. He/she must be psychologically counselled and motivated to accept the treatment. Also the expectation of the patient from the treatment must be addressed by the prosthodontist. As tissues heal after extraction there is a tendency of the dentures to lose their retention. Relining is necessary, which also has to be explained to the patient. Home care instructions for the patient must be verbally given and a written copy must be provided. Patient should be asked to report to the dental office if he/she has any discomfort with the prosthesis and it must be dealt with utmost care and attention.

All the above mentioned factors present a great role in success of this therapy. Also it must be kept in mind that this treatment option cannot be radically applied to all patients coming for replacement of missing teeth. When used and applied correctly immediate dentures serve the purpose with utmost success.

Acknowledgement :

The authors would like to acknowledge Dr. Prashanth Lowell Monis, intern, A B Shetty Memorial Institute of Dental Sciences, Mangalore, for rendering the surgical procedures as intended.

References :

1. Rahn O Arthur, Heartwell M Charles. Text book of complete dentures. New Delhi: Hancourt private limited; 2003.
2. Standard SG. Preparation of cast for immediate dentures. J Prosthet Dent 1958; 8:26-30.
3. Jerbi FC. Trimming the cast in the construction of immediate dentures. JProsthet Dent 1966; 16: 1047-53.
4. Phoenix RD, Fleigel JD. Cast modification for immediate complete dentures: Traditional and contemporary considerations with an introduction of spatial modelling. JProsthet Dent 2008; 100: 399-405.
5. Demer WJ. Minimizing problems in placement of immediate dentures. JProsthet Dent 1972; 3: 275-84.
6. Kelly KE. Follow- up treatment for immediate denture patients. J Prosthet Dent 1967; 1: 16-19.
7. Heartwell CM, Salisbury FW. Immediate complete dentures: An evaluation. JProsthet Dent 1965; 4: 615-623.