

ANTHROPOIDAL POUCH TECHNIQUE FOR HIGHLY RESORBED RIDGES

Laxman Singh Kaira¹ & Esha Dabral²

^{1,2}Consultant Dental Surgeon,

Veer Chandra Singh Garhwali Government Medical Sciences and Research Institute,
Srikot, Srinagar Garhwal, Uttrakhand

Correspondence

Laxman Singh Kaira

Flat No: 4, Faculty Residence, VCSGGMSRI, Srikot, Uttrakhand

Mobile : +91 87559 02525 E-mail : luckysinghkaira111@gmail.com

Abstract :

This article presents a case report on neutral zone technique used for treating a complete edentulous patient with resorbed ridges. It emphasizes on using materials available by the chairside to make impressions for resorbed ridges and to locate the neutral zone. It also presents certain modifications in technique for recording the neutral zone to achieving maximum prosthesis stability, comfort and function.

Keywords : Resorbed Ridges, Neutral Zone, Admix

Introduction :

The goal of dentistry is for patients to keep all their teeth throughout their lives in health and comfort. If the teeth are lost despite all efforts to save them, a restoration should be made in such a manner as to function efficiently and comfortably in harmony with the muscles of the stomatognathic system and the temporomandibular joints. With the increase in the life expectancy of the population, the numbers of complex complete denture cases also have been increasing. The treatment for these complex complete denture cases should be different from those of traditional complete dentures. In case of Atrophic mandible, Dental implants may provide stabilization of mandibular complete dentures, but in cases when it is not possible to provide implants on the grounds of medical risks, economic limitations or patients attitudes, an alternative technique should be thought¹.

Providing complete denture therapy to patients with atrophic residual ridges is challenging. These patients suffer ongoing diminution of denture foundation. Modern approaches often involve dental implant

therapy as a means of improving the denture foundation and supplementing the mechanics of prosthesis support, retention and stability. Regardless of implant availability, physiologically optimal denture contours and physiologically appropriate denture tooth arrangement should be achieved to maximize prosthesis stability, comfort and function for patients³. This article tries to present a novel method to achieve the above mentioned denture qualities by simple usage of materials available by the chair side with every dental clinician.

Case report :

A 58 year old female patient reported to the Department of Dentistry Veer Chandra Singh Garhwali Government Medical sciences and Research Institute, Srinagar Garhwal, Uttrakhand , with a chief complaint of missing teeth, difficulty in speech, mastication and compromised esthetics. The patient gave a history of mild hypertension and denied any symptoms of TMJ disorder or myofascial pain dysfunction.

On clinical examination, the patient had no gross facial asymmetry or muscle tenderness. The

mandibular range of motion was within normal limits. The TMJ, muscles of mastication and facial expression were

Access this article online

Quick Response Code



asymptomatic. On intraoral examination the maxillary and mandibular arches were completely edentulous. No gross abnormalities were detected in the overall soft tissue of the lips, cheeks, tongue and oral mucosa. The maxillary and mandibular arches were severely resorbed (Atwood's class IV) with shallow sulcus depth (Fig 1).

Treatment Objectives :

1. To rehabilitate the patient with complete denture therapy.
2. To achieve maximum prosthesis stability, comfort and function.
3. To locate the neutral zone and accordingly arrange the denture teeth and contour the complete denture polished surfaces.
4. To minimize the ongoing diminution of the residual alveolar ridges.

Treatment Procedure :

The patient was explained about the treatment procedure. As the residual alveolar ridges were

resorbed and the sulcus depth was shallow, a good preliminary impression with impression compound was difficult to achieve. To overcome this problem a three step impression making was planned.

- a) In the first step, alginate impressions of maxillary and mandibular arches were made using stock trays. The impressions were poured in dental plaster. Over this cast a double thickness full spacer (to provide space for impression material) and a custom tray was fabricated.
- b) The custom tray was trimmed checked in patients mouth and then a preliminary impression was made using admix material (a mix of impression compound and greenstick compound in the ratio of 3:7)⁴ (Fig 2). Impressions were poured in dental plaster and a special tray was fabricated with a full spacer.
- c) The special tray was trimmed and checked in the patient's mouth and then the border molded with green stick and final impressions were made in zinc oxide

eugenol impression paste.

- d) On the master casts obtained record bases and wax occlusal rims were fabricated. Jaw relations were recorded and mounted on an articulator.
- e) Following this the upper rim was removed and a second record base with a vertical occlusal stops and retentive loops to retain the material used to record the neutral zone was constructed. Similarly the lower record base was constructed .
- f) These new record bases were trimmed and checked in the patient mouth and admix material was placed over the retentive loops and the neutral zone was recorded. During this procedure the patient was ask to make the movements like pucker the lips, swallowing and sucking to record the neutral zone as shown in (Fig 3).
- g) The admix rims were relined with zinc oxide eugenol impression paste and over these rims plaster indices were constructed (Fig 4).
- h) The admix material was removed from the record bases and the indices rearranged. Then wax flowed into the space to make an occlusal rim to conform to the patient's neutral zone.
- i) The teeth were arranged according to these rims and the try-in was performed in the patients mouth(Fig 5).
- j) After try-in an external impression was made over the dentures using zinc oxide eugenol impression paste.
- k) Following this the dentures were processed, trimmed, polished and denture insertion was done.
- l) Post insertion instructions were given and patient recalled after 1 week(fig 6).

Discussion :

The neutral zone philosophy is based upon the concept that for each patient there exists within the denture space a specific region where the function of the musculature will not unseat the dentures and where forces generated by the tongue are neutralized by the forces generated by lips and

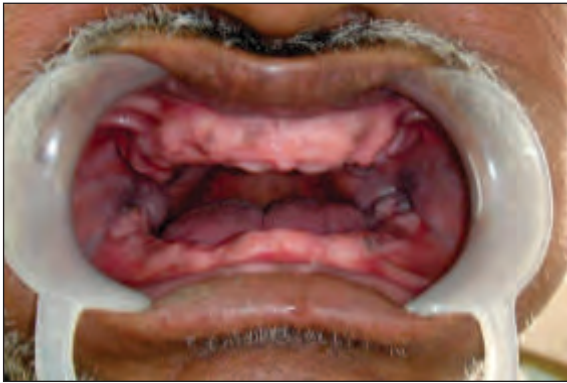

Figure 1 : resorbed Ridges

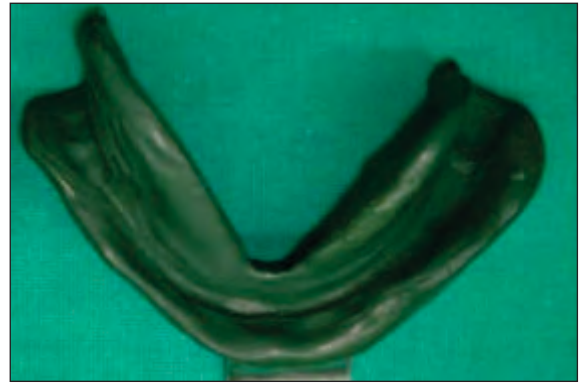

Figure 2 : Admixed Mandibular Preliminary Impression

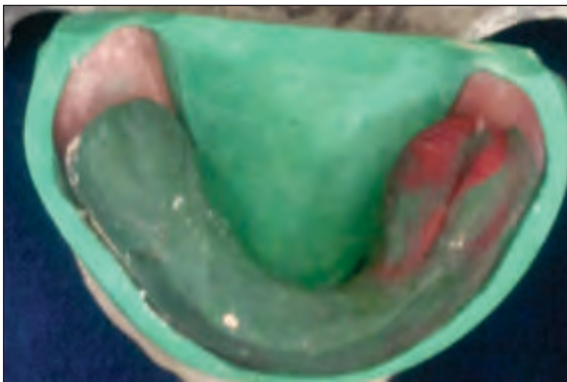


Figure 3 : Admixed Mandibular Occlusal Rim

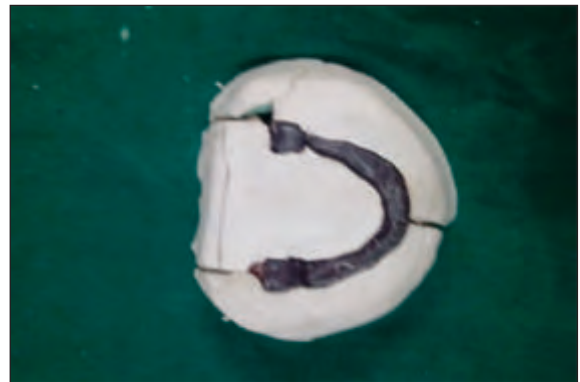

Figure 4 : Plaster Index

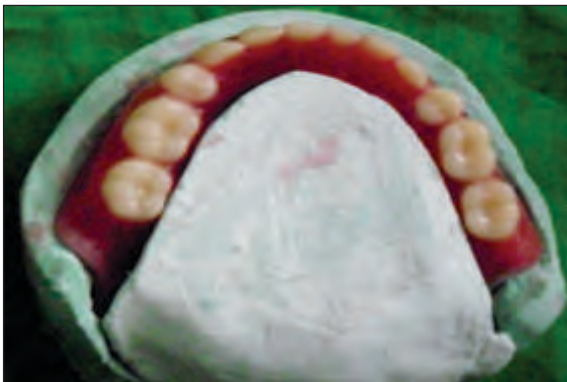

Figure 5 : Teeth Arrangement

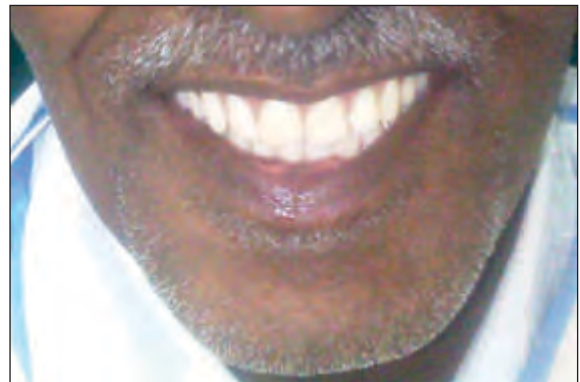

Figure 6 : Postoperative Photograph

cheeks. Since these forces were developed through muscular contraction during the various functions of chewing, swallowing they vary in magnitude and direction in different individuals.² When the residual alveolar ridges have resorbed significantly, denture stability and retention are more dependent on correct position of teeth and contour of the external surfaces of dentures. Keeping these factors in mind, neutral zone method was used for this particular case. The advantage of this method is that the changes that might occur in vertical dimension during recording of the neutral zone can be prevented by the

vertical occlusal stops. The entire procedure was aimed at using the materials that are available easily by the chair side with most of the clinicians.

Conclusion :

This article provides a novel approach in the management of completely edentulous patient with resorbed ridges. The technique described is simple which utilizes the routine materials used for denture fabrication, at the same time minimizing the errors and achieving the treatment goals.

References :

1. Victor E. Beresin; Frank J Schiesser, the neutral zone in complete and partial dentures.
2. The neutral zone in complete dentures, JProsthet Dent 2006;95(2):93-100.
3. The neutral zone revisited, from historical concepts to modern application, JProsthet Dent 2009;101:405-412.
4. The neutral zone impression revisited, Br Dent J 2005; Mar 12:198(5)269-72.
5. Prosthodontic treatment for edentulous patients. 9th edition ,Judson C.Hickey , George A Zarb , Charles L.Bolender.
6. Prosthodontic treatment for edentulous patients. 12th edition, George A Zarb , Charles L.Bolender.